

CASE REPORT

Complex chromosomal rearrangement involving 15q11-q13 interstitial triplication and duplication: A new case report of dysmorphic and neuropsychiatric features

Lekha Chilakamarri  | Estrella Lizbeth Mellin-Sanchez

University of Texas Rio Grande Valley
School of Medicine, Edinburg, Texas,
USA

Correspondence

Estrella Lizbeth Mellin-Sanchez,
Department of Pediatrics, University
of Texas Rio Grande Valley School
of Medicine, 1201 W. University Dr.,
Edinburg, TX 78539, USA.
Email: Lizbeth.mellin@utrgv.edu

Funding information

This research received no institutional
or private funding support or financial
support from grants

Abstract

Our patient is the first to encompass the full spectrum of reported features related to tetrasomy of the Prader–Willi Angelman Critical Region. She has a complex chromosomal rearrangement including an interstitial triplication reported in twelve cases till date and a rare interstitial duplication reported in only four cases till date.

KEYWORDS

15q11-q13 interstitial duplication, 15q11-q13 interstitial triplication, array CGH, autism spectrum disorder, copy number variants, under-represented populations

1 | INTRODUCTION

Chromosome 15 is particularly susceptible to structural variations (SV), such as deletions, duplications, triplications, and translocations. These abnormalities occur in recognized breakpoints (BP) numbered 1 to 5 encompassing the 15q11-q14 region.^{1,2} The identification and categorization of the SV breakpoints on chromosome 15 provide insight into the chromosomal and clinical features, which are more heterogeneous than previously thought.^{2,3}

The Prader–Willi/Angelman critical region (PWACR), located on the 15q11-q14 locus, is prone to forming complex chromosomal rearrangements (CCR). Deletions in this region are associated with two distinct and characteristic syndromes known as Prader–Willi syndrome (PWS) and Angelman syndrome (AS), both of which are associated with delayed developmental milestones, hypopigmentation, and various central nervous system pathologies.^{4,5} These classic symptoms allow clinicians to

more effectively establish the diagnosis of individuals with PWS/AS based on phenotypic patterns, and to confirm the diagnosis, methylation pattern, and/or deleted regions are commonly requested. With confirmatory array comparative genomic hybridization (CGH) studies, detailed analysis of variations in supernumerary marker chromosomes (SMCs) can lend itself to establishing clinical diagnostic criteria for more rare cases of gain in copy number of imprinted genes in this same region.^{2,3}

The reports of interstitial triplications of 15q11–q13 are scarce, and so far only 12 patients are reported in the literature.^{1,6–16} This syndrome leads to tetrasomy of this region, and the affected individuals correlate with a range of features including mild facial dysmorphism, moderate to severe behavioral and neurodevelopmental impairment, movement disorders, hypotonia, and seizures.¹⁶ In addition, interstitial duplication between BP3 and BP5 is a rare rearrangement, with only four patients reported in the literature.¹⁷ While deletions in this region are associated with

This is an open access article under the terms of the [Creative Commons Attribution-NonCommercial-NoDerivs](https://creativecommons.org/licenses/by-nc-nd/4.0/) License, which permits use and distribution in any medium, provided the original work is properly cited, the use is non-commercial and no modifications or adaptations are made.

© 2022 The Authors. *Clinical Case Reports* published by John Wiley & Sons Ltd.

severe cognitive and language impairment, copy number gain presents with a range of relatively milder symptoms.

With whole genome single nucleotide polymorphism (SNP) microarray, we were able to diagnose a child with a rare chromosomal rearrangement: a 15q11-13 interstitial triplication and a rare distal duplication, which represents another clinical manifestation of cytogenetic abnormality in this region. Here, we add a case to the literature and review rearrangements of the PWACR, exalting the importance of equal access to high-end genetic testing for children with medical complexity (CMC).

2 | CLINICAL REPORT

The patient is a Hispanic female and the first-born child of healthy, non-consanguineous parents. Pregnancy was complicated by unspecified maternal arrhythmias during the third trimester treated with metoprolol. Gestational age was 40 weeks by uncomplicated vaginal delivery. Birth weight was 3062 g (~35th centile), and length was approximately 48 cm (~32nd centile). During the neonatal period, she had a history of feeding difficulties and hypotonia. Her history is also significant for developmental delays, as she sat unaided after 1 year and walked at 3 years with several episodes of falling. Her verbal function was at a 2-year-old level at age 6, with an overall low level of function. Approximately at the age of two, she developed behavioral issues such as self-injury to the head, dermatophagia of the fingers, trichotillomania, and trichophagia, repetitive language, and motor stereotypes, preference for isolated play, and significant auditory defensiveness, establishing the diagnosis of autism spectrum disorder (ASD). Parents report sleep disturbance occurring for a few hours daily at night.

She had two episodes of seizure-like activity at the ages of 1 and 4 years. No further episodes of seizure-like activity have occurred. She participates in school for half days and receives developmental services through her school. Family history is significant only for a 4-year-old brother with ASD.

The patient was seen by our medical geneticist at age 6, with confirmed microarray testing from her primary care physician performed at age 18 months. Upon physical examination at the age of 6 years and 4 months, the child was 18.14 kg (~13th centile) and 116.21 cm (~42nd centile), with a BMI of 13.4 (~5th centile). The main dysmorphic features (Figure 1A) included bitemporal narrowing, arched eyebrows, epicanthus folds inversus, telecanthus, left strabismus, depressed nasal bridge, short nose, long and broad smooth philtrum, thin upper lip vermilion, everted vermilion of the lower lip, high and narrow palate, protruding and large ears with a prominent antihelix and

everted antitragus, and one cafe-au-lait macule on the left pectoral region. Patient exhibited proximal hypotonia, hyperlordosis, scoliosis, and syndactyly in two to three toes bilaterally. She also had an ataxic gait.

3 | METHODS

For SNP microarray analysis, genomic DNA was extracted from whole blood using Reveal[®] SNP Microarray Pediatric Kit. The assay evaluates whole-genome SNP-based copy number microarray analysis targeting 2.695 million-copy-number and allele-specific genome sites. Limitations of this assay include the inability to detect balanced rearrangements or low level mosaicism. Methylation status was determined by methylation-specific PCR and capillary electrophoresis using the Quest Diagnostics methylation assay with a blood sample.

We searched for all reported cases with 15q11-q13 triplication and relevant literature in PubMed. We analyzed reported variants and genomic locations using the NCBI GRCh37 hg19 database and ClinVar.

Consent for patient photographs to be reviewed and published was given by the patient's parents. Written informed consent for patient participation in this study was provided by one of the parents, and the Institutional Review Board approved the study at The University of Texas at Rio Grande Valley.

4 | RESULTS

An SNP-based chromosome microarray was performed on DNA from the proband, revealing a triplication and duplication mapped to the 15q11-q13 region. The multiplications are not yet reported in the Database of Genomic Variants (DGV, <http://dgv.tcag.ca/dgv/app/home>). No mosaicism was detected in the analysis but may still be present in other tissues below the level detectable by the array. The triplication was mapped to the 15q11.2q13.1 region, including the Prader-Willi/Angelman syndrome critical region, providing four doses of approximately 6.05 MB (chr15: 22,770,421–28,823,722, hg19). The triplication is continuous, presumed to be de novo, and the cause of the pathologic phenotype of the patient.

Furthermore, the duplication reported in the patient is composed of the more distal interstitial segment BP3 to BP5 corresponding to 15q13.1q13.3 and is approximately 3.48 MB (chr15: 28,958,779–32,439,233, hg19). Due to genomic imprinting in this region, phenotypic features of the triplication/duplication vary based on the parental chromosome of origin.

(A)



(B)

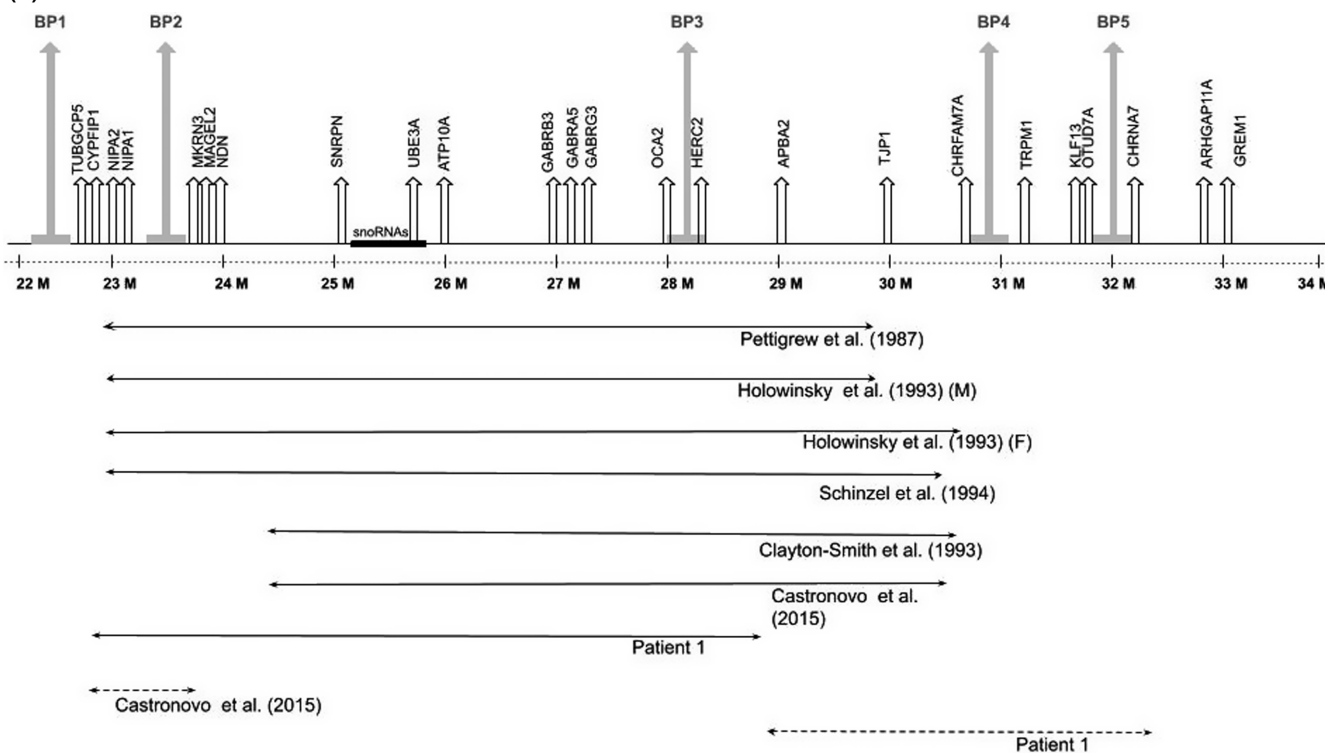


FIGURE 1 (A) Front facial views at ages 4, 5, and 6 years, respectively, showing bitemporal narrowing, arched eyebrows, epicanthus folds inversus, telecanthus, left strabismus, depressed nasal bridge, short nose, long, broad and smooth philtrum, thin upper lip vermillion, everted vermillion of the lower lip, high and narrow palate, protruding and large ears with a prominent antihelix and everted antitragus. (B) Schematic view comparing locations of triplications and complex chromosomal rearrangements of previously reported cases. Solid lines represent triplications, and dashed lines represent duplications in reported patients

Microarray results performed for both parents revealed no rearrangements in the PWACR. The father’s microarray results revealed a 16q23.1 deletion partially overlapping a

single disease-associated gene (ADAMTS18) and a region of homozygosity in chromosome 9q22.32-q31.2, reported as variants of uncertain significance likely unrelated to

the patient's condition. Microarray performed on the patient's mother revealed a lack of any rearrangements in this region. The patient's brother with ASD had negative results from microarray testing. Methylation studies were negative, and revealed both maternal and paternal alleles in the PWACR.

5 | DISCUSSION

We report a new case of interstitial triplication of chromosomal region 15q11-q13 in a patient who is the first to

display all phenotypic features previously recognized to be associated with this condition, as shown in Table 1.^{1,6-16} In addition, our patient is the fifth reported case to display a BP3-BP5 duplication, the rarest 15q13.3 copy number variant (CNV).¹⁷ Our patient's CCR spans the largest region reported so far of ~9.53 Mb, more than twice the length of the typical ~4 Mb length of deletions recorded in PWS/AS.²

A clear understanding of common breakpoint locations can improve our recognition of the effects of varying CNV in the PWACR. Most deletions and duplications in this region share breakpoint locations resulting in a largely

TABLE 1 Analysis of common phenotypic features among reported cases of 15q11-q13 triplication

Symptom/ Condition	Present patient	Castronovo et al. (2015) ¹⁶	Vialard et al. (2003) ¹⁵	Holowinsky et al. (1993) ⁸ and Ungaro et al. (2001) ¹ (M)	Holowinsky et al. (1993) ⁸ and Ungaro et al. (2001) ¹ (F)
Hypotonia	+	+	–	+	+
Seizures	+	+	+	–	–
Ataxia	+	+	–	–	–
Developmental delay	+	+	+	+	+
Intellectual delay	+	+	+	+	+
Autism spectrum disorder	+	+	–	–	–
Behavioral problems ^a	+	–	+	–	–
	Self-aggressiveness, dermatophagia of the fingers, trichotillomania, and trichophagia, repetitive language and motor stereotypes, preference for isolated play, and significant auditory defensiveness		Hyperactive behavior (6 years); no interest towards peers, only repetitive tasks (22 years)		
Dysmorphic features ^a	+	+	+	+	+
	Bitemporal narrowing, arched eyebrows, epicanthus folds inversus, telecanthus, left strabismus, depressed nasal bridge, short nose, long, broad and smooth philtrum, thin upper lip vermillion, everted vermillion of the lower lip, high and narrow palate, protruding and large ears with a prominent antihelix and everted antitragus, one cafe-au-lait macule on the left pectoral region, hyperlordosis, scoliosis, and syndactyly in two to three toes bilaterally	Arched eyebrows, hypertelorism, wide mouth	Long narrow face, prominent forehead, thick arched eyebrows, upward slanting palpebral fissures, long eyelashes, long nose, large and anteriorly rotated ears, small carp shaped mouth, micrognathia, and mild hyperkyphosis	Strabismus and high palate	Brachycephaly, round face, short forehead, mild frontal bossing, temporal hairline extended to the lateral eyebrows, mild synophrys, epicanthic folds, slightly upward slanting palpebral fissures, strabismus, broad nasal bridge and upturned nares, slightly small jaw, midhelical hypoplasia, hypertrichosis, and slightly tapering fingers

^aData collected from Castronovo et al. [16]; (+) feature present in patient; (–) feature not present in patient; (/) information not available.

consistent rearrangement length of ~4 Mb. These rearrangements usually share proximal breakpoints, BP1 and BP2, and distal breakpoints, BP3, BP4, and BP5. However, due to the use of different probes and PCR loci in previous studies, we can only speculate on the exact location of the more distal breakpoints, BP4 and BP5.²

Of the 12 previously reported cases, we could estimate the locations of six rearrangements with the provided cytogenetic information (Figure 1B). Four patients had a common proximal breakpoint location between BP1 and BP2, present in our patient as well.^{1,6,8,9} Two patients shared a proximal breakpoint distal to BP2.^{7,16}

These rearrangements resulted in a shared tetrasomy of the CYPFIP1, NIPA2, NIPA1, MKRN3, MAGEL2, NDN, SNRPN, UBE3A, ATP10A, GABRB3, GABRA5, GABRG3, OCA2, HERC2, and APBA2 genes. Of these six cases, four patients had a more distal breakpoint resulting in additional tetrasomy of the TJP1 gene.^{7-9,16} Till date, few of these genes have evidence for dosage pathogenicity¹⁹ <https://www.ncbi.nlm.nih.gov/clinvar/variation/VCV000397435.1>. While there is sufficient evidence for dosage pathogenicity of UBE3A and little evidence of pathogenicity for MAGEL2 and SNURF, this evidence is primarily related to deletion or methylation of the genes. However,

Clayton-Smith et al. (1993) ⁷ and Ungaro et al. (2001) ¹	Pettigrew et al. (1987) ⁶ and Ungaro et al. (2001) ¹	Reddy and Logan (2000) ¹⁴	Long et al. (1998) ¹³	Cassidy et al. (1996) ¹¹ and Robinson et al. (1993) ¹⁷	Chadwick et al. (1996) ¹²	Crawford et al. (1995) ¹⁰	Schinzel et al. (1994) ⁹ and Robinson et al. (1993) ¹⁷	Fraction of reported patients with feature
-	+	-	-	+	-	-	+	5/12 (41.7%)
-	-	-	+	-	-	+	+	5/12 (41.7%)
+	-	-	+	-	-	-	+	4/12 (33%)
+	-	+	+	+	+	+	+	11/12 (91.7%)
+	+	-	+	+	/	+	/	9/10 (90%)
-	-	-	-	-	-	-	+	2/12 (16.7%)
-	+	-	-	+	+	+	+	6/12 (50%)
	Compulsive eating			Violent and repetitive behaviors	Unspecified	Aggressiveness, pica	Inappropriate laughter, self-aggressiveness, and hyperactivity	
-	+	-	-	+	+	+	+	9/12 (75%)
	Cleft palate and small hands and feet			Wide mouth	Mild, unspecified	Broad nasal tip, underdeveloped anhelices, and large hands	Epicanthic folds, downward slanting palpebral fissures, exotropia, broad nasal bridge, broad and bulbous nasal tip, small and irregularly positioned teeth, prominent lateral palatine ridges, and mild pectus excavatum	

due to the few cases reporting tetrasomy of the PWACR, data are not yet available to propose pathogenicity of over-dosage of imprinted genes in this region.

Our patient is the second of twelve patients with an additional duplication involving the PWACR. While Castronovo's patient has a ~1.1 Mb duplication in the proximal region of the PWACR between BP1 and BP2, our patient displays a larger, more distal ~3.48 Mb duplication spanning between BP3 and BP5, a region involving more than 20 genes including *CHRNA7*.¹⁷

CHRNA7 gene encodes for the alpha-7 nicotinic acetylcholine receptor present in high concentrations in the hippocampus. Notably, this gene has been implicated as a dosage-sensitive gene contributing to conditions such as seizures and a range of mood disorders. Of the four reported cases of BP3-BP5 duplication, three patients report an associated phenotype, all of which include a neuropsychiatric component and cognitive deficits. In addition, two of the three reported phenotypes were also diagnosed with ASD, ADHD, and mood disorders such as anxiety, depression, or bipolar disorder.¹⁷ Given the severe neurological presentation associated with our patient, we hypothesize over-dosage of the *CHRNA7* gene contributes to the phenotype of ASD and impaired speech, cognition, and behavior, a unique combination of features associated with reported cases of 15q11-q13 triplication.

The patients with this condition have reported neurodevelopmental impairment in all the cases so far, and our patient supports this understanding that 15q11-13 triplication syndrome presents with DD especially affecting speech and cognitive function.^{1,6-16} Despite the severe neurological presentation associated with our patient, speech therapy has tremendously aided her progress, notable for the development of 100% intelligible speech and communication in 4-word sentences, with a dramatic increase in vocabulary size to more than 100 words. Physical therapy has improved the patient's hypotonia and gait. In addition, our patient has continued to develop a propensity for puzzles, dancing, and social interaction. While this focus on sufficient speech and behavioral therapies for our patient is a critical representation of the long-term benefits of early intervention, it also highlights the value of these services that may not be available to other minority CMC. Given our patient's inability to receive clinical genetic care until 4 years after her diagnosis via microarray and difficulty receiving information and treatment for sequelae of her disease process, such as her seizure disorder, we emphasize the need to expand specialized care to under-served regions. Further, with inadequate diversity and representation in genomic databases contributing to lack of diagnosis for minority children, we advocate for expanded access to and analysis of genetic studies to advance genotype-phenotype correlations in CMC.²⁰

In conclusion, the data provided by our study contribute to the developing genotype-phenotype correlation and analysis of breakpoints in the PWACR. As the complexity of breakpoint heterogeneity is revealed, the need for expanded genomic data diversity becomes increasingly necessary to better understand the pathogenesis of over-dosage of these imprinted genes, especially for under-represented population genomic databases. With expanded access to specialized genetic care, it will be possible to strengthen the diversity of genomic databases, paving the way for promising analysis of CCR to understand better the pathogenesis, prognosis, and treatment for complex-care children.

AUTHOR CONTRIBUTIONS

Lekha Chilakamarri and E. Lizbeth Mellin-Sanchez both contributed to the literature review, patient examinations, analysis of the data, and writing of the manuscript.

ACKNOWLEDGEMENTS

We thank the patient's family for their willingness and cooperation.

CONFLICTS OF INTEREST

We have no conflict of interest to declare.

DATA AVAILABILITY STATEMENT

The data that support the findings of this study are openly available in PubMed at the DOI numbers listed for references as seen above. The references numbered 2, 4, 6, and 8 were not publicly available and were acquired by request; these references are available from the corresponding author upon reasonable request. The reference numbered 11 is a public database available at the URL as listed above.

ETHICAL APPROVAL

All clinical research was conducted in compliance with ethical standards and standards of research involving humans, with IRB approval.

CONSENT

Written informed consent was obtained from the patient to publish this report in accordance with the journal's patient consent policy.

ORCID

Lekha Chilakamarri  <https://orcid.org/0000-0003-2296-0064>

REFERENCES

1. Ungaro P, Christian SL, Fantes JA, et al. Molecular characterization of four cases of intrachromosomal triplication

- of chromosome 15q11–q14. *J Med Genet.* 2001;38:26–34. doi:[10.1136/jmg.38.1.26](https://doi.org/10.1136/jmg.38.1.26)
2. Roberts SE, Maggouta F, Thomas NS, Jacobs PA, Crolla JA. Molecular and fluorescence in situ hybridization characterization of the breakpoints in 46 large supernumerary marker 15 chromosomes reveals an unexpected level of complexity. *Am J Hum Genetics.* 2003;73(5):1061–1072. doi:[10.1086/379155](https://doi.org/10.1086/379155)
 3. Wang NJ, Liu D, Parokony AS, Schanen NC. High-resolution molecular characterization of 15q11–q13 rearrangements by array comparative genomic hybridization (array CGH) with detection of gene dosage. *Am J Human Genetics.* 2004;75(2):267–281. doi:[10.1086/422854](https://doi.org/10.1086/422854)
 4. Buiting K. Prader-Willi syndrome and Angelman syndrome. *Am J Med Genet Part C Semin Med Genet.* 2010;154C:365–376. doi:[10.1002/ajmg.c.30273](https://doi.org/10.1002/ajmg.c.30273)
 5. Kalsner L, Chamberlain SJ. Prader-Willi, Angelman, and 15q11–q13 duplication syndromes. *Pediatric Clin.* 2015;62(3):587–606. doi:[10.1016/j.pcl.2015.03.004](https://doi.org/10.1016/j.pcl.2015.03.004)
 6. Pettigrew AL, Gollin SM, Greenberg F, Riccardi VM, Ledbetter DH. Duplication of proximal 15q as a cause of Prader-Willi syndrome. *Am J Med Genet Part A.* 1987;28A:791–802. doi:[10.1002/ajmg.1320280403](https://doi.org/10.1002/ajmg.1320280403)
 7. Clayton-Smith J, Webb T, Cheng XJ, Pembrey ME, Malcolm S. Duplication of chromosome 15 in the region 15q11–13 in a patient with developmental delay and ataxia with similarities to Angelman syndrome. *J Med Genet.* 1993;30:529–531. doi:[10.1136/jmg.30.6.529](https://doi.org/10.1136/jmg.30.6.529)
 8. Holowinsky S, Black SH, Howard-Peebles PN, et al. Triplication 15q 11–13 in two unrelated patients with hypotonia, cognitive delays and visual impairment. *Am J Hum Genet.* 1993;53:A125.
 9. Schinzel AA, Brecevic L, Bernasconi F, et al. Intrachromosomal triplication of 15q11–q13. *J Med Genet.* 1994;31:798–803. doi:[10.1136/jmg.31.10.798](https://doi.org/10.1136/jmg.31.10.798)
 10. Crawford EC, Lethco BA, Bealer D, Schroer RJ, Clarkson KB, Phelan MC. Interstitial duplication and triplication of 15q11–q13 confirmed by fluorescence in situ hybridization. *Am J Hum Genet.* 1995;57:A111(618).
 11. Cassidy S, Conroy J, Becker L, Schwartz S. Paternal triplication of 15q11–q13 in a hypotonic developmentally delayed child without Prader-Willi or Angelman syndrome. *Am J Med Genet Part A.* 1996;62:206 (A4).
 12. Chadwick D, Strasberg PM, Farrell S. Intrachromosomal triplication of proximal 15q. *Am J Hum Genet.* 1996;59:A114(627).
 13. Long FL, Duckett DP, Billam LJ, Williams DK, Crolla JA. Triplication of 15q11–q13 with inv dup(15) in a female with developmental delay. *J Med Genet.* 1998;35:425–428. doi:[10.1136/jmg.35.5.425](https://doi.org/10.1136/jmg.35.5.425)
 14. Reddy KS, Logan JJ. Intrachromosomal triplications: Molecular cytogenetic and clinical studies. *Clin Genet.* 2000;58:134–141. doi:[10.1034/j.1399-0004.2000.580208.x](https://doi.org/10.1034/j.1399-0004.2000.580208.x)
 15. Vialard F, Mignon-Ravix C, Parain D, et al. Mechanism of intrachromosomal triplications 15q11–q13: a new clinical report. *Am J Med Genet Part A.* 2003;118A:229–234. doi:[10.1002/ajmg.a.10164](https://doi.org/10.1002/ajmg.a.10164)
 16. Castronovo C, Crippa M, Bestetti I, et al. Complex de novo chromosomal rearrangement at 15q11–q13 involving an intrachromosomal triplication in a patient with a severe neuropsychological phenotype: CLINICAL report and review of the literature. *Am J Med Genet Part A.* 2015;167A:221–230. doi:[10.1002/ajmg.a.36815](https://doi.org/10.1002/ajmg.a.36815)
 17. Gillentine MA, Schaaf CP. The human clinical phenotypes of altered CHRNA7 copy number. *Biochem Pharmacol.* 2015;97(4):352–362. doi:[10.1016/j.bcp.2015.06.012](https://doi.org/10.1016/j.bcp.2015.06.012)
 18. Robinson WP, Binkert F, Giné R, et al. Clinical and molecular analysis of five inv dup (15) patients. *Eur J Hum Genet.* 1993;1(1):37–50.
 19. National Center for Biotechnology Information. ClinVar; VCV000397435.1, <https://www.ncbi.nlm.nih.gov/clinvar/variation/VCV000397435.1> (accessed March 19, 2021)
 20. Popejoy AB, Fullerton SM. Genomics is failing on diversity. *Nature News.* 2016;538(7624):161. doi:[10.1038/538161a](https://doi.org/10.1038/538161a)

How to cite this article: Chilakamarri L, Mellin-Sanchez EL. Complex chromosomal rearrangement involving 15q11–q13 interstitial triplication and duplication: A new case report of dysmorphic and neuropsychiatric features. *Clin Case Rep.* 2022;10:e05835. doi:[10.1002/ccr3.5835](https://doi.org/10.1002/ccr3.5835)