
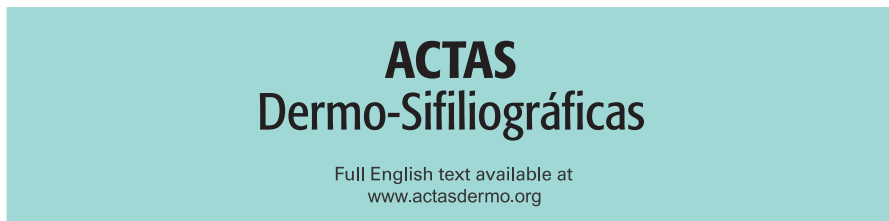




Since January 2020 Elsevier has created a COVID-19 resource centre with free information in English and Mandarin on the novel coronavirus COVID-19. The COVID-19 resource centre is hosted on Elsevier Connect, the company's public news and information website.

Elsevier hereby grants permission to make all its COVID-19-related research that is available on the COVID-19 resource centre - including this research content - immediately available in PubMed Central and other publicly funded repositories, such as the WHO COVID database with rights for unrestricted research re-use and analyses in any form or by any means with acknowledgement of the original source. These permissions are granted for free by Elsevier for as long as the COVID-19 resource centre remains active.



## CASE AND RESEARCH LETTER

### Erythrodermic Psoriasis Following SARS-CoV-2 Infection

#### Psoriasis eritrodérmica tras infección por SARS-CoV-2

Dear Editor:

Exacerbation of psoriasis during SARS-CoV-2 infection has been described in the literature. However, the occurrence of erythroderma remains a very rare manifestation with only a few cases worldwide.<sup>1,2</sup> We report a case of erythrodermic psoriasis following a moderate SARS-CoV-2 infection. The role of stress and the treatments used has been suggested but there is another hypothesis incriminating the virus itself directly.

#### Case report

A 55-year-old patient, followed for 3 years for localized plaque psoriasis, treated with dermocorticoids at the time of flare-ups, presented to the emergency room for a worsening of his psoriasis with the development of erythroderma. The clinical presentation occurred 10 days after a simple form of covid consisting of flu-like syndrome, myalgias, fever and cough. The patient was treated symptomatically with paracetamol and vitamin C, without recourse to synthetic anti-malarial drugs or oral corticosteroids. The general examination revealed a hemodynamically stable patient with a fever of 38°C. The dermatological examination revealed a dry erythroderma (Fig. 1). The patient was hospitalized for 2 weeks and a symptomatic treatment based on dermocorticoids was started at the beginning and then a specific treatment with anti-interleukin 12/23 (Ustekinumab) was started after a general assessment not contraindicating its use.

The evolution was marked by a beginning of improvement from the first injection of ustekinumab and a skin whitening 2 months after the second one.

#### Discussion

Erythrodermic psoriasis is a severe form of psoriasis. It may be a manifestation of unrecognized psoriasis or a

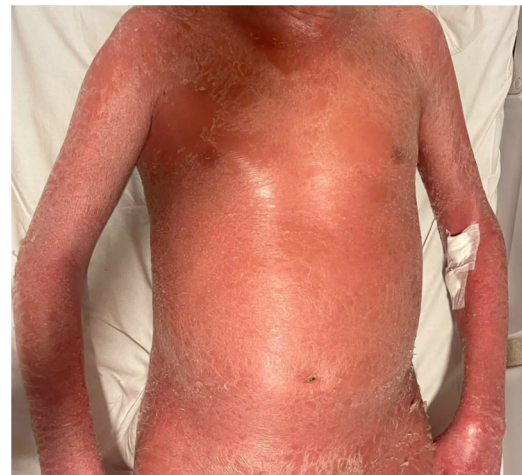


Figure 1 Dry Erythroderma.

complication of diagnosed psoriasis. Several factors have been implicated in the occurrence of this complication such as genetic mutation especially of CARD 14 gene,<sup>3</sup> certain bacterial (streptococcal and staphylococcal) or viral (HIV, CMV and Epstein bar virus) infections<sup>4</sup> and certain medications such as oral corticosteroids, synthetic antimalarials, beta-blockers, terbinafine, cyclins, and non-steroidal anti-inflammatory drugs.<sup>5</sup> The occurrence of erythroderma in patients followed for psoriasis during covid-19 infection is a very rare event. To our knowledge, only two cases have been described in the literature. Ghalamkarpour<sup>1</sup> was the first to report a case of psoriatic erythroderma 3 weeks after a mild form of covid-19 infection. In January 2022, Demiri<sup>2</sup> reported a second case in a patient who presented with dry erythroderma 5 days after a moderate form of covid-19 infection. Several pathophysiological hypotheses may explain the link between covid-19 infection and the occurrence of this complication. Firstly, covid-19 infection is considered to be a stressful state for the body, leading to a decrease in immunity. However, stress alone cannot be considered as a directly responsible factor in the occurrence of psoriasis erythroderma. Secondly, there is the aggravating influence of certain drugs used in the treatment of SARS-CoV-2 infection, in particular oral corticosteroids with a relapse effect and hydroxychloroquine, which is known to cause a dysregulation of epidermal trans-

<https://doi.org/10.1016/j.ad.2022.07.014>

0001-7310/© 2022 AEDV. Published by Elsevier España, S.L.U. This is an open access article under the CC BY-NC-ND license (<http://creativecommons.org/licenses/by-nc-nd/4.0/>).

glutaminase, leading to keratinocyte hyperproliferation. A third hypothesis incriminates the SARS-CoV-2 virus as an aggravating factor in psoriasis through the anti-viral immune response with increased production of pro-inflammatory cytokines such as interleukin 17, interleukin 23, interleukin 6, TNF alpha and INF alpha, the same being involved in the pathophysiology of psoriasis and especially the interferon gamma, implicated in the erythrodermic form.<sup>6</sup> This hypothesis is supported by some published reports that have shown that psoriatic patients on biotherapies, such as anti-interleukin 17, developed fewer severe forms of covid-19 than those on topical therapy alone.<sup>7</sup> There is also the role of Th2 type cytokines which are involved both in the anti-covid immune response<sup>8</sup> and in the erythrodermic form of psoriasis.<sup>9</sup> It also seems that such as streptococcus, the virus SARS-CoV-2 played by the spike protein present on its surface the role of superantigen<sup>10</sup> which is supporting by cases of psoriasis exacerbation after covid-19 vaccination.

In our patient, a coincidence cannot be formally eliminated but the hypothesis retained which would explain the appearance of this erythroderma is the infection by SARS-CoV-2, because of the temporal relation but also because he did not receive any of the treatments incriminated in the occurrence of this complication.

### Author contributions

All authors contributed to the conduct of this work. All authors also state that they have read and approved the final version of the manuscript.

### Funding

The authors did not receive any funding.

### Conflicts of interest

The authors have no conflicts of interest to declare.

### Acknowledgement

We are indebted to the patient for giving us the consent for publication.

### References

1. Ghalamkarpour F, Pourani MR, Abdollahimajd F, Zargari O. A case of severe psoriatic erythroderma with COVID-19. *J Dermatol Treat.* 2020;1-3.
2. Demiri J, Abdo M, Tsianakas A. Erythroderme psoriasis nach COVID-19-erkrankung. *Hautarzt.* 2022;73:156-9.
3. Signa S, Campione E, Rusmini M, Chiesa S, Grossi A, Omenetti A, et al. Whole exome sequencing approach to childhood onset familial erythrodermic psoriasis unravels a novel mutation of CARD14 requiring unusual high doses of ustekinumab. *Pediatr Rheumatol Online J.* 2019;17:38.
4. Morar N, Willis-Owen SA, Maurer T, Bunker CB. HIV-associated psoriasis: pathogenesis, clinical features, and management. *Lancet Infect Dis.* 2010;10:470-8.
5. Balak D, Hajdarbegovic E. Drug-induced psoriasis: clinical perspectives. *Psoriasis Targets Ther.* 2017;7:87-94.
6. Abdallah MA, Abdel-Hamid MF, Kotb AM, Mabrouk EA. Serum interferon-gamma is a psoriasis severity and prognostic marker. *Cutis.* 2009;84:163-8.
7. Zou Y, Meng Z. Literature overview of the IL-17 inhibition from psoriasis to COVID-19. *J Inflamm Res.* 2021;14: 5611-8.
8. Paniz-Mondolfil AE, Ramirez JD, Delgado-Nogueral LA, Rodriguez-Morales AJ, Sordillo EM. COVID-19 and helminth infection: beyond the Th1/Th2 paradigm. *PLoS Negl Trop Dis.* 2021;15:e0009402.
9. Zhang P, Chen H-X, Duan Y-Q, Wang W-Z, Zhang T-Z, Li J-W, et al. Analysis of Th1/Th2 response pattern for erythrodermic psoriasis. *J Huazhong Univ Sci Technolog Med Sci.* 2014;34: 596-601.
10. Cheng MH, Zhang S, Porritt RA, Noval Rivas M, Paschold L, Willscher E, et al. Superantigenic character of an insert unique to SARS-CoV-2 spike supported by skewed TCR repertoire in patients with hyperinflammation. *Proc Natl Acad Sci USA.* 2020;117:25254-62.

A. Fatima-Zahra\*, G. Basri, S. Nejjari, S. Chiheb

*Department of Dermatology, Sheikh Khalifa Hospital, Faculty of Medicine, Mohamed VI University of Health Sciences, Casablanca, Morocco*

\* Corresponding author.

*E-mail address:* [aghmarifz@gmail.com](mailto:aghmarifz@gmail.com) (A. Fatima-Zahra).