



## Case Report



## Rectosigmoid transition perforation by ingá (*Inga laurina*) seeds in the Brazilian amazon: Case report and surgical treatment

Juan Eduardo Rios Rodriguez<sup>a,\*</sup>, Daniella Paula Dias Coelho<sup>b</sup>, Edirany dos Santos Villalaz<sup>a</sup>, Alberto Rubin Figueiredo<sup>a</sup>, Paulo Daumas Kale Martins<sup>c</sup>, José Jorge Pinheiro Guimarães<sup>d</sup>, Aline Morião Carvalho de Souza<sup>e</sup>, Adriana Gonçalves Daumas Pinheiro Guimarães<sup>f</sup>

<sup>a</sup> Department of General Surgery, Getúlio Vargas University Hospital (HUGV), Manaus, Brazil

<sup>b</sup> Department of Radiology, Amazonas State Foundation Oncology Control Center (FCECON), Manaus, Brazil

<sup>c</sup> Faculty of Medicine, Nilton Lins University (UNL), Manaus, Brazil

<sup>d</sup> Department of Surgery, Amazonas State University (UEA), Manaus, Brazil

<sup>e</sup> Department of Radiology, Federal University of Amazonas (UFAM), Manaus, Brazil

<sup>f</sup> Department of General Surgery, Faculty of Medicine, Nilton Lins University (UNL), Manaus, Brazil

## ARTICLE INFO

## Keywords:

Colostomy  
Rectum  
Colon  
Sigmoid  
Foreign bodies  
Case report

## ABSTRACT

**Introduction:** Foreign body ingestion is a common clinical scenario found in clinical practice. Perforations related to foreign bodies are rare, but they can present as a serious condition in emergency surgery services. The most common sites of perforation are angled areas, such as: ileocecal valve, sigmoid colon, duodenojejunal flexure and small intestine. We are going to describe a rare case of extensive perforation of rectosigmoid transition, without associated obstructive clinical picture, related to voluntary ingestion of foreign body caused by multiple seeds of a typical amazon fruit.

**Presentation of case:** This case report describes the presentation and management of a 46-year-old man who presented signs of acute perforating abdomen, without obstructive condition, after ingestion of foreign body. Imaging examination revealed the presence of foreign bodies with signs of intestinal perforation. Exploratory laparotomy was performed to treat the lesion and remove foreign bodies.

**Discussion:** Bowel perforation by a non-sharp foreign body is a rare complication of object ingestion. Object shape, quantity, narrowing of gastrointestinal tract are factors that can favor perforation. The clinic is not very specific, usually preceded by when obstructive or sub occlusive, and the clinical history is relevant for diagnostic formulation. Regions and cultures with a high intake of food with seeds may constitute an extra risk factor.

**Conclusion:** The importance of alerting surgical teams to the possibility of bowel perforation without associated occlusive conditions caused by multiple non-sharp seeds is highlighted, as well as the need for early treatment aiming at favorable clinical outcome.

### 1. Introduction

Gastrointestinal perforation is a rare scenario found in clinical practice. Perforations related to food intake of foreign bodies are rare and associated with an expressive mortality rate, from 30 to 50% [1]. About 80%–90% of ingested foreign bodies will be excreted without causing further complications [2,3].

Ingestion is usually accidental or involuntary, and involves patients

in extreme age, with mental or swallowing disorders. Perforation of the gastrointestinal tract by a punctiform foreign body is more common and occurs mainly in the small intestine, at points of angulation or physiological narrowing [4]. In contrast, ingá seeds have a smooth surface, elliptical in shape without tips, covered by edible pulp. Intestinal perforation related to voluntary ingestion of non-sharp foreign bodies by middle-aged people without cognitive disorders is rarely found. Below, we report a case of unusual foreign body gastrointestinal perforation.

\* Corresponding author. R. Tomas de Vila Nova, 4 - Nossa Sra. das Gracas, Manaus - AM, 69020-545, Brazil.

E-mail addresses: [edu-rios2011@hotmail.com](mailto:edu-rios2011@hotmail.com) (J.E.R. Rodriguez), [danielladiascoelho@gmail.com](mailto:danielladiascoelho@gmail.com) (D.P.D. Coelho), [ediranyvillalaz@gmail.com](mailto:ediranyvillalaz@gmail.com) (E.S. Villalaz), [albertorubinfigueiredo@gmail.com](mailto:albertorubinfigueiredo@gmail.com) (A.R. Figueiredo), [paulokale@gmail.com](mailto:paulokale@gmail.com) (P.D.K. Martins), [guimajor571@gmail.com](mailto:guimajor571@gmail.com) (J.J.P. Guimarães), [alinemoriao@gmail.com](mailto:alinemoriao@gmail.com) (A.M.C. de Souza), [adriana.daumas@gmail.com](mailto:adriana.daumas@gmail.com) (A.G.D.P. Guimarães).

<https://doi.org/10.1016/j.amsu.2021.102897>

Received 4 September 2021; Received in revised form 25 September 2021; Accepted 26 September 2021

Available online 27 September 2021

2049-0801/© 2021 The Authors. Published by Elsevier Ltd on behalf of IJS Publishing Group Ltd. This is an open access article under the CC BY-NC-ND license

(<http://creativecommons.org/licenses/by-nc-nd/4.0/>).

This case follows 2020 SCARE guidelines for reporting of cases in surgery [5].

## 2. Presentation of case

A 46-year-old male patient was admitted to the emergency department, complaining of fever and abdominal pain for 3 days. His past medical history did not include medical, mental illnesses previous surgery or continuous medication. He reported ingestion of a large amount of Inga fruit and its respective seed (*Inga laurina* species) for 7 days, with present evacuation, however, without elimination of seeds, associated with hematochezia for 1 day. The vital signs at admission showed temperature of 38.1 °C, heart rate of 109 bpm and BP of 127 × 87 mmHg. On examination, the abdomen was globular, slightly distended, painful to superficial and deep palpation, with greater intensity on the lower floor, with signs of diffuse peritoneal irritation.

The initial laboratory investigation revealed hemoglobin (12 mg/dL), leukocytosis (19,851 cells/mm<sup>3</sup>), 84% neutrophilia, with no other alterations. Computed tomography of the abdomen and pelvis was performed. The examination revealed the presence of multiple dense oval images distributed over the colonic segments, totaling 29 objects, with a greater number in the cecum and sigmoid, compatible with foreign bodies. Several similar images outside the loop, located in the cul-de-sac of Douglas, and “blurring” of the pericolic fat in the topography of the sigmoid [Fig. 1]. There were no signs of intestinal obstruction, loop distension or air-fluid levels. The CT scan also showed a small to moderate amount of free perihepatic, perisplenic, and pelvic fluid, as well as diffuse peritoneal thickening and small pneumoperitoneum [Fig. 1], considering the hypothesis of free intestinal perforation into the cavity. There was also a small bilateral pleural effusion and compressive atelectasis in the lung bases, especially on the right.

Exploratory laparotomy was immediately indicated, where a moderate amount of seropurulent, non-fecal secretion was observed, with the presence of a significant number of free fruit seeds and associated with small portions of solid feces, in cybals, free in the pelvis, in addition to a small amount of clear liquid and reactive perihepatic and perisplenic citrine. After an initial removal of feces and eighteen foreign bodies from the pelvis, a transverse lesion was identified on the anterior wall of the rectosigmoid transition, measuring approximately 4.0 cm (Fig. 2). A single plane lesion suture was chosen in separate stitches with 3-0 polyglactin suture, tested by a “maneuver of the tire repairman”, including air insufflation in the rectum (via rectal probe after mechanical removal of other seeds and feces in the distal rectum). After releasing the parietocolic fixation of the descending and sigmoid colon, a terminal protective colostomy and suture of the stump were performed with fixation to the abdominal wall, close to the site of passage of the stoma (Fig. 3). The procedure was completed with abundant washing of the abdominopelvic cavity, closure of the abdominal cavity and early maturation of the colostomy.

The patient showed rapid postoperative recovery, with good colostomy functionality, and additional elimination of five seeds. On the fifth postoperative day, the patient was discharged from the hospital with guidelines for colostomy care and outpatient referral for reconstruction of the intestinal transit.

## 3. Discussion

Although the perforation of the digestive tract by foreign bodies is a rare event, it usually results from the ingestion of sharp objects, with only 1% in cases of foreign body ingestion [6]. In this case, eighteen seeds were removed intraoperatively, which have elliptical ends and which probably compressed the wall of the sigmoid colon by impaction. When the intake is of a single object, the fact may be related to neurological conditions, pediatric population, unusual sexual behavior or factors extrinsic to the patient, such as previous abdominal surgeries [7]. When ingesting multiple objects, psychiatric conditions and illegal transport of substances, often narcotics, are more incidents [8,9]. Fruit/fruit intake is related to complications when there is no digestion of the seeds, with their accumulation and compaction forming a single object, known as phytobezoar [10]. Despite this, bezoar is more related to obstructive conditions of the proximal digestive tube, and rarely evolve to perforation [11].

Due to the size of the seed, about 2.5–3.0 cm, the surgical team was surprised by the lack of impaction of the seeds at the level of the ileocecal valve, since obstructive conditions usually result from the discrepancy between the size of the foreign body. and by the anatomy of the gastrointestinal tract [12]. However, this fact was probably due to the liquid aspect of the fecal effluent in this anatomical intestinal region. Another fact that drew attention was the rapid evolution of the case, without presenting a clinical picture of intestinal obstruction. The fact perhaps it is due to the wide perforation determining the immediate escape of contents into the peritoneal lumen.

In cases of perforation, these result from the shape of objects, such as toothpicks, needles or fish bones [13]. Despite not having a punctiform appearance at first sight, an ingá seed has a favorable format for perforation, especially if multiple impacts cause pressure on a narrow anatomical point. Ingá seeds have an elliptic shape without tips and a smooth surface, as seen in some examples in Fig. 2B. However, reports of perforation of the rectosigmoid junction or other colonic segment by this seed were not found in the literature.

The psychiatric and cultural aspect must be evaluated. Fruit seed bezoars such as jabuticaba or granadilla are reported in places with high consumption of these foods [10,11]. In the case reported here, there was no formation of bezoars, but an acute ingestion of ingá seeds (*Inga laurina* species), probably due to the patient’s regional costume, and not due to a psychiatric condition, different from trichobezoars [14].

The clinical profile of patients with intestinal perforation is variable, often preceded by mild progressive pain resulting from impaction of the foreign body, with an abrupt increase in pain, nausea and vomiting,

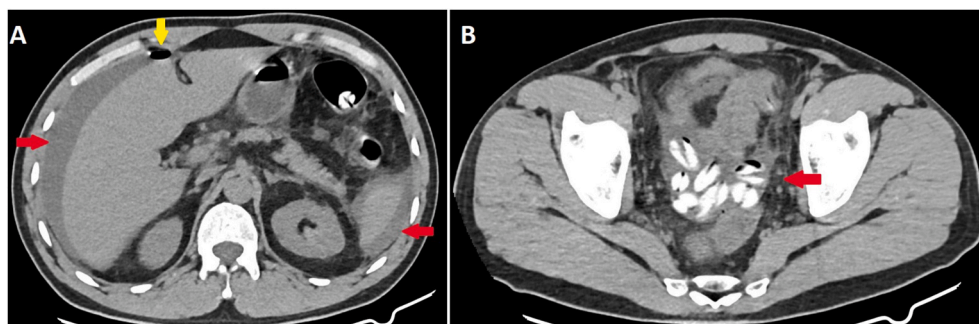


Fig. 1. (A) Arrows pointing to pneumoperitoneum (yellow) and free fluid in the upper abdomen (red). (B) Arrow pointing to foreign bodies in the pelvis associated with free fluid. (For interpretation of the references to colour in this figure legend, the reader is referred to the Web version of this article.)

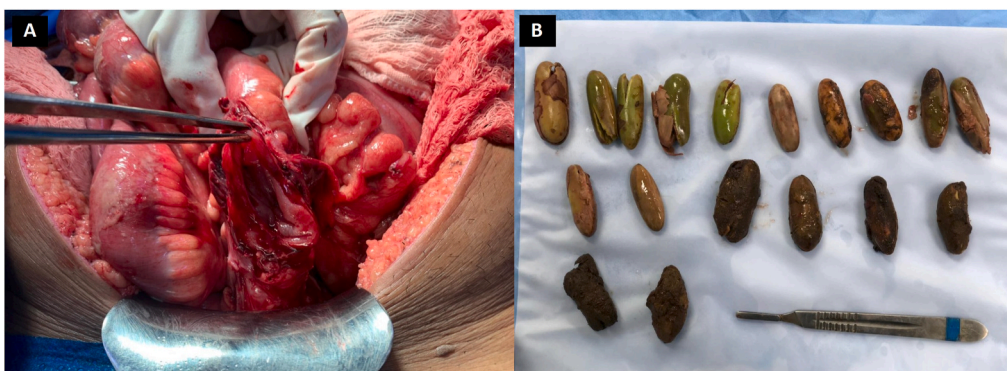

Fig. 2. (A) Intraoperative image of a lesion in the anterior wall of rectosigmoid transition. (B) Visualization of *Inga laurina* seeds after abdominal cavity removal.

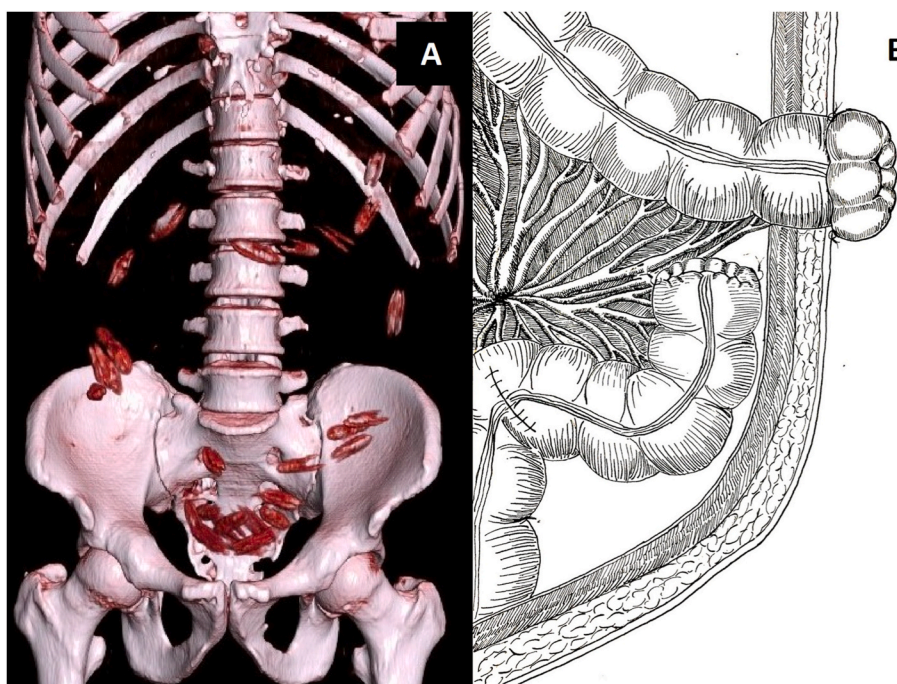


Fig. 3. (A) 3D CT scan with the foreign bodies in the pelvis. (B) Schematic for performing a terminal colostomy and fixation of the distal stump to the abdominal wall near the colostomy orifice (art by Edirany Villalaz).

which may progress to peritoneal irritation. The degrees of systemic repercussion of the signs of septic shock also depend on the stage of the disease, occurrence of comorbidities and virulence of the infectious process. Laboratory tests are not very specific, and there may be leukocytosis with neutrophilia and an unspecific increase in CRP and ESR. After installing the septic frame, lactate will mark the permanence of the septic frame [15].

As for imaging exams, in obstructive conditions, the radiological routine of the acute abdomen remains useful in identifying the signs of obstructive and/or perforating acute abdomen. In patients with probable perforation, a computed tomography is the gold standard, as it is able to identify the perforation site through the thickening of the wall and the adjacent fat, aiding in surgical planning [4].

As for the treatment, this will always consist of an individualized intervention. If the hypothesis is focal intestinal perforation, the possibility of endoscopic treatment initially, if readily available, is suggested. For example, the use of hemostatic clips via colonoscopy is an option for lesions smaller than  $0.5 \times 0.5$  cm in patients without peritoneal irritation or other sign of severity [16]. Otherwise, laparotomic surgical treatment is indicated. Lesions such as the one in the clinical case

reported here, require primary suture of the wide lesion and a protective loop colostomy [17]. In more advanced cases, with plastron formation or other changes such as vascular distress, resection of the affected segment combined with a terminal colostomy is the safest approach [18]. In a recent meta-analysis, the comparison between primary anastomosis and colostomy in cases of perforated diverticulitis with complicated peritonitis showed that both anastomosis and primary raffia can be used safely. However, the same work describes that patients undergoing primary anastomosis had more stable clinical conditions, such as ASA <3 [19]. In the case reported here, we opted for terminal colostomy and distal stump suture with its approximation to the abdominal wall, in order to completely limit the passage of content, but facilitating the reconstruction of the intestinal transit later [20].

#### 4. Conclusion

This report had the main objective of alerting the surgical teams to the possibility of bowel perforation without an obstruction history by a rare cause, multiple seeds with non-sharp shapes. The habit of ingesting seeds can be evaluated as cultural and not in the spectrum of psychiatric

alterations. An alternative form of terminal colostomy was introduced with fixation of the distal stump to the peritoneum near the opening of the stoma after the primary suture of the injury, that can aid in the reconstruction of intestinal transit. Postoperative patient orientation must be emphasized in order to avoid future food intake.

### Provenance and peer review

Not commissioned, externally peer-reviewed.

### Ethical approval

As the manuscript is not a research study, we only have the patient consent for writing and others forms of publication. Also, the ethical approval for this case reports has been exempted by our institution.

### Sources of funding

We do not have any funding source, this manuscript is just a case report, not a research.

### Author contribution

Alberto Figueiredo, Edirany Villalaz and Daniella Coelho made contributions to conception and design. collected the patient details and wrote the paper. Juan Rodriguez, Adriana Guimarães, Paulo Martins, José Guimarães made contributions to patient management. Juan Rodriguez, Aline de Souza and Adriana Guimarães critically revised the article. All authors read and approved the final manuscript.

### Registration of research studies

The manuscript is a case report, not considered a formal research involving participants.

### Guarantor

Juan Eduardo Rios Rodriguez.

### Declaration of competing interest

We do not have any conflicts of interests.

### References

- [1] J.T. Langell, S.J. Mulvihill, Gastrointestinal perforation and the acute abdomen, *Med Clin North Am* 92 (3) (2008) 599–ix, <https://doi.org/10.1016/j.mcna.2007.12.004>.
- [2] K. Rajaguru, S.C. Sheong, Case report on a rare cause of silent duodenal perforation, *Int J Surg Case Rep* 76 (2020) 320–323, <https://doi.org/10.1016/j.ijscr.2020.09.184>.
- [3] T. Ma, W. Zheng, B. An, Y. Xia, G. Chen, Small bowel perforation secondary to foreign body ingestion mimicking acute appendicitis: case report, *Medicine (Baltim.)* 98 (30) (2019), e16489, <https://doi.org/10.1097/MD.00000000000016489>.
- [4] G.C. Nicolodi, C.R. Trippia, M.F. Caboclo, et al., Intestinal perforation by an ingested foreign body, *Radiol. Bras.* 49 (5) (2016) 295–299, <https://doi.org/10.1590/0100-3984.2015.0127>.
- [5] R.A. Agha, T. Franchi, C. Sohrabi, G. Mathew, for the SCARE Group, The SCARE 2020 guideline: updating consensus surgical CAse REport (SCARE) guidelines, *Int. J. Surg.* 84 (2020) 226–230, <https://doi.org/10.1016/j.ijvsu.2020.10.034>.
- [6] R.K. Ravindra, A. Das, G.L. Chew, E. Daniel, Small bowel obstruction with multiple perforations post chestnut ingestion, *BMJ Case Rep.* 12 (2) (2019), <https://doi.org/10.1136/bcr-2018-227999> bcr-2018-227999. Published 2019 Feb 3.
- [7] A. Aamery, R. Al-Shehhi, K. Malik, A. Al-Harthy, Perforation of Meckel's diverticulum with a foreign body mimicking acute appendicitis: a rare complication, *J. Pakistan Med. Assoc.* 67 (6) (2017) 942–944.
- [8] M. Deitel, A.K. Syed, Intestinal obstruction by an unusual foreign body, *Can. Med. Assoc. J.* 109 (3) (1973) 211–212.
- [9] L.M. Schuppener, R.F. Corliss, Death due to complications of bowel obstruction following raw poppy seed ingestion, *J. Forensic Sci.* 63 (2) (2018) 614–618, <https://doi.org/10.1111/1556-4029.13562>.
- [10] R.L. Luporini, L.D. Weirich, M.R. Marciano, L.V. Sipriani, F.D.A. Gonçalves Filho, A.F.F. Sabbag, J.G. Netinho, Intestinal obstruction caused by phytobezoars composed of jaticaba seeds: case report and literature review, *J. Coloproctol. (Rio de Janeiro)* 32 (3) (2012) 308–311.
- [11] A.R. Alexandre, L.D. Costa, P. Raimundo, Giant granadilla's seeds phytobezoar rectal impaction: a very unusual case of intestinal obstruction, *BMJ Case Rep.* 2018 (2018), bcr2017223176, <https://doi.org/10.1136/bcr-2017-223176>. Published 2018 Feb 8.
- [12] T. Iwai, H. Makino, T. Yokoyama, et al., Intestinal obstruction caused by a fruit seed: a rare case without gastrointestinal disease, *Cureus* 10 (12) (2018), e3767, <https://doi.org/10.7759/cureus.3767>. Published 2018 Dec 21.
- [13] R. Gupta, V.S. Mujalde, S. Gupta, P.K. Gupta, A. Bhandari, P. Mathur, Intestinal perforation in obstructed umbilical hernia due to wedged plum seed, *APSP J. Case Rep.* 7 (3) (2016) 25, <https://doi.org/10.21699/ajcr.v7i3.439>. Published 2016 Jun 15.
- [14] R.S. de Souza, B.T.F. Cabral, J.E.R. Rodriguez, LTF de Souza, TD de Andrade, IA. de O. Medeiros, Obstrução intestinal associada a tricobezoaes de grande volume – um relato de caso. REAS, 4mar.2019 [citado 13jun.2021];(20):e544. Available from: <https://acervomais.com.br/index.php/saude/article/view/544>.
- [15] G. Hernandez, R. Bellomo, J. Bakker, The ten pitfalls of lactate clearance in sepsis, *Intensive Care Med.* 45 (1) (2019) 82–85, <https://doi.org/10.1007/s00134-018-5213-x>.
- [16] C. Fang, L. Ye, X. Mao, J. Zhang, Endoscopic treatment of a sigmoid perforation caused by an ingested fish bone, *Endoscopy* 49 (S 01) (2017) E82–E83, <https://doi.org/10.1055/s-0042-124500>.
- [17] X.K. Lin, D.Z. Wu, X.F. Lin, N. Zheng, Intestinal perforation secondary to ingested foreign bodies: a single-center experience with 38 cases, *Pediatr. Surg. Int.* 33 (5) (2017) 605–608, <https://doi.org/10.1007/s00383-017-4075-6>.
- [18] P.A. Boland, S.T. Quidwai, R. Mitru, E. McCarthy, M. Aremu, Sigmoid perforation secondary to accidental ingestion of a chicken bone, *Ir. Med. J.* 113 (1) (2020) 12. Published 2020 Jan 16.
- [19] M. Gachabayov, C.E. Oberkofler, J.J. Tuech, D. Hahnloser, R. Bergamaschi, Resection with primary anastomosis vs nonrestorative resection for perforated diverticulitis with peritonitis: a systematic review and meta-analysis, *Colorectal Dis.* 20 (9) (2018) 753–770, <https://doi.org/10.1111/codi.14237>.
- [20] J.J.R. da Rocha, Estomas intestinais (ileostomias e colostomias) e anastomoses intestinais, *Medicina (Ribeirão Preto)* 44 (1) (2011) 51–56.