

Beauty and Function: The Use of Trimmed Great Toe in Thumb and Finger Reconstruction

Luigi Troisi, MD, PhD,
FEBOPRAS*†
Luca Mazzocconi, MD†
Alessandro Mastroiacovo, MD†
Macarena Vizcay, MD*†
Francesco Zanchetta, MD*
Sara Stucchi, MD†
Giorgio Eugenio Pajardi, MD*†

Background: Finger amputations are one of the most common traumas of daily life. Regularization of the digital stump is the most widely used option in the literature today. The aim of this study was to evaluate a valid functional and aesthetic alternative to amputation.

Methods: We retrospectively investigated our prospective database, selecting the patients who underwent trimmed great toe flap reconstruction for the amputation of a digit from September 2019 to November 2021. All the operations were performed by the first author (L.T.) in the Reconstructive Microsurgery Service of the University Department of Hand Surgery and Rehabilitation of MultiMedica Group.

Results: No flap required anastomosis revision or had major complications. The length of the amputated finger was maintained, with a high functional and aesthetic result achieved.

Conclusions: The trimmed great toe flap has proven to be a viable alternative to finger amputation in the reconstruction of thumb and long finger defects, leading to high aesthetic results. The morbidity of the donor site is reduced compared with the classic great toe flap, allowing a direct closure in most cases. (*Plast Reconstr Surg Glob Open* 2022;10:e4540; doi: [10.1097/GOX.0000000000004540](https://doi.org/10.1097/GOX.0000000000004540); Published online 30 September 2022.)

INTRODUCTION

In the Western population, upper extremity traumas and amputations are among the most common injuries presenting in emergency rooms.¹ Finger amputations have a higher incidence in male manual workers than in women (approximately 4–1), with a higher incidence of partial thumb amputations than complete thumb or long finger amputations.^{2–4}

Digital replantation in a posttraumatic amputation remains the first procedure to perform.⁵ There are still controversies about the indications for replantation, opening up a world of secondary reconstruction.⁶ Thus, secondary reconstruction has become increasingly important in the surgeon's armamentarium over the past decades.

Local flaps, such as homodigital and heterodigital flaps,^{7–10} pedicled hand and forearm flaps, or thin free flaps,^{11,12} are commonly used to replace the loss of substance. However, these procedures do not restore the injured finger's original length and tissue complexity, resulting in poor functional and cosmetic outcomes.¹³

Since the first toe-to-hand transplantation was performed,^{14,15} the foot has been a precious warehouse for digital reconstruction. During the 1960s and 1970s, this consideration allowed surgeons to describe first microsurgical toe transplantations by different techniques, such as great-toe transfer, wrap-around toe, and trimmed great toe (TGT).^{16–20}

The TGT flap is a variation of the great toe transfer that involves reduction of both bone and soft tissue, usually at its medial side to overcome the aesthetic problem regarding the discrepancy in appearance due to differences in joint size, nail width, and circumference that concerns many patients.^{21,22} Although this flap may be ideal for thumb reconstruction, it also allows a desired aesthetic result^{23,24} to be achieved even in patients with distal long finger amputations who are motivated to maintain their previous body image.

From the *Reconstructive Microsurgery Service, University Department of Hand Surgery and Rehabilitation, San Giuseppe Hospital, IRCCS MultiMedica Group, Milan, Italy; and †School of Specialization in Plastic, Reconstructive and Aesthetic Surgery, Milan University, Milan, Italy.

Received for publication April 28, 2022; accepted July 29, 2022.

Copyright © 2022 The Authors. Published by Wolters Kluwer Health, Inc. on behalf of The American Society of Plastic Surgeons. This is an open-access article distributed under the terms of the [Creative Commons Attribution-Non Commercial-No Derivatives License 4.0 \(CCBY-NC-ND\)](https://creativecommons.org/licenses/by-nc-nd/4.0/), where it is permissible to download and share the work provided it is properly cited. The work cannot be changed in any way or used commercially without permission from the journal.

DOI: [10.1097/GOX.0000000000004540](https://doi.org/10.1097/GOX.0000000000004540)

Disclosure: The authors have no financial interest to declare in relation to the content of this article.

Related Digital Media are available in the full-text version of the article on www.PRSGlobalOpen.com.

The purpose of this study is to evaluate the aesthetic and functional outcomes obtained with the TGT free flap in the thumb and long finger amputations, providing a viable alternative in the surgeon's reconstructive toolbox.

METHODS

We retrospectively reviewed our prospective database and selected the patients who underwent TGT flap reconstruction for digit amputations from September 2019 to November 2021, all performed by the first author (L.T.). We reviewed the patients' medical records and included patients' demographics, smoking status, type of trauma, flap reconstruction, operative time, ischemia time, and long-term complications.

All patients performed rehabilitation with therapists specialized in hand diseases and underwent a validated "Patient-Rated Wrist/Hand Evaluation" (PRWHE) questionnaire to assess functional and aesthetic outcomes.^{25,26} After completing wound healing, all patients were examined using the "Michigan Hand Outcomes Questionnaire" (MHOQ).^{27,28} The overall score of the MHOQ was used to reinforce the global hand function data obtained with the PRWHE questionnaire. Subsequently, "section V" of this questionnaire concerning only the aesthetic results was calculated, thus assessing the degree of satisfaction of every single patient.

At physiotherapy sessions, patients were asked about any walking deficits or reduction in daily-covered distances compared with those before the operation.

This study was conducted according to the World Medical Association's Declaration of Helsinki (1964, version 2013) and Good Clinical Practice.

Summary statistics were calculated. Quantitative data are expressed as the mean \pm SD, whereas nominal data were expressed as a percentage. Analyses were performed using SPSS software version 26.0.

Surgical Technique

For thumb amputation, we measured the circumference of the contralateral thumb at three levels: (1) nail eponychium, (2) interphalangeal joint (which corresponds to the widest point), and (3) middle of the proximal phalanx. Nail width was also measured in its central portion. A line was drawn longitudinally and proximally from the eponychium to the base of the first phalanx of the hallux.

At this point, all the measurements of the finger could be transposed, starting from this reference line at the corresponding levels on the great toe leaving excess tissue on the tibial aspect of the hallux (usually 0.5–1.5 cm in width) to allow a free-tension donor site closure. The same approach has been used in long finger amputations using the contralateral digit as a template.

We identified the dorsalis pedis artery course using a handle-Doppler. We drew the planned curvilinear S incision with a marking pen on the dorsal aspect of the first web space of the chosen foot.

All operations were performed under general anesthesia and tourniquet control (~300 mm Hg) at the level of

Takeaways

Question: Is the trimmed great toe flap a viable reconstructive option for different types of amputated fingers?

Findings: The results show that the trimmed great toe flap provides length maintenance and a very high aesthetic result.

Meaning: The trimmed toe flap could be an ideal option for reconstructing thumb and long finger defects.

the thigh. Two teams worked simultaneously. One team harvested the flap, and the other prepared the recipient site and vessels.

The toe incision was started at first web space under loupes magnification (3.5 \times). The neurovascular bundle based on the fibular artery, digital nerve, and a superficial vein was identified, isolated, and protected during the dissection. When the first dorsal metatarsal artery lacked adequate caliber, the first palmar metatarsal artery was preferred. Tendons and nerves dissections were performed differently and tailored to the type of injury.

The flap was harvested from distal to proximal, and the osteotomy was performed with a piezoelectric surgical saw at the chosen amputation levels. No pedicle was divided before releasing the tourniquet to assess flap perfusion. All flaps and remaining tissues demonstrated good reperfusion allowing division of their vascular pedicle and transfer to the recipient site. The recipient arteries we used were usually digital arteries ipsilateral to the lesion if undamaged or the dorsal radial artery with a superficial vein nearby. One or multiple K-wires have been applied for the fixation of the hallux to the amputation stump (Fig. 1, 2).

The postoperative routine followed a rigorous protocol based on flap clinical assessment and Doppler signal, blood testing, 38° thermal blanket, hand elevation, and complete bed rest for the first 3 days. From day 5 to 2–3 weeks after surgery, ambulation was permitted only with a medical shoe that prevented anterior foot bearing.

RESULTS

A total of 10 patients underwent a TGT between September 2019 to November 2021, with a median of 27.5 years of age (range, 25–48). Seven of these 10 patients had only one finger amputation, while three had complex hand trauma with multiple digits affected. Complete patient demographics are illustrated in Table 1.

Nine out of 10 flaps were taken from the ipsilateral foot to the injured hand. A total of seven neo-thumb and three neo-long fingers (second, third, and fourth) were reconstructed with TGT. At intraoperative dissection, in eight cases, first dorsal metatarsal artery was successfully found, whereas in two, first palmar metatarsal artery was preferred due to anatomical variants. We used four branches of the dorsal radial artery, three digital collaterals, and two radial arteries for arterial anastomoses.

In three cases, a vein graft was necessary to lengthen the arterial pedicle due to ruined dorsal radial artery and

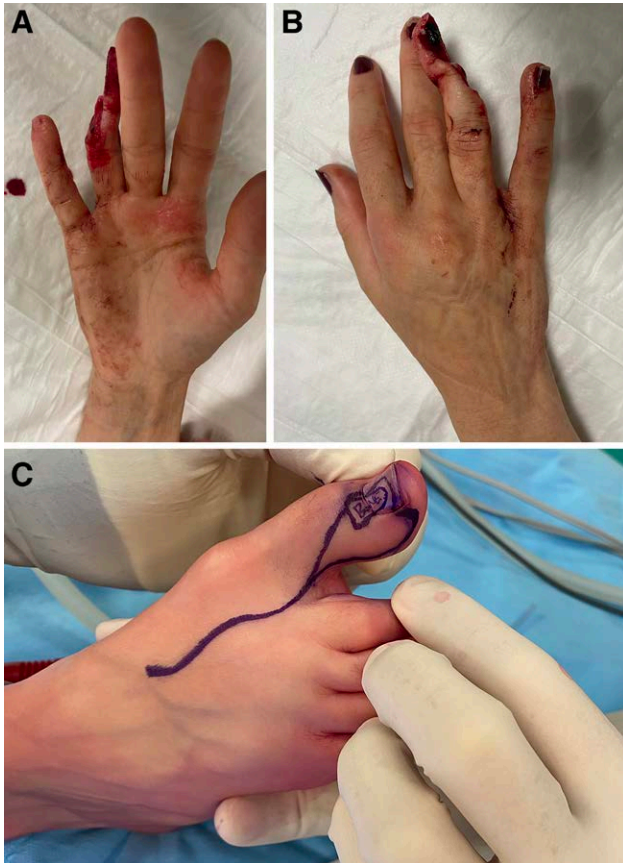


Fig. 1. A 21-year-old female patient with an oblique amputation of fourth digit after trauma. A and B, Preoperative photographs. C, Design of the flap.

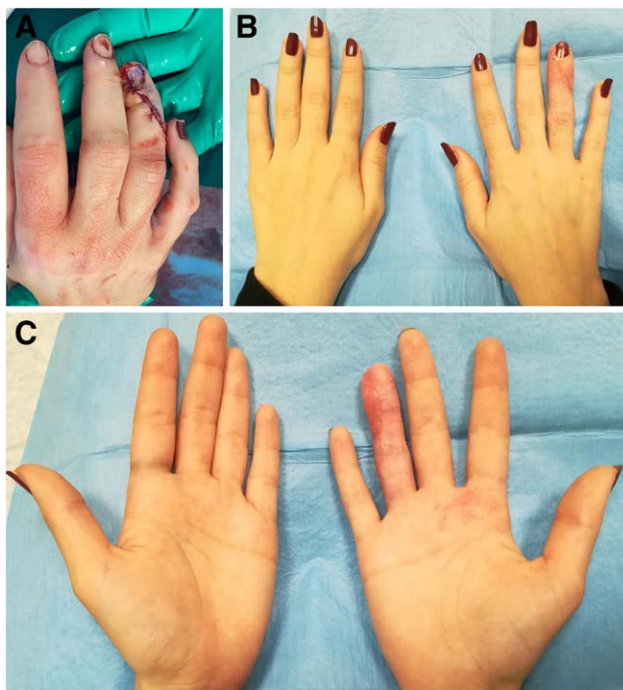

Fig. 2. A, Flap inset immediate postoperative. B and C, Follow-up after 3 months.

digital collateral arteries. In one case, we used the arterial branch for the second toe as a flow through to revascularize a superficial iliac perforator flap, which was needed to cover the second and third metacarpal bones left exposed by the trauma. In all patients, a superficial dorsal vein of the foot was used as a donor vessel, anastomosed to superficial veins of the hand of appropriate size.

The median ischemia time was 80.6 (± 14.96 SD), while the total surgery time was 354.8 (± 72.61 SD) minutes per procedure (Table 2).

There were no major complications, whereas two minor complications were observed. The acute complication involved minimal bony exposure of the implanted distal neo-phalangeal, which required surgical revision with a local flap under local anesthesia. The chronic complication involved pseudarthrosis between the P2 of the great toe and the base of the P3 of the reconstructed digit, which required surgery to place a bone graft. Donor site morbidity occurred in a single case, resulting in acute foot hematoma, resolved spontaneously.

The mean time between surgery and hospital discharge was 5.5 days. No functional deficit of the lower limb was observed, with complete restoration of walking as soon as the talus shoe was removed.

Functional assessment was evaluated using PRWHE questionnaire with a median result of 5.75 (IQR, 0–12.5).

The higher score indicates more pain and functional disabilities (eg, 0 = no disability). After complete wound healing, all patients underwent the MHOQ with a median overall score of 95.44 (IQR, 78.94–97.08). We further evaluated the aesthetic section V of the MHOQ with a median score of 100 (IQR, 81.25–100) (Table 3).

DISCUSSION

Surgical techniques have evolved over the years, starting from the first digital replantation performed by Komatsu and Tamai²⁹ in 1965 up to the most recent attempts of multiple replants. Several approaches have been widely documented^{14,30,31} since the first trimmed toe transfer technique was described as an alternative option for thumb reconstruction.³² The TGT was born to combine the wrap around and the total great toe transfer, thus recreating a normal toe without major functional sacrifice. In 1998, Wei²⁰ described in detail this procedure in the reconstruction of thumb defects, allowing its proportionate and aesthetic reconstruction without sacrificing the entire length of the big toe.

In our surgical experience, the use of the TGT has highlighted many advantages over traditional surgery. The aesthetic result obtained by reducing the initial size of the great toe allows obtaining a “neo-thumb” as similar as possible to the contralateral one. Thanks to like-with-like principle surgery, no other procedures are needed to restore function and aesthetics of the reconstructed thumb/digit. The morbidity of the donor site is reduced compared with other free flaps,³³ allowing a closure in almost all cases by first the intention. No patient complained of partial or total gait deficits in alignment with the literature’s outcomes of TGT reconstruction in finger amputation.^{34–36}

Table 1. Demographics of the Patients with Associate Lesions

Patient Number	Sex	Age	Laterality	Smoking Status	Reconstructed Digit	Associate Lesions
1	M	23	Right	Yes	I	None
2	M	27	Left	No	II	Third, fourth, and fifth distal phalanx amputation of the right hand
3	M	27	Left	No	I	Fifth metacarpal fracture and nail avulsion of the second and third digit
4	M	48	Left	No	III	None
5	M	57	Right	Yes	I	Nail avulsion of the second finger and P3 bone exposure of the fourth finger
6	M	25	Right	Yes	I	None
7	M	74	Right	Yes	I	Former brachial plexus injury of the left limb
8	M	45	Right	No	I	Second, third, and fourth digit amputation
9	F	21	Right	No	IV	None
10	M	28	Left	No	I	Third and fourth P3 amputation

Table 2. Reconstruction Technique including Ischemia and Surgical Time, Recipient Vessels, and Anastomosis Features

Patient Number	Ischemia Time (min)	Surgical Time (min)	Recipient Artery	Stitch Size and Anastomosis	Recipient Vein	Stitch Size and Anastomosis
1	82	342	DRA	9/0 E-E + vein graft	Dorsal vein	9/0 E-E
2	77	340	DUC	9/0 E-E	Dorsal vein	10/0 E-E
3	80	359	DRA	9/0 E-E	Dorsal vein	9/0 E-E
4	70	295	DRC	9/0 E-E	Dorsal vein	9/0 E-E
5	110	431	RA	9/0 E-S	Dorsal vein	9/0 E-E
6	57	246	DRA	9/0 E-S	Dorsal vein	9/0 E-E
7	90	328	DRA	9/0 E-E	Dorsal vein	9/0 E-E
8	90	470	RA	8/0 E-S + vein graft	Dorsal vein	9/0 E-E
9	60	277	DUC	10/0 E-E	Volar vein	10/0 E-E
10	90	460	RA	9/0 E-E + vein graft	Dorsal vein	9/0 E-E

DRA, dorsal radial artery; DUC, digital ulnar collateral; E-E, end to end; E-S, end to side; RA, radial artery.

Table 3. Postoperative Follow-up and Questionnaire Results

Patient Number	Overall MHOQ (%)	MHOQ Score V (%)	PRWHE Score	Complications
1	98.17	100	2	None
2	78.94	81.25	6.5	Pseudoarthrosis
3	96.25	100	0	None
4	38	75	33	P3 bone exposure
5	94.64	100	5	None
6	93.24	93.75	9	None
7	97.08	100	12.5	Foot hematoma
8	76.25	75	18.5	None
9	98.3	100	0	None
10	96.67	100	0	None

There are no cases described in the literature of long toe reconstructions with TGT flaps, focusing on both the functional and aesthetic aspects. Our practice aims to treat the thumb and distal aspect of long finger injuries using the same surgical technique. Examining the results obtained from both the PRWHE and the MHOQ, it is possible to appreciate an overall high median score in both items. Suitable median values can be found through a separate analysis of section V of the MHOQ.

Our data have highlighted, once again, the TGT as an aesthetically valid reconstructive option for digit amputations and led to new perspectives in the literature for its application in long finger defect reconstruction. We believe that meticulous preoperative measurements, attention to detail, and a clear reconstructive plan are essential to achieve the best aesthetic outcome. In our

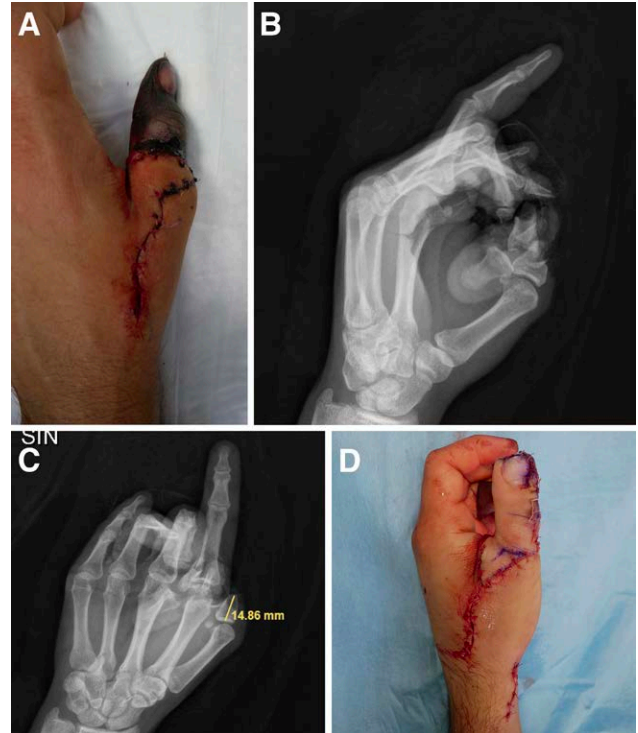

Fig. 3. A, A 28-year-old male patient with a replant failure of left thumb after trauma. B and C, Rx of the defect. D, TGT flap inset immediate postoperative.

clinical experience, symmetry of the reconstructed finger with its counterpart allows the patient to gain a higher level of satisfaction. Due to the versatility of this

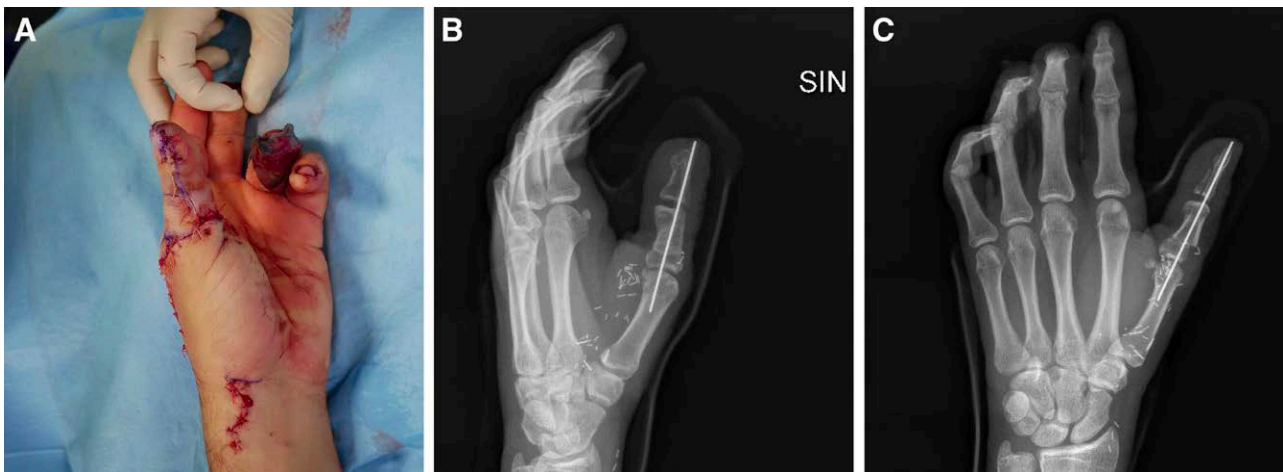

Fig. 4. A, TGT flap inset immediate postoperative. B and C, Rx after the inset of the flap.

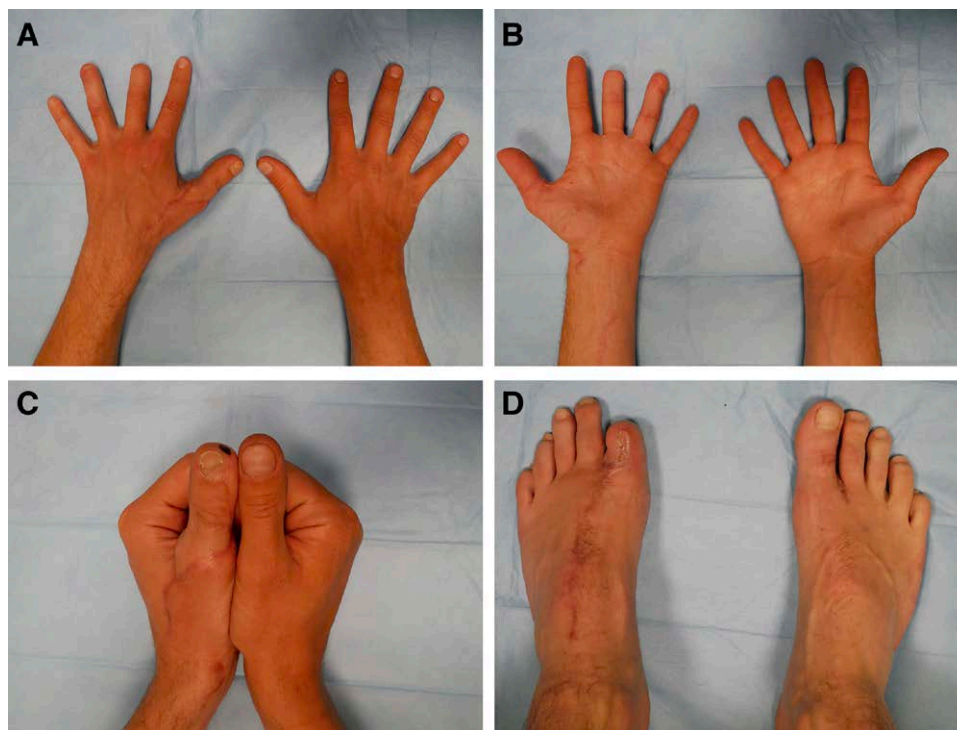


Fig. 5. A–C, Follow-up after 5 months. D, Donor site after 5 months.

flap, combined with great surgical skill, TGT is capable of offering a truly attractive and promising tailored surgical option (Figs. 3–5). (See Video [online], which displays the 28-year-old patient with a replant failure of the left thumb.)

All values achieved from the PRWHE and MHOQ must be related to residual deficits following complex trauma that also affects the other digits or the contralateral hand.

The drawback of this study is the small sample size, but it can pave the way to further research. In our opinion, the patient's choice of restoring length and aesthetics

of the long digit defects should be accepted to and, if possible, granted. The contraindications of the TGT technique are the unavailable recipient vessels of the traumatized hand or previous surgery to the great toe or foot. Compared with a simple regularization, the general disadvantages of this technique are the prolonged surgical time with general anesthesia, length of stay, donor site morbidity, and more prolonged rehabilitation. In our experience, we have found no disadvantages in this technique compared with the classic great toe flap or other microsurgical flaps.

CONCLUSIONS

Based on our preliminary findings, we think that the TGT flap is a viable option for digit reconstruction following amputation, as it provides both functional and aesthetic results. Therefore, this technique should be included in the hand surgeon's toolbox and offered to the patients.

“Aesthetically normal, since in aesthetic importance, the hand is second only to the face.”

—Morrison WA. 1992

Luigi Troisi, MD, PhD, FEBOPRAS

Reconstructive Microsurgery Service
University Department of Hand Surgery and Rehabilitation
San Giuseppe Hospital
IRCCS Multimedica Group
Via San Vittore 1220123
Milan, Italy

REFERENCES

- Kurucan E, Thirukumaran C, Hammert WC. Trends in the management of traumatic upper extremity amputations. *J Hand Surg Am.* 2020;45:1086.e1–1086.e11.
- Win TS, Henderson J. Management of traumatic amputations of the upper limb. *BMJ.* 2014;348:g255.
- Oleske DM, Hahn JJ. Work-related injuries of the hand: data from an occupational injury/illness surveillance system. *J Community Health.* 1992;17:205–219.
- Sorock GS, Lombardi DA, Hauser RB, et al. Acute traumatic occupational hand injuries: type, location, and severity. *J Occup Environ Med.* 2002;44:345–351.
- Ono S, Chung KC. Efficiency in digital and hand replantation. *Clin Plast Surg.* 2019;46:359–370.
- Chung KC, Alderman AK. Replantation of the upper extremity: indications and outcomes. *J Hand Surg.* 2002;2:78–94.
- Kutler W. A new method for finger tip amputation. *J Am Med Assoc.* 1947;133:29.
- Moberg E. Aspects of sensation in reconstructive surgery of the upper extremity. *J Bone Joint Surg Am.* 1964;46:817–825.
- Adani R, Tang JB, Elliot D. Soft and tissue repair of the hand and digital reconstruction. *J Hand Surg Eur Vol.* 2022;47:89–97.
- Tang JB, Elliot D, Adani R, et al. Repair and reconstruction of thumb and finger tip injuries: a global view. *Clin Plast Surg.* 2014;41:325–359.
- Troisi L, Zanchetta F, Berner JE, et al. Reconstruction of digital defects with the free proximal ulnar artery perforator flap. *Plast Reconstr Surg Glob Open.* 2022;10:e4054.
- Halbert CF, Wei FC. Neurosensory free flaps. Digits and hand. *Hand Clin.* 1997;13:251–262.
- Koshima I, Etoh H, Moriguchi T, et al. Sixty cases of partial or total toe transfer for repair of finger losses. *Plast Reconstr Surg.* 1993;92:1331–1338.
- Huemer GM. Carl Nicoladoni and the concept of toe-to-hand transfer at the turn of the nineteenth century. *Plast Reconstr Surg.* 2005;115:1432–1433.
- Buncke HJ Jr, Buncke CM, Schulz WP. Immediate Nicoladoni procedure in the Rhesus monkey, or hallux-to-hand transplantation, utilising microminiature vascular anastomoses. *Br J Plast Surg.* 1966;19:332–337.
- Dongyue Y, Yudong G. Thumb reconstruction utilizing second toe transplantation by microvascular anastomosis: report of 78 cases. *Chin Med J (Engl).* 1979;92:295–309.
- Cobbett JR. Free digital transfer. Report of a case of transfer of a great toe to replace an amputated thumb. *J Bone Joint Surg Br.* 1969;51:677–679.
- Morrison WA. Thumb and fingertip reconstruction by composite microvascular tissue from the toes. *Hand Clin.* 1992;8:537–550.
- Morrison WA, O'Brien BM, MacLeod AM. Thumb reconstruction with a free neurovascular wrap-around flap from the big toe. *J Hand Surg Am.* 1980;5:575–583.
- Wei FC. Tissue preservation in hand injury: the first step to toe-to-hand transplantation. *Plast Reconstr Surg.* 1998;102:2497–2501.
- Lin PY, Sebastin SJ, Ono S, et al. A systematic review of outcomes of toe-to-thumb transfers for isolated traumatic thumb amputation. *Hand (N Y).* 2011;6:235–243.
- Wei FC, Chen HC, Chuang CC, et al. Reconstruction of the thumb with a trimmed-toe transfer technique. *Plast Reconstr Surg.* 1988;82:506–515.
- Wei FC, Chen HC, Chuang DC, et al. Aesthetic refinements in toe-to-hand transfer surgery. *Plast Reconstr Surg.* 1996;98:485–490.
- Morrison WA. Thumb reconstruction: a review and philosophy of management. *J Hand Surg Br.* 1992;17:383–390.
- McLean JM, Hasan AP, Willet J, et al. Asymptomatic reference values for the disability of arm, shoulder and hand and patient-rated wrist/hand evaluation—electronic data collection and its clinical implications. *J Hand Surg Eur Vol.* 2018;43:988–993.
- MacDermid JC, Tottenham V. Responsiveness of the disability of the arm, shoulder, and hand (DASH) and patient-rated wrist/hand evaluation (PRWHE) in evaluating change after hand therapy. *J Hand Ther.* 2004;17:18–23.
- Shauver MJ, Chung KC. The Michigan hand outcomes questionnaire after 15 years of field trial. *Plast Reconstr Surg.* 2013;131:779e–787e.
- Farzad M, Lu Z, MacDermid JC, et al. Measurement properties of the Michigan hand outcomes questionnaire: Rasch analysis of responses from a traumatic hand injury population. *Disabil Rehabil.* 2021;44:4081–4089.
- Komatsu S, Tamai S. Successful replantation of a completely cut-off thumb. *Plast Reconstr Surg.* 1968;42:374–377.
- Michon J, Merle M, Bouchon Y, et al. Functional comparison between pollicization and toe-to-hand transfer for thumb reconstruction. *J Reconstr Microsurg.* 1984;1:103–112.
- Michon J, Merle M, Bouchon Y, et al. Thumb reconstruction pollicisation or toe-to-hand transfers. A comparative study of functional results. *Ann Chir Main.* 1985;4:98–110.
- Wei FC, Chen HC, Chuang CC, et al. Microsurgical thumb reconstruction with toe transfer: selection of various techniques. *Plast Reconstr Surg.* 1994;93:345–351.
- Turner A, Ragowanni R, Hanna J, et al. Microvascular soft tissue reconstruction of the digits. *J Plast Reconstr Aesthet Surg.* 2006;59:441–450.
- García Julve G, Martínez Villén G. The multiple monoblock toe-to-hand transfer in digital reconstruction. A report of ten cases. *J Hand Surg Br.* 2004;29:222–229.
- Buncke GM, Buncke HJ, Oliva A, et al. Hand reconstruction with partial toe and multiple toe transplants. *Clin Plast Surg.* 1992;19:859–870.
- Lister GD, Kalisman M, Tsai TM. Reconstruction of the hand with free microneurovascular toe-to-hand transfer: experience with 54 toe transfers. *Plast Reconstr Surg.* 1983;71:372–386.