

## SHORT COMMUNICATION

# Multiple giant cell formation – A consequence of type II pyrethroid intoxication

**Brijender BHUSHAN, Prabhu Narain SAXENA**

Toxicology Laboratory, Department of Zoology, School of Life Sciences, Dr. Bhim Rao Ambedkar University, Khandari Campus, Agra-282002, India

ITX110218A08 • Received: 4 November 2016 • Accepted: 03 October 2017

## ABSTRACT

Pesticides are the main remedy for pest eradication, but their use has been found to be harmful also to various non-target organisms. In this study, giant cell formation was observed in hepatocytes of experimental albino rats following two type II pyrethroid pesticides, Cypermethrin and Beta-cyfluthrin. Histopathological examination was done for this purpose and the results revealed the formation of giant cells and polyploidy condition following intoxication of these experimental compounds with Beta-cyfluthrin, with an edge over, and Cypermethrin, probably due to structural differences.

**KEY WORDS:** pyrethroids; toxicity; liver

## Introduction

The use of pesticides and their designing has increased with great pace pertaining to increased global food demands as well as genetical modifications leading to resistance development in various pest species. Pyrethroid pesticides, covering of a large part of the world insecticide market, are an integral part of eradication programs and find their use both in domestic and large scale field purposes (Bian *et al.*, 2004; Bhalli *et al.*, 2006; Bhushan *et al.*, 2010; 2013; Saxena & Gaur, 2016). Pyrethroids are considered comparatively safe pesticides and therefore many new synthetic analogues have been added to the market. Contrary to their broad spectrum of use due to their low photostability and non-target toxicity, they can disturb various ecological balances existing on this planet (Rana *et al.*, 2008; Bhushan *et al.*, 2013; Pande *et al.*, 2014; Saxena & Gaur, 2016; Saxena & Bhushan, 2017). We have therefore evaluated and compared hepatocytic toxicity of two broadly used types pyrethroid pesticides, *i.e.* cypermethrin and beta-cyfluthrin, focusing on giant cell formation if any, through histological analysis. Beta-cyfluthrin was found to be designed from cypermethrin by introduction of a fluorine atom at position 4 of the phenyl ring in its structure (Figures 1 and 2).

The present study was conducted on 75 female albino rats, *Rattus norvegicus*, selected from an inbred colony.

The animals were about two weeks in age and 100±20 g in weight. They were kept under appropriate temperature and light conditions, provided with standard rat pellet feed and water *ad libitum*. After one week of acclimatization to laboratory conditions, the rats were divided into three sets of equal number, *i.e.* 25 rats each. The experimental compounds cypermethrin and beta-cyfluthrin (technical grades of approximately 95% purity) were orally administered to the rats in acute (1/10<sup>th</sup> of LD<sub>50</sub> for 1 d) and sub-acute (1/10<sup>th</sup> of LD<sub>50</sub> for 7, 14, 21 and 28 ds) doses. All these three sets, one corresponding to control and the other two, *i.e.* cypermethrin and beta-cyfluthrin, were subdivided into five subsets each comprising five rats. LD<sub>50</sub> for cypermethrin and beta-cyfluthrin (Finney, 1971) were 416.98 and 354.8 mg/kg b.wt., respectively (Bhushan *et al.*, 2010; 2013; Bhushan & Saxena, 2017). The rats were then sacrificed at predetermined time intervals. Liver tissue was excised, washed in physiological saline, cut into small pieces, fixed in carnoys fixative (Gatenby & Beams, 1950) for 4 hours, dehydrated, embedded, sectioned (5 μ sections) and finally stained with hematoxylin and eosin (Humason, 1979). These sections were then observed at 400× and 1000× and appropriate locations were photographed. Maximum incidence of hypertrophy and giant cell formation was found in albino rat liver intoxicated with sub-acute dose for 14 days. The beta-cyfluthrin intoxication was more expressive than that of cypermethrin (Figures 3–5).

The liver size of an organism is tightly regulated, yet stress conditions can increase its size markedly. The consequences of increasing liver size are primarily increase in cell division (hyperplasia) or increase in cell volume (hypertrophy). Giant cell formation as observed in the

Correspondence address:

**Dr. Brijender Bhushan**

Toxicology Laboratory, Department of Zoology, School of Life Sciences,  
Dr. Bhim Rao Ambedkar University  
Khandari Campus, Agra-282002, India  
TEL.: +91-562-2526432 • FAX +91-562-4031312  
E-MAIL: bantu.sls@gmail.com

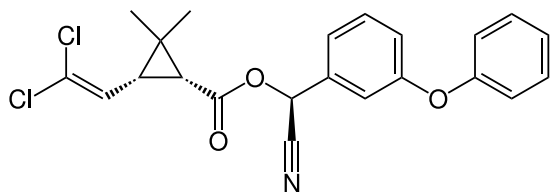


Figure 1. Structure of cypermethrin.

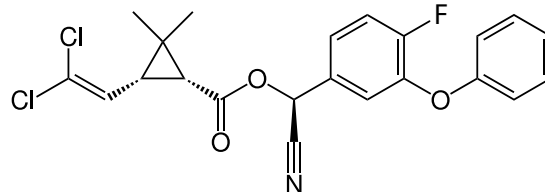


Figure 2. Structure of beta-cyfluthrin.

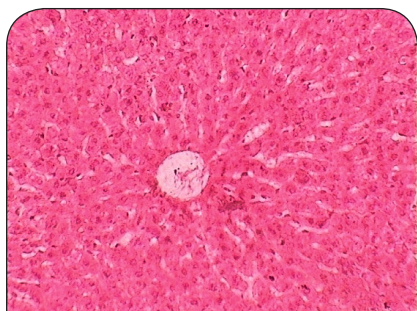

Figure 3. Histo-architecture of control albino rat liver (400x).

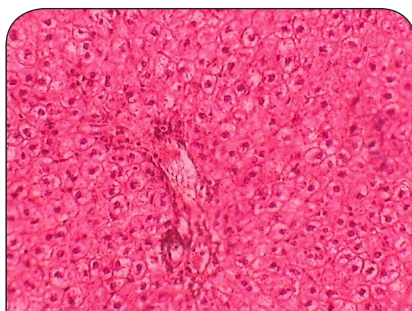

Figure 4. Histo-architecture of cypermethrin intoxicated albino rat liver (400x).

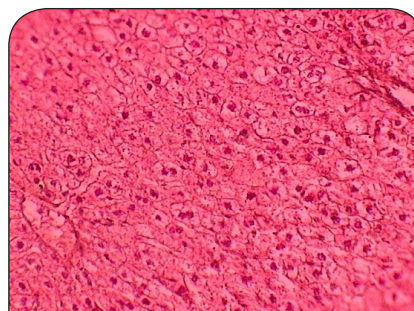


Figure 5. Histo-architecture of beta-cyfluthrin intoxicated albino rat liver (400x).

present study may be a consequence of hypertrophy, which may be a consequence of polyploidy condition. Polyploidy in turn is associated with altered DNA function. However, it is now broadly accepted that type II pyrethroids, including both our experimental compounds, are well capable of causing chromosomal as well as DNA damage and altering cell cycles, which may lead to consequences of tumor promotion (Singh & Saxena, 2002; Bhushan *et al.*, 2010; Madkour 2012). It is though noteworthy to mention cancer promotion by these experimental compounds. The previous results of excess DNA synthesis and now the presence of giant cell formation in subpopulations of hepatic lobule point towards the same aspects. Tumor promotion, is a very complex process having various mysterious and multistep pathways. But initially carcinogenesis induces nuclear enlargement which is generally associated with increase in DNA content. Increase in DNA content and altered cell cycle can also be justified by the fact in our study that we got hepatic ALP values lower in treated rats than in controls (Bhushan *et al.*, 2013). This fact concerns also altered DNA synthesis as ALP is an important enzyme catalyzing cleavage of phosphate groups, an integral part of DNA. This suggest formation of ploidy conditions in these hepatocytes, which further can get transformed into malignant.

Further, giant cell formation is more pronounced in case of beta-cyfluthrin than cypermethrin, probably due to structural differences in their chemistry. Beta-cyfluthrin is a more recent pyrethroid product than cypermethrin and has been designed by modifying basic cypermethrin structure at the level of addition of fluorine group to position 4 of phenyl ring in beta-cyfluthrin, which seems to be responsible for its enhanced toxicity as C-F bond is one of the strongest bond and difficult to break (Bhushan *et al.*, 2013; Bhushan & Saxena, 2017).

## REFERENCES

- Bhali JA, Khan QM, Haq MA, Khalid AM and Nasim A. (2006). Cytogenetic analysis of Pakistani individuals occupationally exposed to pesticides in a pesticide production industry. *Mutagenesis* **21**: 143–148.
- Bhushan B, Saxena N and Saxena PN. (2010). Beta-cyfluthrin induced histochemical alterations in the liver of albino rat. *Scand J Lab Anim Sci* **37**: 61–66.
- Bhushan B, Saxena PN and Saxena N. (2013). Biochemical and histological changes in rat liver caused by cypermethrin and beta-cyfluthrin. *Arh Hig Rada Toksikol* **64**: 57–67.
- Bhushan B and Saxena PN. (2017). Estimation of median lethal dose of cypermethrin and beta-cyfluthrin. *Int J Toxicol Pharmacol Res* **9**(3): 194–198.
- Bian Q, Xu LC, Wang SL, Xia YK, Tan LF, Chen JF, Song L, Chang HC, Wang XR. (2004). Study on the relation between occupational fenvalerate exposure and spermatozoa DNA damage of pesticide factory workers. *Occup Environ Med* **61**: 999–1005.
- Finey DJ. (1971). *Probit Analysis*. Cambridge University Press, 303 pp.
- Gatenby JB and Beams HM. (1950). *The microtome's vade-mecum*. London J. and A. Churchill.
- Humason GL. (1979). *Animal Tissue Techniques*. 4th ed. San Francisco (CA): Freeman and Company.
- Madkour NK. (2012). Protective effect of curcumin on oxidative stress and DNA fragmentation against lambda cyhalothrin-induced liver damage in rats. *J Appl Pharm Sci* **2**(12): 076–081.
- Pande S, Saxena PN, Bhushan B and Saxena N. (2014). Peripheral blood and bone marrow responses under stress of cypermethrin in albino rats. *Interdiscip Toxicol* **7**(1): 33–40.
- Rana N, Saxena N, Sharma HN and Saxena PN. (2008). Comparative genotoxicity of alpha-cyano pyrethroids on *Drosophila melanogaster*. *Entomol* **33**: 135–138.
- Saxena PN and Gaur HK. (2016). Biochemical responses of developing stages of wild *Drosophila melanogaster* after beta-cyfluthrin intoxication. *Eur J Biotech Biosci* **4**(4): 06–08.
- Saxena PN and Bhushan B. (2017). Estimation of median lethal dose of commercial formulations of some type II pyrethroids. *Jordan J Biol Sci* **10**(3): 193–197.
- Singh VK and Saxena PN. (2002). Genotoxic potential of cypermethrin in mammalian haemopoietic system. *Him J Env Zool* **16**(2): 195–202.