

Complete Atrioventricular Block during Thoracic Endovascular Aortic Repair

Abstract

Acute coronary syndrome (ACS) and acute aortic syndrome (AAS) are both life-threatening emergencies. We report a case of ACS with thoracic aneurysm. Thoracic endovascular aortic repair (TEVAR) was arranged. However, perioperative complete atrioventricular block occurred and soon progressed to ST-elevation myocardial infarction. In the case of chest discomfort with elevated troponin I and thoracic aneurysm, it is of tremendous importance to cope with both ACS and the possible AAS. In the era of hybrid operation room, coronary catheterization and intervention first followed by TEVAR may provide timely and more comprehensive treatment.

Keywords: Acute coronary syndrome, aortic aneurysm, atrioventricular block

**Hao-Nung Shyu,
Po-Han Li,
Shih-Kai Liu,
Yi-Ying Chiang**

*Department of Anesthesiology,
China Medical University
Hospital, China Medical
University, Taichung, Taiwan*

Introduction

Possible causes of patients initially presenting with chest pain at the emergency department (ED) include acute coronary syndrome (ACS) and acute aortic syndromes (AAS). ACS and AAS may sometimes mimic each other.^[1] ACS may also occur as a complication of AAS, such as type A aortic dissection.^[2] Accurate diagnosis is a critical component of clinical management. We report a case of ACS who was also found to have a thoracic aneurysm. Emergent thoracic endovascular aortic repair (TEVAR) was performed; however, complete atrioventricular (AV) block occurred during the procedure.

Case Report

A 63-year-old man was sent to the ED due to chest pain, chest tightness, and light-headedness since the previous day. The patient was taking oral medication for benign prostate hypertrophy. He denied other health problems. At the ED, the heart rate was 95 bpm, blood pressure was 127/80 mmHg, and the SpO₂ was 96% breathing room air. Initially, an electrocardiography (ECG) showed a sinus rhythm with first-degree AV block. Troponin I level was 0.21 ng/mL (≥ 0.1 was regarded as abnormal). Two hours later, the ECG was similar to that previously recorded. Troponin I level was raised to 0.37 ng/ml.

This is an open access journal, and articles are distributed under the terms of the Creative Commons Attribution-NonCommercial-ShareAlike 4.0 License, which allows others to remix, tweak, and build upon the work non-commercially, as long as appropriate credit is given and the new creations are licensed under the identical terms.

For reprints contact: reprints@medknow.com

The patient was treated as ACS with aspirin, nitroglycerin, ticagrelor, heparin, and morphine. The patient's symptoms improved partially despite treatment. Therefore, a chest computed tomography was arranged and showed a small aneurysm in the proximal descending aorta close to left subclavian artery [Figure 1]. The cardiovascular surgeon attributed these symptoms as an aneurysm with AAS and arranged TEVAR under general anesthesia in our hybrid operation room.

In the operation room, the initial heart rate was 80 bpm, blood pressure was around 125/65 mmHg in both arms, and the SpO₂ was 98% breathing room air. After establishing the right radial arterial line, general anesthesia was induced with intravenous fentanyl 100 mcg, lidocaine 40 mg, etomidate 12 mg, and rocuronium 50 mg. We intubated the patient, and a central venous catheter was placed in the right internal jugular vein.

Approximately 20 min after completing the preparation, bradycardia to 30 bpm suddenly occurred in association with a systolic blood pressure of around 50 mmHg. The ECG monitor revealed a complete AV block. Intravenous boluses of atropine 0.5 mg were administered in vain. The surgeon performed chest compression for approximately 5 min until transcutaneous pacing started. The systolic blood pressure returned and stayed around 90 mmHg under pacing. TEVAR was

How to cite this article: Shyu HN, Li PH, Liu SK, Chiang YY. Complete atrioventricular block during thoracic endovascular aortic repair. *Ann Card Anaesth* 2019;22:325-7.

Address for correspondence:

*Dr. Yi-Ying Chiang,
Department of Anesthesiology,
China Medical University
Hospital, No. 2 Yude Road,
Taichung 40447, Taiwan.
E-mail: chiang.yiying@gmail.
com*

Access this article online

Website: www.annals.in

DOI: 10.4103/aca.ACA_68_18

Quick Response Code:



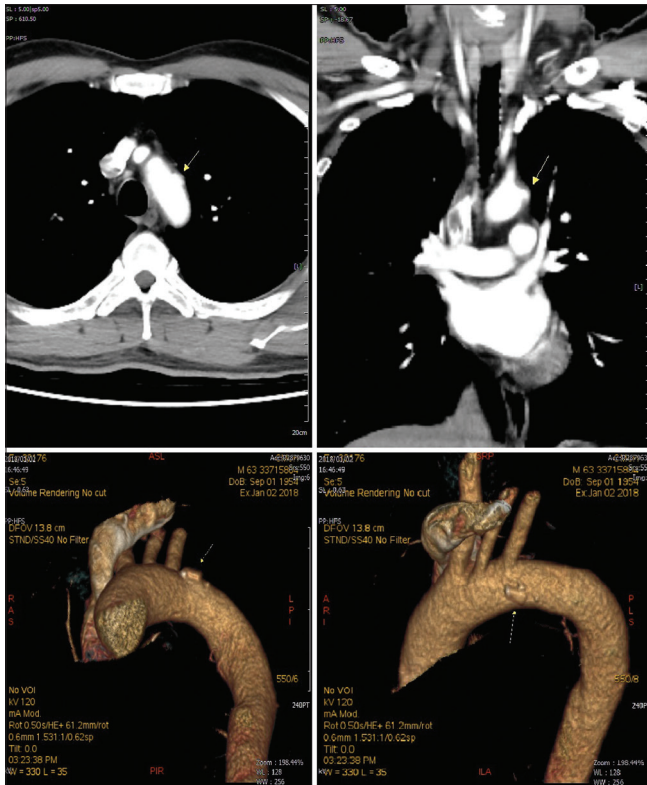


Figure 1: Chest computed tomography showed a small aneurysm in the proximal descending aorta close to the left subclavian artery

still carried out as planned otherwise uneventfully. After TEVAR, the cardiologist was consulted, and a transvenous pacing system was set up in the hybrid operation room before the patient was transferred to Intensive Care Unit (ICU).

Within the 1st h in ICU, serial complete ECG revealed ST elevation in the inferior leads. Emergent coronary angiography was arranged and revealed a right coronary artery total occlusion [Figure 2].

Discussion

AAS presents as abrupt-onset chest pain in approximately 80% of patients, and the pain is frequently sharp and severe in quality.^[3] Acute myocardial infarction (AMI) typically presents as chest tightness and may sometimes be a complication of AAS; however, this occurs in only 3%–7% of acute aortic dissections and is typically associated with Stanford type A dissection.^[4] In this case, although an aneurysm is located in the descending thoracic aorta, it was still considered a possible source of chest pain since the symptoms did not respond as expected after treatment for ACS.

Common causes of AV block include coronary artery disease, degenerative heart diseases, infection, rheumatic heart diseases, vagally induced conduction block, and iatrogenic causes.^[5] The AV node is supplied by the right coronary artery in 90% of individuals.^[6] Complete AV

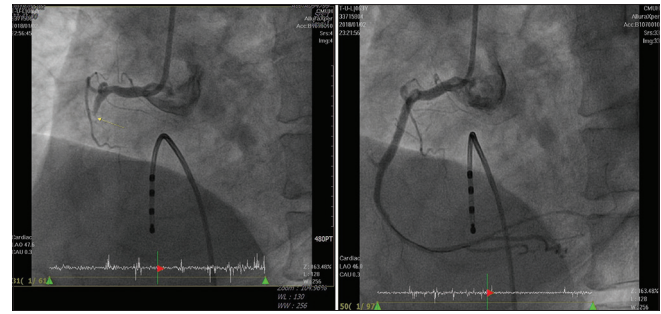


Figure 2: Coronary angiography showed middle right coronary artery total occlusion (left). Coronary angiography after balloon dilatation and stent application (right)

block has been reported to occur in 5% of patients with AMI. Mortality among patients of AMI complicated with complete AV block is three times that among patients of AMI without complete AV block.^[7]

The true prevalence of thoracic aortic aneurysms is uncertain; however, the prevalence at autopsy has been reported as approximately 3%. The majority of thoracic aortic aneurysms were typically asymptomatic and were discovered incidentally on imaging studies. Only approximately 5% of thoracic aortic aneurysms are symptomatic.^[8,9]

If asymptomatic, idiopathic or sporadic thoracic aortic aneurysms would merit surgical repair when the size was 5.5 cm or larger. In thoracic aortic aneurysms associated with Marfan syndrome or with familial thoracic aortic aneurysm, the threshold is lowered to 5.0 cm. However, when thoracic aortic aneurysms become symptomatic, emergent TEVAR could be life saving and is preferred over open surgeries when possible.^[10]

In reality, facing a case of chest discomfort with elevated troponin I and thoracic aneurysm, it is difficult to exclude the possibility of AAS. For thoracic aneurysm with AAS, emergent TEVAR might be reasonable; however, for ACS, timely coronary angiography and intervention is the key for patient survival. Given the hybrid operation room was available, if we perform coronary catheterization and intervention first and then the TEVAR, we can probably treat the patient better without progression to AV block and myocardial infarction.

Declaration of patient consent

The authors certify that they have obtained all appropriate patient consent forms. In the form the patient(s) has/have given his/her/their consent for his/her/their images and other clinical information to be reported in the journal. The patients understand that their names and initials will not be published and due efforts will be made to conceal their identity, but anonymity cannot be guaranteed.

Financial support and sponsorship

Nil.

Conflicts of interest

There are no conflicts of interest.

References

1. Tsai TT, Nienaber CA, Eagle KA. Acute aortic syndromes. *Circulation* 2005;112:3802-13.
2. Imoto K, Uchida K, Karube N, Yasutsune T, Cho T, Kimura K, *et al.* Risk analysis and improvement of strategies in patients who have acute type A aortic dissection with coronary artery dissection. *Eur J Cardiothorac Surg* 2013;44:419-24.
3. Hiratzka LF, Bakris GL, Beckman JA, Bersin RM, Carr VF, Casey DE Jr., *et al.* 2010 ACCF/AHA/AATS/ACR/ASA/SCA/SCAI/SIR/STS/SVM guidelines for the diagnosis and management of patients with thoracic aortic disease: A report of the American College of Cardiology Foundation/American Heart Association Task Force on Practice Guidelines, American Association for thoracic surgery, American College of Radiology, American Stroke Association, Society of Cardiovascular Anesthesiologists, Society for Cardiovascular Angiography and Interventions, Society of Interventional Radiology, Society of Thoracic Surgeons, and Society for Vascular Medicine. *Circulation* 2010;121:e266-369.
4. Kawano H, Tomichi Y, Fukae S, Koide Y, Toda G, Yano K, *et al.* Aortic dissection associated with acute myocardial infarction and stroke found at autopsy. *Intern Med* 2006;45:957-62.
5. Barra SN, Providência R, Paiva L, Nascimento J, Marques AL. A review on advanced atrioventricular block in young or middle-aged adults. *Pacing Clin Electrophysiol* 2012;35:1395-405.
6. Pejčović B, Krajnc I, Anderhuber F, Kosutić D. Anatomical aspects of the arterial blood supply to the sinoatrial and atrioventricular nodes of the human heart. *J Int Med Res* 2008;36:691-8.
7. Spencer FA, Jabbour S, Lessard D, Yarzebski J, Ravid S, Zaleskas V, *et al.* Two-decade-long trends (1975-1997) in the incidence, hospitalization, and long-term death rates associated with complete heart block complicating acute myocardial infarction: A community-wide perspective. *Am Heart J* 2003;145:500-7.
8. Hagan PG, Nienaber CA, Isselbacher EM, Bruckman D, Karavite DJ, Russman PL, *et al.* The international registry of acute aortic dissection (IRAD): New insights into an old disease. *JAMA* 2000;283:897-903.
9. Elefteriades JA, Sang A, Kuzmik G, Hornick M. Guilt by association: Paradigm for detecting a silent killer (thoracic aortic aneurysm). *Open Heart* 2015;2:e000169.
10. Dudzinski DM, Isselbacher EM. Diagnosis and management of thoracic aortic disease. *Curr Cardiol Rep* 2015;17:106.