



Contents lists available at [ScienceDirect](https://www.sciencedirect.com)

# AAACE Clinical Case Reports

journal homepage: [www.aaaceclinicalcasereports.com](http://www.aaaceclinicalcasereports.com)



## Case Report

# The Vanishing Adrenal Glands: A Transient Regression of Adrenal Lymphoma After a Single Dose of 1 mg Dexamethasone

Shamaila Zaman, MRCP<sup>1,\*</sup>, Hessa Boharoon, MD<sup>1</sup>, Neelam Khalid, MRCP<sup>1</sup>, Sasha Marks, PhD<sup>2</sup>, Ali Alsafi, EBIR<sup>3</sup>, Rashpal Flora<sup>4</sup>, Neil Hill, PhD, MRCP<sup>1</sup>, Emma Hatfield, MRCP<sup>1</sup>, Karim Meeran, PhD<sup>1</sup>

<sup>1</sup> Imperial Centre for Endocrinology and Diabetes, Imperial College Healthcare NHS Trust, London, United Kingdom

<sup>2</sup> Haematology Department, Hammersmith Hospital, Imperial College Healthcare NHS Trust, London, United Kingdom

<sup>3</sup> Imaging Department, Hammersmith Hospital, Imperial College Healthcare NHS Trust, London, United Kingdom

<sup>4</sup> Pathology Department, Hammersmith Hospital, Imperial College Healthcare NHS Trust, London, United Kingdom

## ARTICLE INFO

### Article history:

Available online 27 November 2020

### Key words:

adrenal  
adrenal cancer  
adrenal insufficiency

## ABSTRACT

**Objective:** Dexamethasone is a known treatment for lymphoma, but the potency and rapidity of its effect have not been recognized. We present a case of bilateral adrenal lymphoma that significantly reduced in size after a single dose of dexamethasone.

**Methods:** We present the clinical course and investigations, including adrenocorticotropic hormone, cortisol, short synacthen test, computed tomography (CT), and adrenal biopsy results.

**Results:** A 52-year-old man had a fall and was incidentally found to have bilateral adrenal masses (left, 6 cm; right, 5 cm) on CT. His adrenal function tests included plasma metanephrines (normetanephrine, 830 pmol/L [normal, <1180]; metanephrine, <100 pmol/L [<510]; 3-methoxytyramine, <100 pmol/L [<180]); aldosterone, 270 pmol/L (90–700); and random cortisol, 230 nmol/L (160–550). An overnight dexamethasone suppression test with 1 mg of dexamethasone showed cortisol of <28 nmol/L (0–50). A repeat CT scan 8 days thereafter showed adrenal masses of 4.5 and 3.5 cm on the left and right, respectively. He had a follow-up CT scan 3 months later that showed adrenal lesions measuring 8 cm (left) and 9 cm (right). He subsequently presented with fatigue and dizziness. Morning cortisol of 201 nmol/L (160–550) with adrenocorticotropic hormone of 216 ng/L (10–30) indicated primary adrenal insufficiency. Mineralocorticoid and glucocorticoid replacement therapy commenced. An adrenal biopsy showed abnormal enlarged B cells, consistent with a diagnosis of diffuse large B-cell lymphoma.

**Conclusion:** A diagnosis of lymphoma should be considered when adrenal lesions shrink following even a single low dose of dexamethasone administered as a part of a diagnostic test.

© 2020 AAACE. Published by Elsevier Inc. This is an open access article under the CC BY-NC-ND license (<http://creativecommons.org/licenses/by-nc-nd/4.0/>).

## Introduction

Corticosteroids may induce a clinical and radiologic regression in lymphomas, which could lead to a diagnostic challenge.<sup>1</sup> This

*Abbreviations:* ACTH, adrenocorticotropic hormone; CT, computed tomography; DLBCL, diffuse large B-cell lymphoma; ONDST, overnight dexamethasone suppression test; PAI, primary adrenal insufficiency; PET, positron emission tomography; SST, short synacthen test.

\* Address correspondence and reprint requests to Dr Shamaila Zaman, Department of Endocrinology and Diabetes, Floor 9 East, Charing Cross Hospital, Imperial College Healthcare NHS Trust, Fulham Palace Road, Hammersmith, London, W6 8RF, United Kingdom.

E-mail address: [shamaila.zaman1@nhs.net](mailto:shamaila.zaman1@nhs.net) (S. Zaman).

<https://doi.org/10.1016/j.aaace.2020.11.022>

2376-0605/© 2020 AAACE. Published by Elsevier Inc. This is an open access article under the CC BY-NC-ND license (<http://creativecommons.org/licenses/by-nc-nd/4.0/>).

phenomenon has been noted in central nervous system lymphomas; however, “vanishing lymphomas” at other sites are rare.<sup>1–3</sup> We describe a case of incidental bilateral adrenal lesions that fluctuated in size after a single dose of 1 mg of dexamethasone.

## Case Report

A 52-year-old man presented to the emergency department with left-sided chest and upper abdominal pain following a fall from stairs. He had a background of hypertension and atrial fibrillation, and his medications included ramipril, amlodipine, and apixaban. A chest radiograph showed a fracture of the seventh rib.

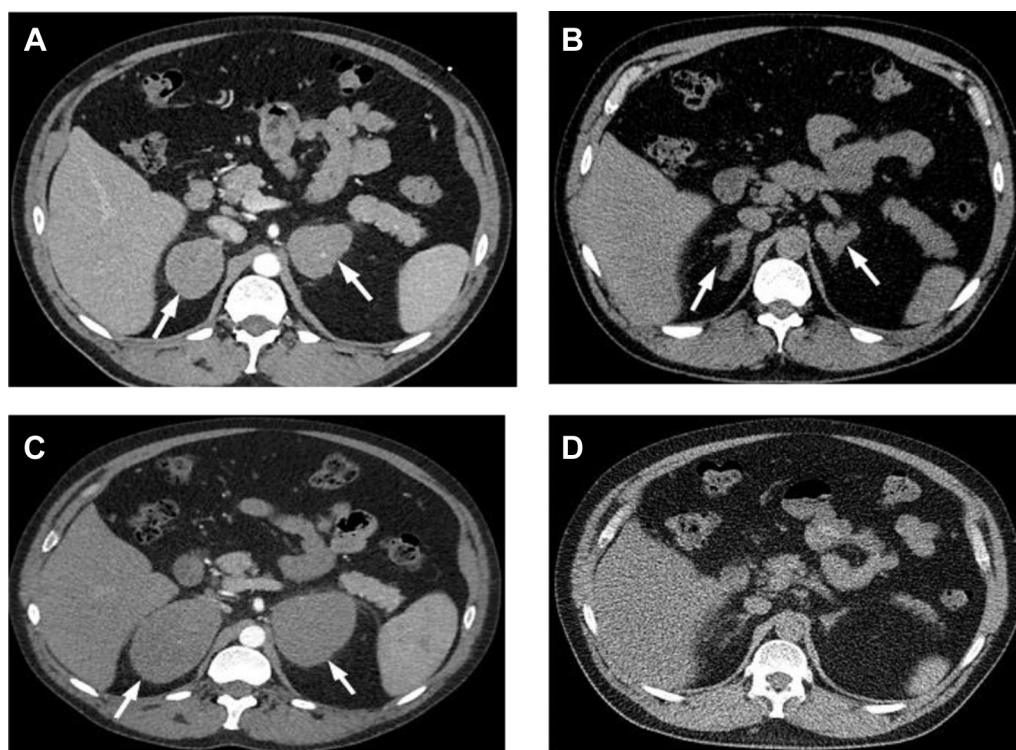
Computed tomography (CT) of the chest, abdomen, and pelvis was undertaken to exclude occult hemorrhage because he was on anticoagulation therapy. This showed an incidental finding of bilateral adrenal masses measuring 6 cm (left) and 5 cm (right), with 50 Hounsfield units in the portal venous phase (Fig. 1 A) and an enlarged spleen measuring 14.5 cm (normal size, up to 13 cm). On review in the endocrine clinic, he reported tiredness, palpitations, and weight gain for the past 6 years. On examination, his blood pressure was 116/90 mm Hg, and his heart rate was 97/min, with a body mass index of 32 kg/m<sup>2</sup>. His systemic examination result was normal, with no lymphadenopathy or Cushingoid features. His baseline adrenal function test results, including plasma metanephrines (normetanephrine, 830 pmol/L; metanephrine <100 pmol/L; and 3-methoxytyramine <100 pmol/L), aldosterone (270 pmol/L), random cortisol (230 nmol/L), and adrenocorticotropic hormone (ACTH; 29.4 ng/L), were normal. An overnight dexamethasone suppression test (ONDST) with 1 mg of dexamethasone showed cortisol of <28 nmol/L the following morning at 8 AM, excluding autonomous cortisol secretion. Eight days following the 1-mg ONDST, a dedicated, follow-up adrenal CT showed a marked reduction in the size of both adrenal glands (left, 4.5 cm; right, 3.5 cm) (Fig. 1 B) and the spleen (12.5 cm). The adrenal radiologist further reported that the noncontrast, portal venous phase, and late phase Hounsfield units were 35, 54, and 45, respectively, with an absolute washout of 47% and a relative washout of 17%, in keeping with indeterminate adrenal lesions.

An infectious screen was negative (including hepatitis B, hepatitis C, cytomegalovirus, Epstein-Barr virus, human immunodeficiency virus, human T-cell lymphoma virus, and tuberculosis [ELISpot screen]). Results of an autoimmune screening ( $\beta_2$ -microglobulin, myeloma screen, and antinuclear antibody) were normal. An early interval CT was planned at 3 months, which showed the

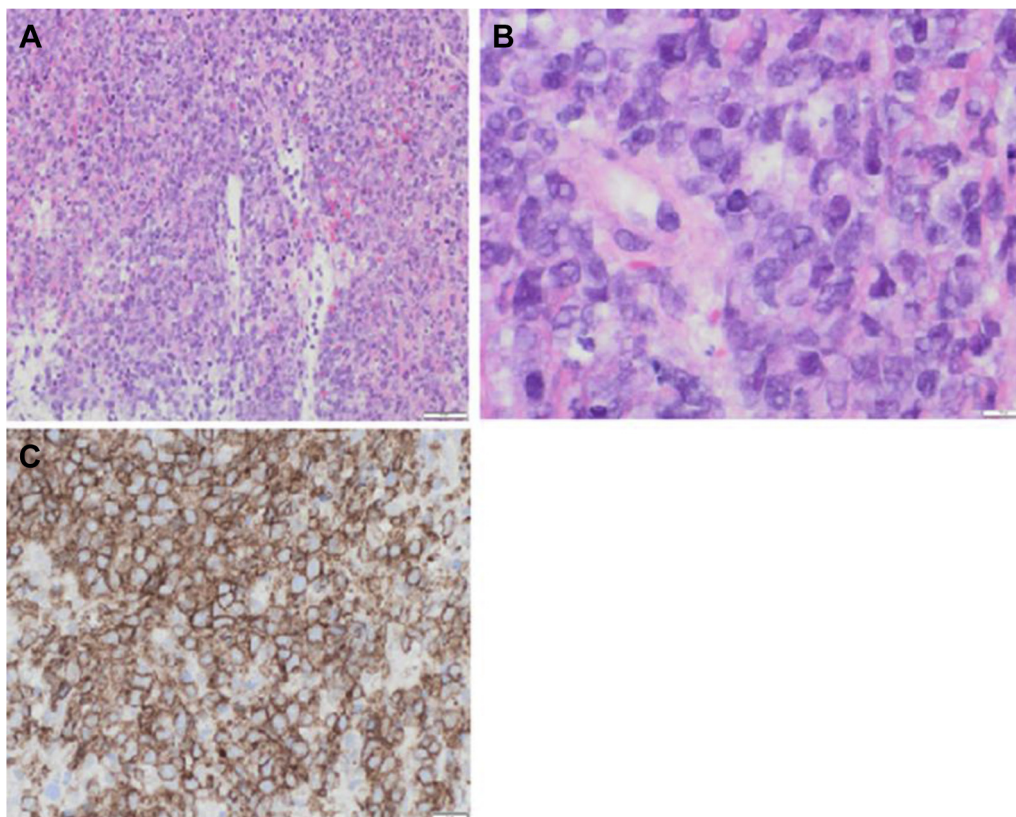
adrenal lesions measuring 8 cm (left) and 9 cm (right) (Fig. 1 C) and splenomegaly of 19 cm. A multisystem disease, such as lymphoproliferative disorder, was suspected due to re-enlargement of the adrenal masses along with splenomegaly. A few days later, the patient was admitted with severe fatigue and postural dizziness. He also reported night sweats for the past few months. On admission, his blood pressure was 91/53 mm Hg, and his heart rate was 103/min. The remainder of his clinical examination was normal.

The laboratory results showed hemoglobin of 105 g/L (normal, 130–168), a white blood cell count of  $3.5 \times 10^9/L$  (4.2–10.6), and platelets of  $114 \times 10^9/L$  (130–370). Random serum cortisol was 261 nmol/L, and ACTH was 74.8 ng/L. Although the random cortisol was within the normal reference range, given the clinical presentation and elevated ACTH, he was diagnosed with primary adrenal insufficiency (PAI) and started on hydrocortisone and fludrocortisone. Two days later, a short synacthen test (SST) showed 30-minute stimulated cortisol of 216 nmol/L (normal response, >450 nmol/L) with baseline cortisol of 201 nmol/L. The baseline ACTH was 108 ng/L. The results confirmed PAI.

An adrenal biopsy was performed, and histology reported atypical lymphoid cells with pleomorphic hyperchromatic nuclei. The cells expressed CD20, c-myc, MUM1, BCL6, and BCL2. These features were considered to be consistent with diffuse large B-cell lymphoma (DLBCL), nongerminal subtype, with a Ki-67 of approximately 80% (Fig. 2). The patient received 2 cycles of rituximab, cyclophosphamide, doxorubicin, vincristine, and methotrexate chemotherapy, with a dose of 100-mg hydrocortisone on the induction of chemotherapy at each cycle. He also had hydrocortisone at doses of 20 mg at 8 AM, 10 mg at 12 AM, and 10 mg at 4 PM and fludrocortisone 50  $\mu$ g once daily. On completion of his chemotherapy, the <sup>18</sup>F-fluoro-2-deoxy-D-glucose positron emission tomography (PET) examination result was normal, with no



**Fig. 1.** CT images showing the varying sizes of the adrenal lesions during the course of the disease. A, Bilateral adrenal lesions (arrows) replacing the entirety of both adrenal glands (July 2018). B, Reduction in the size of the adrenal lesions (arrows) following an overnight dexamethasone suppression test but with residual adrenal nodularity (October 2018). C, Re-enlargement of adrenal masses (arrows) 2 months later (January 2019), which were now larger than the presentation CT image (January 2019). D, Normal-sized adrenal glands following completion of 2 cycles of chemotherapy (September 2019). CT = computed tomography.



**Fig. 2.** Histology. A, Hematoxylin and eosin (magnification: x10) and B, hematoxylin and eosin (magnification: x40) both show the lymphoma, which is composed of a diffuse infiltrate of atypical large lymphoid cells with pleomorphic nuclei. C, CD20 staining (magnification: x20) confirms that these are neoplastic B cells.

evidence of lymphoma. The CT component showed normal size and appearance of the adrenal glands, with complete resolution of the adrenal masses (Fig. 1 D) and splenomegaly. A repeat SST 12 months later showed 30-minute stimulated cortisol of 308 nmol/L with baseline cortisol of 234 nmol/L and ACTH of 54.2 ng/L. The SST showed an improved but suboptimal result, necessitating the continuation of steroid replacement. He is currently on hydrocortisone of 15 mg at 8 AM, 10 mg at 12 AM, and 5 mg at 4 PM and fludrocortisone 50 µg once daily. He remains clinically well and in remission 1 year after completion of chemotherapy and under regular endocrinology and hematology follow-up.

## Discussion

We describe a case of bilateral adrenal masses that reduced in size following the administration of 1 mg of dexamethasone for an ONDST. The patient later presented with PAI, and a repeat CT showed a marked increase in the size of the adrenal lesions. He was given mineralocorticoid and glucocorticoid replacement therapy.

Dexamethasone is a potent fluorinated steroid with a biologic half-life of 72 hours and a duration of action even longer than this.<sup>4</sup> A single dose of dexamethasone has been shown to be as effective as 3 days of prednisolone in acute severe asthma in children.<sup>4</sup> The ONDST involves a single dose administered at 11 PM and a blood sample the following morning to measure cortisol. The therapeutic effects of this single dose are often overlooked.

In our case, an adrenal biopsy showed DLBCL, which responded to rituximab, cyclophosphamide, doxorubicin, vincristine, and methotrexate chemotherapy, and the patient remains in remission at 1 year. Adrenal lymphoma is rare.<sup>5,6</sup> Adrenal insufficiency is commonly reported in adrenal lymphoma and has been described

in up to 61% of cases, which is considerably higher compared with adrenal metastases.<sup>5,6</sup>

CT imaging usually demonstrates complex masses of variable density with slight to moderate contrast enhancement.<sup>5</sup> On magnetic resonance imaging, these lesions show hypointensity on T1- and hyperintensity on T2-weighted imaging.<sup>5</sup> These radiologic findings, however, are not pathognomonic.<sup>3,5</sup> Functional imaging with <sup>18</sup>F-fluoro-2-deoxy-D-glucose PET and <sup>68</sup>Ga-DOTATATE PET demonstrate enhanced uptake by these tumors,<sup>5</sup> but there are no large studies to confirm these findings. Unlike other causes of adrenal pathologies, an adrenal biopsy is required to establish the diagnosis.<sup>3,5</sup> It is imperative that pheochromocytoma is excluded biochemically before a biopsy, to prevent a crisis.<sup>3</sup>

The prognosis for primary adrenal DLBCL is poor.<sup>5</sup> However, R-CHOP (rituximab, cyclophosphamide, doxorubicin, vincristine, and prednisolone) chemotherapy has been shown to be effective, with complete remission in up to 54% of cases.<sup>7</sup> Prednisolone is an effective therapeutic agent, and one report points to prednisolone as 1 of the key treatments for DLBCL.<sup>8</sup>

Our patient's tumors transiently reduced in size following a single dose of dexamethasone. Glucocorticoids have been described to cause clinical and radiologic regression in lymphoma, which could pose a diagnostic dilemma.<sup>1,3</sup> This has been recognized in central nervous system lymphomas; however, "vanishing lymphomas" at other sites have rarely been documented.<sup>1-3</sup> Recently, Grønning et al<sup>3</sup> reported a similar case of a patient with bilateral adrenal masses presenting with adrenal insufficiency. The patient was started on hydrocortisone replacement, and the adrenal masses regressed but later appeared with aggressive regrowth. Similarly, our case also had a striking association between dexamethasone use and a reduction in tumor size. Grønning et al<sup>3</sup>

postulated steroid sensitivity rather than spontaneous recovery as the cause of tumor regression.

Tuberculosis and sarcoidosis are also steroid-responsive diseases<sup>9,10</sup> that could potentially have similar presentations with adrenal involvement. Glucocorticoid use in such cases could pose a diagnostic dilemma by delaying biopsy owing to shrinking tumors or obtaining suboptimal histologic analysis results.<sup>2,3</sup> Glucocorticoids are part of several chemotherapy regimens, and their effect on tumor size is thought to be multifactorial, including tumor sensitivity to glucocorticoids, which seems to be more evident for immature lymphoid cells.<sup>3</sup> Additionally, glucocorticoids have direct and indirect actions on gene transcription.<sup>3</sup>

The differential diagnosis of bilateral adrenal masses includes neoplasms, such as adenomas, lymphomas, metastases, bilateral pheochromocytomas, or adrenocortical carcinomas; macronodular adrenal hyperplasia; and infections, such as tuberculosis, histoplasmosis, and adrenal hemorrhage.<sup>11</sup> Spontaneous regression is often only seen in adrenal hemorrhage, as opposed to the other lesions.

The appearances of the adrenal lesions were indeterminate on initial trauma CT as well as on dedicated follow-up imaging. The initial reduction in size following even a small dose of glucocorticoids should make one consider lymphoma as we did not realize that a single dose of 1 mg of dexamethasone could cause such a dramatic reduction in adrenal tumor size.

## Conclusion

Adrenal lymphoma is rare and requires a high index of suspicion for its timely diagnosis. The diagnosis requires an adrenal biopsy, with histologic confirmation needed before initiation of appropriate chemotherapy. It is important to be aware of the potential

effect of glucocorticoid use on tumor regression, which could help make a timely diagnosis.

## Disclosure

The authors have no multiplicity of interest to disclose.

## References

1. Günaydin A, Er U, Acuduman A, Sabuncuoğlu H, Oztürk E. Diagnostic and surgical pitfalls of an unusual primary central nervous system lymphoma. *Turk Neurosurg.* 2007;17(2):129–133.
2. Farquhar D, Sobanko J, Williams K, Newman JG. A vanishing lymphoma in the cheek. *ORL J Otorhinolaryngol Relat Spec.* 2014;76(4):189–192.
3. Grønning K, Sharma A, Mastroianni MA, et al. Primary adrenal lymphoma as a cause of adrenal insufficiency, a report of two cases. *Endocrinol Diabetes Metab Case Rep.* 2020;19–0131.
4. Cronin J, Kennedy U, McCoy S, et al. Single dose oral dexamethasone versus multi-dose prednisolone in the treatment of acute exacerbations of asthma in children who attend the emergency department: study protocol for a randomized controlled trial. *Trials.* 2012;13(1):141.
5. Rashidi A, Fisher SI. Primary adrenal lymphoma: a systematic review. *Ann Hematol.* 2013;92(12):1583–1593.
6. Harada K, Kimura K, Iwamuro M, et al. The clinical and hormonal characteristics of primary adrenal lymphomas: the necessity of early detection of adrenal insufficiency. *Intern Med.* 2017;56(17):2261–2269.
7. Kim Y, Kim J, Min Y, et al. Prognostic factors in primary diffuse large B-cell lymphoma of adrenal gland treated with rituximab-CHOP chemotherapy from the Consortium for Improving Survival of Lymphoma (CISL). *J Hematol Oncol.* 2012;5(1):49.
8. Ohe M, Hashino S, Hattori A. Successful treatment of diffuse large B-cell lymphoma with clarithromycin and prednisolone. *Korean J Hematol.* 2012;47(4):293–297.
9. Cunha BA. Pulmonary tuberculosis and steroids. *Chest.* 1995;107(6):1486–1487.
10. Shijubo N. Corticosteroid treatment of pulmonary sarcoidosis. *Japanese Journal of Sarcoidosis and Other Granulomatous Disorders.* 2011;31(1):57–59.
11. Gupta P, Bhalla A, Sharma R. Bilateral adrenal lesions. *J Med Imaging Radiat Oncol.* 2012;56(6):636–645.