

Laparoscopic Adrenalectomy for Bilateral Metachronous Aldosteronomas

Philippe Rizek, MD, Piotr Gorecki, MD, Aristid Lindenmayer, MD, Sabita Moktan, MD

ABSTRACT

Introduction: Primary aldosteronism affects 5% to 13% of patients with hypertension. Idiopathic bilateral hyperplasia (IHA) and unilateral aldosterone-producing adenoma (APA) are the most common types of primary aldosteronism. Bilateral APA is a very rare entity with only a few reports in the literature. We present the case of a patient with metachronous bilateral APA treated with metachronous bilateral total and near total adrenalectomy.

Case Report: A 66-year-old female was evaluated for hypokalemia and hypertension refractory to medical therapy 2 years after laparoscopic adrenalectomy for right APA. Follow-up abdominal CT scan revealed a new 1.1-cm left adrenal mass. The patient underwent a laparoscopic near total adrenalectomy for her new left adrenal mass. Pathology examination revealed a new APA. The operation and the patient's postoperative course were uneventful. Potassium levels were normalized and her hypertension became well controlled.

Conclusion: APA can present metachronously months to years after adrenalectomy for APA in the contralateral adrenal gland. Laparoscopic adrenalectomy remains the approach of choice for this pathology.

Key Words: Conn's syndrome, Metachronous adenoma, Hypertension, Aldosterone-producing adenoma, Laparoscopic adrenalectomy.

INTRODUCTION

It is estimated that approximately 28.7% of the total US population are hypertensive.¹ The most common form of secondary hypertension is primary hyperaldosteronism, first described by Conn in 1955.² Primary aldosteronism has been shown to affect 5% to 13% of nonselected patients with hypertension.^{3,4} It is characterized by excess plasma aldosterone leading to suppression of renin levels, hypertension, and hypokalemia. Many patients will not be hypokalemic,⁵⁻⁸ and the plasma aldosterone concentration (PAC) to plasma renin activity (PRA) ratio is widely accepted as the screening test of choice for primary aldosteronism.^{4,9,10} Idiopathic bilateral hyperplasia (IHA) and aldosterone-producing adenoma (APA) are the most common subtypes of primary aldosteronism, comprising approximately 65% and 30% of cases, respectively.³ Less common subtypes of primary aldosteronism include unilateral hyperplasia in 3% of patients, aldosterone-producing adrenocortical carcinoma in 1% of patients and familial hyperaldosteronism in <1% of patients.⁴ Patients with APA tend to have more severe hypertension, more frequent hypokalemia, higher plasma (>25ng/dL) and urinary (>30μg/24h) levels of aldosterone, and are younger (<50 years old) than those with IHA.^{3,11,12} Initial testing should include CT scan imaging of the adrenal glands. Selective adrenal venous sampling is the most accurate method for distinguishing the difference between unilateral and bilateral adrenal aldosterone hypersecretion.^{4,13} Bilateral IHA may be treated pharmacologically with mineralocorticoid receptor antagonists; however, the optimal treatment for APA or unilateral hyperplasia involves surgical intervention.⁴ Laparoscopic adrenalectomy is regarded as the gold-standard therapy for benign lesions of the adrenal gland.¹⁴⁻¹⁸ Bilateral APA is an extremely rare entity with only a few reports in the literature.¹⁹⁻²¹ We describe the case of a patient with metachronous bilateral APAs with left APA identified 2 years after total adrenalectomy for right APA.

CASE REPORT

A 66-year-old woman was evaluated for recurrence of hypokalemia and poorly controlled hypertension. Two years before this presentation, she underwent a laparo-

Department of Surgery, New York Methodist Hospital, Brooklyn, New York, USA (Drs Rizek, Gorecki).

Department of Pathology, New York Methodist Hospital, Brooklyn, New York, USA (Dr Lindenmayer).

Department of Internal Medicine, New York Methodist Hospital, Brooklyn, New York, USA (Dr Moktan).

Address correspondence to: Piotr Gorecki, New York Methodist Hospital, Department of Surgery, 506 6th Street, Brooklyn, NY 11215, USA. Telephone: 718-7803288, Fax: 718-7803154, E-mail: pgorecki@pol.net

DOI: 10.4293/108680811X13071180407230

© 2011 by JSLS, *Journal of the Society of Laparoendoscopic Surgeons*. Published by the Society of Laparoendoscopic Surgeons, Inc.

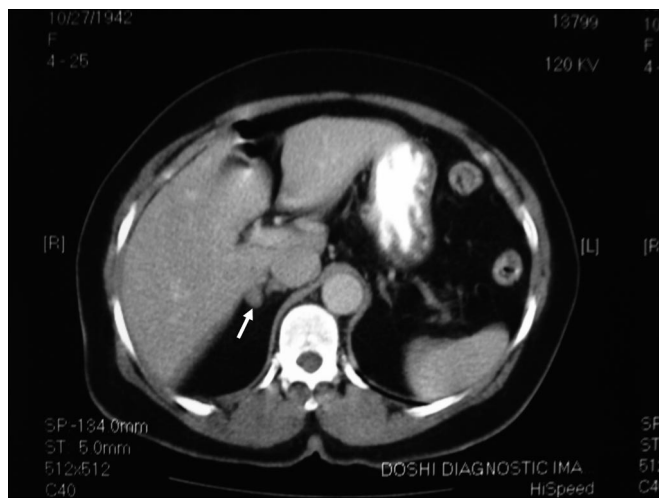


Figure 1. (A) CT of the abdomen with contrast demonstrates a 1-cm nodule in the right adrenal gland consistent with benign adenoma (arrow). **(B)** The same CT of the abdomen showing a normal left adrenal gland (arrow).

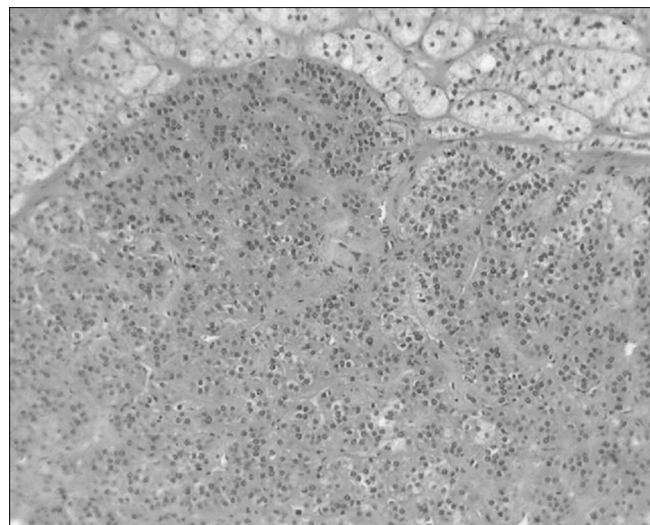


Figure 2. Histopathology (H&E, 100X) of right adrenal gland nodule after right adrenalectomy is consistent with APA.

scopic right adrenalectomy for a 1-cm hyperfunctioning right adrenal mass found on abdominal CT scan (**Figure 1A**) with a normal-appearing left adrenal gland (**Figure 1B**). The site of her hyperaldosteronism was confirmed with selective adrenal venous sampling to the right adrenal that corresponded to the right aldosterone-producing adenoma. Surgical pathology at the time revealed an adrenal cortical adenoma measuring 1cm x 1cm x 0.8cm consistent with aldosteronoma (**Figure 2**). The patient was discharged on the second postoperative day after an uneventful recovery. Her hypokalemia resolved, her blood pressure normalized on anti-hypertensive medications, and her aldosterone level returned to normal. Two years later, the patient developed signs of recurrent hyperaldosteronism with hypertension refractory to anti-hypertensive medication, hypokalemia as well as elevated aldosterone level and suppressed serum renin. Follow-up CT scan revealed radiological features of a new 1.1-cm left adrenal nodule (**Figure 3**) and absent adrenal gland on a right side consistent with a new contralateral hyperfunctioning left adrenal adenoma. Her blood pressure was 195/102mm Hg, plasma renin activity (PRA) was 0.24ng/mL/hr, plasma aldosterone concentration was 20.9ng/dL, and the PAC to PRA ratio was 87.08ng/dL per ng/mL/hour, consistent with second primary hyperaldosteronism. At this time, the patient underwent a laparoscopic left near total adrenalectomy for the new adrenal mass that was confirmed to be an adrenal cortical adenoma measuring 1cm x 0.7cm x 0.6cm (**Figure 4**). We defined a term near total adrenalectomy as a near total excision of the adrenal

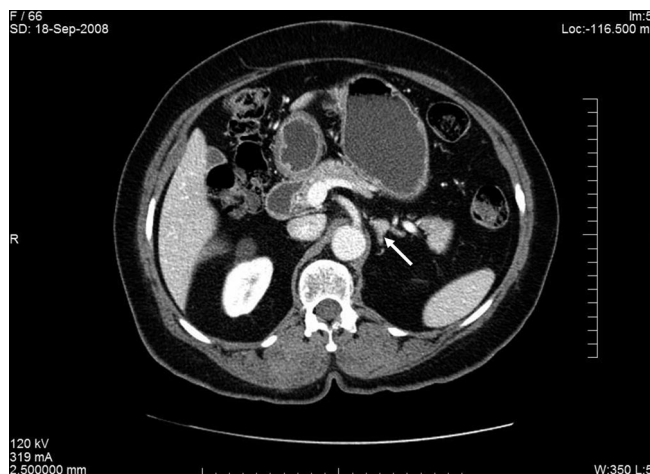


Figure 3. CT of the abdomen with contrast (2 years after right adrenalectomy) demonstrates a new 1.1-cm nodule with non-specific characteristics in the left adrenal gland consistent with benign adenoma (arrow).

gland containing an adenoma and most of the adjacent normal adrenal gland and leaving only a rim of normal adrenal tissue in the superior pole of the gland away from the adenoma. Postoperative serum examination revealed PAC of 3ng/dL and PRA of 0.30ng/mL/hr. **Figure 5** demonstrates changes in the patient's PAC over the course of 2 years. After initial normal levels of serum cortisol for the first 10 days postoperatively, the patient was advised by her endocrinologist to take 20mg of oral hydrocortisone twice daily and 0.25mg of fludrocortisone daily, which was later reduced to hydrocortisone 10mg in the morning

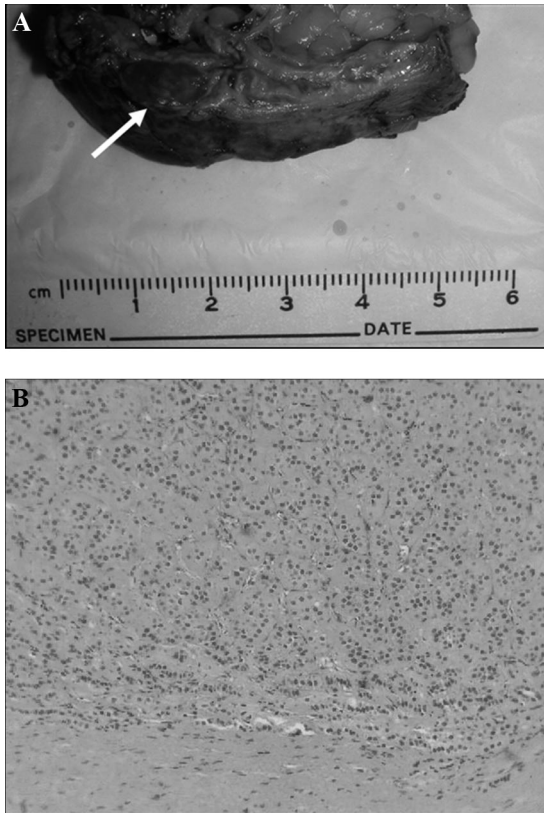


Figure 4. (A) Left adrenal gland with 1.1-cm nodule (arrow) that was identified as an APA after left adrenalectomy 2 years after right adrenalectomy for right APA. (B) Histopathology (H&E, 100X) of the specimen is consistent with APA.

and 5mg in the evening. She continued with the same dose of fludrocortisone. She subsequently continued to require hormone replacement therapy, and her ACTH levels were high and consistent with the primary adrenal insufficiency. This was most likely either the result of the insufficient mass of the remaining adrenal tissue that was left, or a secondary event leading to adrenal insufficiency. On a 2-year follow-up, the patient remains clinically well, her blood pressure is well controlled, potassium levels were normal, and potassium supplementation was discontinued. The patient continues to require hormone replacement therapy.

DISCUSSION

Adrenal masses occur bilaterally in 15% of adrenal incidentalomas. The differential diagnosis includes metastatic disease, congenital adrenal hyperplasia, lymphoma, infection (tuberculosis, fungal), hemorrhage, adrenocorticotropic hormone (ACTH)-dependent Cushing's syndrome,

pheochromocytoma, and infiltrative diseases, such as amyloidosis.²² Bilateral synchronous APA is a rare entity with few reports in the literature.^{19–21} Recognizing that most bilateral adrenal masses have been reported to be metastatic tumors, a retrospective study of 18 cases of bilateral adrenal masses by Zhou et al²¹ reported common causes to be pheochromocytoma, primary lymphoma, and non-functioning cortical adenoma, with only one case due to primary aldosteronism. We describe a rare case of metachronous adrenal APA 2 years following adrenalectomy of the contralateral APA. The review of the literature has identified only one paper (Chinese literature) reporting such cases.²⁰ Several features support our observation of this pathology not to be due to bilateral hyperplasia. First, there was a normal-appearing left adrenal gland on the initial CT scan and clearly demonstrated 1-cm nodule on a right adrenal gland. Second, the selective venous sampling localized the hyperfunctioning gland to the right. Finally, the pathology revealed adenomas in both cases and not hyperplasia.

Screening for primary hyperaldosteronism should be considered in a patient with hypertension and hypokalemia, resistant hypertension, finding of an adrenal incidentaloma on CT or MRI and hypertension, or whenever considering secondary hypertension. Screening can be accomplished by a morning blood sample in a seated ambulatory patient for PAC and PRA with a PAC to PRA ratio ≥ 20 ng/dL per ng/mL/hr and PAC ≥ 15 ng/dL with subsequent investigation of primary aldosteronism.^{3,23} Selective adrenal venous sampling is the most accurate method for determining the site of aldosterone overproduction^{4,13} or when CT scan is equivocal to avoid wrong-site adrenalectomy.²⁴ A gradient of aldosterone to cortisol ratio of more than 4 between the left and right adrenal vein is consistent with unilateral aldosterone excess and indicates the presence of an APA, or, infrequently, unilateral hyperplasia or aldosterone-producing carcinoma.¹³ Our patient presented with hypertension refractory to medical treatment 2 years after her first adrenalectomy for right APA. The increase in her PAC and decrease in PRA, and more importantly the PAC to PRA ratio of 87.08ng/dL per ng/mL/hour along with the new left-sided nodule confirmed on CT scan was consistent with new metachronous APA.

Laparoscopic adrenalectomy is regarded as the gold standard for benign lesions < 6 cm of the adrenal gland. It is less invasive with minor operative blood loss, a lower analgesic requirement, earlier oral intake, better cosmesis, lower morbidity, and faster recovery.^{14–18} Simultaneous adrenalectomy has also been shown to be safe and effec-

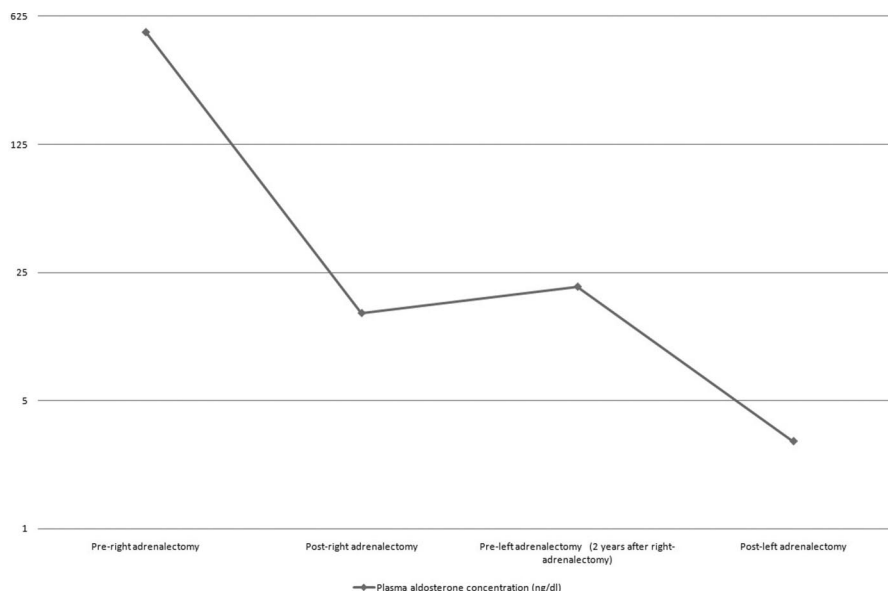


Figure 5. Plasma aldosterone concentration (PAC) before and after right adrenalectomy, and 2 years after right adrenalectomy. An increase in PAC was evident 2 years after right adrenalectomy; the patient subsequently underwent left adrenalectomy for left APA, and postoperative PAC returned to normal.

tive in treating cases of bilateral Cushing’s syndrome and pheochromocytoma.^{18,25} One study describes a rare case of recurring APA 9 years postadenomectomy, in which the authors concluded in that case that enucleation may not be adequate therapy for patients with APA, and a completion adrenalectomy of the affected adrenal gland cured this patient of the recurrent disease.²⁶ There are no data comparing enucleation or near total adrenalectomy with a total adrenalectomy as a treatment for hyperfunctioning adenomas. Fortunately, this clinical dilemma is not pertinent to the overwhelming majority of clinical situations, because bilateral aldosterone-producing adenomas are exceptionally rare; therefore, at the present time such a study is impossible to conduct. In addition, we postulate that near-total adrenalectomy is a different procedure than enucleation of the adenoma. In the presented case, we excised the adenoma with at least a 1-cm margin of the adjacent normal gland, leaving only a rim of normal adrenal tissue in the superior pole of the gland. This clinical decision was based on the presumption that the remaining normal adrenal tissue may offer some protection for the patient if lost to follow-up or other adverse events. We suggest that, weighing overall risks and benefits, to preserve some adrenal function, a near-total adrenalectomy of the contralateral gland may be considered in such cases. Long-term follow-up of this patient and possibly future similar case series may only be able to address this clinical issue in a more methodological way.

In the majority of patients with surgically managed APA, control of blood pressure improves, and serum potassium levels normalize. Between 33% and 73% will become normotensive without the aid of antihypertensive medications.^{13,27–29} Some cases have demonstrated persistent hyperaldosteronism after adrenalectomy.³⁰ In the presented case, the patient underwent bilateral metachronous laparoscopic adrenalectomy, total on the right and near total on the left. This patient experienced resolution of hypokalemia and, on follow-up, her hypertension was well-controlled.

CONCLUSION

Although very rare, APA can present metachronously months to years after total adrenalectomy for APA in the contralateral adrenal gland. More studies are needed to determine the optimal surgical management in this rare clinical scenario.

References:

- Hajjar I, Kotchen TA. Trends in prevalence, awareness, treatment, and control of hypertension in the United States, 1988–2000. *JAMA*. 2003;290(2):199–206.
- Conn JW. Presidential address. I. Painting background. II. Primary aldosteronism, a new clinical syndrome. *J Lab Clin Med*. 1955;45(1):3–17.

3. Young WF Jr. Minireview: primary aldosteronism—changing concepts in diagnosis and treatment. *Endocrinology*. 2003;144(6):2208–2213.
4. Mattsson C, Young WF Jr. Primary aldosteronism: diagnostic and treatment strategies. *Nat Clin Pract Nephrol*. 2006;2(4):198–208.
5. Gordon RD, Stowasser M, Tunny TJ, Klemm SA, Rutherford JC. High incidence of primary aldosteronism in 199 patients referred with hypertension. *Clin Exp Pharmacol Physiol*. 1994;21(4):315–318.
6. Benchetrit S, Bernheim J, Podjarny E. Normokalemic hyperaldosteronism in patients with resistant hypertension. *Isr Med Assoc J*. 2002;4(1):17–20.
7. Bernini G, Moretti A, Argenio G, Salvetti A. Primary aldosteronism in normokalemic patients with adrenal incidentalomas. *Eur J Endocrinol*. 2002;146(4):523–529.
8. Shargorodsky M, Zimlichman R. Primary aldosteronism: the most frequent form of secondary hypertension? *Isr Med Assoc J*. 2002;4(1):32–33.
9. Young WF Jr. Primary aldosteronism: A common and curable form of hypertension. *Cardiol Rev*. 1999;7(4):207–214.
10. Stowasser M, Gordon RD, Rutherford JC, Nikwan NZ, Daunt N, Slater GJ. Diagnosis and management of primary aldosteronism. *J Renin Angiotensin Aldosterone Syst*. 2001;2(3):156–169.
11. Young WF Jr., Hogan MJ, Klee GG, Grant CS, van Heerden JA. Primary aldosteronism: diagnosis and treatment. *Mayo Clin Proc*. 1990;65(1):96–110.
12. Blumenfeld JD, Sealey JE, Schlüssel Y, et al. Diagnosis and treatment of primary hyperaldosteronism. *Ann Intern Med*. 1994;121(11):877–885.
13. Young WF, Stanson AW, Thompson GB, Grant CS, Farley DR, van Heerden JA. Role for adrenal venous sampling in primary aldosteronism. *Surgery*. 2004;136(6):1227–1235.
14. Bjornsson B, Birgisson G, Oddsdottir M. Laparoscopic adrenalectomies: A nationwide single-surgeon experience. *Surg Endosc*. 2008;22(3):622–626.
15. Gagner M, Pomp A, Heniford BT, Pharand D, Lacroix A. Laparoscopic adrenalectomy: lessons learned from 100 consecutive procedures. *Ann Surg*. 1997;226(3):238–246.
16. MacGillivray DC, Shichman SJ, Ferrer FA, Malchoff CD. A comparison of open vs laparoscopic adrenalectomy. *Surg Endosc*. 1996;10(10):987–990.
17. Kebebew E, Siperstein AE, Duh QY. Laparoscopic adrenalectomy: the optimal surgical approach. *J Laparosc Adv Surg Tech A*. 2001;11(6):409–413.
18. Pugliese R, Boniardi M, de Carli S, et al. Laparoscopic bilateral simultaneous adrenalectomy: results of 11 operations. *J Laparosc Adv Surg Tech A*. 2008;18(4):588–592.
19. Chung SD, Huang KH, Yu HJ, Wu KD, Chueh SC. Diagnosis of bilateral aldosterone-producing adenomas. *Kidney Int*. 2007;72(2):228.
20. Yu XY, Kong CZ, Li ZH, et al. [Study on multiple aldosterone-producing adenomas] *Zhonghua Wai Ke Za Zhi*. 2007;45(24):1701–1703. Chinese.
21. Zhou J, Ye D, Wu M, et al. Bilateral adrenal tumor: causes and clinical features in eighteen cases. *Int Urol Nephrol*. 2009;41(3):547–551.
22. Young WF Jr. Management approaches to adrenal incidentalomas. A view from Rochester, Minnesota. *Endocrinol Metab Clin North Am*. 2000;29(1):159–185.
23. Handler J. Hypertension associated with large bilateral adrenal masses. *J Clin Hypertens (Greenwich)*. 2007;9(7):572–575.
24. Toniato A, Bernante P, Rossi GP, Pelizzo MR. The role of adrenal venous sampling in the surgical management of primary aldosteronism. *World J Surg*. 2006;30(4):624–627.
25. Takata MC, Kebebew E, Clark OH, Duh QY. Laparoscopic bilateral adrenalectomy: results for 30 consecutive cases. *Surg Endosc*. 2008;22(1):202–207.
26. Calvo-Romero JM, Ramos-Salado JL. Recurrence of adrenal aldosterone-producing adenoma. *Postgrad Med J*. 2000;76(893):160–161.
27. Sywak M, Pasiaka JL. Long-term follow-up and cost benefit of adrenalectomy in patients with primary hyperaldosteronism. *Br J Surg*. 2002;89(12):1587–1593.
28. Meyer A, Brabant G, Behrend M. Long-term follow-up after adrenalectomy for primary aldosteronism. *World J Surg*. 2005;29(2):155–159.
29. Lumachi F, Ermani M, Basso SM, Armanini D, Iacobone M, Favia G. Long-term results of adrenalectomy in patients with aldosterone-producing adenomas: multivariate analysis of factors affecting unresolved hypertension and review of the literature. *Am Surg*. 2005;71(10):864–869.
30. Fendrich V, Ramaswamy A, Nies C. Hyperaldosteronism persisting after subtotal adrenalectomy [in German]. *Chirurg*. 2003;74(5):473–477.