



Tehran University of Medical  
Sciences Publication  
<http://tums.ac.ir>

## Iran J Parasitol

Open access Journal at  
<http://ijpa.tums.ac.ir>



Iranian Society of Parasitology  
<http://isp.tums.ac.ir>

### Short Communication

## Wound Myiasis in Diabetic Foot Ulcer: Calliphoridae and Sarcophagidae Family

\*Evren Tileklioğlu<sup>1</sup>, İbrahim Yildiz<sup>1</sup>, Fürüzan Bozkurt Kozan<sup>2</sup>, Erdoğan Malatyali<sup>1</sup>,  
Mustafa Bülent Ertuğrul<sup>3</sup>, Hatice Ertabaklar<sup>1</sup>

1. Department of Parasitology, Faculty of Medicine, Aydın Adnan Menderes University, Aydın, Turkey
2. Nazlı-Selim Eren Chronic Wounds and Infections Care Unit, Faculty of Medicine, Aydın Adnan Menderes University, Aydın, Turkey
3. Department of Infectious Diseases and Clinical Microbiology, Aydın Adnan Menderes University School of Medicine, Aydın, Turkey

Received 18 Mar 2021

Accepted 14 Jun 2021

#### **Keywords:**

Myiasis; Wound;  
Diabetic foot;  
Calliphoridae;  
Sarcophagidae

#### **\*Correspondence**

##### **Email:**

[etileklioglu@gmail.com](mailto:etileklioglu@gmail.com)

#### **Abstract**

**Background:** Myiasis is a parasitic infestation of tissues or body cavities of mammals with dipterous larvae. The patients with diabetic foot ulcers are more vulnerable to acquiring infestation; however, the infestation may be neglected and mistreated in some cases.

**Methods:** Data were collected of twelve myiasis cases with diabetic foot ulcers in Nazlı-Selim Eren Chronic Wound and Infections Care Unit, Aydın, Turkey between 2017 and 2019. Demographic, clinical characteristics of the patients and clinical examination of the wound were recorded. To morphology-based identification method of the agents, the developmental stages of the maggots were examined.

**Results:** The cases aged between 46 and 81 years (10 males, two females). Eight of the larvae collected from wounds had Calliphoridae and four had Sarcophagidae family. The larvae were infested right/left foot sole, thumb, ankle, and mostly left toes. The number of larvae collected from the cases ranged from 2 to 48. Third-stage larvae (L3) were mostly detected. Mixed (L1-L2, L2-L3) larvae were detected in a patient. The infestations were more common in July and August. According to the score of Infectious Diseases Society of America (IDSA), ten (83%) cases had moderate and two (17%) cases were mild diabetic foot infections (DFIs).

**Conclusion:** Diabetic foot ulcers should be evaluated in terms of myiasis. This was the first study in our province indicating that myiasis should not be neglected and different species of flies were responsible for myiasis cases.



## Introduction

Myiasis is an ectoparasitic infection caused by the larvae or maggots of true flies (Diptera). The species of *Calliphoridae*, *Sarcophagidae*, *Oestridae*, *Muscidae*, and *Hypodermatidae* are responsible for human myiasis (1). The infection is much prevalent in tropical and subtropical regions of the world because the climatic potentials prepare suitable breeding places for flies. The flies are mostly found in urban areas where sanitation, inadequate garbage disposal and animal husbandry are suitable for the development of the larvae (2). The predisposing factors for the flies include the following: Psychological disorders, low socioeconomic status, advanced age, poor hygiene conditions, vascular disorders, necrosis, open or wounds and especially neuropathic ulcers (diabetic foot ulcer) (3). In foot ulcers are the presence of a break in the skin of the foot in a person with diabetes, which does not promptly heal. These cases are a leading cause of hospitalization, amputation, reduced mobility, loss of social inclusion, and poor quality of life (4).

Myiasis can be divided into seven categories according to anatomical region and biology of the parasitic species by the WHO, ICD-10 classification (5). Cutaneous myiasis occurs when adult flies infest the wounds by laying host's open wounds. The larvae (L1) develop to the third instar (L3) in a short time, cause new wounds and invade the dermal layers in the surrounding healthy tissue for feed on the host's living/dead tissue, body fluids, or in-

gested food as a source of nutrition. After penetration, they cause deep irritation and can lead to cartilage or bone loss (6,7). Therefore, the infestation can be life threatening in non-healing wounds with diabetic foot ulcers and it may lead to significant tissue damage if the larvae invade the central nervous system. As a key for diagnosis is the identification of the larvae in tissues or organs. The management of myiasis usually consists of three stages; mechanical removal of the larvae, surgical debridement of the infested wound tissue and irrigation of the wound with antiseptic solutions (8,9). In addition, topical and oral ivermectin is successfully used for the removal of the larvae (10).

The prevention of re-infestation and the spread of larvae are important of underlying conditions in the treatment of disease. Here, we report, for the first time, myiasis infestation of twelve patients with diabetic foot ulcers from a wound care unit in Aydın Province of Turkey on the Western Coast.

## Materials & Methods

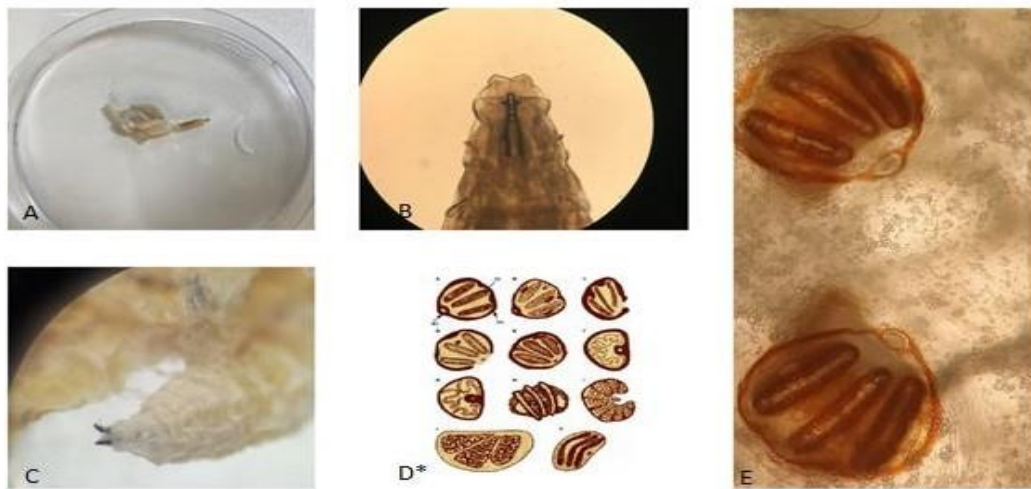
The present study included twelve myiasis cases with diabetic foot ulcers in Nazli-Selim Eren Chronic Wound and Infections Care Unit, Aydın, Turkey between 2017 and 2019. Demographic, clinical characteristics of the patients and clinical examination of the wound were recorded (Fig. 1).

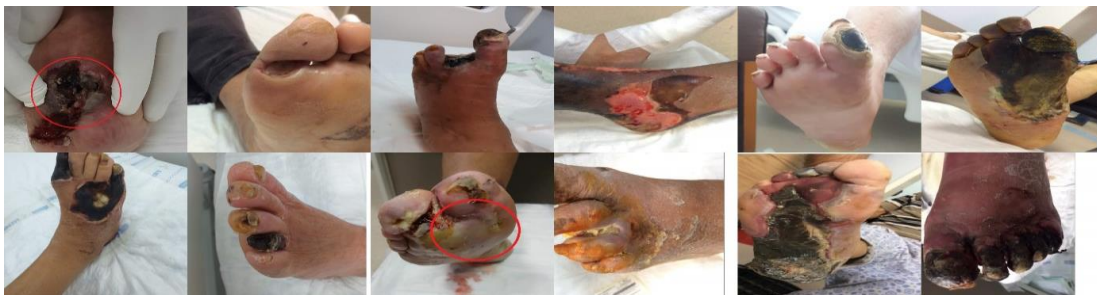


Fig. 1: Twelve myiasis cases with diabetic foot ulcers

The wounds were examined and the larvae were removed with sterile tweezers and were cleaned with saline (0.9% sodium chloride). The wound debridement therapy was performed at the bedside in consecutive sessions. The wound bed was washed with hypochlorous acid (HOCl) (11). Myiasis larvae were sent to the parasitology department in the same hospital for entomological identification. To morphology-based identification method of the agents, the developmental stages of the maggots were examined by macroscopically and microscopically (shape of the mouth-

pharynx skeleton, the number of structures and spiracles of the anterior and posterior stigmas) (Fig. 2) (12). The dead maggots were stored in 70% alcohol or 10% formalin for identification. Alive maggots were placed in a chicken liver and stored at room temperature until they reached to next stages (pupae and adult fly) (Fig. 3). The maggots were fed on chicken liver, and then were placed on wood shavings to complete the pupal period. Finally, adult flies were obtained from the pupae. All developmental stages of the larvae were examined for entomological identification (Fig. 4).



**Fig. 2:** Larvae were identified as macro and microscopically. (A) Third-stage of larvae, (B) cephaloskeleton of third-stage larvae of *Calliphora* spp, (C) anterior view of mouth-pharynx, (D) identification key of posterior spiracles of the third-instar larvae of myiasis, (E) posterior spiracles of *Calliphora* spp. (Original photos)  
\*The twelfth source is cited.



**Fig. 3:** Development stages of the larvae. (A) Larvae were placed in a chicken liver, (B) wood shavings for pupal period, (C) stage of pupa obtained from the larvae, (D) adult fly. (Original photos)



**Fig. 4:** Adult form of *Calliphora* spp.(A), stage of pupa of *Calliphora* spp. (B), stage of pupa of *Sarcophaga* spp. (C), adult form of *Sarcophaga* spp. (D) were identified as macro- and microscopically. (Original photos)

### **Ethics Committee Approval**

The research protocol was approved by Aydin Adnan Menderes University Faculty of Medicine, Non-Interventional Clinical Trials Ethics Committee (Protocol No: 2019/190).

### **Results**

The cases aged between 46 and 81 years and all had diabetic foot ulcers. The great majority (n=10, 83%) of patients were male and two were female. All cases were in close contact with animals (income from animal husbandry) except one patient. The larvae were infested in

the different body regions (right/left foot sole, thumb, ankle) mostly left toes. The number of larvae collected from the cases ranged from 2 to 48 and L3 larvae were the dominantly detected stage. In addition, L2 and mixed (L1-L2, L2-L3) larvae were detected in a patient. The infestations were more common in July and August. The demographic and clinical characteristics of patients were presented in Table 1. According to the score of Infectious Diseases Society of America (IDSA), ten (83%) cases had moderate and two (17%) cases were mild diabetic foot infections (DFIs).

**Table 1.** Features of the cases and myiasis agents

<i>Cases</i>	<i>Gender</i>	<i>Age</i>	<i>Infestation month</i>	<i>Localities</i>	<i>Anatomical localization</i>	<i>Maggots obtained from the wound</i>	<i>Larval stages</i>	<i>Fly spp. identification</i>	<i>Animal husbandry</i>	<i>Necrosis</i>	<i>IDSAs Infection Severity</i>	<i>Bedridden</i>
1	Female	48	August	Germencik, Aydin	Left Toes	25	3	Sarcophagidae	+	+	Moderate	+
2	Male	60	April	Efeler, Aydin	Left Toes	36	3	Sarcophagidae	+	+	Moderate	+
3	Male	62	August	Germencik, Aydin	Left foot	6	2	Calliphoridae	+	+	Moderate	-
4	Male	65	August	Nazilli, Aydin	Left Toes	48	2	Calliphoridae	+	+	Moderate	+
5	Male	67	August	Kuyucak, Aydin	Right foot sole	3	1-2	Calliphoridae	+	+	Moderate	-
6	Female	55	October	Efeler, Aydin	Right foot thumb	4	3	Calliphoridae	-	+	Mild	-
7	Male	71	July	Efeler, Aydin	Right foot sole	2	3	Calliphoridae	+	+	Moderate	-
8	Male	74	March	Söke, Aydin	Right ankle	2	2	Sarcophagidae	+	+	Moderate	+
9	Male	72	August	Germencik, Aydin	Right foot	4	2-3	Calliphoridae	+	+	Moderate	-
10	Male	58	May	Söke, Aydin	Right foot thumb	3	3	Calliphoridae	+	+	Mild	-
11	Male	67	July	Bozdoğan, Aydin	Left Toes	18	3	Calliphoridae	+	+	Moderate	+
12	Male	81	July	Söke, Aydin	Left Toes	7	2-3	Sarcophagidae	+	+	Moderate	-

## Discussion

Myiasis is an ectoparasitic disease that causes serious health problems including loss of labour force and disruption in physical appearance (13). Clinically, the infestation is classified according to the anatomical position: Cutaneous which is the most common clinical form, oral, nasal, ocular, gastrointestinal, and genitourinary myiasis (14). Human infestations are rare, but the larvae can go through the

deeper layers of the skin (the dermis), and cause a serious clinical outcome due to loss of limb, depending on the facultative or obligatory nature (15,16).

It was reported that metabolic and systemic diseases such as diabetes mellitus increased the severity of infestation (17). In addition, because of peripheral neuropathy and pain loss, diabetic cases are considered a major risk group for the disease (18). The flies are attracted by alkali wastes and necrosis in diabetic foot ulceration and it was stated that a mi-

nor wound or an abrasion on the skin is enough for laying the eggs (19).

Many cases of myiasis are reported from other countries. Zagloul et al, detected a *Sarcophaga* spp. larvae in a wound on the shoulder of a 40-year-old diabetic patient living in the rural area. The open and neglected wound in this patient with uncontrolled diabetes covered the way for the development of myiasis (20). A 62-year-old woman who suffered from diabetes and anemia was infested by 50 *Lucilia sericata* (belong to Calliphoridae family) larvae. The researcher stated that myiasis could be a risk for elderly and seriously ill people (21).

Despite a number of studies from other countries, there are a few reports of cutaneous myiasis in diabetic foot ulcers from Turkey (22-24). Eighteen case series with diabetic foot infection caused by the *Calliphora* spp. larvae (25). A case of *Sarcophaga* spp. in diabetic case was reported by Demirel Kaya et al (26).

Calliphoridae family was the most frequent agent of myiasis in Turkey (27-29). However, no data was presented from Aydin, in the southwest of the Turkey. Here we reported for the first time twelve-myiasis cases with diabetic foot ulcers.

It is important that myiasis must be diagnosed as early as possible in diabetic patients. The diagnosis of the infestation links to an appropriate history of patients and clinical examination. Because of the relatively short stages, identification of the flies can be difficult. For the entomological identification of the larvae, a few methods were reported (30, 31). In the present study, in order to better identification of the larvae, we used chicken liver and wood shavings to metamorphosis into adults. In addition, we detected all stages of the larvae collected from the patients: four of Calliphoridae and eight of the Sarcophagidae family.

Diabetic foot ulceration is the most frequent clinical manifestation in diabetic cases. The ulceration can be cured; unfortunately, many cases unnecessarily undergo amputations be-

cause of inadequate diagnosis and therapy. Clinically by the manifestation of inflammation (redness, warmth, swelling, tenderness or pain) or purulence in foot wounds should be classified by severity (32). Diabetic foot infections were classified as moderate in ten (83%) of the cases and mild in two (17%) cases.

Cutaneous myiasis has worldwide distribution and more frequent in summer. However, certain species are also responsible for infestations in winter (33). In our study, Calliphoridae and Sarcophagidae were more dominant in July and August.

It was reported that wound myiasis was common in rural areas where the people had close contact with livestock animals (34). In accordance with the literature, the great majority of our cases (11 out of 12) live in rural areas and work in animal husbandry sector. A correlation between the frequency of myiasis and increased age was proposed in previous studies (35, 36).

In the present study, the elderly cases with foot ulcers were predominantly acquired myiasis. Previous studies have emphasized in this subject and indicated that these cases have a lack of appropriate home care, severe neurological underlying diseases, debilitated, or diabetes like our cases. (37, 38). Five of our diabetic cases were bedridden and lived alone. Therefore, in our cases have developed ulcers due to the delayed diagnosis and treatment. However, in a study stated that myiasis occurs not only in the elderly but also in the young or children (39).

Open wounds, necrosis, or ulcers may not be clinical manifestations of myiasis. In a study reported that cutaneous superficial myiasis caused by *Sarcophaga* larvae in the absence of skin ulceration or necrosis in a geriatric patient with limited motor and neurological capacity who lives in a nursing home. The researchers emphasized that myiasis should be considered even if the patients had no significant destruction in skin/tissue integrity (40).

## Conclusion

Our results of this study clearly indicated that people with diabetic foot ulcers should be evaluated in terms of myiasis. This was the first study in our province indicating that myiasis should not be neglected and different species of flies were responsible for myiasis cases.

## Acknowledgements

No financial support was revived.

## Conflict of interest

The authors declare that there is no conflict of interests.

## References

1. Manickam A, Sengupta S, Saha J, et al. Myiasis of the tracheostomy wound: A case report with review of literature. *Otolaryngology*. 2015; 5(4): 198.
2. Francesconi F, Lupi O. Myiasis. *Clin Microbiol Rev*. 2012;25(1):79-105.
3. Singh A, Singh Z. Incidence of myiasis among humans-a review. *Parasitol Res*. 2015; 114(9):3183-99.
4. Bowering CK. Diabetic foot ulcers. Pathophysiology, assessment, and therapy. *Can Fam Physician*. 2001; 47(5): 1007-16.
5. World Health Organization: History of the Development of the ICD. <https://icd.who.int/browse10/2019/en#/B87>
6. Hoyer P, WilliamsRR, Lopez M, et al. Human nasal myiasis caused by *Oestrus ovis* in the highlands of Cusco, Peru: report of a case and review of the literature. *Case Rep Infect Dis*. 2016;2016:2456735.
7. de Arruda JAA, de Oliveira Silva LV, Silva PUJ, et al. Head and neck myiasis: a case series and review of the literature. *Oral Surg Oral Med Oral Pathol Oral Radiol*. 2017; 124(5): e249-e256.
8. Pierre-filho PDTP, Minguini N, Pierre LM, et al. Use of ivermectin in the treatment of orbital myiasis caused by *Cochliomyia hominivorax*. *Scand J Infect Dis*. 2004;36(6-7):503-5.
9. Sherman RA. Maggot therapy for foot and leg wounds. *Int J Low Extrem Wounds*. 2002;1(2):135-42.
10. Osorio J, Moncada L, Molano A, et al. Role of ivermectin in the treatment of severe orbital myiasis due to *Cochliomyia hominivorax*. *Clin Infect Dis*. 2006;43(6):e57-9.
11. Sakarya S, Gunay N, Karakulak M, et al. Hypochlorous acid: an ideal wound care agent with powerful microbicidal, antibiofilm, and wound healing potency. *Wounds*. 2014; 26(12): 342-50.
12. Mathison BA, Pritt BS. Laboratory identification of arthropod ectoparasites. *Clin Microbiol Rev*. 2014;27(1):48-67.
13. Solomon M, Lachish T, Schwartz E. Cutaneous Myiasis. *Curr infect Dis Rep*. 2016;18(9):28.
14. Goddard J. Physician's Guide to Arthropods of Medical Importance: Flies whose maggots cause myiasis in humans 2nd ed. Florida, CRC Press: 1996: 169-187.
15. Robbins K, Khachemoune A. Cutaneous myiasis: a review of the common types of myiasis. *Int J Dermatol*. 2010;49(10):1092-8.
16. Hosni EM, Kenawy MA, Nasser MG, et al. A Brief Review of Myiasis with Special Notes on the Blow Flies' Producing Myiasis (F.: Calliphoridae). *Acad J Biol Sci A Entomol*. 2019;11(2):25-32.
17. Wang X, Ota N, Manzanillo P, et al. Interleukin-22 alleviates metabolic disorders and restores mucosal immunity in diabetes. *Nature*. 2014;514(7521):237-241.
18. Olea MS, Centeno N, Aybar CAV, et al. First report of myiasis caused by *Cochliomyia hominivorax* (Diptera: Calliphoridae) in a diabetic foot ulcer patient in Argentina. *Korean J Parasitol*. 2014;52(1):89-92.
19. Singh A, Singh D. Wound myiasis due to *Chrysomya bezziana* (Diptera: Calliphoridae) in patients of diabetic foot. *J Entomol Res Soc*. 2006;30(4):367-369.
20. Zagloul DAM, Tayeb K, Khodari YAW, et al. First case report of human myiasis with *Sarcophaga* species in Makkah city in the wound

- of a diabetic patient. J Nat Sc Biol Med. 2013;4(1):225-228.
21. Roozbehani M, Shamseddin J, Moradi M, et al. Myiasis of Mandible Due to *Lucilia sericata*, in Diabetic Woman Patient: A Case Report. Arch Clin Infect Dis. 2019;14(1): e59824.
  22. Şenel E, Uslu A, Taylan Özkan HA. Interdigital Myiasis Caused by *Lucilia sericata* in a Diabetic Patient. Flora. 2016; 21(1):131-133.
  23. Gödekmerdan A, Kaplan M, Burma S, et al. Diabetli bir hastada saptanan eksternal miyazis: Olgu sunusu. Türkiye Parazitoloji Dergisi. 2001; 25(1): 72-74.
  24. Polat E, Ağgez H. Larva Debridman Tedavisi İçin Gelen Bir Hastada Görülen Miyaz Olgusu. Türkiye Parazitol Derg. 2018; 42(3): 229-232.
  25. Uysal S, Ozturk AM, Tasbakan M, et al. Human myiasis in patients with diabetic foot: 18 cases. Ann Saudi Med. 2018;38(3):208-213.
  26. Demirel Kaya F, Orkun O, Cakmak A, et al. [Cutaneous myiasis caused by *Sarcophaga* spp. larvae in a diabetic patient]. Mikrobiyol Bul. 2014; 48(2):356-61.
  27. Kılıç K, Arslan MÖ, Kara M. [A postoperative wound myiasis caused by *Lucilia sericata* (Diptera: Calliphoridae) in a woman in Kars]. Türkiye Parazitol Derg. 2011; 35(1): 43-46.
  28. Karakuş M, Ünver A, Turgay N, et al. Ege Üniversitesi Hastanesi'nde yatmakta olan bir hastada nazal miyaz. Ege Tıp Dergisi. 2015; 54(1): 36-38.
  29. Balcıoğlu IC, Ecemiş T, Ayer A, et al. Subungual myiasis in a woman with psychiatric disturbance. Parasitol Int. 2008; 57(4):509-11.
  30. Stevens JR, Wallman JF, Otranto D, et al. The evolution of myiasis in humans and other animals in the Old and New Worlds (part II): biological and life-history studies. Trends Parasitol. 2006; 22(4):181-8.
  31. Service M. Flies and myiasis. In Medical Entomology for Students. Cambridge: Cambridge University Press; 2008. p. 151-67.
  32. Lipsky BA, Berendt AR, Cornia PB, et al. Infectious Diseases Society of America clinical practice guideline for the diagnosis and treatment of diabetic foot infections. Clin Infect Dis. 2012; 54(12):e132-e73.
  33. Baird JK, Baird CR, Sabrosky CW. North American cuterebrid myiasis: report of seventeen new infections of human beings and review of the disease. J Am Acad Dermatol. 1989; 21(4 Pt 1):763-72.
  34. Gour S, Kumar V, Thapliyal G, Nalini N. An Update on Cutaneous Myiasis: A Review. Rev Artic Saudi J Oral Dent Res. 2017; 2:31-37.
  35. Villwock JA, Harris TM. Head and neck myiasis, cutaneous malignancy, and infection: a case series and review of the literature. J Emerg Med. 2014; 47(2): e37-41.
  36. Zhou X, Kambalame DM, Zhou S, et al. Human *Chrysomya bezziana* myiasis: A systematic review. PLoS Negl Trop Dis. 2019; 13(10): e0007391.
  37. Shilpakar O, Karki B, Rajbhandari B. (2020). Cutaneous myiasis in a neglected elderly. Oxf Med Case Reports. 2020(8): omaa063.
  38. Dueñas Moreira O, Gámez Sánchez D, González Guerra QM. Cutaneous myiasis in an elderly from an ecuatorian rural community. Medi San. 2017; 21(05): 590-594.
  39. Boscarelli A, Sandri GBL. Periungual myiasis caused by *Wohlfahrtia magnifica* mimicking an ingrown toenail. Transl Pediatr. 2016; 5(2):95-6.
  40. Dutto M, Bertero M. Cutaneous superficial myiasis: report of a rare nosocomial parasitic disease caused by *Sarcophaga* spp. (Diptera, Sarcophagidae). Cent Eur J Public Health. 2011; 19(4):232-4.