

Mitral Valve Repair in Infective Endocarditis during Pregnancy

Abstract

Infective endocarditis (IE) during pregnancy and subsequent cardiac surgery are rare and associated with a high risk of mortality for the mother and fetus. It is difficult to determine the right time for cardiac intervention when IE is diagnosed early in pregnancy. A 33-year-old previously healthy woman in the 11th week of pregnancy was diagnosed with IE and underwent surgical intervention. The cardiopulmonary bypass settings and the anesthetic drugs were carefully chosen. Although she was in good health, while being discharged, the fetus did not survive. Anesthesiologists prioritizing the mother's survival should aim to improve fetal outcomes in such cases.

Keywords: Anesthetic agents, cardiac surgery, cardiopulmonary bypass, early gestation week, infective endocarditis, pregnancy

Introduction

Cases of infective endocarditis (IE) during pregnancy and subsequent cardiac surgery with cardiopulmonary bypass (CPB) for the treatment of this condition are rare and are associated with a high risk of mortality for the mother and fetus.^[1] Due to the high risk, it is difficult to determine the most appropriate time for cardiac intervention when IE is diagnosed early in pregnancy. Multidisciplinary planning of treatment strategies is required during the perioperative period because of the complexity of these cases. The management strategies employed for patients in the early stages of pregnancy remain controversial. We report a case involving a 33-year-old woman diagnosed with active methicillin-sensitive *Staphylococcus aureus* (MSSA) mitral valve acute bacterial endocarditis during the 11th week of gestation, who underwent mitral valve plasty.

Case Report

This case report was approved by the review board of Japanese Red Cross Nagoya Daiichi Hospital; informed consent was obtained from the patient. A 33-year-old previously healthy woman in the 11th week of pregnancy presented with high fever and lower back pain and was admitted for intravenous antibiotic treatment for pyelonephritis. Her platelet

count decreased daily [Table 1]. Two days after admission, she was transferred to our intensive care unit after being diagnosed with disseminated intravascular coagulation with sepsis. Her body temperature was 40°C, and tachycardia and systolic murmur were observed. Transthoracic echocardiography (TTE) revealed severe mitral valve regurgitation (MR) without vegetation. Three sets of blood cultures performed within 24 h of admission grew MSSA. Intravenous gentamicin (a single dose of 3 mg/kg/day) and intravenous teicoplanin (800 mg once a day) were administered for the treatment of IE.^[2] Recombinant human soluble thrombomodulin was not used because of the risk of vaginal bleeding and the reported risk of maternal and fetal death.^[3] Initially, the patient's laboratory data for inflammatory markers showed gradual improvement [Table 1], but her clinical condition worsened abruptly on hospital day 8. High-dose diuretic and inotropic support and noninvasive positive pressure ventilation were necessary to reestablish hemodynamic stability. On identifying the exacerbation of MR and heart failure due to the mitral valve destruction as identified by TTE, we performed a minimally invasive thoracoscopic mitral valve repair through a small incision 10 days after admission. Just before the procedure, routine evaluation of the fetal heart rate showed no abnormalities.

With the patient in the supine position, rapid sequence induction of anesthesia

Takahiro Tamura, Shuichi Yokota¹

Department of Anesthesiology, Nagoya University Graduate School of Medicine, ¹Division of Anesthesiology, Japanese Red Cross Nagoya Daiichi Hospital, Nagoya, Japan

Address for correspondence:

Dr. Takahiro Tamura,
Department of Anesthesiology,
Nagoya University
Graduate School of
Medicine, 65 Tsurumai-cho,
Showa-Ku, Nagoya, Japan.
E-mail: takahiro@med.
nagoya-u.ac.jp

Access this article online

Website: www.annals.in

DOI: 10.4103/aca.ACA_165_17

Quick Response Code:



How to cite this article: Tamura T, Yokota S. Mitral valve repair in infective endocarditis during pregnancy. *Ann Card Anaesth* 2018;21:189-91.

This is an open access journal, and articles are distributed under the terms of the Creative Commons Attribution-NonCommercial-ShareAlike 4.0 License, which allows others to remix, tweak, and build upon the work non-commercially, as long as appropriate credit is given and the new creations are licensed under the identical terms.

For reprints contact: reprints@medknow.com

Table 1: Laboratory results

	Preoperative					Surgical intervention		Postoperative	
	Outside hospital	Admission	Hospital day 1	Hospital day 2	Hospital day 5	Immediately before	Immediately after	Day 3	Day 5
Leukocyte ($\times 10^9/L$)	10.5	9.8	7.4	6.9	5.5	6.2	30.9	6.7	4.9
RBC ($\times 10^{12}/L$)	3.80	3.84	3.64	3.60	3.52	3.74	4.14	3.46	3.80
Hemoglobin (g/L)	117	119	112	112	110	115	126	105	120
Hematocrit (proportion of 1.0)	0.34	0.32	0.30	0.30	0.31	0.33	0.36	0.31	0.34
Platelet ($\times 10^9/L$)	82	98	85	82	218	285	181	197	264
CRP (nmol/L)	160.0	163.81	147.62	116.19	20.0	7.62	-	76.2	7.62
APTT (s)	-	35.0	31.1	30.8	31.0	30.1	35.9	30.1	-
PT (s)	-	12.9	12.5	12.1	12.4	-	13.2	13.3	11.5
Fibrinogen ($\mu\text{mol/L}$)	-	11.85	9.61	-	-	-	8.91	14.29	-
FDP (mg/L)	-	27.4	28.6	-	-	-	-	-	-
SOFA score	-	2	-	-	-	-	2	-	-

-: No data. RBC: Red blood cell, CRP: C-reactive protein, APTT: Activated partial thromboplastin time, SOFA: Sequential organ failure assessment, PT: Prothrombin time, FDP: Fibrinogen degradation products

was performed using intravenous propofol, rocuronium bromide, and fentanyl. Tracheal intubation was accomplished without difficulty, and general anesthesia was maintained with a target propofol concentration of 1.5–2.5 $\mu\text{g/ml}$ using a target controlled syringe pump, an oxygen-air mixture of 0.1–0.25 $\mu\text{g/kg/min}$ remifentanyl, and fentanyl throughout the operation. Standard radial artery catheter, Swan–Ganz catheter (Edwards Lifesciences Japan Co., Tokyo, Japan), bispectral index, and cerebral oximetry monitoring were used to titrate the anesthetic doses to maintain adequate invasive arterial pressure and cerebral oxygen saturation.

Intraoperative transesophageal echocardiography (Sonos 5500, Philips Electronics Japan K. K., Tokyo, Japan) showed severe MR and rupture of the chordae tendineae of the A3 segment (Carpentier's classification) of the anterior mitral valve leaflet ([Figure 1a–d] and supplementary video) while the other valves were not affected. Hypothermic CPB was performed at 32°C with a pump flow rate of 100% of the theoretical value through a 16-Fr percutaneous femoral artery cannula and femoral vein cannula with a standard pump flow rate of 2.6 L/min/m² of body surface area and mean blood pressure over 70 mmHg. We monitored maternal uteroplacental perfusion and the fetus using abdominal and transvaginal (site determined by procedural circumstances at the time of monitoring) intermittent Doppler flow ultrasound throughout the operation, including the period of CPB. Successful repair was performed, and the patient was weaned off the CPB with inotropic support; the total CPB and aortic cross-clamp durations were 108 and 70 min. Propofol was used for sedation with dobutamine. The tracheal tube was extubated without problems; her postoperative condition was favorable, and she received transvaginal ultrasound for the fetal heart rate regularly. However, the fetus was diagnosed with hydrops fetalis on postoperative day 5, and the patient subsequently underwent dilation and curettage. Two sets

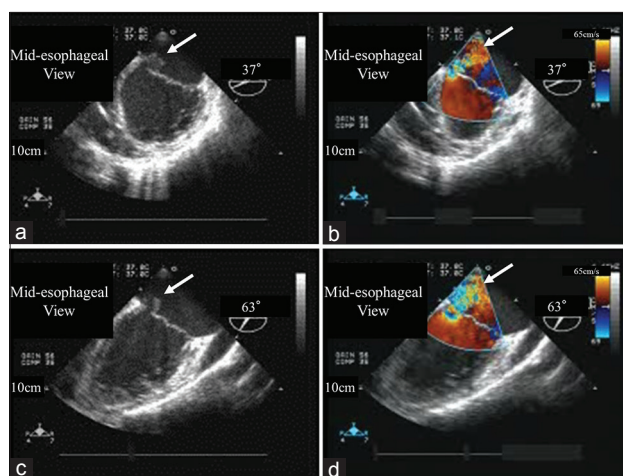


Figure 1: Transesophageal echocardiography in the mid-esophageal view. Severe mitral valve regurgitation and rupture of the chordae tendineae of the A3 segment of the anterior mitral valve leaflet (Figure 1-a-b, at 37°; Figure 1-c-d, at 63°)

of blood cultures performed 5 days postoperatively did not detect bacterial growth, and antibiotics were administered for a total of 8 weeks.

Discussion

We present a case involving a 33-year-old woman diagnosed with acute bacterial endocarditis during the 11th week of gestation who was treated with mitral valve plasty. Cardiovascular surgery using CPB in pregnant women is rarely performed because it is associated with a high maternal and fetal mortality rate.^[4] Montoya *et al.* reported that the incidence of IE during pregnancy was 0.006%, and it is regarded as a serious condition for both the mother and fetus. Multidisciplinary planning of the treatment is required to improve care for both the mother and the fetus affected by IE. It is difficult to determine the best course of treatment for pregnant women with IE because optimal management is strongly dependent on

the clinical situation. Reports indicate that the timing of surgery in pregnant patients undergoing cardiac procedures is related to surgical outcomes.^[5] Earlier intervention results in lower maternal risk while fetal complications are associated with intervention during an early gestational age and the surgical procedure performed.

According to the reports of cases where both the mother and fetus survived after undergoing CPB during pregnancy, Doppler ultrasound should be used to monitor them for uteroplacental perfusion.^[6] In such cases, high blood flow and mean arterial blood pressure >70 mmHg are recommended to maximize placental perfusion without pulsatile flow.^[7] A further consideration to be made is that the physiologic variations of pregnancy may alter drug metabolism and sensitivity to anesthetic agents. Cardio- and vaso-active medications, including vasopressors, inotropes, diuretics, digoxin, vasodilators, and beta-blockers, are safe for use during pregnancy, and there is no clear evidence to contraindicate their use. However, angiotensin-converting enzyme inhibitors, angiotensin II receptor blockers, and aldosterone antagonists should not be used in pregnant women.^[1,8,9] Several animal studies indicate that inhaled anesthetic agents, propofol, and ketamine cause increased neuronal apoptosis and negative effects on neurodevelopment of the fetus, and diazepam may be associated with cleft palate.^[10-12] However, with the exceptions of angiotensin-converting enzyme inhibitors, angiotensin II receptor blockers, and aldosterone antagonists, there is no evidence that any specific anesthetic or vasopressor should be avoided in pregnancy owing to any possible impairment of fetal brain development, teratogenicity, or low placental perfusion.

In the present case, high-flow and high-pressure CPB, ultrasound monitoring, and anesthetic agents generally considered safe for use during pregnancy were utilized according to previously reported recommendations. However, during the postoperative period, while the patient's condition showed gradual improvement, the fetus developed hydrops fetalis. Cardiac surgery with CPB for IE treatment during pregnancy is rarely performed during the early stages of gestation, and the optimal time for surgical intervention that can prevent complications for the mother and fetus remains controversial. Anesthesiologists prioritize saving the life of the mother and should explore interventions to improve the fetal outcomes post-CPB in the early stages of gestation by gathering evidence on such challenging cases.

Declaration of patient consent

The authors certify that they have obtained all appropriate patient consent forms. In the form the patient(s) has/have

given his/her/their consent for his/her/their images and other clinical information to be reported in the journal. The patients understand that their names and initials will not be published and due efforts will be made to conceal their identity, but anonymity cannot be guaranteed.

Financial support and sponsorship

Nil.

Conflicts of interest

There are no conflicts of interest.

References

1. European Society of Gynecology (ESG), Association for European Paediatric Cardiology (AEPIC), German Society for Gender Medicine (DGesGM), Regitz-Zagrosek V, Blomstrom Lundqvist C, Borghi C, *et al.* ESC guidelines on the management of cardiovascular diseases during pregnancy: The task force on the management of cardiovascular diseases during pregnancy of the European Society of Cardiology (ESC). *Eur Heart J* 2011;32:3147-97.
2. Baddour LM, Wilson WR, Bayer AS, Fowler VG Jr., Tleyjeh IM, Rybak MJ, *et al.* Infective endocarditis in adults: Diagnosis, antimicrobial therapy, and management of complications: A Scientific statement for healthcare professionals from the American Heart Association. *Circulation* 2015;132:1435-86.
3. Oneda S, Yamamoto T, Nishida Y, *et al.* Reproductive and developmental toxicity study of recombinant human soluble thrombomodulin (ART-123) -study on intravenous administration during the period of organogenesis in cynomolgus monkeys (*Macaca fascicularis*). *Jpn Pharmacol Ther* 2007;35:1201-9.
4. Montoya ME, Kamath BM, Ahmad M. Endocarditis during pregnancy. *South Med J* 2003;96:1156-7.
5. John AS, Gurley F, Schaff HV, Warnes CA, Phillips SD, Arendt KW, *et al.* Cardiopulmonary bypass during pregnancy. *Ann Thorac Surg* 2011;91:1191-6.
6. Velauthar L, Plana MN, Kalidindi M, Zamora J, Thilaganathan B, Illanes SE, *et al.* First-trimester uterine artery Doppler and adverse pregnancy outcome: A meta-analysis involving 55,974 women. *Ultrasound Obstet Gynecol* 2014;43:500-7.
7. Strickland RA, Oliver WC Jr., Chantigian RC, Ney JA, Danielson GK. Anesthesia, cardiopulmonary bypass, and the pregnant patient. *Mayo Clin Proc* 1991;66:411-29.
8. Cooper WO, Hernandez-Diaz S, Arbogast PG, Dudley JA, Dyer S, Gideon PS, *et al.* Major congenital malformations after first-trimester exposure to ACE inhibitors. *N Engl J Med* 2006;354:2443-51.
9. Alwan S, Polifka JE, Friedman JM. Angiotensin II receptor antagonist treatment during pregnancy. *Birth Defects Res A Clin Mol Teratol* 2005;73:123-30.
10. Dolovich LR, Addis A, Vaillancourt JM, Power JD, Koren G, Einarson TR, *et al.* Benzodiazepine use in pregnancy and major malformations or oral cleft: Meta-analysis of cohort and case-control studies. *BMJ* 1998;317:839-43.
11. Olsen EA, Brambrink AM. Anesthetic neurotoxicity in the newborn and infant. *Curr Opin Anaesthesiol* 2013;26:535-42.
12. Davidson AJ. Anesthesia and neurotoxicity to the developing brain: The clinical relevance. *Paediatr Anaesth* 2011;21:716-21.