




Since January 2020 Elsevier has created a COVID-19 resource centre with free information in English and Mandarin on the novel coronavirus COVID-19. The COVID-19 resource centre is hosted on Elsevier Connect, the company's public news and information website.

Elsevier hereby grants permission to make all its COVID-19-related research that is available on the COVID-19 resource centre - including this research content - immediately available in PubMed Central and other publicly funded repositories, such as the WHO COVID database with rights for unrestricted research re-use and analyses in any form or by any means with acknowledgement of the original source. These permissions are granted for free by Elsevier for as long as the COVID-19 resource centre remains active.



Contents lists available at ScienceDirect

# American Journal of Otolaryngology–Head and Neck Medicine and Surgery

journal homepage: [www.elsevier.com/locate/amjoto](http://www.elsevier.com/locate/amjoto)

## Aerosol and droplet generation from mandible and midface fixation: Surgical risk in the pandemic era

Michael J. Ye<sup>a,\*</sup>, Dhruv Sharma<sup>a</sup>, Vincent J. Campiti<sup>b</sup>, Kolin E. Rubel<sup>a</sup>, Sarah J. Burgin<sup>a</sup>, Elisa A. Illing<sup>a</sup>, Jonathan Y. Ting<sup>a</sup>, Jae Hong Park<sup>c</sup>, Jeffrey D. Johnson<sup>a</sup>, Dominic J. Vernon<sup>a</sup>, Hui Bae Lee<sup>d</sup>, B. Ryan Nesemeier<sup>e</sup>, Taha Z. Shipchandler<sup>a</sup>

<sup>a</sup> Indiana University Department of Otolaryngology – Head & Neck Surgery, 1130 W Michigan St, FH 400, Indianapolis, IN 46202, USA

<sup>b</sup> Indiana University School of Medicine, 340 W 10th St #6200, Indianapolis, IN 46202, USA

<sup>c</sup> School of Health Sciences, Purdue University, 550 W Stadium Ave, West Lafayette, IN 47907, USA

<sup>d</sup> Indiana University Department of Ophthalmology, 1160 W Michigan St, Indianapolis, IN 46202, USA

<sup>e</sup> The Ohio State University Department of Otolaryngology – Head and Neck Surgery, 915 Olentangy River Rd, Columbus, OH 43212, USA

### ARTICLE INFO

**Keywords:**  
COVID-19  
Coronavirus  
Mandible  
Midface  
Droplet  
Aerosol

### ABSTRACT

**Purpose:** The COVID-19 pandemic has led to concerns over transmission risk from healthcare procedures, especially when operating in the head and neck such as during surgical repair of facial fractures. This study aims to quantify aerosol and droplet generation from mandibular and midface open fixation and measure mitigation of airborne particles by a smoke evacuating electrocautery hand piece.

**Materials and methods:** The soft tissue of the bilateral mandible and midface of two fresh frozen cadaveric specimens was infiltrated using a 0.1% fluorescein solution. Surgical fixation via oral vestibular approach was performed on each of these sites. Droplet splatter on the surgeon's chest, facemask, and up to 198.12 cm (6.5 ft) away from each surgical site was measured against a blue background under ultraviolet-A (UV-A) light. Aerosol generation was measured using an optical particle sizer.

**Results:** No visible droplet contamination was observed for any trials of mandible or midface fixation. Total aerosolized particle counts from 0.300–10.000 µm were increased compared to baseline following each use of standard electrocautery ( $n = 4$ ,  $p < 0.001$ ) but not with use of a suction evacuating electrocautery hand piece ( $n = 4$ ,  $p = 0.103$ ). Total particle counts were also increased during use of the powered drill ( $n = 8$ ,  $p < 0.001$ ).

**Conclusions:** Risk from visible droplets during mandible and midface fixation is low. However, significant increases in aerosolized particles were measured after electrocautery use and during powered drilling. Aerosol dispersion is significantly decreased with the use of a smoke evacuating electrocautery hand piece.

### 1. Introduction

As the Coronavirus Disease 2019 (COVID-19) pandemic has evolved, the global conversation has largely centered on a debate about the balance between lockdowns, social distancing, and the availability of services in light of a disease that may spread via asymptomatic carriers [1,2]. Within the medical field, the question of how to provide care safely when it cannot be deferred without detriment to the patient has led to a heterogeneity of policies across institutions and specialties [3,4]. Topics ranging from the recommended level of personal protective equipment (PPE) to the utility of pre-procedural COVID-19 testing

remain unclear, demonstrating a need for standardized recommendations. This is especially true in the care of craniomaxillofacial (CMF) trauma, as operative repair may be time-sensitive to prevent long-term complications [5,6], and multiple specialties are typically involved in the care of these individuals whose injuries often require various approaches [7].

A high viral load of severe acute respiratory syndrome coronavirus 2 (SARS-CoV-2) exists in the nasal cavity and nasopharynx [8,9]. The virus has also been isolated in the mastoid and middle ear [10]. Several recent studies have demonstrated droplet and aerosol generation from endonasal and otologic procedures, with suction techniques and custom

\* Corresponding author at: Department of Otolaryngology – Head and Neck Surgery, Indiana University School of Medicine, 1130 W. Michigan Street, Suite 400, Indianapolis, IN 46202, USA.

E-mail address: [mjye@iu.edu](mailto:mjye@iu.edu) (M.J. Ye).

<https://doi.org/10.1016/j.amjoto.2020.102829>

Received 30 October 2020;

Available online 5 November 2020

0196-0709/© 2020 Elsevier Inc. All rights reserved.

barrier devices demonstrating effectiveness at mitigating dispersion of these particulates [11–14]. Although the generation of droplets and aerosols during rhinologic and otologic procedures has been of particular interest during the COVID-19 pandemic due to instrumentation of the mucosal surface lining, surgeries involving the oral cavity, which has been demonstrated as a significant viral reservoir [15,16], likely also pose significant risk.

Open surgical repair of CMF trauma involving the midface and mandible often requires an intra-oral vestibular approach and use of powered drills, which we hypothesize to be aerosol generating. Therefore, the quantification of droplet and aerosol generation during CMF surgery is critical in determining when the respective procedure can be performed safely and what level of PPE is required. In order to provide data to guide these safe practices, this cadaveric simulation was designed to quantify the generation of droplets and aerosols from techniques utilized during mandible and midface fixation and trial use of a smoke evacuating electrocautery device in reducing particulate production.

## 2. Materials and methods

### 2.1. Biological specimens

This study was granted exempt status by the Indiana University Institutional Review Board due to involving only de-identified human cadaveric tissue specimens (IRB protocol #2004100753). All experiments were performed using two fresh-frozen cadaveric head specimens in a dedicated surgical laboratory. Surgical approach and fixation of the mandible and midface was performed bilaterally on each specimen while measuring droplet and aerosol production using the protocol as described below.

### 2.2. Droplet measurement

Each cadaver head was oriented supine with the superior surface facing surgeon left. Three 183 cm (6 ft) × 50 cm (1.64 ft) nonabsorbent blue boards were placed at 90° from each other in the following directions: 1) superior to the head, 2) left side of the head or across from the surgeon, and 3) inferior to the head [Fig. 1A]. These were positioned such that the border of each board was 15.24 cm (6 in.) away from the surgical site. The surgeon wore a face-shield and a 25 cm × 25 cm sheet of nonabsorbent blue paper on the chest.

Fluorescein was employed in droplet measurement as it fluoresces

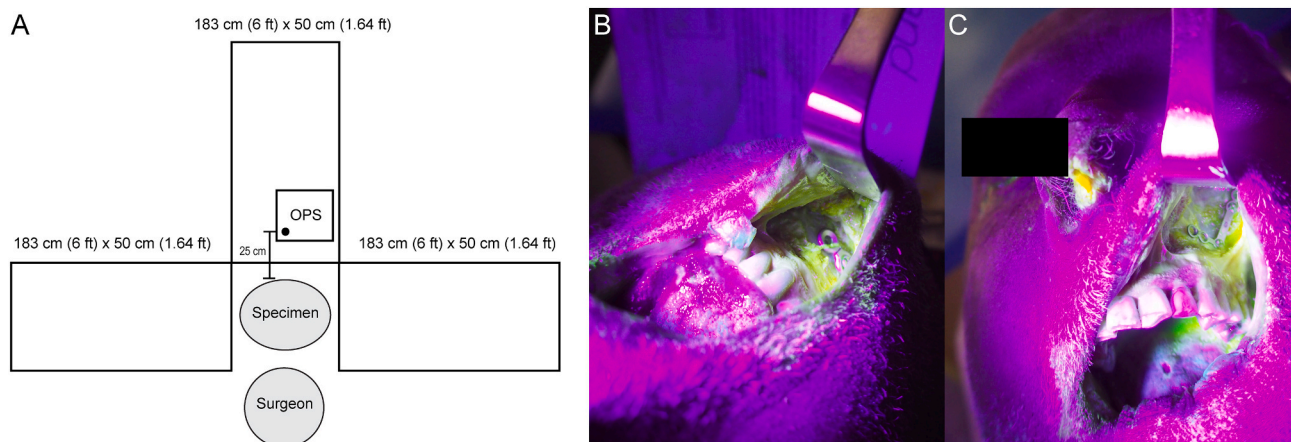
yellow under UV-A light, while the blue background does not. This is an established method for reliably detecting droplet production from surgical procedures in the submillimeter and greater range [17–19]. A 0.1% fluorescein solution was prepared with AK-Fluor® (fluorescein injection, USP) and sterile saline. Mandible and midface surgical sites on each specimen were instilled with fluorescein using submucosal infiltration and a deeper injection performed with the needle inserted until the bone was contacted then withdrawn while injecting. 10 mL was injected into each site. Broad fluorescein positivity was observed in all soft tissues at all times during dissection, confirming adequate instillation [Fig. 1B/C]. During drilling, 0.1% fluorescein solution was used as irrigation fluid. Immediately prior to each procedure, all surfaces were inspected under UV-A light for fluorescein droplets and cleaned such that none were visible.

### 2.3. Aerosol sampling

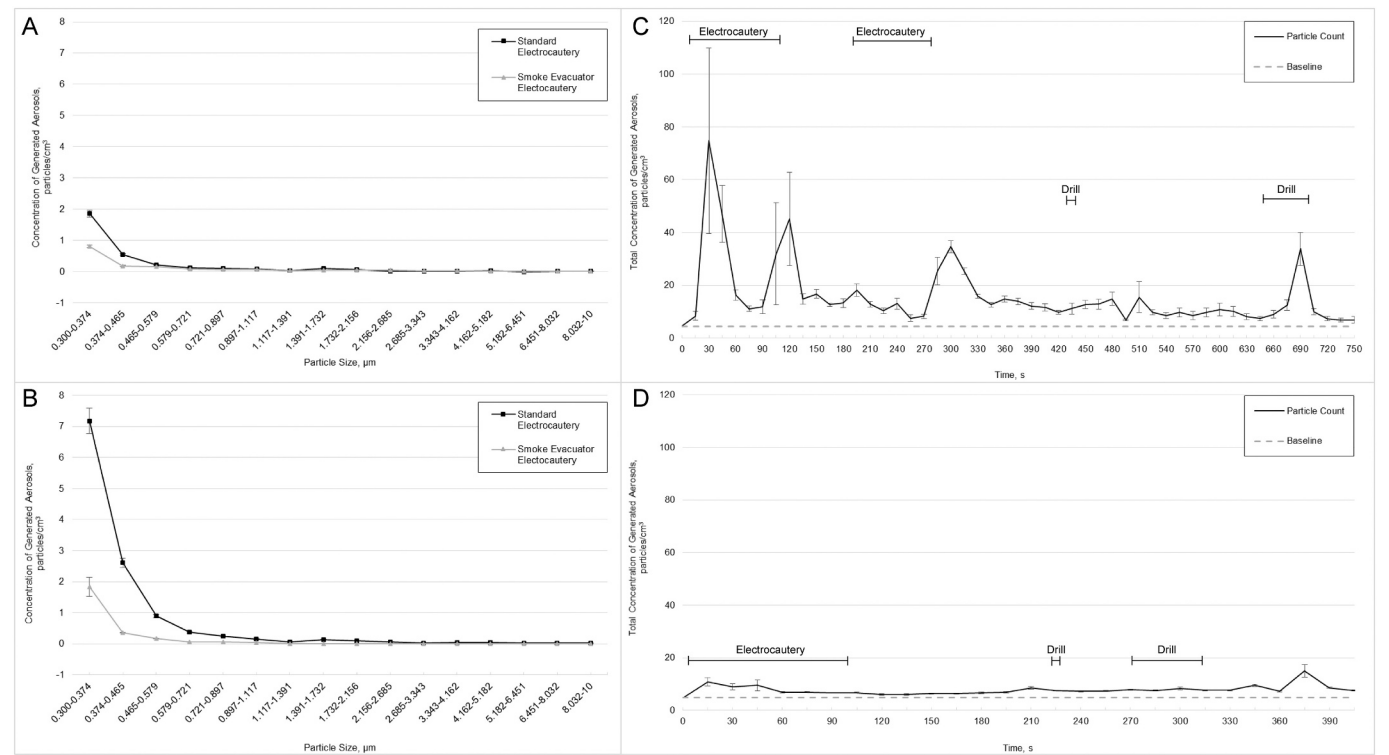
Size distributions of aerosols were monitored using an optical particle sizer (OPS 3330; TSI Inc., Shoreview, Minnesota), which measures particle concentration from 0.300 to 10.000 µm distributed across 16 intervals as depicted on the x-axis of Fig. 2A. The OPS was set up with a sampling flow rate of 1.0 L/min through the 3-mm inlet port which was positioned 25 cm from each surgical site across from the surgeon [Fig. 1A]. Aerosol measurement occurred once every second for the duration of each condition. Prior to each procedure, a 60-second baseline was taken measuring the ambient aerosols in the room. Immediately following this, each procedure was initiated. A high efficiency particulate absorbing (HEPA) filter was employed between experiments until aerosol levels returned to baseline as measured by the OPS.

### 2.4. Surgical equipment and technique

Procedures were performed by a right-handed, fellowship-trained facial plastic surgeon. Soft tissue dissection was performed using standard and smoke evacuating electrocautery handpieces powered by a Megadyne Mega Power Electrosurgical Generator with settings of 25 on both cut and coagulation. The smoke evacuation system was run through a Stryker Neptune 3 Waste Management System on 100% power. The bilateral mandible and midface on one specimen were addressed using a standard needle-tipped electrocautery device and with a smoke evacuating electrocautery hand piece on the second such that a left and right dissection was included in the data of each subsite. Drilling was done using a Stryker CORE Micro Drill hand piece and a 5



**Fig. 1.** A) Schematic representation of experimental setup. Impermeable blue paper was affixed to three 183 × 50 cm boards and to a 25 × 25 cm area of the surgeon's chest. The optical particle sizer (OPS) was positioned 25 cm from each surgical site; B) photograph under ultraviolet-A (UV-A) light of mandibular surgical site after fixation demonstrating broad fluorescein positivity and plate in place; C) photograph under UV-A light of midface surgical site after fixation demonstrating broad fluorescein positivity and plate in place. (For interpretation of the references to color in this figure legend, the reader is referred to the web version of this article.)



**Fig. 2.** A) Aerosol generation during mandible fixation using standard versus smoke evacuating electrocautery; B) aerosol generation during midface fixation using standard versus smoke evacuating electrocautery; C) representative tracing of total aerosol particle counts over time during mandible fixation using standard electrocautery; D) representative tracing of total aerosol particle counts over time during mandible fixation using smoke evacuating electrocautery.

mm midface drill at 40,000 rotations per minute (RPM). Electrocautery and drilling were not performed continuously but rather intermittently in a goal-directed fashion to perform each procedure as would be typical during surgery.

The mandibular and midface fixation was performed via oral vestibular approaches. For each subsite, the vestibular incision was made using electrocautery on the cut mode. Deeper dissection was performed using the coagulation setting combined with blunt dissection until adequate bony exposure was achieved in the subperiosteal plane. For the mandible, a 4-screw 1.5 mm reconstruction plate was placed in standard fashion along the inferior parasymphseal margin with the use of the powered drill. For the midface, a 6-hole 0.6 mm L-plate was placed to fix the lateral zygomaticomaxillary buttress. A self-drilling screw was placed first in order to anchor the plate. The remaining five screws were placed with the assistance of the powered drill. A surgical assistant aided with retraction.

2.5. Statistical analysis of aerosol data

All statistical analyses were performed using the Statistical Package for Social Sciences (IBM SPSS Statistics for Windows, Version 26.0; IBM Corp., Armonk, NY). Because electrical interference from the electrocautery device resulted in intermittent read errors from the OPS, all data during the duration of electrocautery use was excluded from statistical analysis. The 0.300–10.000 µm particle counts (referred to as the ‘total’ particle count) as well as each of the 16 defined size distributions was analyzed for each experimental condition compared to baseline levels. Change from baseline during electrocautery or drill use was determined by subtracting the average 60-second pre-intervention concentration from measurements taken during or after the intervention. All inferential statistics were performed using Mann-Whitney *U* tests with statistical significance determined at alpha = 0.05.

3. Results

3.1. Droplet analysis

Adequate instillation was confirmed visually for all mandible or midface surgical sites prior to each dissection. On inspection under U-VA light. No droplets or debris were visible on the surgeon’s chest, face-mask, or the blue nonabsorbent boards positioned 15.24–198.12 cm (0.5–6.5 ft) away from the surgical site following any trials of mandible (*n* = 4) or midface (*n* = 4) fixation [Table 1]. Fluorescein positivity was observed but not quantified on surgical instruments and on the specimen itself after each condition [Fig. 1B/C].

**Table 1**  
Droplet splatter results following cadaveric mandible and midface fixation.

Droplet splatter results			
Specimen	Site	Electrocautery hand piece	Droplet or splatter contamination
1	Left mandible	Standard	No
1	Right mandible	Standard	No
1	Left midface	Standard	No
1	Right midface	Standard	No
2	Left mandible	Smoke evacuating	No
2	Right mandible	Smoke evacuating	No
2	Left midface	Smoke evacuating	No
2	Right midface	Smoke evacuating	No

### 3.2. Aerosol generation

Mandible and midface fixation were performed using standard ( $n = 2$ ) and smoke evacuating ( $n = 2$ ) electrocautery. When averaged over the course of the procedure, particle counts were increased for mandible and midface fixation across all particle size distributions compared to baseline for both the standard and smoke evacuating electrocautery conditions [Fig. 2A/B]. The amplitude of this increase was on average lower when the smoke evacuating electrocautery was used. Representative tracings of total aerosol counts compared to baseline demonstrate large spikes in aerosol production following electrocautery and drill use [Fig. 2C/D]. Further statistical analysis of overall aerosol counts was not performed for each subsite and dissection technique due to the small sample size.

On pooled subgroup analysis, the 60 s following each instance of standard ( $n = 4$ ) and smoke evacuating ( $n = 4$ ) electrocautery use was compared to the 60 s prior to electrocautery. Significant elevations from baseline were seen in 14 of 16 size distributions ( $p \leq 0.020$ ) and in total particle counts ( $p < 0.001$ ) after standard electrocautery. Only the two largest size distributions, 6.451–8.032  $\mu\text{m}$  ( $p = 0.318$ ) and 8.032–10.000  $\mu\text{m}$  ( $p = 0.081$ ), did not show significant change from baseline. Comparatively, after dissection using the smoke evacuating electrocautery hand piece, significant elevations from baseline were only seen in the 0.579–0.721  $\mu\text{m}$  distribution (1 of 16 size distributions measured,  $p = 0.005$ ), and total particle counts were not significantly changed from baseline ( $p = 0.103$ ). The particle concentration change was significantly higher in the standard compared to the smoke evacuating electrocautery group in all 16 size distributions ( $p < 0.001$ ) [Fig. 3A]. The average total change from baseline concentration was 317% higher in the standard electrocautery group ( $p < 0.001$ ) [Fig. 3C]. When employing the powered drill to install mandible and midface hardware, total particle counts were significantly elevated compared to the 60 s before drilling ( $p < 0.001$ ). However, the 60 s following completion of drilling did not demonstrate a significant change from baseline ( $p = 0.103$ ). When comparing during drilling to after drilling, particle counts were elevated in 4 of the 16 size distributions, all in the submicron range ( $p < 0.001$ ) and in total ( $p < 0.001$ ) [Fig. 3B/C].

### 4. Discussion

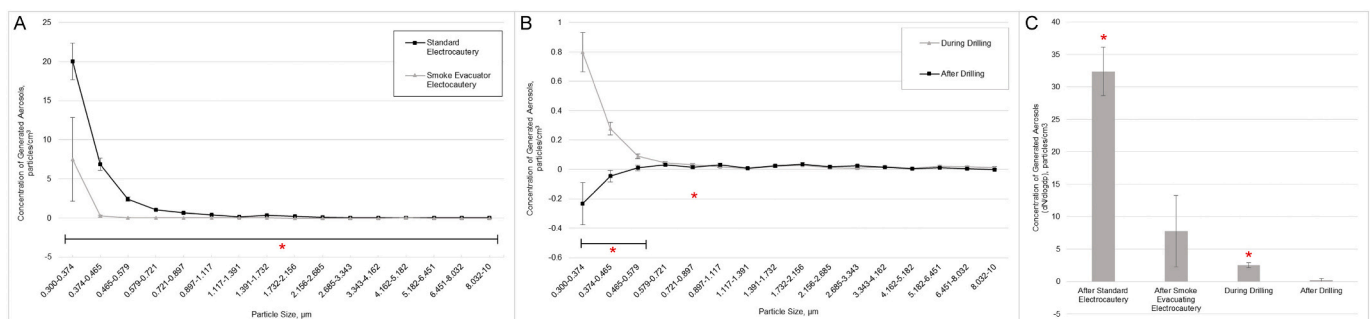
As the global health crisis caused by the coronavirus pandemic continues, the risk of viral transmission during healthcare procedures has been a constant concern [20]. However, an overall lack of objective data has impeded decision making on key topics including PPE recommendations and pre-procedural COVID-19 testing. While aerosol and droplet generation has been demonstrated from other head and neck procedures in areas such as endonasal and otologic surgery [11,17–19,21], there is little published data on the treatment of facial trauma. This is a key knowledge gap as surgical fixation of facial

fractures often requires interaction with the same mucosal surfaces in the oral and nasal cavity which have been demonstrated to harbor high viral loads in infected patients [8], and surgeries often cannot be deferred to allow viral infections to clear [5,6].

Respiratory droplets are a key mechanism of transmission of many viral illnesses including COVID-19. These droplets can carry viral particles greater than two meters away from an infected individual, contaminating surfaces on which they land [22]. Our experiments demonstrated that mandible ( $n = 4$ ) and midface ( $n = 4$ ) fixation performed through the oral vestibular approach generated no visible droplets between 15.24 and 198.12 cm (0.5–6.5 ft) away from the surgical site when measured superior and inferior to the specimen and across from the surgeon. Additionally, no droplets were seen on the surgeon's chest or face shield in any condition tested. Droplets were seen but not quantified on the instruments and specimen after each dissection. This provides evidence that droplet generation from these approaches likely all occurs within 15.25 cm (0.5 ft) from the surgical site. One possible factor is that the oral cavity and lips function as a partial barrier to droplet splatter. As such, mandible and midface fixation through more open approaches may be more droplet generating. This novel finding is an important consideration that should be weighed against the risk of interacting with oral cavity mucosa when performing these procedures on patients who may harbor viral illness.

As the pandemic has continued, aerosols have become more recognized as a source of viral transmission [23,24]. Human papilloma and hepatitis B viral DNA have been detected in electrocautery smoke [25,26], which establishes surgical plume as a possible source of viable infectious particles. In our experiment, aerosol levels measured during mandible and midface fixation were overall higher than baseline with spikes seen during electrocautery and drill use. Using pooled data, significant elevations in aerosol levels were observed following electrocautery use with the standard non-smoke evacuating handpiece. This was seen in total particle counts ( $p < 0.001$ ) and across 14 of 16 particle size distributions ( $p < 0.001$ ), with only the two largest size distributions in the 6.451–10.000  $\mu\text{m}$  range unchanged from baseline ( $p > 0.08$ ). The smoke evacuating handpiece effectively mitigated aerosol generation with an average reduction in total particle counts of 73.0% ( $p < 0.001$ ) [Fig. 3C]. While it is well known that smoke evacuation systems are effective at aerosol and infection mitigation [27], this novel demonstration of its efficacy in the setting of craniomaxillofacial trauma highlights its usefulness during this era of heightened concern for aerosolization of SARS-CoV-2. Moreover, this finding further complements the growing literature of suction devices mitigating aerosol generation [11,13,14].

The use of powered instrumentation including drills has been an area of concern for aerosol generation. Küçükdemir et al. demonstrated production of these airborne particles from orthopedic drilling [28]. In addition, recent literature has provided evidence for aerosol generation from powered endonasal and otologic drilling [11,14,17–19,21]. Our



**Fig. 3.** A) 0.300–10.0  $\mu\text{m}$  aerosol generation due to standard versus smoke evacuating electrocautery. Asterisk (\*) represents a significant reduction in particle counts with the use of smoke evacuating compared to standard electrocautery ( $p < 0.001$ ); B) aerosol generation from craniomaxillofacial fixation during and after drilling; C) average change from baseline in total aerosolized particle counts. Asterisk (\*) represents a significant change from baseline ( $p < 0.001$ ).



data demonstrate that for mandible and midface fixation, use of the powered drill for plating also produces a modest increase in particle counts compared to baseline during drilling for total counts ( $p < 0.001$ ) and in 11 of 16 size distributions measured ( $p \leq 0.028$ ) [Fig. 3B]. However, total particle counts during the 60 s following completion of drilling, and the increase seen during drilling was a fraction of the amplitude compared to electrocautery use [Fig. 3C]. This suggests that while drilling does produce aerosols, the number of particles produced is relatively low compared to electrocautery, and the generated particles dissipate quickly. Differences compared to other types of drilling may be due to the smaller caliber of drill bit and short duration of use. In addition, recent literature suggests that using irrigation while drilling as in this study mitigates aerosol generation [29].

Overall, these findings suggest that fixation of mandible and midface fractures poses little droplet risk. Aerosol generation resulted largely from the use of electrocautery, with powered drilling producing a statistically significant but relatively small number of particles. Large amounts of particles were produced in the respirable ( $<5 \mu\text{m}$ ) [30] and sub-micron range. Production of sub-micron particles is of particular concern as these have been demonstrated to have a greater propensity to penetrate N95 respirators [31]. The authors recommend the use of a smoke evacuating electrocautery hand piece when possible in patients who may harbor SARS-CoV-2, as its use resulted in a significant reduction in particle counts. However, further research is required to accurately quantify the risk of viral transmission posed by these procedures. Until then, the use of enhanced PPE with N95 or powered air purifying respirator (PAPR) and pre-procedural testing is recommended where resources permit.

There are a number of limitations to this study that warrant discussion. Only droplets visible to the human eye were measured, and the measurement was performed in the cardinal directions instead of a complete 360-degree assessment. In terms of aerosols, the OPS measures particle concentrations only in the 0.300 to 10.000  $\mu\text{m}$  size range at a single fixed location, which in this study was across from the surgeon. Therefore, our data may only reflect aerosol exposure to the surgeon and surgical technologist. Further studies should measure aerosol levels at the average distance of anesthesia and circulating staff. Moreover, future studies should also investigate aerosol generation with patients in the operating room, as surgery in live patients may be different than cadaver heads due to normal physiologic temperature and blood flow. Finally, we did not study the presence of viral particles or their infectious ability, aerodynamic properties, desiccation, or deposition patterns.

## 5. Conclusions

The risk posed to operating room personnel from visible droplets during transoral fixation of the mandible and midface low. However, significant increases in aerosolized particles were measured after electrocautery and during powered drilling. Detectable particle counts were significantly decreased with the use of a smoke evacuating electrocautery hand piece.

## Data sharing and permissions

Not applicable.

## Acknowledgements

We would like to thank Stryker Corp. (Kalamazoo, MI) and Rhonda Talbott, RN (Riley Hospital for Children, Indianapolis) for their generosity and flexibility in providing equipment with which to perform these studies.

## Author confirmation statements

All authors contributed significantly to the completion of this work. Details of each individual contribution are listed below.

**Michael J. Ye, MD** - Experimental design, IRB application, materials acquisition, subject recruitment, data collection, analysis, manuscript, final approval, corresponding author.

**Dhruv Sharma, MD, Vincent J. Campiti, BS, Kolin E. Rubel, MD** - Experimental design, data collection, analysis, manuscript, final approval

**Sarah J. Burgin, MD, Elisa A. Illing, MD, Jonathan Y. Ting, MD, MS, MBA, Park, Jae Hong, PhD, CIH** - Experimental design, materials acquisition, data analysis, manuscript, final approval.

**Jeffrey D. Johnson, MD, Dominic J. Vernon, MD, Hui Bae Lee, MD, B. Ryan Nesemeier, MD** - Experimental design, data collection, analysis, manuscript, final approval

**Taha Z. Shipchandler, MD** - Experimental design, materials acquisition, data collection, analysis, manuscript, final approval, senior author

## Funding source

Self-funded.

## Declaration of competing interest

The authors have no conflict of interests to disclose. This work has not been submitted for publication elsewhere.

## References

- [1] Bai Y, Yao L, Wei T, et al. Presumed asymptomatic carrier transmission of COVID-19. *Jama* 2020;323:1406–7.
- [2] Nishiura H, Kobayashi T, Miyama T, et al. Estimation of the asymptomatic ratio of novel coronavirus infections (COVID-19). *Int J Infect Dis* 2020;94:154–5.
- [3] Dollinger MT, Kumta NA, Greenwald DA, et al. Outcomes of universal pre-procedure COVID-19 testing prior to endoscopy in a tertiary care center in New York City. *Gastroenterology* 2020 [Epub ahead of print].
- [4] Agopian V, Verna E, Goldberg D. Changes in liver transplant center practice in response to coronavirus disease 2019: unmasking dramatic center-level variability. *Liver Transpl* 2020;26:1052–5.
- [5] Hurrell MJ, Batstone MD. The effect of treatment timing on the management of facial fractures: a systematic review. *Int J Oral Maxillofac Surg* 2014;43:944–50.
- [6] Derdyn C, Persing JA, Broaddus WC, et al. Craniofacial trauma: an assessment of risk related to timing of surgery. *Plast Reconstr Surg* 1990;86:238–45 [discussion 246–237].
- [7] Sherick DG, Buchman SR, Patel PP. Pediatric facial fractures: analysis of differences in subspecialty care. *Plast Reconstr Surg* 1998;102:28–31.
- [8] Zou L, Ruan F, Huang M, et al. SARS-CoV-2 viral load in upper respiratory specimens of infected patients. *N Engl J Med* 2020;382:1177–9.
- [9] Zhu N, Zhang D, Wang W, et al. A novel coronavirus from patients with pneumonia in China, 2019. *N Engl J Med* 2020;382:727–33.
- [10] Frazier KM, Hooper JE, Mostafa HH, et al. SARS-CoV-2 virus isolated from the mastoid and middle ear: implications for COVID-19 precautions during ear surgery. *JAMA Otolaryngol Head Neck Surg* 2020 [Epub ahead of print].
- [11] Workman AD, Xiao R, Feng A, et al. Suction mitigation of airborne particulate generated during Sinonasal drilling and cautery. *Int Forum Allergy Rhinol* 2020;18:22644.
- [12] Chen JX, Workman AD, Chari DA, et al. Demonstration and mitigation of aerosol and particle dispersion during mastoidectomy relevant to the COVID-19 era. *Otology & neurotology*: official publication of the American Otological Society. *Am Neurotol Soc [and] Eur Acad Otol Neurotol* 2020;41(9):1230–9. <https://doi.org/10.1097/MAO.0000000000002765>.
- [13] Chari DA, Workman AD, Chen JX, et al. Aerosol dispersion during mastoidectomy and custom mitigation strategies for otologic surgery in the COVID-19 era. *Otolaryngol. Head Neck Surg.* 2020;194599820941835.
- [14] Sharma D, Ye MJ, Campiti VJ, Rubel KE, Higgins TS, Wu AW, et al. Mitigation of aerosols generated during rhinologic surgery: a pandemic era cadaveric simulation. *Otolaryngol Head Neck Surg* 2020. <https://doi.org/10.1177/0194599820951169> [Epub ahead of print].
- [15] Herrera D, Serrano J, Roldán S, et al. Is the oral cavity relevant in SARS-CoV-2 pandemic? *Clin Oral Invest* 2020;24:2925–30.
- [16] Xu J, Li Y, Gan F, et al. Salivary glands: potential reservoirs for COVID-19 asymptomatic infection. *J Dent Res* 2020;99:989.
- [17] Sharma D, Rubel KE, Ye MJ, et al. Cadaveric simulation of otologic procedures: an analysis of droplet splatter patterns during the COVID-19 pandemic. *Otolaryngol Head Neck Surg* 2020;163(1):145–50. <https://doi.org/10.1177/0194599820929274>.

- [18] Sharma D, Rubel KE, Ye MJ, et al. Cadaveric simulation of endoscopic endonasal procedures: analysis of droplet splatter patterns during the COVID-19 pandemic. *Otolaryngol Head Neck Surg* 2020 [194599820929274].
- [19] Workman AD, Welling DB, Carter BS, et al. Endonasal instrumentation and aerosolization risk in the era of COVID-19: simulation, literature review, and proposed mitigation strategies. *Int Forum Allergy Rhinol* 2020;10(7):798–805. <https://doi.org/10.1002/alr.22577>.
- [20] Elizabeth Brindle M, Gawande A. Managing COVID-19 in surgical systems. *Ann Surg* 2020;272:e1–2.
- [21] Workman AD, Jafari A, Welling DB, et al. Airborne aerosol generation during Endonasal procedures in the era of COVID-19: risks and recommendations. *Otolaryngol Head Neck Surg* 2020. <https://doi.org/10.1177/0194599820931805> [Epub ahead of print].
- [22] Bahl P, Doolan C, de Silva C, et al. Airborne or droplet precautions for health workers treating COVID-19? *J Infect Dis* 2020. <https://doi.org/10.1093/infdis/jiaa189> [Epub ahead of print].
- [23] Wang J, Du G. COVID-19 may transmit through aerosol. *Ir J Med Sci* 2020;1–2.
- [24] Asadi S, Bouvier N, Wexler AS, et al. The coronavirus pandemic and aerosols: does COVID-19 transmit via expiratory particles? *Aerosol Sci Tech* 2020;0:1–4.
- [25] Zhou Q, Hu X, Zhou J, et al. Human papillomavirus DNA in surgical smoke during cervical loop electrosurgical excision procedures and its impact on the surgeon. *Cancer Manag Res* 2019;11:3643–54.
- [26] Kwak HD, Kim SH, Seo YS, et al. Detecting hepatitis B virus in surgical smoke emitted during laparoscopic surgery. *Occup Environ Med* 2016;73:857–63.
- [27] Alp E, Bijl D, Bleichrodt RP, et al. Surgical smoke and infection control. *J Hosp Infect* 2006;62:1–5.
- [28] Küçükduymaz F, İmren Y, Akkoyunlu Y, et al. Domestic electric drills in the service of orthopaedic surgery: a potential and preventable source of surgical site infections. *Acta Orthop Traumatol Turc* 2012;46:455–9.
- [29] Gadkaree SK, Derakhshan A, Workman AD, et al. Quantifying aerosolization of facial plastic surgery procedures in the COVID-19 era: safety and particle generation in craniomaxillofacial trauma and rhinoplasty. *Facial Plast Surg Aesth Med* 2020;22(5):321–6. <https://doi.org/10.1089/fpsam.2020.0322>.
- [30] Seto WH. Airborne transmission and precautions: facts and myths. *J Hosp Infect* 2015;89:225–8.
- [31] Qian Y, Willeke K, Grinshpun SA, et al. Performance of N95 respirators: filtration efficiency for airborne microbial and inert particles. *Am Ind Hyg Assoc J* 1998;59:128–32.