

OPEN

# A Case Report of Mass-Forming *Aspergillus* Tracheobronchitis Successfully Treated with Voriconazole

Da Sol Kim, MD, Jae Seok Jeong, MD, So Ri Kim, MD, PhD, Gong Yong Jin, MD, PhD, Myoung Ja Chung, MD, PhD, and Yong Chul Lee, MD, PhD

**Abstract:** *Aspergillus* tracheobronchitis (ATB) represents a rare disease entity accounting for 3.5% to 5.0% of cases of invasive aspergillosis. Particularly, mass-forming ATB is extremely rare, and clinical reports are limited. Given that the patency of the trachea and bronchi are essential for maintaining sufficient airflow, a central airway mass originating from an *Aspergillus* infection is likely to be associated with severe clinical manifestations and fatal outcomes. Although several therapeutic options for ATB have been suggested, including medication and airway interventions, the optimal choice of treatment in diverse clinical conditions remains under discussion.

We report a case of ATB that initially manifested as severe dyspnea and total atelectasis of the left lung in a patient with newly detected diabetes.

Radiographic study, bronchoscopy, and pathologic findings of the lesion revealed mass-forming type of ATB.

Interestingly, our patient's symptoms dramatically resolved with voriconazole without further invasive intervention.

This clinical experience highlights the beneficial role of voriconazole in the treatment of rare and potentially fatal cases of ATB.

(*Medicine* 94(34):e1434)

**Abbreviations:** ATB = *Aspergillus* tracheobronchitis, CT = computed tomography.

## INTRODUCTION

*Aspergillus* tracheobronchitis (ATB) refers to a unique type of *Aspergillus*-associated pulmonary disease in which the trachea and bronchi may be the main or even sole site of infection.<sup>1</sup> ATB represents a rare disease entity accounting for only 3.5% to 5.0% of all cases of invasive aspergillosis and is known to occur primarily in immunocompromised hosts.<sup>1,2</sup> Furthermore, 1 report indicated that ATB leads to devastating clinical outcomes with a mortality rate of up to 84% in severe immunocompromised hosts.<sup>3</sup>

Editor: Rana El Feghaly.

Received: April 25, 2015; revised: July 27, 2015; accepted: July 30, 2015. From the Department of Internal Medicine, Research Center for Pulmonary Disorders (DSK, JSJ, SRK, YCL); Department of Radiology (GYJ); and Department of Pathology (MJC), Chonbuk National University Medical School, Deokjin-gu, Jeonju, South Korea.

Correspondence: Yong Chul Lee, Department of Internal Medicine, Research Center for Pulmonary Disorders, Chonbuk National University Medical School, San 2-20, Geumam-dong, Deokjin-gu, Jeonju 561-180, South Korea (e-mail: leeyc@jbnu.ac.kr).

DSK, JSJ, and SRK are contributed equally to this work.

The authors have no conflicts of interest to disclose.

Copyright © 2015 Wolters Kluwer Health, Inc. All rights reserved.

This is an open access article distributed under the terms of the Creative Commons Attribution-NonCommercial-ShareAlike 4.0 License, which allows others to remix, tweak, and build upon the work non-commercially, as long as the author is credited and the new creations are licensed under the identical terms.

ISSN: 0025-7974

DOI: 10.1097/MD.0000000000001434

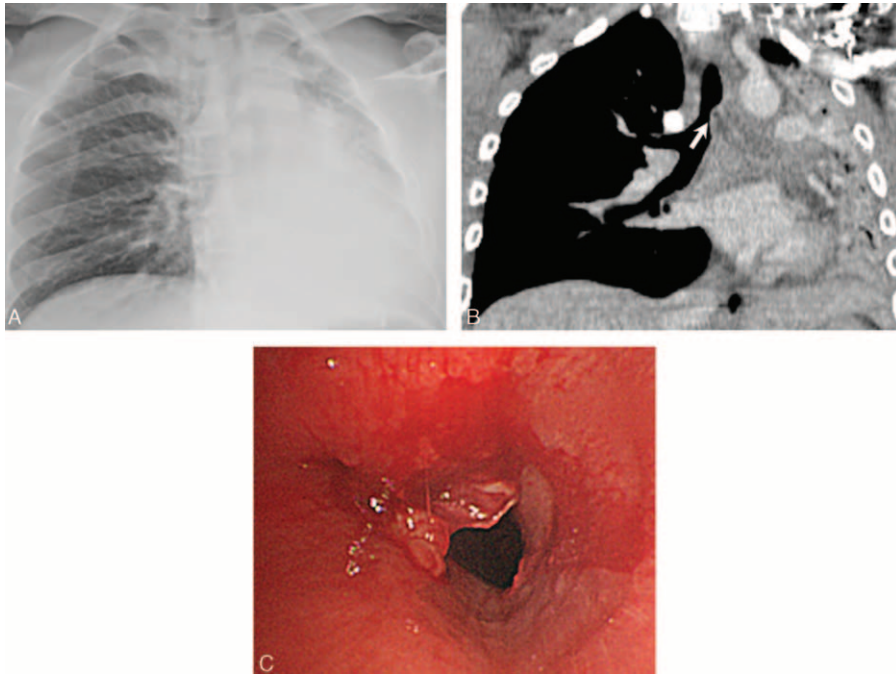
To aid characterization and early diagnosis of ATB, there are several classification systems based on bronchoscopic findings with histologic data and depth of invasion (eg, obstructive, ulcerative, and pseudomembranous ATB by Denning,<sup>4</sup> superficial infiltration, full-layer involvement, occlusion, and mixed type by Wu et al).<sup>5</sup> However, it is difficult to characterize various types of tracheobronchial involvement into a uniform system. Moreover, diverse clinical manifestations and the rarity of ATB render its diagnosis quite difficult. In particular, mass-forming types of ATB may not fit clearly into the suggested ATB classification systems, and to the best of our knowledge only 2 cases of mass-forming ATB have been reported to date.<sup>6,7</sup> Given that the patency of the trachea and bronchi are essential for maintaining sufficient airflow, a central airway mass containing *Aspergillus* is likely to be associated with severe clinical manifestations and fatal outcomes. For example, symptoms in these patients involve severe dyspnea and/or wheezing.<sup>6,7</sup>

Herein, we report a case of ATB that initially manifested as severe dyspnea and total atelectasis of the left lung in a patient with newly detected diabetes. Radiographic study, bronchoscopy, and pathologic findings of the lesion led to a diagnosis of mass-forming ATB. Interestingly, the obstructing lesion dramatically resolved with voriconazole without further invasive interventions.

## CASE PRESENTATION

A 31-year-old man with no past history of known medical illnesses was admitted to our emergency department because of severe dyspnea and accompanying tachypnea (30 breaths per minute). The patient had never smoked and had no previous history of allergic diseases. On physical examination, there was dullness over the left lung field, and decreased breath sounds on the left lung heard on auscultation. There were no enlarged lymph nodes in the body. Arterial blood gas analysis revealed PO<sub>2</sub> 80.3 mmHg, PCO<sub>2</sub> 33.1 mmHg, pH 7.46, and SaO<sub>2</sub> 96.5%. Laboratory data showed that platelets, white blood cells, and differential cell counts were within the normal range. The patient's erythrocyte sedimentation rate was 70 mm/hour (reference range: 0–9 mm/hour) and C-reactive protein was 27.75 mg/L (reference range: 0–5 mg/L), which together indicated an underlying inflammatory process. Notably, urine glucose was 4+ and HbA1c was 19.4%, confirming underlying diabetes mellitus.

On imaging studies, chest radiographs showed total opacification of the left lung (Figure 1A). Subsequently, chest computed tomography (CT) revealed total atelectasis of the left lung and a mass-forming lesion at the distal trachea (Figure 1B, white arrow). However, simultaneous mediastinal or hilar lymphadenopathy was not detected. Examination of the lesion with bronchoscopy revealed an erythematous, swollen, and soft mass approximately 4 cm above the carina (Figure 1C).



**FIGURE 1.** (A) Chest X-ray demonstrating total opacity of the left lung. (B) Coronal view computed tomography (CT) scan showing a mass-forming lesion (white arrow) and total atelectasis of the left lung. (C) Bronchoscopic examination at the distal trachea revealed an erythematous, swollen, and soft mass. The initial attempt of bronchoscopic biopsy caused bleeding as shown in the figure.

We subsequently performed transtracheal biopsy of the lesion; however, we were unable to obtain enough tissue for culture due to the severe clinical condition of the patient during bronchoscopic examination. Bronchial washing culture revealed no microorganisms; however, upon histopathologic examination using Grocott-Gomori's methenamine silver staining (Figure 2A, black arrows), invasion of the tracheal cartilage by septate hyphae was observed (Figure 2B, black arrows). In addition, numerous inflammatory cells were recruited to the adjacent tracheal epithelium (Figure 2B, inset box). The invading hyphae exhibited acute angle branching patterns, indicating possible infection with an *Aspergillus* species. Based on these findings, a presumptive diagnosis of ATB was established.

During the bronchoscopic examination, we attempted to perform debridement of the lesion via bronchoscopy to maintain airway patency. However, the patient's clinical condition and respiratory symptoms worsened after bronchoscopy necessitating endotracheal intubation and mechanical ventilation (oxygen saturation was 74.8% in spite of maximal degree of supplementary oxygen). Moreover, the likelihood of procedure-associated adverse events (eg, bronchoesophageal fistula) was substantially high considering the severity of the pathologic findings including deep invasion of the *Aspergillus* species into the cartilage wall and the presence of uncontrolled diabetes. Thus, we decided to treat the patient with voriconazole. On the first day of treatment, 6 mg/kg of voriconazole was administered intravenously for every 12 hours as a loading dose, which was then switched to 400 mg/day of oral voriconazole as a maintenance dose according to the guidelines for treating invasive aspergillosis.<sup>8</sup>

After treatment with voriconazole, the respiratory symptoms of the patient gradually improved without additional invasive management. On the 19th day of medication, follow-up CT and bronchoscopy showed successful resolution

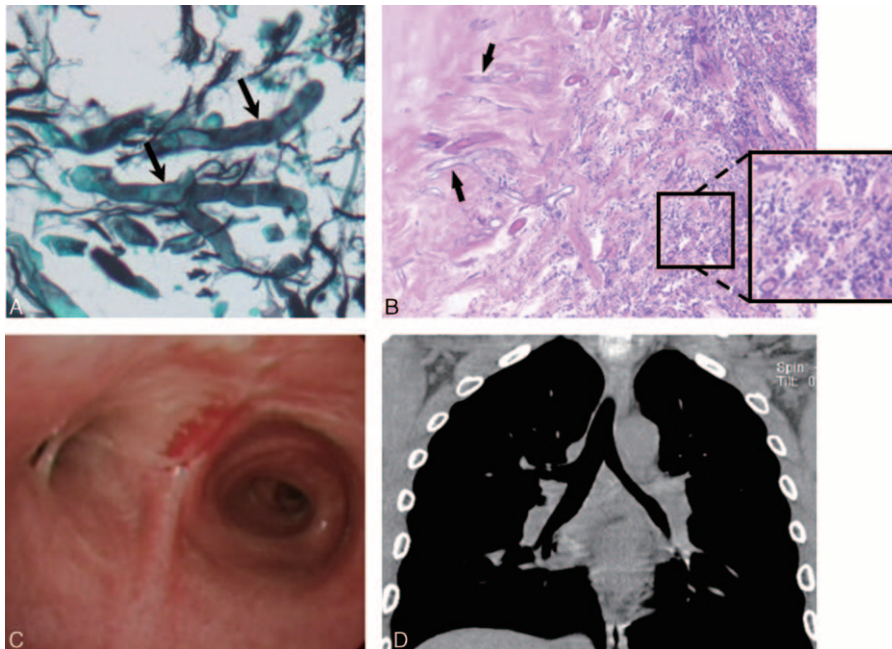
of the lesion (Figure 2C, D). After a month of admission, the patient was discharged without any respiratory sequelae. The patient was treated with voriconazole for a total of 10 weeks, and there has been no evidence of recurrence of disease in this patient at the time of this publication.

## DISCUSSION

Here, we report a rare and severe case of ATB that occurred in a young patient with newly detected diabetes but without severe immune suppression. The patient suffered from dyspnea owing to an obstructive mass in the distal trachea coinciding with total atelectasis of the left lung. Subsequent examinations revealed that the lesion was an extremely rare type of ATB, namely, mass-forming ATB. Although clinical symptoms of the patient required urgent therapeutic intervention, the possibility of intervention-associated complications was considerably high due to the extensive invasion of ATB into the tracheal cartilage and to the presence of uncontrolled diabetes. Therefore, we chose monotherapy with voriconazole. Interestingly, signs and symptoms of respiratory illness in the patient gradually improved, and the lesion successfully resolved based on follow-up images 19 days after treatment with voriconazole.

In general, immunocompromised patients are usually associated with poor prognoses. Several previous reports have suggested that the immune status of patients with mass-forming ATB is not uniform. For example, Routsis et al<sup>6</sup> reported a mass-forming type of ATB in an immunocompromised patient who took chemotherapy for erythroleukemia whereas another study reported that a relatively immunocompetent patient with well controlled diabetes mellitus experienced mass-forming ATB.<sup>7</sup>

The symptoms of the patient in this study were devastating with subsequent respiratory failure, but the patient's immune system was not severely impaired. The spectrum of the initial



**FIGURE 2.** (A) A transbronchial biopsy of the lesion showing *Aspergillus* species with acute angle branching and septate hyphae (black arrows) (GMS,  $\times 400$ ). (B) Biopsy showing deep invasion of *Aspergillus* hyphae into tracheal cartilage (black arrows) and various inflammatory cells infiltrations (H&E,  $\times 100$ ); inset shows a higher magnification of infiltration of inflammatory cells (H&E,  $\times 200$ ). (C, D) A follow-up bronchoscopic examination and CT scan on the 19th day of medication revealed successful resolution of the lesion. GMS = Grocott-Gomori's methenamine silver, H&E = hematoxylin and eosin.

clinical manifestations and the underlying immune status of our patient made establishing an appropriate therapeutic strategy quite difficult. Interestingly, the patient showed dramatic therapeutic response to voriconazole after treatment for 19 days, with the ATB resolved completely thereafter. This outcome was in contrast to a previous report on ATB, where antifungal treatment lasting approximately 4 to 19 months was required to achieve complete resolution on chest CT.<sup>9</sup> Based on our experience, monotherapy with voriconazole appears to have a beneficial role even in treating rare and severe types of ATB.

Although the reason for mass formation in ATB is not clearly understood, intact immune responses in the host appear to influence mass development partly through the accumulation of various inflammatory cells as depicted in the pathologic examination of a previous case.<sup>7</sup> Similarly, the pathologic examination of our case also showed prominent infiltration of various inflammatory cells. Moreover, our patient had newly detected diabetes with a high level of HbA1c (19.4%) before the onset of evident metabolic decompensation. Considering the impact of hyperglycemia in the immune system (eg, impairment of transmigration and chemotaxis of neutrophils, decrease of their bactericidal activity, decrease of response to antigens of CD4<sup>+</sup> cells, and unnecessary glycosylation of antibodies),<sup>10</sup> the gradual decrease in the competence of immune system likely affords sufficient time for mass formation following *Aspergillus* infection. In the same context, the relatively well preserved immune system in our patient may have played an important role in the dramatic response to voriconazole.

In this report, we describe a case of mass-forming ATB that presented with disastrous respiratory signs and symptoms that required immediate airway management. However, considering the significantly high possibilities of procedure-associated complications, we decided to treat with voriconazole without

further interventions. Surprisingly, the patient's respiratory symptoms were successfully improved with voriconazole. This clinical experience suggests that medication with voriconazole may be an effective therapeutic option in rare and severe ATB patients who are not candidates for invasive airway procedures.

#### ETHICAL REVIEW AND PATIENT CONSENT

The Institutional Review Board of Chonbuk National University Hospital stated that it was not necessary to achieve IRB approval for this case report, but that patient consent was required as the study dealt only with retrospective use of the patient's medical record and related images. Written informed consent was obtained from the patient prior to the publication of this case report and accompanying images.

#### ACKNOWLEDGMENTS

The authors thank Professor Mie-Jae Im for critical reading of the manuscript and Peter Lee for correction of grammatical errors. This work was supported by the Korea Healthcare Technology R&D Project, Ministry for Health and Welfare, Republic of Korea (Grant A121931), by Basic Science Research Program through the National Research Foundation of Korea (NRF) funded by the Ministry of Science, ICT and Future Planning (NRF-2014R1A2A1A01002823), and by the fund of Biomedical Research Institute, Chonbuk National University Hospital. This study was performed under a project entitled "Medical school students training program: Dream of being a Nobel Prize Winner," part of the Research Center for Pulmonary Disorders, Chonbuk National University Medical School and Research Institute of Clinical Medicine of Chonbuk National University-Biomedical Research Institute of Chonbuk National University Hospital.

## REFERENCES

1. Krenke R, Grabczak EM. Tracheobronchial manifestations of *Aspergillus* infections. *ScientificWorldJournal*. 2011;11:2310–2329.
2. Steinbach WJ, Marr KA, Anaissie EJ, et al. Clinical epidemiology of 960 patients with invasive aspergillosis from the PATH alliance registry. *J Infect*. 2012;65:453–464.
3. Tasci S, Glasmacher A, Lentini S, et al. Pseudomembranous and obstructive *Aspergillus* tracheobronchitis – optimal diagnostic strategy and outcome. *Mycoses*. 2006;49:37–42.
4. Denning DW. Commentary: unusual manifestations of aspergillosis. *Thorax*. 1995;50:812–813.
5. Wu N, Huang Y, Li Q, et al. Isolated invasive *Aspergillus* tracheobronchitis: a clinical study of 19 cases. *Clin Microbiol Infect*. 2010;16:689–695.
6. Routsis C, Platsouka E, Prekates A, et al. *Aspergillus* bronchitis causing atelectasis and acute respiratory failure in an immunocompromised patient. *Infection*. 2001;29:234–244.
7. Park BJ, Kim YK, Kim H, et al. A case of endobronchial aspergillosis completely obstructing lobar bronchus. *Tuberc Respir Dis (Seoul)*. 2005;59:311–314.
8. Walsh TJ, Anaissie EJ, Denning DW, et al. Treatment of aspergillosis: clinical practice guidelines of the Infectious Diseases Society of America. *Clin Infect Dis*. 2008;46:327–360.
9. Choi JK, No JH, Lee BH, et al. Invasive tracheobronchial aspergillosis: Case reports and a literature review. *Infect Chemother*. 2011;43:76–81.
10. Peleg AY, Weeraratna T, McCarthy JS, et al. Common infections in diabetes: pathogenesis, management and relationship to glycaemic control. *Diabetes Metab Res Rev*. 2007;23:3–13.