

Response to oral gliclazide in a pre-pubertal child with hepatic nuclear factor-1 alpha maturity onset diabetes of the young

Abdelhadi M. Habeb,^a Elizabeth T. George,^b Verghese Mathew,^b Andrew L. Hattersley^c

From the ^aPaediatric Endocrine Unit, Maternity and Children Hospital, Medina, Saudi Arabia, ^bPaediatric Department, Hull Royal Infirmary, Anlaby Road, Hull, ^cPeninsula Medical School, Barrack Road, Exeter, United Kingdom

Correspondence: Abdelhadi M. Habeb, MD · Paediatric Endocrine unit, Maternity and Children Hospital, PO Box 25374, Medina, Saudi Arabia · T: +966 552028350, F: +966 48640391 · amhabeb@hotmail.com · Accepted: March 2010

Ann Saudi Med 2011; 31(2): 190-193

PMID: **** DOI: 10.4103/0256-4947.75590

The term “maturity onset diabetes of the young” (MODY) describes a heterogeneous group of monogenic diabetes of which hepatic nuclear factor-1 alpha (HNF-1 α) MODY is the most common. Patients with HNF-1 α mutations typically present after puberty, and oral sulfonylureas (SU) have been shown to be effective in adults with this condition. A 7-year-old boy presented with asymptomatic hyperglycemia ranging between 6.2 and 10.1 mmol/L and glycosuria for nearly a year. The child’s initial HbA_{1c} was 6.9% and the pancreatic Islet cell autoantibodies were negative. His response to the oral glucose tolerance test (OGTT) showed a large increment of glucose from basal level of 7.7 to 21.1 mmol/L in 120 min. The mild presentation, family history, and negative autoantibodies were suggestive of HNF-1 α MODY, which was confirmed by mutation analysis. Initial management with diet alone was not sufficient, but he responded well to 20 mg oral gliclazide once a day with an improvement of HbA_{1c} from 7.2% to 6.5% within 3 months of treatment. The case is an illustration of the clinical utility of molecular genetic tests in the management of childhood diabetes.

Maturity onset diabetes of the young (MODY) is a clinically heterogeneous autosomal dominant non-insulin-dependent diabetes mellitus that often presents before 25 years of age. A recent UK survey showed that MODY is the most common form of monogenic diabetes and accounts for 10% of non-type 1 diabetes in children.¹ The condition is caused by defects in genes that control beta cell function. At present, mutations in seven genes, which encode for the glucose sensor enzyme glucokinase (GCK) and six transcription factors (hepatocyte nuclear factor (HNF)-1 α , HNF-4 α , HNF-1 β , insulin promoter factor-1 (IPF-1), neurogenic differentiation-1 (NEUROD-1) and carboxyl-ester lipase (CEL), have been associated with different MODY phenotypes ranging from mild hyperglycemia to more aggressive forms that are associated with diabetes-related complications.²

Mutations in the gene encoding for the HNF-1 α are associated with MODY type 3, which is the most common form of MODY in the white population.^{3,4}

More than 350 mutations have been identified in the HNF-1 α gene leading to variable clinical expression and age of presentation.⁵ HNF-1 α is a protein that binds to promoter regions of other genes and activates the transcription to mRNA. By doing so, it controls the function of genes involved in the insulin synthesis and pancreatic development as well as glucose transport and metabolism in the pancreatic alpha cell.³

Individuals with HNF-1 α MODY typically present after puberty with non-ketotic hyperglycemia and/or glycosuria at relatively normal blood glucose levels. They may have a family history of diabetes in two or three generations or at least a diabetic parent even if he or she was labeled as having type 1 or type 2 diabetes. The condition is progressive in nature and, if untreated, can lead to early microvascular complications.⁶ Patients can be initially treated with diet, but the majority will eventually need glucose-lowering agents.⁷ Low-dose oral sulfonylureas (SU) have been shown to be at least as effective as insulin in adults with HNF-1 α MODY.^{8,9} However, experience with their use in children is limited.

ited. We report a child with HNF-1a MODY who presented unusually during the pre-pubertal period and responded well to oral gliclazide as an initial therapy.

CASE

A 7-year-old white male was referred to Hull Royal Infirmary, UK, with a history of intermittent hyperglycemia for nearly a year. His serial blood glucose measurements taken by his father's home blood glucose monitor showed variable fasting readings ranging between 6.2 and 10.1 mmol/L with random ones of more than 13 mmol/L. His urine often had traces of glucose with no ketones. He was otherwise fit and healthy with no history of polyurea, polydipsia, weight loss, or bed wetting. He was born at term with a birth weight of 3.3 kg and had no neonatal hyperglycemia. He was previously well and healthy and not treated with any medications. He was the eldest of two children to his unrelated parents and his younger brother had no evidence of diabetes. The 39-year-old father was diagnosed with type 1 diabetes at the age of 30 years with evidence of

advanced retinopathy at the time of diagnosis. He had been on insulin since then with poor glycemic control and needed multiple laser treatments for diabetic retinopathy. The father was an adopted child and neither his parents nor his sibling were known to be diabetic. The mother was healthy and none of her family had diabetes.

On examination, he was well and non-dysmorphic. At the age of 7.3 years, his weight and height were both on the 75th percentiles and he had no acanthosis nigricans. The remaining examination was unremarkable. A random blood glucose in the clinic was 6.3 mmol/L, but his urine showed glycosuria and his HbA_{1c} was 6.9% (normal range, 4.5%-6.2%). Further investigation revealed normal liver function, lipid profile, and abdominal ultrasound. Islet cells cytoplasmic autoantibodies (ICA) were negative as tested by indirect immunofluorescence and his glutamic acid decarboxylase autoantibodies (GADA), which was measured by radioimmunoassay, were also negative.

The patient was given dietary advice with a follow-

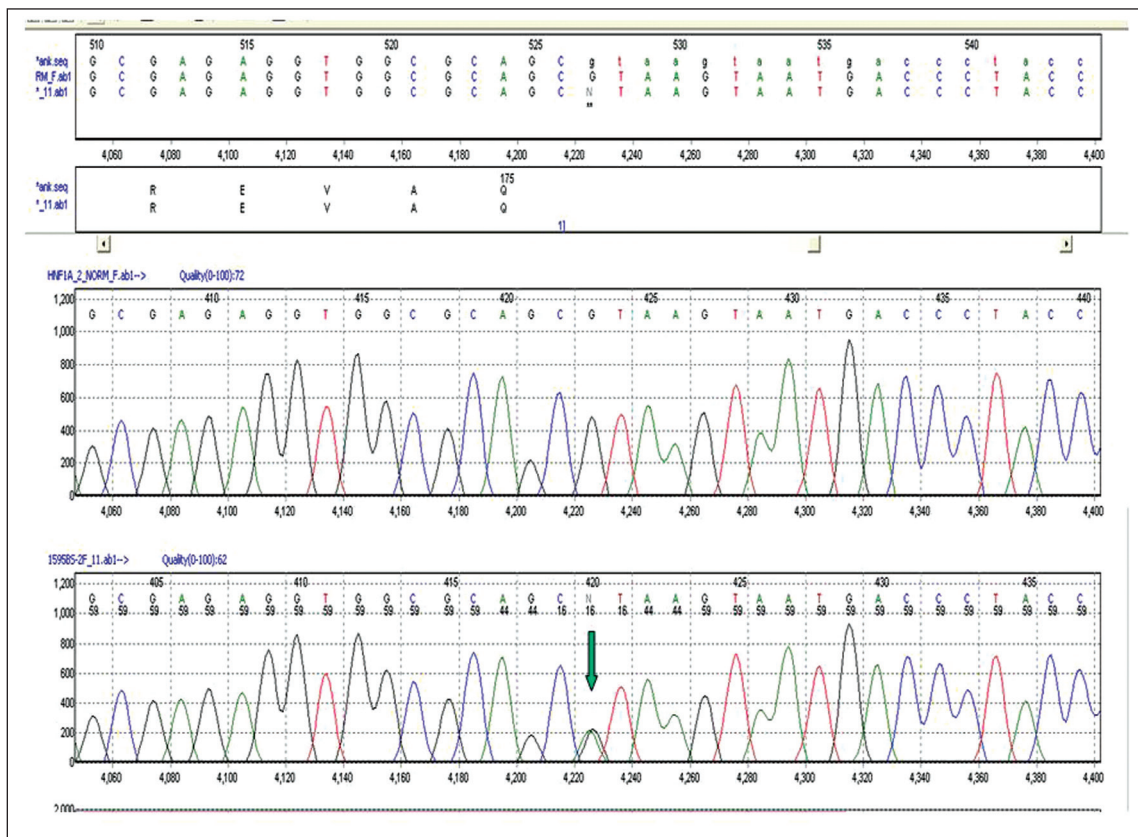


Figure 1. Chromatogram of the c.526+1G>A mutation taken from the Mutation Surveyor sequencing analysis software provided by Soft Genetics. The upper sequence is the normal control and the lower sequence is the patient. The mutation is indicated by the peak in the comparison trace at the bottom (arrowed). The top frame contains the reference nucleotide and amino acid sequences.

up appointment in the diabetes clinic. Two months later he was admitted to the hospital with a viral illness and his blood glucose rose to >20 mmol/L with no ketonuria. His blood glucose improved without insulin, but his HbA_{1c} rose to 7.8%. An oral glucose tolerance test (GTT) using 1.75 g/kg glucose showed a blood glucose of 7.7, 15.7, 18.7, 20.6, and 21.7 mmol/L at 0, 30, 60, 90, and 120 minutes, respectively. Direct DNA sequencing of all exons and intron-exon boundaries of the HNF-1a gene was done at Peninsula University, Exeter. The analysis showed that the child was heterozygous for a known GT-AT mutation (c.526+1G>A) of the splice donor site in intron 2 of the HNF-1a gene. A chromatogram of this mutation is shown in **Figure 1**. This confirmed the diagnosis of HNF1A-MODY, also known as MODY 3. The father was not keen to be tested as he was depressed at the time and the rest of the family were not screened as they were asymptomatic and the mutation had already been described in patients with MODY 3. After discussion with the family, he was placed on oral gliclazide 20 mg once daily. He was followed up at the clinic on an every 3 month basis. His home blood glucose profile showed no significant hyperglycemia and he reported no symptoms of hypoglycemia. His HbA_{1c} was reduced from 7.2% to 6.5% within 3 months of starting gliclazide and this improvement in HbA_{1c} was maintained for the following 18 months (**Figure 2**).

DISCUSSION

Young children presenting with diabetes are often diagnosed as having type 1 diabetes and treated with insulin, based on age. Although our case resembles an early phase of type 1 diabetes, the combination of long-standing non-ketotic hyperglycemia, glycosuria, at a relatively normal fasting glucose, and negative pancreatic auto-antibodies in a child with a diabetic father raised the possibility of MODY. The presence of retinopathy at diagnosis in the father was unusual for type 1 diabetes, suggesting that the father may also have a progressive form of MODY that was mislabeled as type 1 diabetes. Obesity-related type 2 diabetes is emerging in children, but this child was lean and had no acanthosis nigricans.

The next step was to identify which MODY subtype this child had as this would have a major impact on management. For example, if he had a glucokinase (GCK) mutation (MODY 2) then no treatment would be needed as the condition is usually stable and not associated with microvascular complications, but if he had one of the common transcription factor MODY (HNF-1a, HNF-1a, HNF-4a) then treatment would

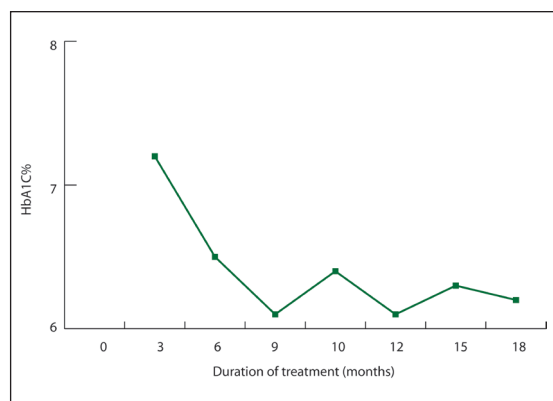


Figure 2. Serial changes in HbA_{1c} over 18 month period after starting oral gliclazide 20 mg/day.

be required because of the risk of diabetes-related complications.^{6,10} The age of presentation was more suggestive of GCK MODY, as other MODY subtypes often present in adolescence and young adulthood; however, this condition did not explain the early retinopathy in his father from whom he inherited the diabetes. The absence of renal cysts and other extrapancreatic features ruled out the possibility of HNF-1a MODY.^{11,12}

Both MODY 1 (HNF-4a) and MODY 3 (HNF-1a) have similar phenotype, as HNF-4a regulates the expression of HNF-1a, but the latter is more common and is associated with a low renal threshold for glucose resulting in glycosuria at a relatively low blood glucose concentration,^{13,14} which was detected in our patient. We performed OGTT as the response to this test can differentiate between HNF-1a and GCK MODY.¹⁵ Patients with GCK MODY usually have a higher fasting glucose than those with HNF-1a MODY, but the blood glucose increment at 120 minutes does not often exceed 5.5 mmol/L. In our patient, the baseline fasting glucose was not high and the increment at 120 minutes was >5.5 mmol/L as typically seen in HNF-1a MODY. Therefore, on clinical grounds, our case was more typical of MODY³ except for the age of presentation.

As tests for MODY mutations are still not widely available and can be expensive, it is recommended that these tests be performed when they are likely to be positive and alter the management.⁷ We used the clinical phenotype and biochemical tests to guide the mutation analysis, which confirmed the diagnosis of HNF-1a MODY.

Because the child was asymptomatic and at lower risk of developing ketoacidosis, it was important to discuss the treatment options with the family, particularly with the absence of data on the use of SU in pre-

pubertal children with HNF-1a MODY and the risk of SU-associated hypoglycemia. Because of the rise of the HbA_{1c} despite the dietary management alone and the progressive nature of the condition with the history of early retinopathy in the father, it was felt that a trial of low-dose SU was justified. The decision to use oral gliclazide was based on the fact that it has a lower hypoglycemic risk than other SUs and its efficacy has been tested in adults with HNF-1a MODY in a randomized, crossover controlled trial.¹⁶ In that trial adults with HNF-1a MODY showed a 5.2-fold better response to gliclazide than to metformin and a 4-times greater fall in fasting glucose to gliclazide than in BMI-matched type 2 diabetes patients. There are few reports of using SU in the pediatric age group with HNF-1a;¹⁷⁻¹⁹ however, these children were all significantly older than our patient and they were treated with other SU agents than gliclazide. We started with a small dose (20 mg once daily) and the families were educated on the recognition and manage-

ment of hypoglycemia. Our patient showed an excellent response, on the same dose, without any side effects.

It has been suggested that individuals with HNF-1a MODY usually present late, if they inherited the condition from the father²⁰ and earlier if they were exposed to intrauterine hyperglycemia.²¹ However, this was not the case with our patient. We cannot explain the exact reason for the early presentation in our patient; however, it is possible that this may be the result of variable expression, which is a feature of autosomal dominant conditions or it may be an example of the relationship between the genotype and the age of presentation as shown recently in some mutations.⁵

To the best of our knowledge, this is the youngest patient with HNF-1a MODY to receive gliclazide as initial treatment. As the mutation analysis allowed for selection of the most appropriate treatment, the case is another illustration of the clinical utility of molecular genetic tests in the care of patients with diabetes.

REFERENCES

- Haines L, Wan KC, Lynn R, Barrett TG, Shield JP. Rising incidence of type 2 diabetes in children in the UK. *Diabetes Care* 2007;30:1097-101.
- Hattersley AT, Pearson ER. Minireview: Pharmacogenetics and beyond: The interaction of therapeutic response, β -cell physiology, and genetics in diabetes. *Endocrinology* 2006;147:2657-63.
- Frayling TM, Bulman MP, Ellard S, Appleton M, Dronsfield MJ, Mackie AD, et al. Mutations in the hepatocyte nuclear factor 1 alpha gene are a common cause of maturity-onset diabetes of the young in the United Kingdom. *Diabetes* 1997;46:720-5.
- Ehtisham S, Hattersley AT, Dunger DB, Barrett TG; British Society for Paediatric Endocrinology and Diabetes Clinical Trials Group. First UK survey of paediatric type 2 diabetes and MODY. *Arch Dis Child* 2004;89:526-9.
- Bellanné-Chantelot C, Carette C, Riveline JP, Valéro R, Gautier JF, Langer E, et al. The type and the position of HNF1A mutation modulate the age at diagnosis of diabetes in patients with maturity onset diabetes of the young (MODY) 3. *Diabetes* 2008;57:503-8.
- Isomaa B, Henricsson M, Lehto M, Forsblom C, Karanko S, Sarelin L, et al. Chronic diabetic complications in patients with MODY3 diabetes. *Diabetologia* 1998;41:467-73.
- Hattersley A, Bruining J, Shield J, Njolstad P, Donaghy K; International Society for Pediatric and Adolescent Diabetes. ISPAD Clinical practice consensus guidelines 2006-2007 the diagnosis and management of monogenic diabetes in children. *Pediatr Diabetes* 2006;7:352-60.
- Shepherd M, Pearson ER, Houghton J, Salt G, Ellard S, Hattersley AT. No deterioration in glycaemic control in HNF-1 α MODY following transfer from long-term insulin to sulphonylureas. *Diabetes Care* 2003;26:3191-2.
- Pearson ER, Liddell WG, Shepherd M, Corral RJ, Hattersley AT. Sensitivity to sulphonylureas in patients with HNF-1 gene mutations: evidence for pharmacogenetics in diabetes. *Diabet Med* 2000;17:543-5.
- Pearson ER, Velho G, Clark P, Stride A, Shepherd M, Frayling TM, et al. beta-Cell genes and diabetes: Quantitative and qualitative differences in the pathophysiology of hepatic nuclear factor-1 α and glucokinase mutations. *Diabetes* 2001;50:S101-S107.
- Frayling TM, Evans JC, Bulman MP, Pearson E, Allen L, Owen K, et al. β -Cell genes and diabetes: Molecular and clinical characterization of mutations in transcription factors. *Diabetes* 2001;50:S94-100.
- Edghill EL, Bingham C, Ellard S, Hattersley AT. Mutations in hepatocyte nuclear factor-1beta and their related phenotypes. *J Med Genet* 2006;43:84-90.
- Menzel R, Kaisaki PJ, Rjasanowski I, Heinke P, Kerner W, Menzel S. A low renal threshold for glucose in diabetic patients with a mutation in the hepatocyte nuclear factor-1 α (HNF-1 α) gene. *Diabet Med* 1998;15:816-20.
- Pontoglio M, Prié D, Cheret C, Doyen A, Leroy C, Froguel P, et al. HNF1 α controls renal glucose reabsorption in mouse and man. *EMBO Rep* 2001;1:359-65.
- Stride A, Vaxillaire M, Tuomi T, Barbetti F, Njolstad PR, Hansen T, et al. The genetic abnormality in the beta cell determines the response to an oral glucose load. *Diabetologia* 2002;45:427-35.
- Pearson ER, Starkey BJ, Powell RJ, Gribble FM, Clark PM, Hattersley AT. Genetic causes of hyperglycaemia and response to treatment in diabetes. *Lancet* 2003;362:1275-81.
- Brunerová L, Treslová L, Pr_hová S, Vosáhl J, Broz J, Lebl J, et al. Glibenclamide instead of insulin: a new chance for MODY 3 type diabetes patients: Case report. *Vnitr Lek* 2006;52:275-9.
- Jesic MD, Sajic S, Jesic MM, Maringa M, Micic D, Necic S. A case of new mutation in maturity-onset diabetes of the young type 3 (MODY 3) responsive to a low dose of sulphonylurea. *Diabetes Res Clin Pract* 2008;81:e1-3.
- Palomo Atance E, Ballester Herrera MJ, Giralt Muiña P, López Garrido P. Childhood onset diabetes treated with sulphonylurea. *An Pediatr (Barc)* 2008;69:568-71.
- Klupa T, Warram JH, Antonellis A, Pezolesi M, Nam M, Malecki MT, et al. Determinants of the development of diabetes (maturity-onset diabetes of the young-3) in carriers of HNF-1 mutations: Evidence for parent-of-origin effect. *Diabetes Care* 2002;25:2292-301.
- Stride A, Shepherd M, Frayling TM, Bulman MP, Ellard S, Hattersley AT. Intrauterine hyperglycemia is associated with an earlier diagnosis of diabetes in HNF-1 gene mutation carriers. *Diabetes Care* 2002;25:2287-91.