



Case report

A case report of robotic-guided prone transpoas lumbar fusion in a patient with lumbar pseudarthrosis, adjacent segment disease, and degenerative scoliosis

Shane Shahrestani^{a,b,1}, Nolan J. Brown^{c,1}, Nischal Acharya^{c,*,1}, Luis Daniel Diaz-Aguilar^d, Martin H. Pham^d, William R. Taylor^d

^a Keck School of Medicine, University of Southern California, Los Angeles, CA, USA

^b Department of Medical Engineering, California Institute of Technology, Pasadena, CA, USA

^c School of Medicine, University of California, Irvine, Orange, CA, USA

^d Department of Neurosurgery, University of California, San Diego, La Jolla, CA, USA

ARTICLE INFO

Keywords:

Prone
Transpoas
Robotic
Pseudarthrosis
Scoliosis
Case report

ABSTRACT

Background: Surgical treatment of scoliosis includes long and invasive multi-level instrumentation and correction which may result in high rates of postoperative complications, especially in elderly patients with osteopenia or multiple comorbidities. Minimally invasive surgical options may benefit these patients.

Case description: A 73-year-old female patient with a history of degenerative lumbar scoliosis, L4–5 pseudarthrosis, and resulting L5–S1 adjacent segment following prior unsuccessful lateral L4–5 interbody fusion presented to the clinic with severe lower back pain and lower extremity radiculopathy. The decision was made to proceed with surgical correction via a robotic-guided prone transpoas (PTP) approach, which is a novel approach similar to lateral lumbar interbody fusion (LLIF) with the patient in a prone decubitus position. Excellent spinal alignment was achieved with no complications. On two-month follow-up, imaging revealed pedicle screws at the L3, L4, L5 levels and at the sacrum without change and continued interbody cages position with no signs or symptoms of infection.

Discussion: Minimally invasive procedures have demonstrated benefit in spine surgery especially for at risk populations. The LLIF procedure has been well established for use in a wide range of spinal pathologies given its noted benefits in increasing spinal column stability through posterior fixation and indirect decompression. However, only marginal improvements in segmental lordosis are expected and there are reports of neurological complications. The PTP procedure has emerged as an alternative to LLIF for the treatment of spinopelvic pathologies. This approach enables greater improvements to spinal lordosis through single-position surgery while simultaneously reducing intraoperative repositioning and providing the known benefits of lateral interbody surgery.

Conclusion: Our experience suggests that the PTP approach is safe and effective because it does not require patient repositioning, easily interfaces with robotic guidance, and achieves increased lordosis gains via the prone positional effect compared to LLIF and comparable approaches.

1. Introduction

Degenerative disease of the lumbar spine encompasses a broad range of age-related pathologies, including scoliosis, spondylolisthesis, and stenosis [7,13,21,23]. In particular, the etiology of degenerative scoliosis stems from the gradual breakdown of spinal structural elements,

thus resulting in spinal column misalignment and a Cobb angle greater than 10° [11,14,21]. Changes in spine biomechanics and unstable load bearing in patients with degenerative scoliosis result in worsening chronic axial lower back pain (LBP), with superimposed lower limb radiculopathy in some patients [3]. Furthermore, recent shifts of focus towards improved patient quality of life versus cost have made

* Corresponding author at: Department of Neurosurgery, University of California, Irvine, 101 The City Drive South, Orange, CA 92868, USA.

E-mail address: nischala@hs.uci.edu (N. Acharya).

¹ These authors contributed equally to the present manuscript.

degenerative lumbar scoliosis a prominent public health concern in the large elderly population of the United States [14]. As such, three surgical treatment options are commonly considered for patients with degenerative scoliosis, including surgical decompression alone, decompression and limited short fusion, and long fusion with correction of deformity [6]. However, surgical treatment of scoliosis often includes long and invasive multi-level instrumentation and correction which may result in high rates of postoperative complications, especially in elderly patients who may have osteopenia or have existing comorbidities [7,22].

Thus, to treat this patient population, minimally invasive surgery (MIS) is often implemented with hopes of reducing incision length, intraoperative blood loss, hospital length of stay (LOS), and damage to spinal structures [17,26]. One MIS technique that has gained recent attention is lateral interbody fusion through a PTP approach, which is similar to the LLIF technique but positions the patient in a prone decubitus [20]. This positional variation has been shown to increase segmental lordosis and correct various spinopelvic alignment parameters compared to LLIF approaches, and contemporary studies have demonstrated its safety and efficacy in treating lumbar pathologies [20].

We report a complex case of a patient with degenerative scoliosis who presented to the University of California San Diego's Department of Neurological Surgery with right-sided back pain. Radiographic evidence suggests that the patient's symptoms were further complicated by L4–5 pseudarthrosis and L5-S1 adjacent segment disease following prior unsuccessful lateral interbody fusion. As a result, the patient received robotic PTP surgical re-fusion for correction of her spinal pathologies. This study was conducted in accordance with our local Institutional Review Board.

2. Case description

2.1. Presentation

A 73-year-old white female with degenerative scoliosis refractory to prior unsuccessful L4–5 interbody fusion presented with right-sided back pain and lower extremity radiculopathy. All vital signs were within normal limits and her BMI was 26.38 kg/m². Her past medical

history included lumbar and lumbosacral degenerative disk disease, gastroesophageal reflux disease (GERD), and a single episode of major depressive disorder. Her past surgical history included appendectomy, breast augmentation, cervical disk surgery, and lateral L4–5 interbody fusion (Fig. 1). The patient is a former cigarette smoker who quit 40 years ago, and the patient reports drinking one glass of wine per day. Patient medications included calcium-vitamin D, daily multivitamins, docusate sodium, ondansetron, simvastatin, and trazodone. All work was conducted and reported in line with the SCARE 2020 criteria [1].

2.2. Examination

Patient was alert and oriented x3 with appropriate mood and affect. Motor strength was 5/5 and deep tendon reflexes were 2+ in all upper and lower extremities. Sensation was intact throughout. Physical exam and 12 system review of systems revealed no significant findings. Patient gait was normal with negative Romberg and pronator drift testing.

The patient was injected with 27.2 (mCi) of Tc-99m MDP intravenously. Single-photon emission computed tomography (SPECT) of the lower thoracic, lumbar, and sacral spine was obtained. Imaging revealed a degenerative pattern of uptake, most pronounced at the lower lumbar spine. The images were also evaluated on separate IMPAX PET-CT software, demonstrating elevated uptake along the right aspect of L3–4, and the superior endplate of L5 with small focal uptake along the left aspect of inferior endplate of L4. In addition, imaging revealed pseudarthrosis at the site of previous surgical fusion (L4–5), L5-S1 adjacent segment disease, and a concave scoliosis to the right (Fig. 2).

2.3. Clinical course

Clinical evaluation revealed that the patient had L4–5 pseudarthrosis and adjacent segment disease associated with spinal stenosis and lumbar radiculopathy in the setting of lumbar degenerative disc disease. The patient described significant back pain and sought intervention to alleviate their pain and correct their degenerative pathology. The decision was made to proceed with surgical treatment with hopes of correcting all spinal pathologies.

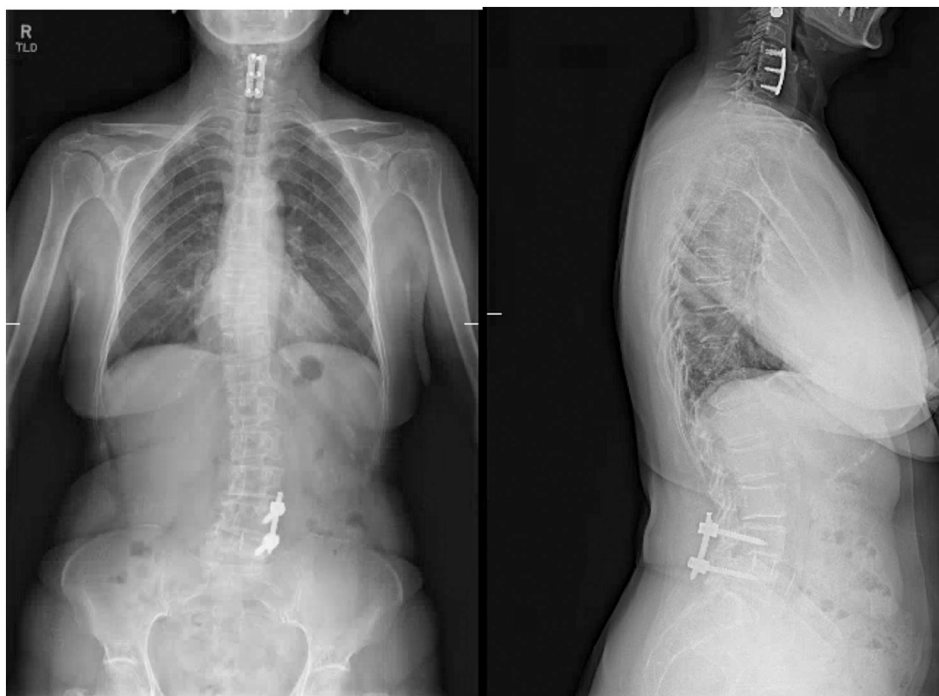

Fig. 1. Anteroposterior (left) and lateral (right) scoliosis radiographs demonstrating prior anterior interbody graft at L4/L5, anterolisthesis at L4/L5, and L convex scoliosis, apex L3 with Cobb's angle 16°.

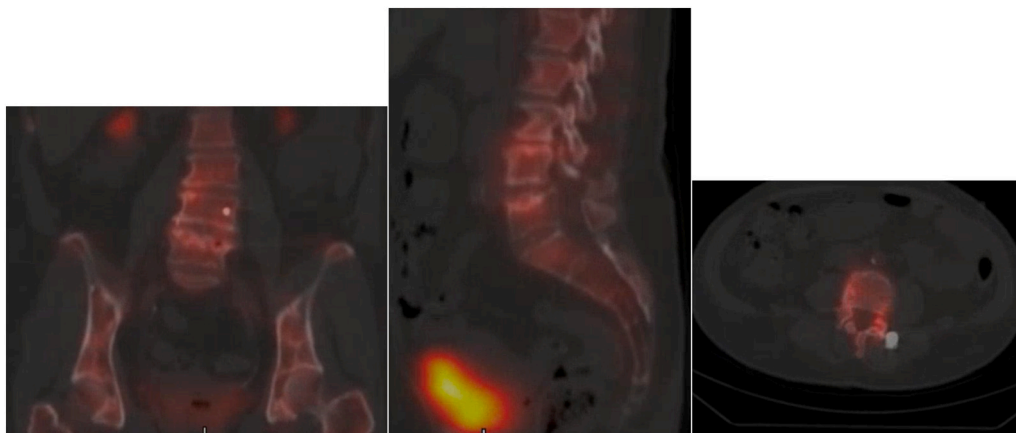


Fig. 2. a–c: a) Coronal (left), b) sagittal (middle), and c) axial (right) L4 SPECT CT of the lower thoracic, lumbar, and sacral spine demonstrating elevated uptake along the right aspect of L3–L4, and the superior endplate of L5 with small focal uptake along the left aspect of inferior endplate of L4.

2.4. Operation

With general endotracheal anesthesia achieved and an adequate intravenous line started, Dr. William Taylor led the team, placing the patient prone on the ProAXIS table with spine attachments and with mild lordosis. The neuro monitoring was used throughout the procedure and showed no change in the saphenous somatosensory evoked potentials (SSEP), electromyography (EMG) and/or triggered EMG with lateral approach. The initial attachment of the posterior superior iliac spine (PSIS) was completed with a pin attached to the Mazor robot and the robot was brought into the field. Using fluoroscopic guidance, it was calibrated with the preoperative CT scan. With this in good working order, the robot was then used to mark the left side. It appeared that a single incision on the left side would suffice, which was opened to its fullest extent in a paramedian approach.

Initial pedicle screws below were then removed through the paramedian approach and the fusion was noted to be intact with direct palpation and movement with reduction of the unilateral pedicle screws. Given that the pedicle screws were removed using robotic guidance with a Mazor, a marker drill tap and pedicle screws were placed under power into the pedicle through the vertebral bodies. An identical procedure was performed on the right side. We initially attempted to make separate skin incisions for the robotic insertion; however, a single incision was then made. These were connected and small skin bridges were left between the incisions.

Using robotic guidance, the L3–4, 5 and S1 screws were placed, and at the L5 and S1 levels on the right K-wires were placed into the screw holes. With the screws in position and the fusion noted to be solid, attention was then turned to the L3–4 location. Using the robotic guidance, a skin incision was made on the right side with the patient in the prone position for the lateral approach. A single incision, approximately 5 cm in length was made and the retroperitoneal space was opened with blunt dissection, both through the separate incision and posteriorly along the level of the transverse process. With this in position, an appropriately sized dilator was placed down to the midportion of the disk and tamped into position. Dilation tubes were then completed, and the fluoroscopy was brought into the procedure, noting the K-wire to be in good position. The posterior shim was removed once and replaced.

With all this in position posteriorly, the dilation tubes were placed down and a 2-blade retractor from Alphatec was then used and opened anteriorly. The instrumentation was noted to be slightly canted posteriorly, all 3 tubes of dilation were checked with a neuro monitoring device and they were greater than 10 milliamps posteriorly with no stimulation anteriorly. The retractor was brought in the procedure. The disk space was identified and opened with a bayoneted knife. With this

in position, a complete discectomy was then performed with a box chisel, a Cobb curette and a pituitary rongeur. An appropriate size trial was then selected and then an appropriate size cage filled with Trinity bone graft and a single sponge cut in half of Infuse was placed into the cage and tamped into position in the vertebral body. It was noted to be slightly posterior in that location, although contained by the posterior longitudinal ligament and was left in that position. The retractor was then removed. Surgiflo was placed across that location. There was no evidence of complications. No EMG and/or SSEP and/or other changes were recorded. Skin incision on that side was then closed with a 2-0 inverted Vicryl and 4-0 undyed subcuticular in the skin. The posterior incisions were then used to place a dilation tube using robotic navigation down to the L5–S1 location. Fluoroscopy confirmed this and a single Medtronic clear tube was placed down to identify the lamina at L5, the spinous process of L5, and the facet joints. Near complete laminectomy was performed on the ipsilateral side. The patient had increased right-sided leg pain and her left-sided leg pain was essentially absent at that point.

Dissection continued across the midline, undercutting the lamina and generous foraminotomy removed the facet joint on the right side. The disk space was entered, and a complete discectomy was performed. An appropriately sized Medtronic expansile cage was placed in that location and this area was packed with a single sponge of Infuse, which was placed anteriorly. The middle of the cage was packed with bone graft. The entire disk space was filled with the remainder of the Trinity and a rotating cutter was placed down that location for placement of the graft within the bone graft. It was tamped into the appropriate position and expanded to the appropriate position. There was no evidence of extrusion of the bone fragments and/or fusion material. Surgiflo was placed across that and the retractor was removed. A CT scan with the O-arm was done and the right pedicle screw at L5 was noted to be laterally placed. Given the 2 separate holes placed in that we elected to remove the screw and replace the rod and final tightening of the rod. On the left side the remainder of the Osteoecel bone graft was placed over the posterior lateral transverse process that was identified at L3–4 and 5. The rod was then attached bilaterally fixed to the final tightening. Incisions were both copiously irrigated and the muscle and fascia closed over vancomycin powder with a 0 Vicryl, 2-0 Vicryl and 4-0 undyed subcuticular in the skin. Final sponge and instrument counts were correct. There were no complications.

2.5. Postoperative outcomes and follow-up

On two-month follow-up at the University of California San Diego Department of Neurological Surgery, imaging revealed pedicle screws at the L3, L4, L5 levels and at the sacrum without change or complications.

Anterior interbody cages were placed at L3/L4, L4/L5 and L5/S1 without extrusion (Fig. 3). Spinal alignment was maintained. There was no fracture. Surgical incision was closed and healing well without any signs and symptoms of infection. However, some nerve pain persisted and 600 mg of Gabapentin was prescribed. Lumbar spine X-rays will again be collected in a year.

3. Discussion

The current case report describes a robotic-assisted lateral interbody fusion through a PTP approach for the treatment of lumbar degenerative scoliosis, L4–5 pseudarthrosis, and resulting L5-S1 adjacent segment disease. No intraoperative or postoperative complications were reported, and patient symptoms were found to improve at two-month follow-up.

At present, LLIF is an established, safe, and effective approach that is commonly used to treat a wide range of degenerative spinal pathologies and deformities [20]. As a MIS technique, it can provide benefits including reduced blood loss, shortened operative duration and hospitalization, reduced posterior muscle damage, and faster recovery time [20]. Additionally, LLIF has gained popularity because of its unique procedural advantages: compared to other posterior techniques, its strengths include the use of an indirect decompression coupled with a posterior fixation that confers significant stability to the spinal column. More specifically, this stability is associated with the wider cages used in LLIF and the superior gain of segmental lordosis which it provides [20]. Despite the success and advantages of the LLIF, it comes with its own set of limitations as only small improvements in segmental lordosis can be obtained and postoperative neurological complications have been reported [20]. Additionally, there is always room for improvement and/or circumstances for which an alternative technique might be indicated. Recently, one such technique, the PTP approach, has emerged as an alternative to LLIF for the surgical treatment of spinopelvic alignment disorders. This technique was devised with the understanding that decreased segmental lordosis exerts negative effects on the process of decompensation following corrective surgery. These drawbacks, coupled with the findings that cage angle and positioning, performance of posterior osteotomies, and anterior longitudinal ligament rupture are each associated with segmental lordosis after interbody fusion, pointed

to the need for a technique involving a positional change that could optimize each of these factors: the PTP approach [20].

In the PTP approach, the patient is placed in the prone decubitus position over a Jackson and/or frame-type table in such a manner that the lower trunk and legs are extended and the patient is secured at the chest and hips, allowing the abdomen to relax and hang freely [20]. In this prone position, the standard lateral approach is used to gain access to the retroperitoneal space, and once the space is reached, the surgeon can use their finger to place a dilator – paired with triggered EMG feedback – over the psoas muscle. Once placed, the dilator-EMG feedback system can be used to navigate in the transpsoas plane and anchor to the spine using an expandable retractor placed laterally orthogonal to the spinal column. Subsequently, an anterior retractor blade is used to retract the anterior-most tissues in the forward direction, after which the disk is prepared in the traditional manner. In order to yield full release of the disk, a Cobb elevator will be placed through the superior, inferior, and contralateral annulus. After trial and error selecting for an implant size suitable for the patient's disk space, the cage is placed after which the retractor is removed and layered closure is obtained. Furthermore, in the event that they are indicated, direct decompression and/or posterior fixation can be performed with the patient already in the proper, prone position [20].

In 2019, Miyazaki et al. compared postoperative L4–5 segmental lordosis among patients placed in the prone decubitus position on a Jackson table versus those placed on a four-poster type frame [16]. At 2 year follow up, they found that patients placed in the prone decubitus position during TLIF exhibited a significantly increased L4–5 segmental lordosis compared to those positioned for TLIF in the traditional manner. Although these results were promising, a related study repeating a similar assessment protocol found that there was no significant difference in segmental lordosis observed when patients were placed initially laterally and then prone [20]. This finding prompted formation of the hypothesis that the repositioning itself could alter the original biomechanics of the spine related to the interbody fusion performed prior to reposition. Thus, the PTP approach was partially born out of the desire to avoid repositioning during surgery.

The PTP approach has several benefits compared to other surgical techniques such as LLIF, which are commonly used to treat lumbosacral disorders. First, the PTP approach avoids flip time, as it is a single-

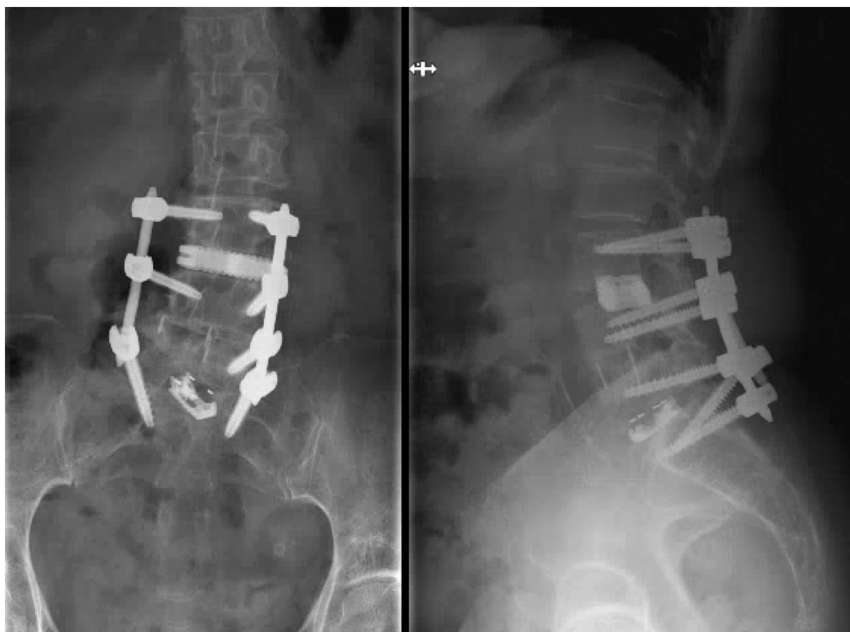


Fig. 3. Anteroposterior (left) and lateral (right) scoliosis radiographs demonstrating 2-month post-op pedicle screws at L3, L4, L5 and the sacrum and anterior interbody cage at L3/L4, L4/L5, L5/S1.

position surgery. At the same time, it allows for prone patient positioning, allowing for a familiar, common, and straightforward procedure that can be done either sitting or standing. Importantly, increased lordosis gains are achieved via the prone positional effect during the PTP approach compared to alternative approaches, including LLIF [4,12,19]. At least some of these effects may result from the lordotic curvature provided by the presence of a cushion underlying the iliac crest in the prone position [20].

Further, the PTP approach allots the surgeon the advantages of lateral interbody work, such as MIS interbody approaches, while accommodating concomitant posterior procedures, including pedicle fixation, decompression, and releases. However, despite all of these advantages, the PTP approach does not eliminate all risks of nervous system complications. To minimize the risk of neurological injury, triggered EMG should be utilized to gain safe transpsoas access and saphenous SSEP to monitor the femoral nerve during surgery [5,15,25].

Furthermore, prone positioning easily accommodates the use of intraoperative robotic guidance, which greatly facilitates interventions in both the lateral and posterior dimensions. Robotic spine surgery and computer-assisted navigation allow for the implementation of real-time guidance and visualization of the comprehensive three-dimensional surgical space [8,18]. In addition, a 2019 review conducted by Stull et al. evaluated the role of robotic guidance in MIS spine surgery, demonstrating its ability to improve the accuracy of pedicle screw placement [9,24], reduced blood loss [10,24], and reduced hospital LOS compared to freehand techniques. These advantages, paired with the previously described advantages of the PTP approach, greatly facilitate surgical intervention in complex cases, such as the one described in this case report.

3.1. Limitations

This study is not without limitations. Primarily, the current case report includes a single unique and complex patient, and future studies should include a large clinical series of patients with adequate follow-up to confirm the present findings. In addition, the quantity and quality of patient data included in this study was subject to the quality of notes documented during the patient's hospital stay.

4. Conclusion

In this case report, we describe an elderly patient with degenerative scoliosis, pseudarthrosis, and adjacent segment disease who received robotic-guided PTP lumbar re-fusion. The patient did not experience complications intraoperatively or postoperatively, with two-month follow-up. Robotic-guided lateral interbody fusion through the PTP approach is a safe and effective technique, even in uniquely complicated cases.

Provenance and peer review

Not commissioned, externally peer-reviewed.

Consent

Written informed consent was obtained from the patient for publication of this case report and accompanying images. A copy of the written consent is available for review by the Editor-in-Chief of this journal on request.

Ethical approval

This study was conducted in accordance with institutional and federal regulations under Institutional Review Board (IRB: 201607).

Funding

None.

Guarantor

Dr. William R. Taylor.

Research registration number

NA.

Credit authorship contribution statement

Shane Shahrestani: Data curation, Investigation, Writing - original draft, Writing - review & editing.

Nolan J. Brown: Data curation, Investigation, Writing - original draft, Writing - review & editing.

Nischal Acharya: Data curation, Investigation, Writing - review & editing.

Luis Daniel Diaz-Aguilar: Supervision, Writing - review & editing.

Martin H. Pham: Supervision, Writing - review & editing.

William R. Taylor: Conceptualization, Investigation, Methodology, Supervision, Validation, Writing - review & editing.

Declaration of competing interest

There are no conflicts of interest or disclosures of funding for this study.

References

- [1] R.A. Agha, T. Franchi, C. Sohrabi, G. Mathew, A. Kerwan, SCARE Group, The SCARE 2020 guideline: updating consensus Surgical CAse REport (SCARE) guidelines, *Int. J. Surg.* 84 (2020 Dec) 226–230, <https://doi.org/10.1016/j.ijsu.2020.10.034>. Epub 2020 Nov 9. PMID: 33181358.
- [3] A. Kelly, A. Younus, Adult degenerative scoliosis – a literature review, *Interdiscip. Neurosurg.* (06/2020) 20.
- [4] P.L. Benfanti, A.E. Geissele, The effect of intraoperative hip position on maintenance of lumbar lordosis: a radiographic study of anesthetized patients and unanesthetized volunteers on the Wilson frame, *Spine* 22 (1997) 2299–2303.
- [5] I. Cheng, M.R. Briseño, R.T. Arrigo, N. Bains, S. Ravi, A. Tran, Outcomes of two different techniques using the lateral approach for lumbar interbody arthrodesis, *Glob. Spine J.* 5 (2015) 308–314.
- [6] K.-J. Cho, Y.-T. Kim, S.-H. Shin, S.-I. Suk, Surgical treatment of adult degenerative scoliosis, *Asian Spine J.* 8 (2014) 371–381.
- [7] K.-J. Cho, S.-I. Suk, S.-R. Park, J.-H. Kim, S.-S. Kim, T.-J. Lee, et al., Short fusion versus long fusion for degenerative lumbar scoliosis, *Eur. Spine J.* 17 (2008) 650–656.
- [8] M. D'Souza, J. Gendreau, A. Feng, L.H. Kim, A.L. Ho, A. Veeravagu, Robotic-assisted spine surgery: history, efficacy, cost, and future trends, *Robot. Surg.* 6 (2019) 9–23.
- [9] Y. Fan, J.P. Du, J.J. Liu, J.N. Zhang, H.H. Qiao, S.C. Liu, et al., Accuracy of pedicle screw placement comparing robot-assisted technology and the free-hand with fluoroscopy-guided method in spine surgery: an updated meta-analysis, *Medicine* 97 (2018), e10970.
- [10] Y. Fan, J. Du, J. Zhang, S. Liu, X. Xue, Y. Huang, et al., Comparison of accuracy of pedicle screw insertion among 4 guided Technologies in Spine Surgery, *Med. Sci. Monit.* 23 (2017) 5960–5968.
- [11] S.D. Glassman, K. Bridwell, J.R. Dimar, W. Horton, S. Berven, F. Schwab, The impact of positive sagittal balance in adult spinal deformity, *Spine* 30 (2005) 2024–2029.
- [12] K. Harimaya, L.G. Lenke, T. Mishiro, K.H. Bridwell, L.A. Koester, B.A. Sides, Increasing lumbar lordosis of adult spinal deformity patients via intraoperative prone positioning, *Spine* 34 (2009) 2406–2412.
- [13] H.N. Herkowitz, Degenerative lumbar spondylolisthesis: evolution of surgical management, *Spine J.* 9 (2009) 605–606.
- [14] S. Kotwal, M. Pumberger, A. Hughes, F. Girardi, Degenerative scoliosis: a review, *HSS J.* 7 (2011) 257–264.
- [15] J.A. Lehmen, E.J. Gerber, MIS lateral spine surgery: a systematic literature review of complications, outcomes, and economics, *Eur. Spine J.* 24 (Suppl. 3) (2015) 287–313.
- [16] M. Miyazaki, T. Ishihara, T. Abe, S. Kanezaki, N. Notani, M. Kataoka, et al., Effect of intraoperative position in single-level transforaminal lumbar interbody fusion at the L4/5 level on segmental and overall lumbar lordosis in patients with lumbar degenerative disease, *Medicine* 98 (2019), e17316.

- [17] R.J. Mobbs, K. Phan, G. Malham, K. Seex, P.J. Rao, Lumbar interbody fusion: techniques, indications and comparison of interbody fusion options including PLIF, TLIF, MI-TLIF, OLIF/ATP, LLIF and ALIF, *J. Spine Surg.* 1 (2015) 2–18.
- [18] S.C. Overley, S.K. Cho, A.I. Mehta, P.M. Arnold, Navigation and robotics in spinal surgery: where are we now? *Neurosurgery* 80 (2017) S86–S99.
- [19] M.D. Peterson, L.M. Nelson, A.C. McManus, R.P. Jackson, The effect of operative position on lumbar lordosis. A radiographic study of patients under anesthesia in the prone and 90–90 positions, *Spine* 20 (1995) 1419–1424.
- [20] L. Pimenta, R. Amaral, W. Taylor, A. Tohmeh, G. Pokorny, R. Rodrigues, et al., The prone transpoas technique: preliminary radiographic results of a multicenter experience, *Eur. Spine J.* (2020) 108–113, <https://doi.org/10.1007/s00586-020-06471-y>, 32472346.
- [21] A. Ploumis, E.E. Transfledt, F. Denis, Degenerative lumbar scoliosis associated with spinal stenosis, *Spine J.* 7 (2007) 428–436.
- [22] J.W. Pritchett, D.T. Bortel, Degenerative symptomatic lumbar scoliosis, *Spine* 18 (1993) 700–703.
- [23] M. Sirvanci, M. Bhatia, K.A. Ganiyusufoglu, C. Duran, M. Tezer, C. Ozturk, et al., Degenerative lumbar spinal stenosis: correlation with Oswestry disability index and MR imaging, *Eur. Spine J.* 17 (2008) 679–685.
- [24] J.D. Stull, J.J. Mangan, A.R. Vaccaro, G.D. Schroeder, Robotic guidance in minimally invasive spine surgery: a review of recent literature and commentary on a developing technology, *Curr. Rev. Musculoskelet. Med.* 12 (2019) 245–251.
- [25] A.G. Tohmeh, W.B. Rodgers, M.D. Peterson, Dynamically evoked, discrete-threshold electromyography in the extreme lateral interbody fusion approach, *J. Neurosurg. Spine* 14 (2011) 31–37.
- [26] D.S. Xu, C.T. Walker, J. Godzik, J.D. Turner, W. Smith, J.S. Uribe, Minimally invasive anterior, lateral, and oblique lumbar interbody fusion: a literature review, *Ann. Transl. Med.* 6 (2018) 104.