

## Phase II Trial Using a Combination of Oxaliplatin, Capecitabine, and Celecoxib with Concurrent Radiation for Newly Diagnosed Resectable Rectal Cancer

EMILIO P. ARAUJO-MINO,<sup>a</sup> YEHUDA Z. PATT,<sup>b</sup> CRISTINA MURRAY-KREZAN,<sup>b</sup> JOSHUA A. HANSON,<sup>b</sup> PRANSHU BANSAL<sup>1b</sup>,<sup>b</sup> BEN J. LIEM,<sup>b</sup> ASHWANI RAJPUT,<sup>b</sup> M. HOUMAN FEKRAZAD,<sup>c</sup> GLENORY HEYWOOD,<sup>b</sup> FA CHYI LEE<sup>d</sup>

<sup>a</sup>Kymera Independent Physicians, Roswell, New Mexico, USA; <sup>b</sup>University of New Mexico, Albuquerque, New Mexico, USA; <sup>c</sup>City of Hope Cancer Center, Duarte, California, USA; <sup>d</sup>Santa Clara Valley Medical Center, San Jose, California, USA

### TRIAL INFORMATION

- **ClinicalTrials.gov Identifier:** NCT00250835
- **Sponsor(s):** New Mexico Cancer Center Alliance
- **Principal Investigators:** Emilio P. Araujo-Mino, Yehuda Z. Patt
- **IRB Approved:** Yes

### LESSONS LEARNED

- Colorectal cancers exhibit a high level of cyclooxygenase-2 (COX-2) expression with strong preclinical rationale for improved clinical outcomes with COX-2 inhibition. Celecoxib is a COX-2 inhibitor and we have shown that it can be safely combined with capecitabine and oxaliplatin as part of neoadjuvant treatment with radiation therapy (RT) in rectal cancer.
- There was a significant improvement in skin toxicity with this combination as compared with historical data. Considering the field has moved on to single-agent capecitabine, we believe future trials with capecitabine and celecoxib hold potential.

### ABSTRACT

**Background.** Improved survival is seen among patients with rectal cancer who achieve pathologic complete response (pCR) after neoadjuvant therapy. Cyclooxygenase-2 (COX-2) expression is increased in gastrointestinal malignancies and it may serve as a target to enhance pathologic response. A trial combining chemoradiation and COX-2 inhibition was conducted to evaluate the pCR rate, surgical outcomes, survival, and treatment toxicity.

**Methods.** Patients with resectable (T3-4, N1-2) rectal cancer within 12 cm of the anal verge were included in this phase II clinical trial. The neoadjuvant treatment consisted of capecitabine 850 mg/m<sup>2</sup> b.i.d. Monday through Friday for 5 weeks, weekly oxaliplatin 50 mg/m<sup>2</sup> intravenous (IV), celecoxib 200 mg b.i.d. daily, along with concurrent 45 gray radiation therapy in 25 fractions.

**Results.** Thirty-two patients were included in the final analysis. The primary endpoint was pCR: 31% (95% confidence interval [CI]: 16%–50%). Secondary endpoints were surgical downstaging (SD): 75% (95% CI: 57%–89%) and sphincter-sparing surgery (SSS): 56% (95% CI: 38%–74%). Common grade >3 toxicities were diarrhea and abnormal liver function tests (9% each). Grade 0 and 1 toxicities included radiation

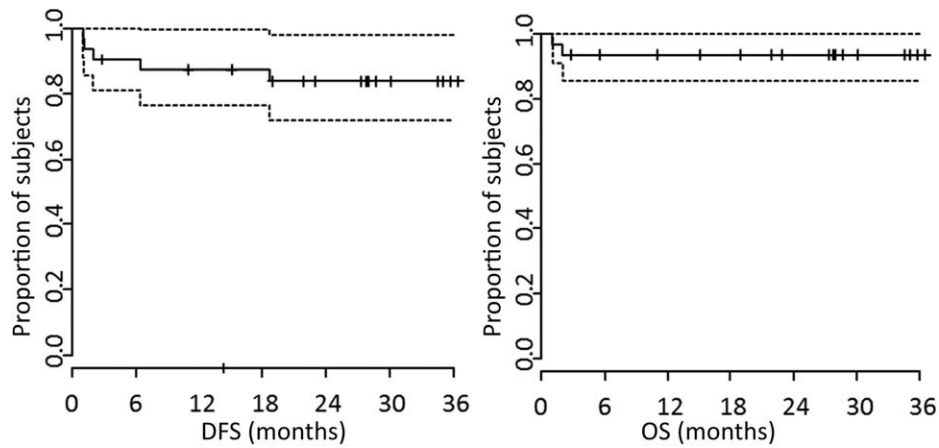
dermatitis (59% and 34%, respectively) and proctitis (63% and 28%, respectively). At 3 years, disease-free survival and overall survival (OS) were 84% (95% CI: 65%–93%) and 94% (95% CI: 77%–98%), respectively.

**Conclusion.** Chemoradiation with celecoxib in rectal cancer was well tolerated and demonstrated high rates of pCR, SD, and SSS. Improvement in skin toxicity (34% grade 1 and no grade 3/4) as compared with historical results (43%–78% grade 3/4) seems to be a significant improvement with addition of celecoxib to neoadjuvant chemotherapy. *The Oncologist* 2018;23:2–e5

### DISCUSSION

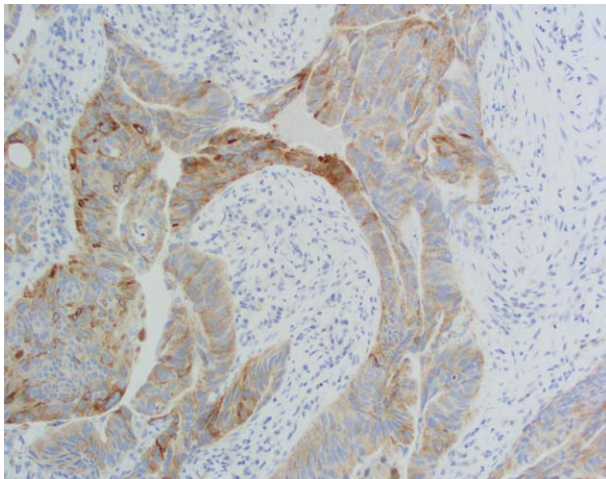
The management of localized rectal cancer has evolved into a multidisciplinary effort that requires medical, radiation, and surgical oncologists to elucidate an optimal treatment plan. Combination of chemo and radiation therapy is currently the standard of care for patients with localized rectal cancer. This combination has been associated with a pCR rate of 15%–20%, SSS rate of 39%–44%, and SD rate of 40%–80%. Grade 3 or higher radiation dermatitis at 43%–78% and proctitis at 2%–39% have been previously reported.

Correspondence: Pranshu Bansal, M.D., University of New Mexico, 1201 Camino de Salud, Albuquerque, New Mexico 87110, USA. Telephone: 505-272-4946; e-mail: pranshu.doc@gmail.com; and Emilio P. Araujo-Mino, M.D., Department of Medical Oncology, Kymera Independent Physicians, 400 Military Heights Place, Roswell, New Mexico 88201, USA. Telephone: 575-627-9500; e-mail: emilio.ecu@gmail.com Received August 16, 2017; accepted for publication September 13, 2017; published Online First on November 20, 2017. ©AlphaMed Press; the data published online to support this summary is the property of the authors. <http://dx.doi.org/10.1634/theoncologist.2017-0474>

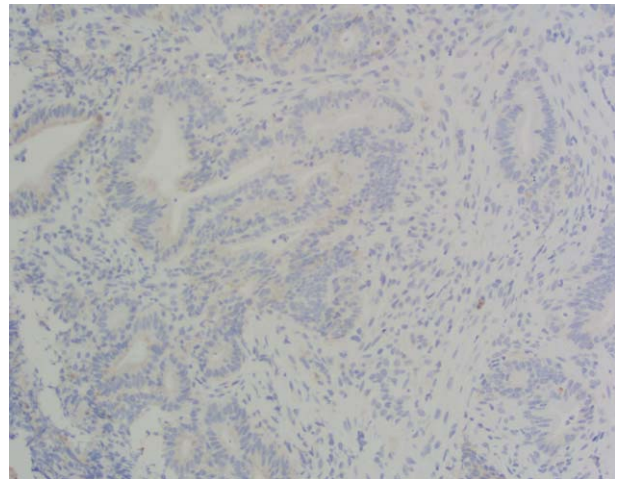


**Figure 1.** Survival analysis. Kaplan-Meier survival curve for the entire group (black line) and the upper and lower 95% confidence intervals (dotted lines).

Abbreviations: DFS, disease-free survival; OS, overall survival.



**Figure 2.** Cyclooxygenase-2 positive on immunohistochemistry.



**Figure 3.** Cyclooxygenase-2 negative on immunohistochemistry.

At the inception of this trial in 2005, 5-fluorouracil (5-FU) and oxaliplatin in combination with radiation therapy (RT) were standard of care in the neoadjuvant setting for localized rectal cancer. Over the last few years, the utility of adding oxaliplatin to 5-FU/capecitabine has been called into question and multiple well-designed prospective trials have shown that 5-FU or capecitabine (oral prodrug for 5-FU) alone with RT is as efficacious with improved tolerability.

Based on robust preclinical evidence of increased COX-2 expression in rectal cancer and multiple preclinical studies showing improved radiation response, decreased microvessel density, inhibition of angiogenesis and metastasis with COX-2 inhibition, we designed this trial to potentially improve upon pCR results and assess tolerability of the combination of celecoxib with standard of care chemotherapy and RT. Our trial noted a pCR rate of 31%, SD rate of 75%, and SSS rate of 56%, and very good treatment tolerance as evidenced by absence of grade 3 dermatitis and lower incidence of grade 3 proctitis (3%) as compared with historical data.

Another phase II trial of 35 patients treated rectal cancer patients with 5-FU plus celecoxib 400 MG BID versus 5-FU plus

placebo in the neoadjuvant setting. This trial showed an improved pCR rate in the celecoxib group, although results were not statistically significant (pCR 39% vs. 29%); and better response defined as good regression + pCR (61% vs. 35%;  $p = .13$  for both). Authors concluded a trend toward better response and improvement in treatment-related pain in the experimental arm.

From our encouraging response data and toxicity results, along with other recent trials reporting futility of adding oxaliplatin, there exists a potential to use only 5-FU/capecitabine in combination with celecoxib in future trials. This combination holds potential in improving toxicity further when compared with 5-FU and RT while preserving or possibly improving response rates.

Reported concerns of COX-2 inhibition such as peptic ulcer disease and ischemic cardiovascular diseases occur with longer-term administration of these drugs, and in our study, there were no such side effects observed.

The limitations of this study were slow accrual rate over 7 years, addition of oxaliplatin, which has since shown to be inactive in this setting, relatively small sample size, and lack of a comparator arm.

TRIAL INFORMATION	
Disease	Colorectal cancer
Stage of Disease/Treatment	Neo-adjuvant
Prior Therapy	None
Type of Study - 1	Phase II
Type of Study - 2	Single arm
Primary Endpoint	pCR
Secondary Endpoint	Toxicity
Secondary Endpoint	SD
Secondary Endpoint	Incidence of SSS
Secondary Endpoint	Progression-free survival
Secondary Endpoint	OS
Secondary Endpoint	Pelvic recurrence
<b>Additional Details of Endpoints or Study Design</b>	
<p>This study used a Simon two-stage optimum design so that the study could be terminated early for futility. In stage I of this design, we enrolled 19 patients, and if 3 or fewer achieved pCR (<math>\leq 15\%</math> recurrence rate (RR)), with a probability of 0.68, the study would be terminated. If 4 or more patients achieved pCR, the study would enroll an additional 36 patients, for a total of 55, to achieve an 80% power to detect a pCR of <math>\geq 30\%</math> at one-sided 5% level of significance. If 12 or fewer patients achieved pCR over the two stages, futility would be declared.</p> <p>The study was terminated without completing accrual; 38 patients were enrolled, of whom 32 were included in final analysis.</p>	
Investigator's Analysis	Active and should be pursued further

DRUG INFORMATION FOR PHASE II STUDY	
<b>Drug 1</b>	
Generic/Working name	Oxaliplatin
Trade name	Eloxatin
Company name	Pfizer
Drug type	Chemotherapy
Drug class	Platinum compound
Dose	50 milligrams (mg) per squared meter (m <sup>2</sup> )
Route	IV
Schedule of administration	Weekly
<b>Drug 2</b>	
Generic/Working name	Capecitabine
Trade name	Xeloda
Company name	Genentech
Drug type	Other
Drug class	Antimetabolite
Dose	850 mg/m <sup>2</sup>
Route	p.o.
Schedule of administration	b.i.d. Monday through Friday
<b>Drug 3</b>	
Generic/Working name	Celecoxib
Trade name	Celebrex
Company name	Pfizer
Drug type	COX-2 inhibitor
Drug class	Anti-inflammatory
Dose	200 mg per flat dose
Route	p.o.
Schedule of administration	b.i.d. daily without interruption

PATIENT CHARACTERISTICS FOR PHASE II STUDY	
Number of Patients, Male	18
Number of Patients, Female	14
Stage	Stage IIa: 8 Stage IIb: 22 Stage III: 2
Age	Median (range): 52.7 years ( $\pm 12.7$ )
Number of Prior Systemic Therapies	Median (range): 0
Performance Status: ECOG	Patients were required to have ECOG performance status 0–2

Patient Characteristics	<i>n</i>
<b>Ethnicity</b>	
Hispanic	17
White	12
Asian	1
Native American	1
Not reported	1
<b>TNM staging</b>	
T3	30
T4	2
N0	7
N1	16
N2	8
Mean CEA levels	7.4 $\pm$ 11.4
Mean BMI mg/m <sup>2</sup>	27.1 $\pm$ 5.2

Abbreviations: BMI, basal metabolic index; CEA, carcino embryonic antigen; TNM, tumor, node, metastasis.

PRIMARY ASSESSMENT METHOD FOR PHASE II STUDY	
Title	Total Patient Population
Number of Patients Screened	80
Number of Patients Enrolled	38
Number of Patients Evaluable for Toxicity	32
Number of Patients Evaluated for Efficacy	32
Evaluation Method	pCR on surgery
Response Assessment CR	<i>n</i> = 10 (31%)

PHASE II STUDY ADVERSE EVENTS							
Name	All Dose Levels, All Cycles						All grades
	NC/NA	1	2	3	4	5	
Dermatitis radiation	59%	41%	0%	0%	0%	0%	41%
Peripheral sensory neuropathy	78%	22%	0%	0%	0%	0%	22%
Infections and infestations—Other, specify	88%	3%	0%	9%	0%	0%	12%
Lymphocyte count decreased	88%	3%	0%	9%	0%	0%	12%
Fatigue	59%	38%	0%	3%	0%	0%	41%
Nausea	59%	38%	0%	3%	0%	0%	41%
Abdominal pain	66%	28%	0%	6%	0%	0%	34%
Aspartate aminotransferase increased	78%	13%	0%	9%	0%	0%	22%
Alanine aminotransferase increased	78%	13%	0%	9%	0%	0%	22%

Proctitis	63%	34%	0%	3%	0%	0%	37%
Dehydration	88%	6%	0%	6%	0%	0%	12%
Diarrhea	44%	47%	0%	9%	0%	0%	56%

Abbreviation: NC/NA, no change from baseline/no adverse event.

## ASSESSMENT, ANALYSIS, AND DISCUSSION

### Completion

Study terminated before completion

### Terminated Reason

Did not fully accrue

### Investigator's Assessment

Active and should be pursued further

Approximately 135,430 new cases of colorectal cancer in the U.S. are estimated for 2017 (approximately 95,520 colon and 39,910 rectal cancers), accounting for 8% of all new cancer cases following breast, lung, and prostate cancers [1]. The 5-year probability of death from loco-regional rectal cancer is 44%, and local recurrence rate can be up to 40% [2, 3]. Therefore, it is important to explore treatment strategies that can affect survival and improve treatment toxicity profile for rectal cancer.

The landmark German Rectal Cancer study group CAO/ARO/AIO-94 identified improved local control with preoperative versus postoperative chemoradiation [4]. Updated results from the same study showed the degree of tumor regression and the rate of pathologic complete response (pCR) were associated with improved metastasis-free and disease-free survival as well as a lower local recurrence rate. Therefore, pCR is considered an acceptable endpoint for phase II studies.

This study was a nonrandomized, single-center, single-arm, phase II clinical trial that evaluated the efficacy of adding celecoxib to standard concurrent neoadjuvant chemoradiation for surgically resectable rectal cancer patients. Enrollment of patients started in 2005, with accrual completing in 2012. The statistical design allowed enrollment of patients after the first stage of the study; however, further accrual was low and the study was closed without reaching the expected 55 patients. A data cutoff for survival analysis was done in February 2015. A total of 38 patients were enrolled; 2 withdrew consent before starting therapy, 3 became ineligible prior to starting therapy, and 1 observation had missing data for analysis. There were 32 patients available for efficacy and toxicity analysis.

The management of rectal cancer has evolved into a multidisciplinary effort that requires medical, radiation, and surgical oncologists to elucidate an optimal treatment plan. The standard of care currently is the combination of chemotherapy and radiation. Chemoradiation has been associated with a pCR rate of 15%–20%, sphincter-sparing surgery (SSS) rate of 39%–44%, surgical downstaging (SD) rate of 40%–80%, incidence of grade 3 or more radiation dermatitis of 43%–78%, and an incidence of radiation proctitis of 2%–39% [5–10]. To improve upon these results, we decided to add a cyclooxygenase-2 (COX-2) inhibitor (celecoxib) to the then-established treatment regimen of 5-FU, oxaliplatin, and radiation. The rationale of adding celecoxib was based on robust preclinical evidence of increased COX-2 expression in rectal cancer and multiple preclinical studies showing improved radiation response, decreased tumor microvessel density, and inhibition of metastasis and angiogenesis with COX-2 inhibition [11–13]. Our trial noted a pCR rate

of 31%, SD rate of 75%, and SSS rate of 56%, and the treatment was well tolerated as evidenced by absence of grade 3 dermatitis and low incidence of grade 3 proctitis (3%) (Table 2).

When this protocol was initiated in 2005, the addition of oxaliplatin to fluoropyrimidines and radiation therapy seemed promising [14, 15]. However, more recent large prospective trials asserted that the addition of oxaliplatin was actually associated with increased toxicity without significant improvement in pCR when compared with capecitabine alone [16–18].

The addition of celecoxib may have indeed improved pCR and resulted in a more favorable toxicity profile. Benefit from celecoxib may have been related to an enhanced radiation-induced apoptosis or direct inhibition of tumor neovascularization when a COX-2 inhibitor was added. Another phase II trial of 5-FU with celecoxib 400 MG BID versus placebo in the neoadjuvant treatment of rectal cancer showed an improved pCR rate in the celecoxib group, but was not statistically significant (pCR 39% vs. 29%); and better response (good regression + pCR: 61% vs. 35%;  $p = .13$  for both) [19].

Secondary endpoints of this trial were to assess the rates of SSS and SD. We observed SSS rate of 56% and SD rate of 75%, as compared with the reported rates of SD at 54% (ranging from 40% to 80%) and SSS at 39%–44% [7, 8, 17]. Disease-free survival and overall survival rates at 3 years were 84% (95% confidence interval [CI]: 65%–93%) and 94% (95% CI: 77%–98%), respectively (Fig. 1).

Issues concerning toxicity of COX-2 inhibitors such as peptic ulcer disease and ischaemic heart disease have been observed only with long-term administration [20, 21]. There were no reported cases of either of these two complications in our study. The good tolerability was likely due to the relatively short period and low dose of the COX-2 inhibitor. Incidence of proctitis and dermatitis was 37% and 13%, respectively, with only one patient experiencing grade 3 proctitis; historically, grade 3 or 4 proctitis has been reported at 43%–78% and dermatitis at 2%–39% [10]. Also, as suggested by Zhang et al., it is possible that improved tolerance of capecitabine among our patients was possibly related to the use of celecoxib [22].

We also performed COX-2 expression analysis (Figs. 2, 3) in a subset of patients (18/32). However, none of the associations tested, namely pCR, SD, SSS, and dermatitis and proctitis incidence, were related to the degree of tumor expression of COX-2 (Table 1). However, it was remarkable that pretreatment COX-2 expression remained 80% unchanged in pre- versus post-radiation among nonresponders. Prior studies have suggested an increase in COX-2 expression after radiation, whereas others

suggest less COX-2 expression with celecoxib [23, 24]. In our trial, celecoxib did not seem to affect COX-2 expression but the improved results may be related to COX-2 enzyme function and downstream signaling.

The limitations of this study were slow accrual rate over 7 years, where most of the patients came from a single center, with a 40% enrollment/screen ratio in a less populous state. The sample size is limited to 32 patients and a larger randomized study would be needed to better determine the effectiveness of this combination. Future studies should focus on combination of 5-FU/capecitabine and celecoxib versus 5-FU plus placebo in combination RT in neoadjuvant setting. Cyclooxygenase-2 staining has not been standardized and variability in reproducibility may be present; although we were only able to test COX-2 expression in 18 patients, we did not find it to be a predictable biomarker.

Most of the recent improvements in rectal cancer management have been in the metastatic setting, especially with the advent of immunotherapy in microsatellite instability-high patients. This trial showed an inexpensive drug such as celecoxib was well tolerated and improved clinical outcomes. We believe combination of 5-FU and celecoxib holds promise in treatment of localized rectal cancer. Our main limitation was slow accrual; a multi-institutional, randomized study may help mitigate this limitation, and we would like to pursue this in the future.

#### DISCLOSURES

**Houman Mahammad Fekrazad:** Genentech, Onxy Pharmaceuticals, Inc. (H). The other authors indicated no financial relationships.

(C/A) Consulting/advisory relationship; (RF) Research funding; (E) Employment; (ET) Expert testimony; (H) Honoraria received; (OI) Ownership interests; (IP) Intellectual property rights/inventor/patent holder; (SAB) Scientific advisory board

#### REFERENCES

- National Cancer Institute. Cancer Topics: Colon and Rectal Cancer. Available at <http://www.cancer.gov/cancertopics/types/colon-and-rectal>. Accessed November 17, 2014.
- Edwards BK, Noone AM, Mariotto AB et al. Annual report to the nation on the status of cancer, 1975–2010, featuring prevalence of comorbidity and impact on survival among persons with lung, colorectal, breast, or prostate cancer. *Cancer* 2014;120:1290–1314.
- Aklilu M, Eng C. The current landscape of locally advanced rectal cancer. *Nat Rev Clin Oncol* 2011;8:649–659.
- Sauer R, Liersch T, Merkel S et al. Preoperative versus postoperative chemoradiotherapy for locally advanced rectal cancer: Results of the German CAO/AIO/AIO-94 randomized phase III trial after a median follow-up of 11 years. *J Clin Oncol* 2012;30:1926–1933.
- Lawrence TS, Haffty BG, Harris JR. Milestones in the use of combined-modality radiation therapy and chemotherapy. *J Clin Oncol* 2014;32:1173–1179.
- Francois Y, Nemoz CJ, Baulieux J et al. Influence of the interval between preoperative radiation therapy and surgery on downstaging and on the rate of sphincter-sparing surgery for rectal cancer: The Lyon R90-01 randomized trial. *J Clin Oncol* 1999;17:2396.
- Sauer R, Becker H, Hohenberger W et al. Preoperative versus postoperative chemoradiotherapy for rectal cancer. *N Engl J Med* 2004;351:1731–1740.
- Valentini V, Coco C, Picciocchi A et al. Does downstaging predict improved outcome after preoperative chemoradiation for extraperitoneal locally advanced rectal cancer? A long-term analysis of 165 patients. *Int J Radiat Oncol Biol Phys* 2002;53:664–674.
- Koukourakis GV, Zacharias G, Tsalafoutas J et al. Capecitabine for locally advanced and metastatic colorectal cancer: A review. *World J Gastrointest Oncol* 2010;2:311–321.
- Do NL, Nagle D, Poylin VY. Radiation proctitis: Current strategies in management. *Gastroenterol Res Pract* 2011;2011:917941.
- Xiong B, Sun TJ, Yuan HY et al. Cyclooxygenase-2 expression and angiogenesis in colorectal cancer. *World J Gastroenterol* 2003;9:1237–1240.
- Fenwick SW, Toogood GJ, Lodge JP et al. The effect of the selective cyclooxygenase-2 inhibitor rofecoxib on human colorectal cancer liver metastases. *Gastroenterology* 2003;125:716–729.
- Sheng H, Shao J, Kirkland SC et al. Inhibition of human colon cancer cell growth by selective inhibition of cyclooxygenase-2. *J Clin Invest* 1997;99:2254–2259.
- Gérard JP, Chapet O, Nemoz C et al. Preoperative concurrent chemoradiotherapy in locally advanced rectal cancer with high-dose radiation and oxaliplatin-containing regimen: The Lyon R0-04 phase II trial. *J Clin Oncol* 2003;21:1119–1124.
- Carraro S, Roca EL, Cartelli C, et al. Radiochemotherapy with short daily infusion of low-dose oxaliplatin, leucovorin, and 5-FU in T3-T4 unresectable rectal cancer: A phase II IATGI study. *Int J Radiat Oncol Biol Phys* 2002;54:397–402.
- O'Connell MJ, Colangelo LH, Beart RW et al. Capecitabine and oxaliplatin in the preoperative multimodality treatment of rectal cancer: Surgical end points from National Surgical Adjuvant Breast and Bowel Project trial R-04. *J Clin Oncol* 2014;32:1927–1934.
- Aschele C, Cionini L, Lonardi S et al. Primary tumor response to preoperative chemoradiation with or without oxaliplatin in locally advanced rectal cancer: Pathologic results of the STAR-01 randomized phase III trial. *J Clin Oncol* 2011;29:2773–2780.
- Gérard JP, Azria D, Gourgou-Bourgade S et al. Clinical outcome of the ACCORD 12/0405 PRODIGE 2 randomized trial in rectal cancer. *J Clin Oncol* 2012;30:4558–4565.
- Debuquoy A, Roels S, Goethals L et al. Double blind randomized phase II study with radiation + 5-fluorouracil + /-celecoxib for resectable rectal cancer. *Radiother Oncol* 2009;93:273–278.
- Andersohn F, Suissa S, Garbe E. Use of first- and second-generation cyclooxygenase-2-selective nonsteroidal antiinflammatory drugs and risk of acute myocardial infarction. *Circulation* 2006;113:1950–1957.
- Bresalier RS, Sandler RS, Quan H et al. Cardiovascular events associated with rofecoxib in a colorectal adenoma chemoprevention trial. *N Engl J Med* 2005;352:1092–1102.
- Zhang RX, Wu XJ, Wan DS et al. Celecoxib can prevent capecitabine-related hand-foot syndrome in stage II and III colorectal cancer patients: Result of a single-center, prospective randomized phase III trial. *Ann Oncol* 2012;23:1348–1353.
- Choy H, Milas L. Enhancing radiotherapy with cyclooxygenase-2 enzyme inhibitors: A rational advance? *J Natl Cancer Inst* 2003;95:1440–1452.
- Wang ZL, Fan ZQ, Jiang HD et al. Selective Cox-2 inhibitor celecoxib induces epithelial-mesenchymal transition in human lung cancer cells via activating MEK-ERK signaling. *Carcinogenesis* 2013;34:638–646.

## TABLES

**Table 1.** COX-2 immunohistochemistry status at diagnosis

Clinical variable	High expression n (%)	Low expression n (%)	p value <sup>a</sup>
pCR			.12
Yes	5 (36)	1 (25)	
No	9 (64)	3 (75)	
SD			0.92
Present	12 (86)	4 (100)	
None	2 (14)	0 (0)	
SSS			.16
Yes	11 (79)	1 (25)	
No	3 (21)	3 (75)	

<sup>a</sup>p value obtained from the Fisher's exact test.

Abbreviations: pCR, pathologic complete response; SD, surgical downstaging; SSS, sphincter-sparing surgery.

**Table 2.** Adverse events by grade in evaluable patients

Event	Grade 1–2 n (%)	Grade 3–4 n (%)
Diarrhea	15 (47)	3 (9)
Dehydration	2 (6)	2 (6)
Radiation proctitis	11 (34)	1 (3)
Abnormal liver function test	4 (13)	3 (9)
Abdominal pain	9 (28)	2 (6)
Nausea/vomiting	12 (37)	1 (3)
Constitutional	18 (57)	2 (6)
Lymphopenia	1 (3)	3 (9)
Infection	1 (3)	3 (6)
Cytopenia	7 (22)	0 (0)
Rectal bleeding	11 (34)	0 (0)
Neuropathy	7 (22)	0 (0)
Radiation dermatitis	13 (40)	0 (0)

[Click here to access other published clinical trials.](#)