

Utility of gastric ultrasound in evaluating *nil per os* status in a child

ABSTRACT

Although rare, the aspiration of gastric contents can lead to significant morbidity or even mortality in pediatric patients receiving anesthetic care. For elective cases, routine preoperative practices include the use of standard *nil per os* times to decrease the risk of aspiration. However, patients may fail to adhere to provided NPO guidelines or other patient factors may impact the efficacy of standard NPO times. Gastric point-of-care ultrasound provides information on the volume and quality of gastric contents and may allow improved patient management strategies. We present a 4-year-old patient who presented for bilateral myringotomy with tympanostomy tube insertion, who was found to have evidence of a full stomach during preoperative gastric ultrasound examination. The use of preoperative gastric point-of-care ultrasound in evaluating stomach contents and confirming NPO times is reviewed and its application to perioperative practice discussed.

Key words: Acid aspiration; full stomach; gastric ultrasound; point-of-care ultrasonography

Introduction


The aspiration of gastric contents is a rare yet potentially fatal consequence of anesthetic care with an incidence of 5.5 in 10,000 cases.^[1] Measures to decrease the incidence of and complications from aspiration include the use of standardized *nil per os* (NPO) times prior to elective procedures to ensure that the stomach is empty.^[2] However, patients may fail to adhere to these NPO requirements or other factors may affect gastric emptying thereby increasing the risk of aspiration. Point-of-care ultrasound (POCUS) has seen increased use in the perioperative arena for vascular access, cardiac and pulmonary examinations; and the evaluation of gastric contents.^[3] Gastric POCUS has been

useful to guide anesthetic management in evaluating NPO status prior to elective, urgent, and emergent surgery.^[4,5] Gastric POCUS can measure the quantity of fluid as well as assess its quality (liquid versus solid).^[6] This objective information may be used to supplement clinical information and guide clinical decisions regarding the timing of surgery, anesthetic induction techniques, and airway management strategies. We describe a 4-year-old patient who presented for bilateral myringotomy with tympanostomy tube insertion who was found to have evidence of a full stomach during preoperative gastric POCUS despite parental report of an adequate NPO time. The use of preoperative gastric POCUS

This is an open access journal, and articles are distributed under the terms of the Creative Commons Attribution-NonCommercial-ShareAlike 4.0 License, which allows others to remix, tweak, and build upon the work non-commercially, as long as appropriate credit is given and the new creations are licensed under the identical terms.

For reprints contact: reprints@medknow.com

How to cite this article: Munlemvo D, Moharir A, Yamaguchi Y, Khan S, Tobias JD. Utility of gastric ultrasound in evaluating *nil per os* status in a child. Saudi J Anaesth 2021;15:46-9.

Access this article online	
Website: www.saudija.org	Quick Response Code 
DOI: 10.4103/sja.SJA_702_20	

DOLLY MUNLEMVO¹, ALOK MOHARIR^{1,2}, YOSHIKAZU YAMAGUCHI³, SARAH KHAN^{1,2}, JOSEPH D. TOBIAS^{1,2}

¹Department of Anesthesiology and Pain Medicine, Nationwide Children's Hospital, ²Department of Anesthesiology and Pain Medicine, The Ohio State University College of Medicine, Columbus, OH, USA, ³Department of Anesthesiology, Yokohama Municipal Citizen's Hospital, Yokohama, Japan

Address for correspondence: Dr. Dolly Munlemvo, Department of Anesthesiology and Pain Medicine, Nationwide Children's Hospital, 700 Children's Drive, Columbus, OH 43205, USA. E-mail: dolly.munlemvo@nationwidechildrens.org

Submitted: 30-Jun-2020, **Accepted:** 30-Jun-2020, **Published:** 05-Jan-2021

in evaluating stomach contents is reviewed and its application to perioperative practices discussed.

Case Report

Review of this case and presentation in this format was in accordance with the guidelines of the Institutional Review Board of Nationwide Children's Hospital (Columbus, Ohio). A 4-year-old, 18.8 kilogram girl with a history of chronic bilateral serous otitis media with effusion presented for bilateral myringotomy with tympanostomy tube insertion. Her past medical history was significant for chronic serous otitis media and Wolff Parkinson-White syndrome. Her home medication regimen included only cetirizine, administered as needed. By parental report, the patient had fasted for more than 8 h prior to the POCUS examination and surgery. Her last *per os* intake was the evening before at a fast food restaurant. Her family consented to enrollment in a separate clinical trial to assess gastric contents and aspiration risk using gastric POCUS. The patient was enrolled in the healthy, fasted, control arm of the trial. Twenty minutes prior to scanning, the patient received oral midazolam and acetaminophen (total volume of 8 mL) for premedication. Ultrasonography was performed in the preoperative care unit using a Sonosite X-Porte (Fujifilm Sonosite Inc, Bothwell, WA) with a mid-frequency (3-8 MHz) curvilinear probe in the standard abdominal setting. During gastric POCUS, the presence of gastric contents was observed. In the right lateral decubitus position (RLD), the cross-sectional area of the gastric antrum was traced and found to measure 5.9 cm² [Figure 1]. The pattern of the material in the gastric antrum was heterogeneous suggesting the recent intake of solid food. Based on the grading system for antrum assessment, she was classified as a high risk of aspiration.^[7] To reduce aspiration

risk, surgery was postponed for an additional 2 h. A repeat ultrasound was performed noting an empty stomach and a Grade 0 score [Figure 2]. In the operating room, standard American Society of Anesthesiologists' monitors were placed. Following pre-oxygenation with 100% oxygen, general anesthesia was induced with sevoflurane in nitrous oxide and oxygen. The patient received intranasal fentanyl (25 µg) to provide postoperative analgesia. She tolerated the procedure well and her postoperative course was unremarkable.

Discussion

Gastric POCUS can define both the volume and quality of contents in the gastric antrum, thereby defining the presence or absence of a full stomach and potentially decreasing the risk of aspiration during anesthetic care. The qualitative assessment allows the healthcare provider to differentiate the type and volume of gastric content that are present based on its sonographic appearance and potentially determine timing of surgery and thereby mitigate the risk of gastric aspiration during anesthetic induction.^[8,9] In a fasted patient, presenting for surgery, one would expect to see an empty gastric antrum with a characteristic "bull's eye" pattern, which is classified as Grade 0 and which suggests a low aspiration risk.^[7,10] This pattern was seen on the second ultrasound in our patient. Solid food or thick liquid demonstrated by an expanded gastric antrum and the presence of hyperechoic material is considered a high risk of aspiration. The hyperechoic material will appear either homogenous for thick liquids or heterogenous with a mixture of air and fluid for solid food. The latter was noted on the first gastric POCUS in our patient. This grading system can also be used to estimate the quantity of clear liquids compared to baseline fasting secretions, both of which appear hypoechoic. A low volume

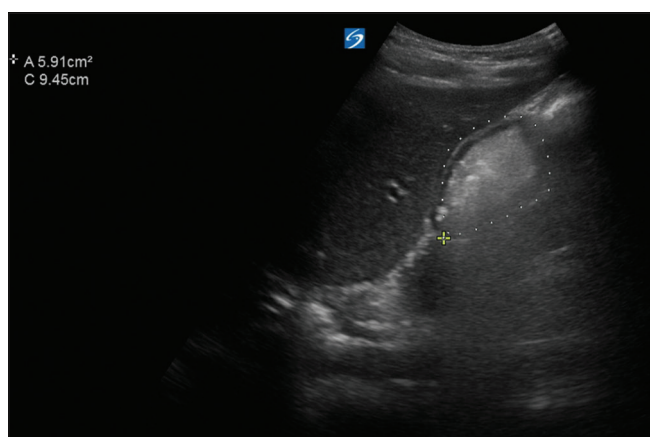


Figure 1: Gastric point-of-care ultrasound image showing solid/thick fluid in the gastric antrum suggestive of recent food ingestion. The cross-sectional area of the gastric antrum was calculated to be 5.9 cm². Based on the grading system for gastric antrum assessment, she was classified as a high risk for potential aspiration

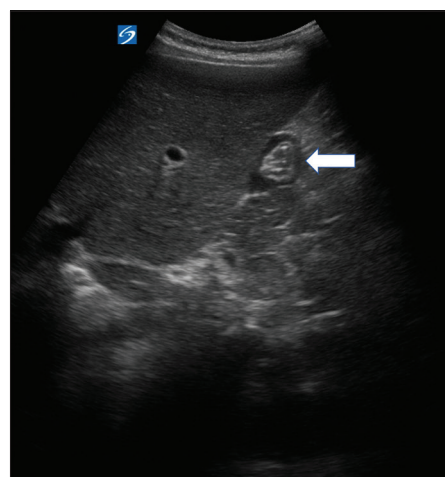


Figure 2: Repeat gastric point-of-care ultrasound performed 2 hours later showing a small gastric antrum with minimal echogenic fluid, demonstrating a bull's eye sign (arrow)

of clear (hypoechoic) gastric fluid is classified as Grade I and suggests a low aspiration risk; whereas a higher volume is classified as Grade II and indicates a higher aspiration risk.^[7] The more accepted upper limit for gastric clear fluid secretions is 1.2–1.5 mL/kg.^[7-11]

The presence of solid content or thick fluid during gastric POCUS raises the possibility of noncompliance with the NPO fasting instructions. However, other factors including genetic factors, comorbid conditions, or acute processes can delay gastric emptying resulting in a full stomach despite appropriate NPO times. In our patient, even with repeated questioning, there was no history of failure to adhere to the recommended NPO times. Previous clinical studies have suggested that a full stomach may be presented despite adhering to the 6–8 h fasting times suggested for elective surgery. In a prospective series of 116 patients, ranging in age from 2 to 17 years old, who were presented for procedural sedation, 69% were found to have a full stomach on gastric POCUS despite a median fasting time of 5.8 h.^[11] The authors used a gastric volume of less than 1.2–1.5 mL/kg to define appropriate NPO. The majority of patients had eaten full meals and were taking opioid analgesics for pain before surgery, thereby explaining the high incidence of a full stomach noted in the series.

Gastric POCUS performed preoperatively may limit unnecessary delays in surgery and may also provide insight into situations where standard NPO practices cannot ensure an empty stomach including acute abdominal processes, traumatic injuries, and in the presence of comorbid features which may delay gastric emptying. In our patient, gastric POCUS identified the presence of echogenic material in the gastric antrum suggestive of an NPO violation. Given this finding, surgery was delayed 2 h and a repeat gastric ultrasound performed prior to providing with surgery.

When there is evidence of a full stomach on gastric ultrasound before an elective surgery, the procedure should be delayed to allow additional time for gastric emptying. An observational prospective cohort study assessed the gastric antrum prior to pyloromyotomy in infants.^[12] The authors reported a strong correlation between the antral area measured in the RLD position and the volume of gastric content aspirated from the nasogastric tube. Gastric POCUS led to a change of the planned induction technique for approximately half of the patients.

In summary, we present anecdotal evidence that gastric POCUS may be useful in identifying inadequate stomach emptying related to NPO violations or other factors that may

delay gastric emptying. Although standard of care mandates use of appropriate NPO times to limit the incidence of perioperative aspiration, gastric POCUS may also provide useful information especially in clinical situations where comorbid features, genetic variability, or associated clinical conditions affect gastric emptying.^[13] Despite careful history taking, it may not always be feasible to ensure appropriate adherence to NPO times. Based on the gastric POCUS, timing of surgery may be adjusted or induction techniques modified to limit the risk of aspiration. In our patient, we were able to change patient management by delaying surgery, confirming appropriate gastric emptying at a later time, and then safely proceeding with anesthesia.

Declaration of patient consent

The authors certify that they have obtained all appropriate patient consent forms. In the form the patient(s) has/have given his/her/their consent for his/her/their images and other clinical information to be reported in the journal. The patients understand that their names and initials will not be published and due efforts will be made to conceal their identity, but anonymity cannot be guaranteed.

Financial support and sponsorship

Nil.

Conflicts of interest

There are no conflicts of interest.

References

1. Eisler L, Huang G, Lee KM, Busse JA, Sun M, Lin AY, *et al.* Identification of perioperative pulmonary aspiration in children using quality assurance and hospital administrative billing data. *Paediatr Anaesth* 2018;28:218-25.
2. American Society of Anesthesiologists Committee. Practice guidelines for preoperative fasting and the use of pharmacologic agents to reduce the risk of pulmonary aspiration: Application to healthy patients undergoing elective procedures: An updated report by the American society of anesthesiologists task force on preoperative fasting and the use of pharmacologic agents to reduce the risk of pulmonary aspiration. *Anesthesiology* 2017;126:376-93.
3. Srinivasan S, Cornell TT. Bedside ultrasound in pediatric critical care: A review. *Pediatr Crit Care Med* 2011;12:667-74.
4. van de Putte P, van Hoonacker J, Perlas A. Gastric ultrasound to guide anesthetic management in elective surgical patients non-compliant with fasting instructions: A retrospective cohort study. *Minerva Anestesiol* 2018;84:787-95.
5. Alakkad H, Kruisselbrink R, Chin KJ, Niazi AU, Abbas S, Chan VW, *et al.* Point-of-care ultrasound defines gastric content and changes the anesthetic management of elective surgical patients who have not followed fasting instructions: A prospective case series. *Can J Anaesth* 2015;62:1188-95.
6. Desgranges FP, Gagey Riegel AC, Aubergy C, de Queiroz Siqueira M, Chassard D, Bouvet L. Ultrasound assessment of gastric contents in children undergoing elective ear, nose and throat surgery: A prospective cohort study. *Anaesthesia* 2017;72:1351-6.

7. Van de Putte P, Perlas A. Ultrasound assessment of gastric content and volume. *Br J Anaesth* 2014;113:12-22.
8. Kruisselbrink R, Gharapetian A, Chaparro LE, Ami N, Richler D, Chan VW, *et al.* Diagnostic accuracy of point-of-care gastric ultrasound. *Anesth Analg* 2019;128:89-95.
9. Bouvet L, Bellier N, Gagey-Riegel AC, Desgranges FP, Chassard D, De Queiroz Siqueira M. Ultrasound assessment of the prevalence of increased gastric contents and volume in elective pediatric patients: A prospective cohort study. *Paediatr Anaesth* 2018;28:906-13.
10. El-Boghdadly K, Wojcikiewicz T, Perlas A. Perioperative point-of-care gastric ultrasound. *BJA Educ* 2019;19:219-26.
11. Leviter J, Steele DW, Constantine E, Linakis JG, Amanullah S. "Full stomach" despite the wait: Point-of-care gastric ultrasound at the time of procedural sedation in the pediatric emergency department. *Acad Emerg Med* 2019;26:752-60.
12. Gagey AC, de Queiroz Siqueira M, Desgranges FP, Combet S, Naulin C, Chassard D, *et al.* Ultrasound assessment of the gastric contents for the guidance of the anaesthetic strategy in infants with hypertrophic pyloric stenosis: A prospective cohort study. *Br J Anaesth* 2016;116:649-54.
13. Parekh UR, Rajan N, Iglehart RC, McQuillan PM. Bedside ultrasound assessment of gastric content in children noncompliant with preoperative fasting guidelines: Is it time to include this in our practice? *Saudi J Anaesth* 2018;12:318-20.