



Contents lists available at ScienceDirect

International Journal of Surgery Case Reports

journal homepage: www.casereports.com

Malignant rhabdoid tumours of the small intestine with multiple organ involvement: Case report

Aya Noguchi^{a,b}, Hirofumi Imoto^{b,*}, Hiroshi Yoshida^a, Shigeyuki Asano^c, Michiaki Unno^b, Fumiaki Shinya^a

^a Department of Surgery, Iwaki City Medical Center, 16 Kuzehara, Uchigou Mimaya-machi, Iwaki City, Fukushima, 973-8555, Japan

^b Department of Surgery, Tohoku University Graduate School of Medicine, 1-1 Seiryomachi, Aoba-ku, Sendai, Miyagi, 980-8574, Japan

^c Department of Pathology, Iwaki City Medical Center, 16 Kuzehara, Uchigou Mimaya-machi, Iwaki City, Fukushima, 973-8555, Japan

ARTICLE INFO

Article history:

Received 14 December 2020

Received in revised form 18 January 2021

Accepted 18 January 2021

Available online 22 January 2021

Keywords:

Case report

Gastrointestinal bleeding

Malignant rhabdoid tumour

Metastasis

Small intestine

ABSTRACT

INTRODUCTION AND IMPORTANCE: Malignant rhabdoid tumours (MRTs) were first described as an infrequent variant of Wilms' tumour and have been reported in several organs. The small intestine is a rare site for MRTs.

CASE PRESENTATION: A 70-year-old man presented with appetite loss and melena. Haemorrhagic small intestinal tumours, swollen mesenteric and paraaortic lymph nodes, a tumour in the left kidney, and multiple tumours in the lung were found. He underwent partial resection of two haemorrhagic small intestinal tumours classified as MRTs based on the results of a pathological examination. However, melena appeared again on postoperative day 6. We performed another operation and resected approximately 180 cm of the small intestine that contained multiple tumours. All lesions were classified as MRTs. Unfortunately, melena appeared again 4 days after the second operation. He did not want invasive therapy and died from massive melena 2 months after the initial surgery.

CLINICAL DISCUSSION: MRTs of the small intestine are uncommon and have an extremely poor prognosis. Although curative resection is an important treatment, cases of metastasis at diagnosis and postoperative early recurrence have been observed, as was the case for the patient described herein. In these cases, effective systemic therapy is necessary. Recently, tumour suppressor genes were shown to be involved in the occurrence of MRT, and new therapies for MRT have been studied.

CONCLUSION: We herein conclude effective systemic therapy is necessary for MRTs with multiple organ involvement. The development of new drugs for this disease is ongoing.

© 2021 The Authors. Published by Elsevier Ltd on behalf of IJS Publishing Group Ltd. This is an open access article under the CC BY-NC-ND license (<http://creativecommons.org/licenses/by-nc-nd/4.0/>).

1. Introduction

Malignant rhabdoid tumours (MRTs), first described as a subtype of Wilms' tumour in the kidneys of children, have a poor prognosis [1]. At present, MRTs have been reported in several organs [2]; however, MRTs of the small intestine are exceedingly rare. We herein describe an aggressive case of MRTs of the small intestine with multiple organ involvement that recurred in the early postoperative period.

This case report is in line with the SCARE criteria [3].

2. Presentation of case

A 70-year-old man with a past medical history of catheter ablation for tachyarrhythmia, hypertension, diabetes, and hyper-

lipidaemia presented to our emergency department with appetite loss and melena. There was nothing particular in his family history. His haemoglobin level dropped to 6.6 g/dL. No lesions were detected by upper gastrointestinal endoscopy and colonoscopy. Small bowel enteroscopy showed a haemorrhagic tumour at the upper jejunum. Contrast-enhanced computed tomography (CECT) revealed two tumours in the small intestine, swollen mesenteric and paraaortic lymph nodes, a left tumour in the kidney and multiple tumours in the lung (Fig. 1). We prioritized surgery over a histological examination since small intestinal tumour haemorrhaging necessitated frequent blood transfusions. There were no ascites or dissemination. We partially resected two small intestinal tumours measuring 6 cm and 1.5 cm and reconstructed the intestine with end-to-end anastomosis, confirming no other haemorrhagic lesions. The tumours appeared dark red, with an irregular surface (Fig. 2).

Histologically, neoplastic cells were composed of eosinophilic cytoplasm and unevenly distributed nuclei and exhibited extensive hyperchromatic nucleoli proliferation (Fig. 3). Immuno-

* Corresponding author.

E-mail address: hiofumi-i@surg.med.tohoku.ac.jp (H. Imoto).

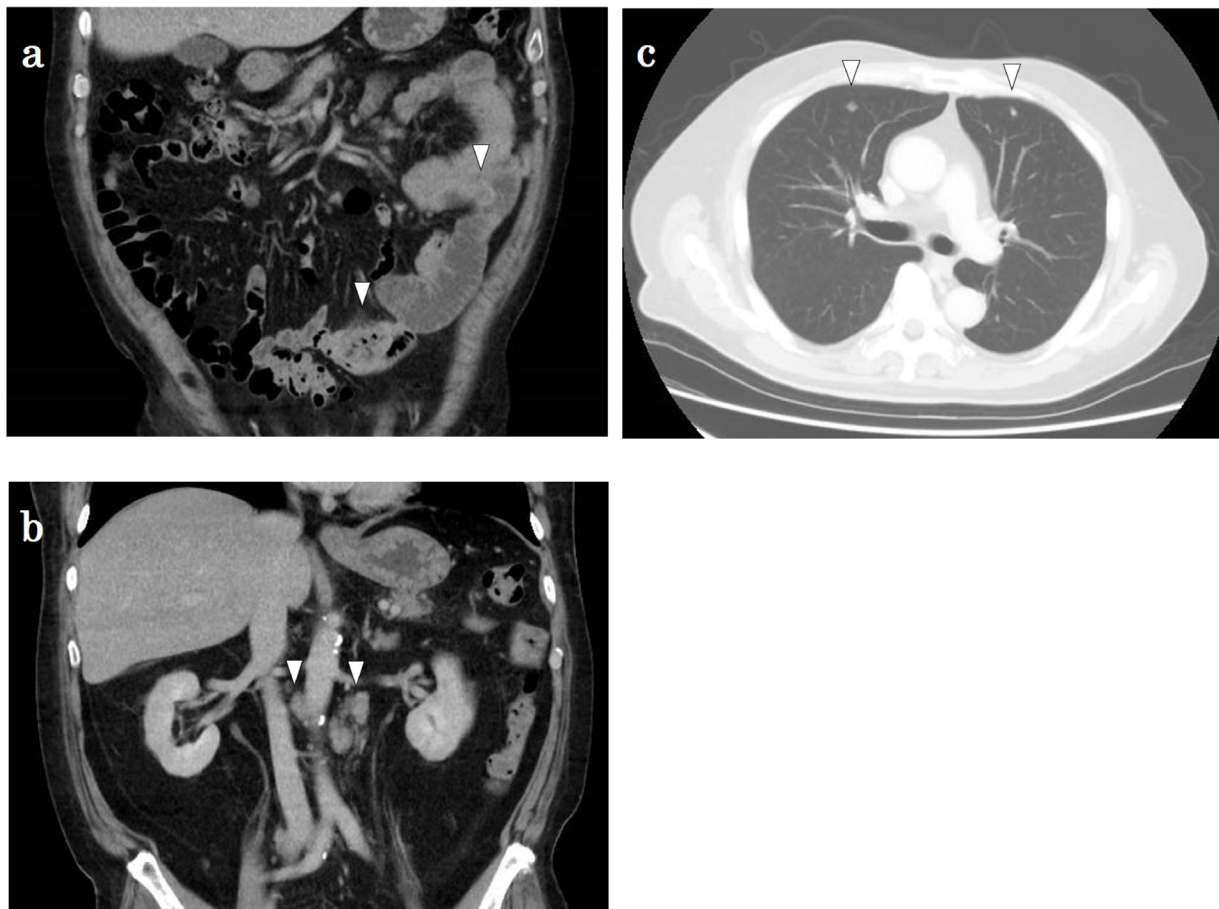


Fig. 1. CECT revealed two tumours in the small intestine (a), swollen paraaortic lymph nodes (b), and multiple tumours in the lung (c).

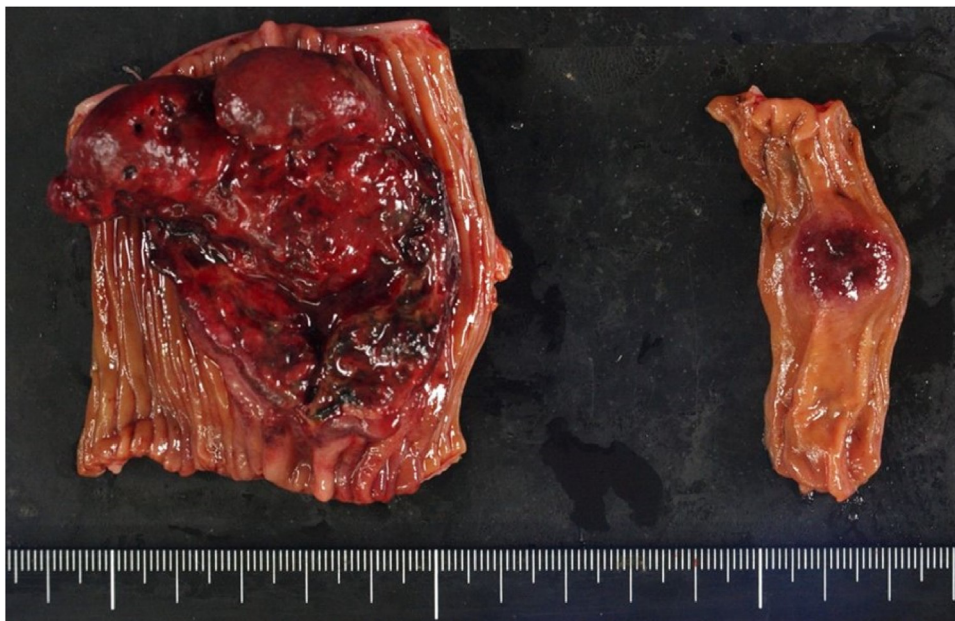


Fig. 2. The tumours appeared dark red, measuring 6 × 5.5 cm and 1.5 × 1 cm, and had irregular surfaces.

histochemical examination revealed the expression of cytokeratin and vimentin in the neoplastic cells. These cells were negative for the epithelial membrane antigen, myogenin and myoglobin. Thus, we diagnosed the patient with MRTs of the small intestine.

Unfortunately, melena appeared again on postoperative day 6, and frequent blood transfusions were required. Although we detected a small intestinal haemorrhage from capsule endoscopy and scintigraphy for gastrointestinal bleeding, a catheter-related bloodstream infection of methicillin-resistant coagulase-negative

Table 1
Clinical features of reported cases of malignant rhabdoid tumour of the small intestine.

Case	Author	Age	Sex	Location	Max size	Metastasis at diagnosis	Treatment	Time to recurrence	Site of recurrence	Outcome
1	Lee	58	M	Duodenum	5 cm	Small intestine, mediastinal lymph nodes	Duodenotomy, radiation	–	–	Dead/11 days
2	Chen	54	M	Jejunum	10 cm	Regional lymph nodes	Partial resection of the small intestine	2 weeks	Liver, pelvic cavity, peritoneum, sigmoid colon	Dead/1 month
3	Al-Nafussi	65	M	Jejunum	8 cm	None	Partial resection of the small intestine	3 months	Anastomotic site, adrenal gland, cervical and paratracheal lymph nodes	Dead/3 months
4	Amrikachi	70	F	Small intestine	12 cm	None	Partial resection of the small intestine	8 months	Pancreas, retroperitoneum	Dead/10 months
5	Abdulkader	56	M	ileum	10 cm	ND	Partial resection of the small intestine	No recurrence	–	Alive/18 months
6	Abdulkader	58	M	Small intestine	6 cm	Adrenal glands, liver	Partial resection of the small intestine	–	–	Dead/Postoperatively
7	Kunze	52	M	Jejunum	4.5 cm	Adrenal gland, lung, thoracic wall	Partial resection of the small intestine	–	–	Dead/2 weeks
8	Salamanca	70	M	Jejunum	9 cm	Adrenal gland, liver, pleura, peripancreatic, mediastinal and supraclavicular lymph nodes	Partial resection of the small intestine, chemotherapy	–	–	Dead/8 months
9	Sheikh	52	M	Small intestine	3 cm	Regional lymph nodes	Partial resection of the small intestine	No recurrence	–	Alive/5 years
10	Toth	81	M	ileum	9 cm	None	Partial resection of the small intestine	5 months	Abdominal wall, ileum, peritoneum	Dead/7 months
11	Voglino	76	M	Jejunum	9 cm	Regional lymph nodes	Partial resection of the small intestine	ND	ND	Dead/2 months
12	Alejandro	64	ND	Jejunum	ND	Adrenal gland	Chemotherapy	ND	ND	Alive
13	Present Case	70	M	Small intestine	5 cm	Kidney, lung, regional and paraaortic lymph nodes	Partial resection of the small intestine	–	–	Dead/2 months

GI: gastrointestinal, ND: no detected.

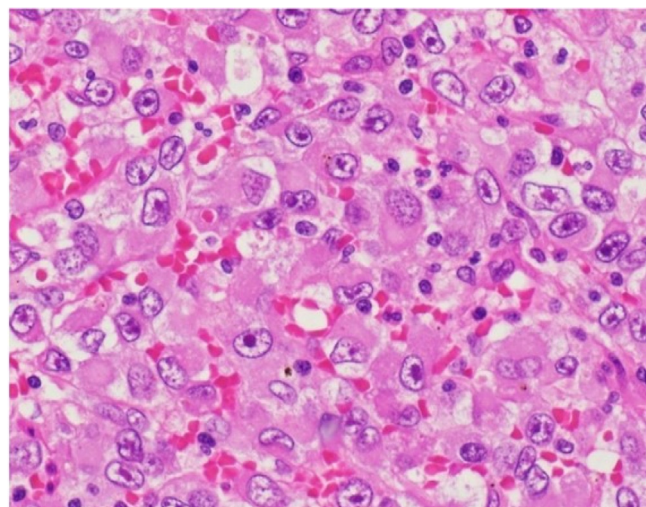


Fig. 3. Histological and immunohistochemical features. Rhabdoid cells exhibited eosinophilic cytoplasm, unevenly distributed nuclei and substantial hyperchromatic nucleoli proliferation (haematoxylin and eosin staining).

staphylococci and purulent discitis occurred. The patient continued to exhibit a high fever and inflammation despite daptomycin treatment, which hindered another operation. Melena persisted, and his general condition gradually deteriorated; thus, we performed another operation on postoperative day 52. Two tumours measuring 5 cm and multiple small tumours were observed in the

small intestine. These lesions were undetectable from the intestinal lumen by upper gastrointestinal endoscopy during the operation, and we thus resected approximately 180 cm of the small intestine with gross lesions at the serosa. We confirmed that no other lesions were apparent. All resected tumours were classified as MRTs, as they exhibited the same properties as those observed in the previous histopathological examination. Although he presented with melena again on 4 days after reoperation, he received the best supportive care in line with his requests. He died from massive melena probably caused by MRTs 2 months after the initial surgery.

3. Discussion

In 1978, MRT was first reported as a subtype of Wilms' tumour by Beckwith and his colleagues [1]. Currently, MRTs have been reported in several organs [2]. MRTs of the small intestine in adults are rare, and we found only 12 cases in PubMed [4,5]. The data from these cases and ours are summarized in Table 1. Only one patient was female. The median patient age was 64 (range 52–81) years, and the maximum size of the primary tumour was 8.5 (range 3–12) cm. All patients except for one underwent tumour resection. Each patient received postoperative radiotherapy or chemotherapy. Only one patient survived for longer than 5 years, and he underwent resection of the main tumour and regional lymph nodes. The performance of gross total resection and localized disease are better prognostic factors for children with MRT [6]. Curative resection is considered the most important treatment for MRT in adults; however, there are cases of extremely poor prognosis for patients with metastasis at diagnosis or recurrence in the

early postoperative period, and multimodal therapy is thus needed. Postoperative chemotherapy and radiotherapy have led to good outcomes in some paediatric MRT cases [6] and thus might be helpful for adults. In addition, new MRT therapies have been developed based on genetic findings. A mutation of SMARCB1 (SNF5/INI1), a tumour suppressor gene on chromosome 22q11.2, was detected in MRT [7], and loss of SMARCB1 was shown to result in the altered expression of key cell cycle regulators and in the reversal of cell cycle arrest [8]. The cyclin-dependent kinase 4/6 inhibitor ribociclib displayed preclinical activity in MRT models, and the study was conducted for future clinical use [9]. Moreover, Phase II study of alisertib which is aurora A kinase inhibitor for MRTs is ongoing [10].

4. Conclusion

MRTs of the small intestine in adults are extremely rare and aggressive. Effective systemic therapy is necessary for MRTs with multiple organ involvement, like ours. The aetiology of MRTs has gradually been elucidated, and new therapeutic drugs for this disease are expected.

Declaration of Competing Interest

The authors report no declarations of interest.

Funding

All authors have no source of funding in association with this case report.

Ethical approval

There is no ethical approval.

Consent

Written informed consent was obtained from the patient for publication of this case report and accompanying images. A copy of the written consent is available for review by the Editor-in-Chief of this journal on request.

Author contribution

Aya Noguchi: Writing - Original Draft.
Hirofumi Imoto: Writing - Review & Editing.
Hiroshi Yoshida: Operated.
Shigeyuki Asano: Reported Pathological findings.

Michiaki Unno: Supervision.

Fumiaki Shinya: Supervision.

Registration of research studies

Not applicable.

Guarantor

Hrofumi Imoto.

Provenance and peer review

Not commissioned, externally peer-reviewed.

Acknowledgement

We would like to thank American Journal Experts for editing the English language in this manuscript.

References

- [1] J.B. Beckwith, N.F. Palmer, Histopathology and prognosis of Wilms tumors: results from the first national Wilms' tumor study, *Cancer* 41 (5) (1978) 1937–1948.
- [2] H. Cheng, S. Yang, S. Cai, X. Ma, H. Qin, W. Zhang, et al., Clinical and prognostic characteristics of 53 cases of extracranial malignant rhabdoid tumor in children. A single-institute experience from 2007 to 2017, *Oncologist* 24 (7) (2019) 551–558.
- [3] R.A. Agha, T. Franchi, C. Sohrabi, G. Mathew, for the SCARE Group, The SCARE 2020 guideline: updating consensus Surgical CAse REport (SCARE) guidelines, *Int. J. Surg.* (84) (2020) 226–230.
- [4] C. Voglino, M. Scheiterle, G. Di Mare, F. Mariani, A. De Stefano, A. Ginori, et al., Malignant rhabdoid tumor of the small intestine in adults: a brief review of the literature and report of a case, *Surg. Today* 45 (7) (2015) 924–928.
- [5] A. Pérez Fernández, J.F. Sánchez Melgarejo, J.M. Rubio Mateos, Rhabdoid cavitated adenocarcinoma in the jejunum, an exceptional case by enteroscopy, *Rev. Esp. Enferm. Dig.* 112 (4) (2020) 327.
- [6] K. Nemes, S. Bens, D. Kachanov, M. Teleshova, P. Hauser, T. Simon, et al., Clinical and genetic risk factors define two risk groups of extracranial malignant rhabdoid tumours (eMRT/RTK), *Eur. J. Cancer* 142 (2020) 112–122.
- [7] I. Versteeg, N. Sevenet, J. Lange, M.F. Rousseau-Merck, P. Ambros, R. Handgretinger, et al., Truncating mutations of hSNF5/INI1 in aggressive paediatric cancer, *Nature* 394 (6689) (1998) 203–206.
- [8] S. Venneti, P. Le, D. Martinez, K.W. Eaton, N. Shyam, K.L. Jordan-Sciutto, et al., p16INK4A and p14ARF tumor suppressor pathways are deregulated in malignant rhabdoid tumors, *J. Neuropathol. Exp. Neurol.* 70 (7) (2011) 596–609.
- [9] B. Georger, F. Bourdeaut, S.G. DuBois, M. Fischer, J.I. Geller, N.G. Gottardo, et al., A phase I study of the CDK4/6 inhibitor ribociclib (LEE011) in pediatric patients with malignant rhabdoid tumors, neuroblastoma, and other solid tumors, *Clin. Cancer Res.* 23 (10) (2017) 2433–2441.
- [10] ClinicalTrials.gov [Internet], Phase 2 Study of Alisertib Therapy for Rhabdoid Tumors (SJATRT), National Library of Medicine (US), Bethesda (MD), 2000, Feb 29, Identifier NCT02114229 <https://clinicaltrials.gov/ct2/show/record/NCT02114229>.

Open Access

This article is published Open Access at [sciencedirect.com](https://www.sciencedirect.com). It is distributed under the [IJSCR Supplemental terms and conditions](#), which permits unrestricted non commercial use, distribution, and reproduction in any medium, provided the original authors and source are credited.