

# Modified quad helix appliance for thumb sucking and cross bite correction

C. VINAY, V. SANDEEP, C. H. HANUMANTH RAO<sup>1</sup>, K. S. ULOOPI, A. SIVA KUMAR<sup>1</sup>

## Abstract

Digit sucking habit is a learned pattern of behavior commonly seen in children of preschool age. Prolonged digit sucking beyond the preschool age, lead to the development of malocclusion such as anterior open bite, maxillary constriction and posterior crossbite. Treatment strategies include interception of habit and correction of the malocclusion. The present case report describes a modified quad helix appliance used successfully in a 9-year-old child to intercept thumb sucking habit and simultaneous correction of posterior crossbite. The appliance has the advantage of easy fabrication, being versatile and more patients compliant.

**Keywords:** Crossbite, digit sucking, modified quad helix appliance

## Introduction

Comprehensive treatment protocol in pediatric dentistry involves detection and interception of deleterious habits, which predispose young children to the development of malocclusion. Non-nutritive sucking habits constitute the majority of oral habits affecting the pliable hard tissues in primary and mixed dentition period leading to malocclusion. Childhood digit sucking has an adaptive value for children up to the age of 4 years.<sup>[1]</sup> Normally about two-third of such habits are self-limiting by the age of 4-5 years with no long-term consequence.<sup>[2]</sup> However, prolonged sucking beyond 5 years can lead to various types of malocclusion including open bite, cross bite (unilateral/bilateral), increased overjet, crowding and increased probability of developing Class II malocclusion.<sup>[3]</sup> Intensity, duration and frequency of the habit practiced dictate the severity of malocclusion. Clinical and experimental evidence suggest that 4-6 h of force per day is probably the minimum time to cause tooth movement.<sup>[2]</sup> Pressure habits may simulate the same phenomenon, if continued over 6 h/day may prompt development of malocclusion.<sup>[4]</sup>

Departments of Pedodontics and Preventive Dentistry,  
and <sup>1</sup>Orthodontics, Vishnu Dental College, Bhimavaram,  
Andhra Pradesh, India

**Correspondence:** Dr. C. Vinay, Department of Pedodontics and Preventive Dentistry, Vishnu Dental College, Bhimavaram - 534 202, Andhra Pradesh, India.  
E-mail: vinaychandrappa@yahoo.co.in

Prolonged thumb sucking alters the functional equilibrium between tongue and orofacial musculature<sup>[5]</sup> and lead to narrowing of the maxillary arch, resultant posterior crossbite and sometimes can also lead to simple anterior open bite.<sup>[6]</sup> Untreated posterior crossbite especially unilateral type can lead to disturbance in temporomandibular articulation, skeletal asymmetries, modifications of soft-tissue profile and attrition of the primary and permanent teeth.<sup>[7]</sup>

Treatment of malocclusion associated with thumb sucking mainly depends upon the willingness of the child to stop the habit. The therapy should be advocated to the child as an aid, but not as a punishment and also to provide psychological support to help the child adjust to it.<sup>[2]</sup> Various therapeutic approaches include counseling the child, reward system, remainder therapy using a habit deterrent appliance. If the behavior modification technique fails, then the preferred treatment modality is using the appliance therapy.<sup>[2]</sup>

There are numerous devices that effect on the particular characteristic. Very often, more than one appliance is advocated for the correction of habit and associated malocclusion. This generally prolongs the treatment duration with increased treatment cost. The following case report describes the use of a modified quad helix appliance in intercepting thumb sucking habit and simultaneous correction of associated bilateral posterior crossbite and mild anterior open bite in a 9-year-old boy.

## Case Report

A 9-year-old boy accompanied by his parents reported to the Department of Pediatric Dentistry with the chief complaint of forwardly placed upper front teeth. Parents reported history of active thumb sucking by the child since childhood, sucking his left thumb during sleep only. Child's mother revealed that he was unable to refrain from the habit even after repeated motivation from them. Clinical examination revealed the following features: Early mixed dentition stage, narrow and V shaped maxilla, proclined maxillary central incisors, mesio

Access this article online	
Quick Response Code: 	Website: <a href="http://www.contempclindent.org">www.contempclindent.org</a>
	DOI: 10.4103/0976-237X.123064

labial rotation of 11, 21. Median diastema of about 2 mm was also present [Figure 1a and b]. Patient exhibited an overjet of 9 mm, a negative open bite of 0.5 mm and bilateral posterior crossbite extending up to primary canines.

Cephalometric evaluation revealed a skeletal Class II tendency with normodivergent facial pattern [Figure 2a and b]. The anterior dentition presented with mild dentoalveolar proclination [Table 1]. Analysis of the cast revealed adequate arch length in both maxilla and mandible with arch dimensions depicted in Table 2. Based on the investigations, the case was diagnosed as skeletal Class II (border line) and dental Class I with bilateral posterior crossbite and anterior open bite.

The child was counseled in the same visit regarding the deleterious effect of digit-sucking habit on dental occlusion, facial esthetics and he was self-motivated to stop the habit by himself. However, he expressed inability to refrain from the habit. Then, we planned intercepting the habit with a modified design of quad helix appliance.

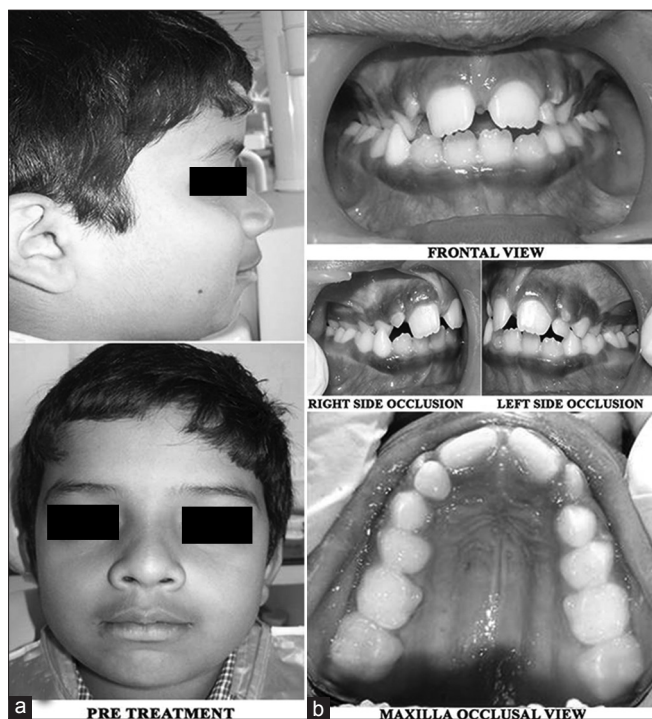
**Appliance design**

Molar separation was achieved using orthodontic separators. After banding the maxillary molar, an alginate impression was made with the bands in position and the cast was prepared. A modified quad helix crib appliance was fabricated with 0.036 inch stainless steel wire. Anterior component of the quad helix was modified to form 3 cribs, which are continuous with

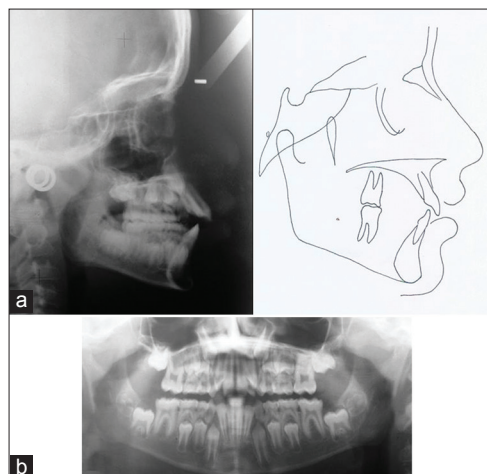
the anterior helices and the posterior component retained the conventional design. The expansion arms extended up to the primary canine region. The wire component was soldered to the molar bands *in situ* [Figure 3a].

**Table 1: Pre-treatment and post-treatment cephalometric parameters**

Cephalometric parameters	Pre-treatment	Post-treatment
SNA	83°	83.5°
SNB	76°	77°
ANB	7°	7.5°
Mandibular plane angle G0-Gn-SN ( instead of small 'n' it should be capital N)	30°	31.6°
Occlusal plane angle	18°	21°
Palatal plane angle	7.5°	9.0°
Upper incisor to N-A angle	26°/6	13°/2
Upper incisor to SN plane	108°	90°
Upper incisor to N-Pog linear	14 mm	8 mm
Lower incisor to N-B angle	27°/6	27°/6
Lower incisor to mand plane	98°	9°
Lower incisor to N-Pog linear	5 mm	4 mm
Interincisal angle	122°	140°
Naso labial angle	90°	102°
Saddle angle	124°	121°
Articular angle	145°	144°
Gonial angle	125°	125°
Anterior facial height	113 mm	119 mm
Posterior facial height	74 mm	78 mm
Jarabak ratio	65.2	



**Figure 1:** (a) A 9-year-old boy with mild convex profile. (b) Intra-oral pictures showing bilateral posterior crossbite and mild open bite



**Figure 2:** (a) Pre-treatment cephalometric radiograph and tracing. (b) Pre-treatment orthopantomogram

**Table 2: Model analysis pre-treatment and post-treatment**

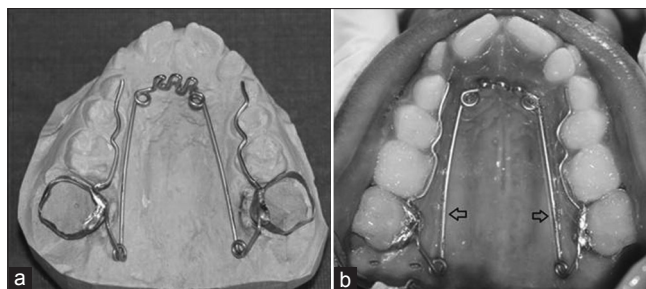
Parameter	Pre-treatment (mm)	Post-treatment (mm)
Inter canine distance	27	35
Intermolar distance (primary II molars)	34	43
Intermolar distance (permanent I molars)	41	47

**Clinical management**

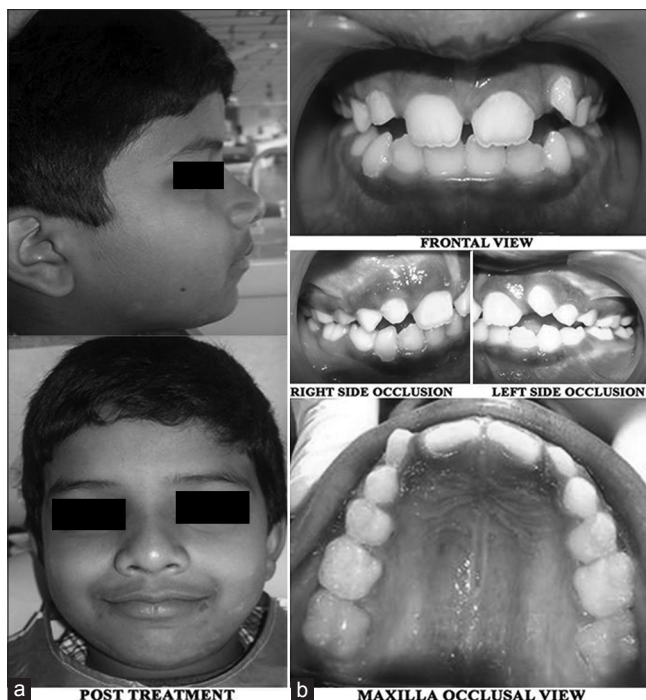
The appliance was tried intra orally before cementation to ensure optimal fit and extension of the crib. It was cemented in the passive form and was not activated until 2 weeks, which allowed the child to acclimatize. The presence of crib in the appliance made it extremely difficult for the child to place the thumb in the mouth. Thus it acted as a deterrent to eliminate the habit. After 2 weeks, the appliance was activated for transverse expansion of maxillary arch using 3-prong plier at the inner leg [Figure 3b]. The activation expanded the appliance close to 2 mm generating 100-150 g force. The correction of posterior crossbite was monitored every 3 weeks and the appliance was activated until overcorrection was achieved. Crossbite correction was achieved in 6 months along with successful interception of habit [Figure 4a and b]. The magnitude of expansion achieved in inter-canine and inter-molar width is demonstrated. Post-treatment cephalometric evaluation revealed marked improvement in the upper incisor inclination, interincisal angle, palatal plane and increased vertical dimension. No change was noted in the sagittal relation of the jaws [Figure 5 and Table 1]. A simple Hawley’s retainer was prescribed as retention appliance.

**Discussion**

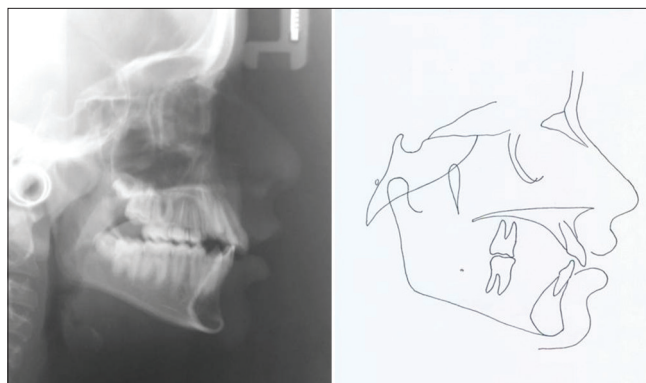
Children with digit sucking habit are routinely managed by age appropriate explanation, positive reinforcement, digital reminders and intra oral appliance therapy. Intraoral appliance therapy serves as an effective deterrent in children with more deeply ingrained habits.<sup>[8]</sup> The average time period required for the correction of posterior crossbite during mixed dentition period was reported to be 0.6-1.2 years, based on the complexity and type of appliance used.<sup>[9]</sup> Treatment protocol generally requires more than one appliance to intercept habit and to correct the dentofacial changes.<sup>[10]</sup> Such therapeutic approach is time consuming and increases the treatment cost considerably. Different designs have been reported in the literature for correction of thumb sucking habit, but no conclusion were made as to which is the best type of appliance to use and how long to use them.<sup>[10,11]</sup> Cozza reported a modified quad helix appliance with soldered cribs on to the anterior segment, which acted as a habit deterrent.<sup>[12]</sup> They reported clinical effectiveness of 85-90% in correcting dental open bite in the study sample and a clinically significant improvement in maxillomandibular vertical skeletal relationships because of the



**Figure 3:** (a) Modified quad helix appliance. (b) Arrows indicate the site of activation of the appliance using 3-prong plier for more anterior expansion



**Figure 4:** (a) Post-treatment extra oral photographs. (b) Intra-oral pictures showing establishment of positive overbite and bucco-lingual relationship



**Figure 5:** Post-treatment cephalometric radiograph and tracing rotation of the palatal plane.<sup>[13,14]</sup> Although the appliance was effective in the correction of dentoalveolar discrepancies, it

proved to be cumbersome in the fabrication. The present design of quad helix has the advantage of easy fabrication, which does not require any soldering of cribs to the anterior component. Thus the metallurgical side-effects of soldering are eliminated. It can simultaneously correct the habit, open bite and posterior crossbite. Significant correction in over bite from  $-0.5$  mm to  $1.5$  mm was achieved post-operatively in the present case ( $2.0$  mm). Cephalometric evaluation revealed considerable clockwise rotation of the palatal plane ( $1.5^\circ$ ) and increased anterior facial height ( $6$  mm). This was also accompanied by reduction in incisor inclination. Increased intermolar arch width may be the additional factor responsible for decreased overjet in our patient. For every  $1$  mm increase in arch width at the molars will allow  $0.3$  mm reduction in the overjet.<sup>[15]</sup>

## Conclusion

The quad helix design described in the present report is easier to fabricate and versatile. It did act as a habit deterrent and intend to correct associated dentofacial discrepancies. Clinical and cephalometric changes demonstrated good improvement in dentoalveolar inclination and maxillo-mandibular vertical relationships. Hence, we believe that this appliance can be indicated in patients with deep seated thumb sucking habit.

## References

1. Wright L, Schaefer A, Solomons G. Encyclopedia of Pediatric Psychology. Baltimore: University Park Press; 1979.
2. Christensen JR, Fields HW Jr, Adair SM. Oral habits. In: Pinkham JR, Casamassimo PS, Fields HW Jr, McTigue DJ, Nowak AJ, editors. Pediatric Dentistry: Infancy Through Adolescence. 4<sup>th</sup> ed. St. Louis, MO: Elsevier Saunders; 2005. p. 431-9.
3. Nanda RS, Khan I, Anand R. Effect of oral habits on the occlusion in preschool children. ASDC J Dent Child 1972;39:449-52.
4. Warren JJ, Bishara SE. Duration of nutritive and nonnutritive sucking behaviors and their effects on the dental arches in the primary dentition. Am J Orthod Dentofacial Orthop 2002;121:347-56.
5. Peterson JE Jr. Pediatric oral habits. In: Stewart RE, Barber TK, Troutman KC, Wei SH, editors. Pediatric Dentistry: Scientific Foundations and Clinical Practice. St. Louis: C V Mosby Company; 1982. p. 361-72.
6. Macena MC, Katz CR, Rosenblatt A. Prevalence of a posterior crossbite and sucking habits in Brazilian children aged 18-59 months. Eur J Orthod 2009;31:357-61.
7. Binder RE. Correction of posterior crossbites: Diagnosis and treatment. Pediatr Dent 2004;26:266-72.
8. Maguire JA. The evaluation and treatment of pediatric oral habits. Dent Clin North Am 2000;44:659-70.
9. Erdinç AE, Ugur T, Erbay E. A comparison of different treatment techniques for posterior crossbite in the mixed dentition. Am J Orthod Dentofacial Orthop 1999;116:287-300.
10. Kulkarni GV, Lau D. A single appliance for the correction of digit-sucking, tongue-thrust, and posterior cross bite. Pediatr Dent 2010;32:61-3.
11. Moore NL. Suffer the little children: Fixed intraoral habit appliances for treating childhood thumbsucking habits: A critical review of the literature. Int J Orofacial Myology 2002;28:6-38.
12. Cozza P, Giancotti A, Rosignoli L. Use of a modified quad helix in early interceptive treatment. J Clin Orthod 2000;34:473-6.
13. Cozza P, Mucedero M, Baccetti T, Franchi L. Treatment and posttreatment effects of quad-helix/crib therapy of dentoskeletal open bite. Angle Orthod 2007;77:640-5.
14. Cozza P, Baccetti T, Franchi L, McNamara JA Jr. Treatment effects of a modified quad-helix in patients with dentoskeletal open bites. Am J Orthod Dentofacial Orthop 2006;129:734-9.
15. O'Higgins EA, Lee RT. How much space is created from expansion or premolar extraction? J Orthod 2000;27:11-3.

**How to cite this article:** Vinay C, Sandeep V, Hanumanth Rao CH, Uloopi KS, Kumar AS. Modified quad helix appliance for thumb sucking and cross bite correction. Contemp Clin Dent 2013;4:523-6.

**Source of Support:** Nil. **Conflict of Interest:** None declared.