

Case Report

Recurrent breast carcinoma presenting as postmenopausal vaginal bleeding: A case report



Anna Binstock^a, Ashlee L. Smith^b, Alexander B. Olawaiye^{b,*}

^a Division of Obstetrics and Gynecology, Magee-Womens Hospital of UPMC, Pittsburgh, PA, United States

^b Division of Gynecologic Oncology, Magee-Womens Hospital of UPMC, Pittsburgh, PA, United States

ARTICLE INFO

Article history:

Received 18 March 2013

Accepted 15 June 2013

Available online 24 June 2013

Keywords:

Breast carcinoma

Metastases

Endometrium

Tamoxifen

Introduction

Metastases to the female genital tract from extra-genital primaries are rare, with the most common sites affected being the vagina and ovaries (Mazur et al., 1984). Uterine metastases account for approximately 4% of genital tract metastases, with 47% of cases involving the breast as the primary site (Mazur et al., 1984; Kumar and Hart, 1982). In addition, most genital tract metastases are asymptomatic, and are found incidentally or on autopsy. While there have been several case reports of metastases from the breast to the uterus, involvement of the endometrium by such metastases is extremely rare. A PubMed search of the terms “breast carcinoma”, “metastases”, and “endometrium” revealed that most symptomatic metastases were diagnosed in the setting of post menopausal vaginal bleeding. The search also yielded a unique case in which the patient presented with abdominal pain, distension, and a pelvic ultrasound significant for diffuse thickening of the uterus (Arslan et al., 2013). Most cases in which the endometrium is involved present with vaginal bleeding, whereas myometrial involvement tends to be asymptomatic. Herein, we review a case in which a post-menopausal female on Tamoxifen with an established diagnosis of breast cancer presented with vaginal

bleeding and was subsequently diagnosed with breast cancer metastases to the endometrium.

Case

A 43 yo G1P0010 presented to her primary gynecologist with postmenopausal vaginal bleeding. At age 35, she was diagnosed with Stage IIA cancer of the right breast and underwent a segmental mastectomy with sentinel lymph node dissection. Pathology was consistent with an infiltrating ductal carcinoma measuring 3.3 cm, ER/PR+ and Her-2 Neu-. Margins were positive for disease and she underwent re-excision. She was treated with adjuvant chemotherapy and right breast radiation. She initially recurred 3 years following her initial diagnosis with biopsy proven bony metastases in the left pubic symphysis. A bone scan identified innumerable bony metastases in the skull, ribs, spine, and pelvis and a PET scan revealed metastases to the liver. She was treated with zoledronic acid and chemotherapy. Two years following her initial recurrence, she was diagnosed with another recurrence, and was found to have right-sided breast cancer and multi-focal left-sided breast cancer with the largest tumor measuring 5.5 cm. Pathology was consistent with her primary cancer (Fig. 1). She underwent a bilateral mastectomy with reconstruction followed by adjuvant chemotherapy and Tamoxifen. Following her treatment, the patient had stable, but extensive bony metastases in her neck, chest, abdomen, and pelvis.

Approximately 7 years after her initial diagnosis and 2 years following her bilateral mastectomy, she underwent a routine PET scan which revealed decreasing bony metastases and no other evidence of disease. One month after this PET scan, she reported a two month history of scant vaginal bleeding to her gynecologist. She endorsed menopause at 38 yo with no prior episodes of postmenopausal vaginal bleeding. A transvaginal ultrasound revealed a uterus measuring 1.7 × 3 × 5.7 cm with a 1.2 cm posterior leiomyoma and a 3 mm endometrial lining. Endometrial biopsy confirmed adenocarcinoma of breast origin, consistent with her primary tumor. She was referred to Gynecologic Oncology for evaluation and surgical management. She was treated with 6 cycles of paclitaxel and underwent a robotic-assisted total laparoscopic hysterectomy with bilateral salpingo-oophorectomy approximately 5 months after her diagnosis. Intraoperative findings were significant for a uterus that appeared to be normal in size with nodular appearing lesions present on the uterine serosa, malignant appearing lesions present on the surface of bilateral ovaries, and miliary lesions in the posterior cul-de-sac. There were no other areas in the abdomen

* Corresponding author at: Division of Gynecologic Oncology, Department of Obstetrics, Gynecology and Reproductive Sciences, University of Pittsburgh School of Medicine, Magee-Womens Hospital of UPMC, 300 Halket Street, Pittsburgh, PA 15213, USA. Tel: + 14126415468; fax: + 14126415417.

E-mail addresses: binstockab@upmc.edu (A. Binstock), olawaiyea@mail.magee.edu (A.B. Olawaiye).

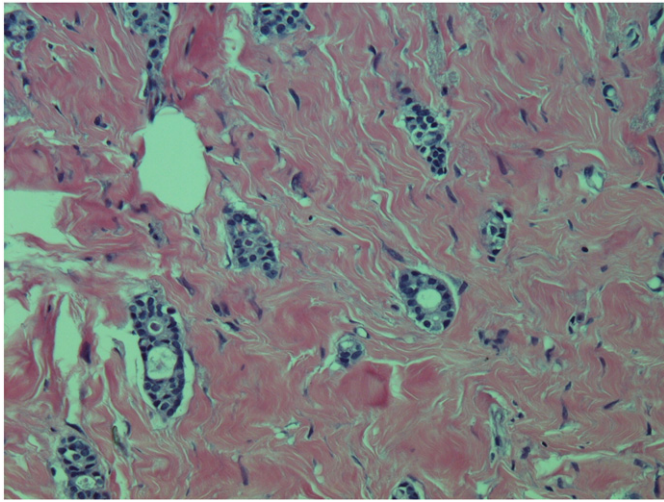


Fig. 1. Pathologic specimen from multi-focal breast cancer recurrence in 2008; invasive ductal carcinoma, fixed in buffered formalin and stained with hematoxylin and eosin.

with gross disease. Pathology was significant for multiple nodules of ductal carcinoma located on bilateral ovaries, fallopian tubes, uterine serosa, myometrium, endometrium, and endocervical stroma. Lymphovascular space invasion and perineural invasion were present (Figs. 2, 3, 4, 5). Immunohistochemical staining was weakly ER positive, PR negative, and Her-2 Neu negative. The sample was strongly positive for Ki-67, consistent with primary breast adenocarcinoma.

Postoperatively, her course was complicated by an obstructing gallstone requiring ERCP, SIADH, and abdominal ascites secondary to progressive liver metastases. She passed away from progression of her primary disease 5 months following her surgery.

Discussion

Metastases to the genital tract from extra-genital cancers are exceedingly rare. However, the most common origins of metastases to the genital tract are the gastrointestinal tract and the breast. A review by Piura et al. revealed that 56% of primary extra-genital cancers that metastasize to the uterus originate from the breast, most commonly lobular carcinomas (Piura et al., 1999; LeBouedec et al., 1991). When the genital tract is affected, the ovaries are the reproductive site most

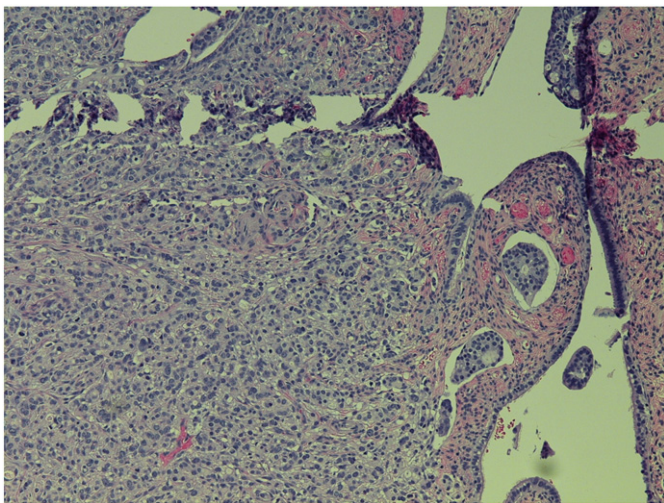


Fig. 2. Pathologic specimen from robotic-assisted total laparoscopic hysterectomy with bilateral salpingo-oophorectomy (3/2011); fallopian tube with invasive ductal carcinoma and lymphovascular space invasion, stained with hematoxylin and eosin.

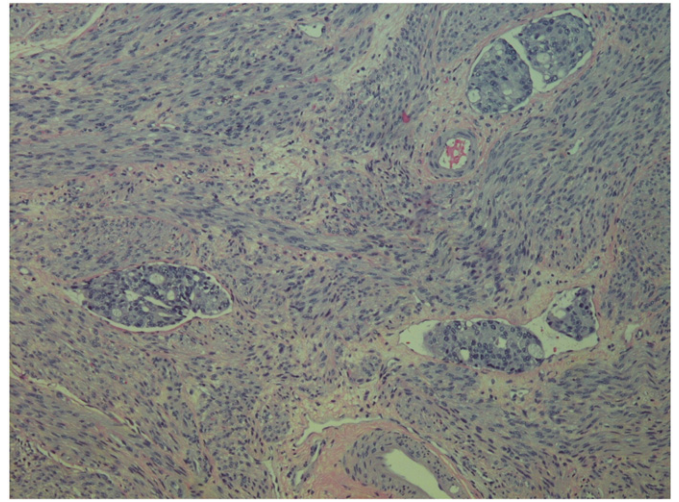


Fig. 3. Pathologic specimen from robotic-assisted total laparoscopic hysterectomy with bilateral salpingo-oophorectomy (3/2011); uterus with lymphovascular space invasion, stained with hematoxylin and eosin.

commonly involved. Any patient with abnormal vaginal bleeding should be evaluated for vaginal, cervical, and uterine pathology. As this case aptly demonstrates, negative imaging should not reduce the concern for pathology or alter the work-up of a patient with abnormal symptoms.

Tamoxifen is a common adjuvant therapy in the treatment of hormone-receptor positive breast cancer, and is known to increase the risk of simple endometrial hyperplasia, complex atypical hyperplasia, and endometrioid adenocarcinoma, and therefore can result in abnormal uterine bleeding. In patients with primary breast cancer maintained on Tamoxifen, there are few reported cases of uterine metastases (Piura et al., 1999; Maymon et al., 1996; Famoriyo et al., 2004). This case illustrates the importance of obtaining a rapid pathologic diagnosis, as treatment of Tamoxifen-induced endometrial pathology and uterine metastases are very different (Ben-Baruch et al., 1990). In cases of a primary uterine disease induced by Tamoxifen, surgical intervention with hysterectomy, with or without bilateral salpingo-oophorectomy is often sufficient for treatment (Ben-Baruch et al., 1990). However, in cases of uterine metastases, there is also a role for systemic adjuvant therapy. Often, at the time of diagnosis of uterine metastases there is widespread disease.

There is a paucity of data regarding the best way to manage such cases. As mentioned, once widespread metastases from the primary breast cancer are confirmed, there is no foreseeable benefit from hysterectomy outside of symptom control, namely control of vaginal bleeding and compressive symptoms. This case demonstrates the rapidity with which patient's primary disease progressed despite surgical resection of uterine disease and appropriately timed chemotherapy.

Interestingly, a PET scan done prior to her gynecologic surgery revealed no areas of increased uptake in either the ovaries or the uterus. This finding may be explained by the fact that FDG uptake is weaker in ductal carcinomas than in lobular carcinomas (Hara et al., 2010). However, the patient did have numerous other bony lesions that were evident on PET. In addition, several cases of incidental uptake in the uterus and ovaries in metastatic breast cancer have been reported (Groheux et al., 2013). As previously mentioned, the patient's transvaginal ultrasound was also unremarkable. In one reported case of uterine metastases, the patient had a thickened endometrial lining, measuring 11 mm, with no CT findings (Piura et al., 1999). Most cases in the literature present with vaginal bleeding and are diagnosed with endometrial biopsy. Rare cases of incidental imaging findings have been reported, but are not typical (Groheux et al., 2013). Because uterine metastases from primary breast cancer are rare, there is little

data available to support which imaging modality is most effective in diagnosis. If imaging is absolutely necessary to assess uterine disease, an enhanced pelvic MRI may be a reasonable choice.

We reviewed a case of a 43 yo female with metastatic breast carcinoma presenting as postmenopausal bleeding while on Tamoxifen. Despite unremarkable pelvic imaging findings, prompt evaluation of her postmenopausal bleeding led to the timely diagnosis of her recurrence and initiation of treatment. Ultimately the patient succumbed to her primary disease. This case demonstrates the importance of maintaining a broad differential diagnosis in the patient with postmenopausal bleeding in the setting of a history of breast cancer and Tamoxifen use. Imaging alone is not sufficient for a diagnosis, and may be misleading. Evaluation of symptoms with a tissue biopsy remains essential in identifying the underlying pathology.

Supplementary data to this article can be found online at <http://dx.doi.org/10.1016/j.gynor.2013.06.003>.

Conflict of interest statement

The authors declare that there are no conflicts of interest.

References

- Arslan, D., Tural, D., Tatli, A.M., Akar, E., Uysal, M., Erdogan, G., 2013. Isolated uterine metastasis of invasive ductal carcinoma. *Case Rep. Oncol. Med.* 793418.
- Ben-Baruch, G., Segal, O., Serlin, J., Menczer, J., 1990. Metastases to the endometrium from breast carcinoma. *Eur. J. Gynecol. Oncol.* 11, 61–66.
- Famoriyo, A., Sawant, S., Banfield, P.J., 2004. Abnormal uterine bleeding as a presentation of metastatic breast disease in a patient with advanced breast cancer on tamoxifen therapy. *Arch. Gynecol. Obstet.* 270, 192–193.
- Groheux, D., Espie, M., Giacchetti, S., Hindie, E., 2013. Performance of FDG PET/CT in the clinical management of breast cancer. *Radiology* 266 (2), 388–405 (Feb).
- Hara, F., Kiyoto, S., Takabatake, D., Takashima, S., Aogi, K., Ohsumi, S., Teramoto, N., Nishimura, R., Takashima, S., 2010. Endometrial metastasis from breast cancer during adjuvant endocrine therapy. *Case Rep. Oncol.* 3 (2), 137–141 (Apr 29).
- Kumar, N.B., Hart, W.R., 1982. Metastases to the uterine corpus from extragenital cancers. A clinicopathologic study of 63 cases. *Cancer* 50, 2163–2169.
- LeBouedec, G., Kauffmann, P., De Latour, M., Fondrinier, E., Cure, H., Dauplat, J., 1991. Uterine metastases of breast cancer. Report of 8 cases. *J. Gynecol. Obstet. Biol. Reprod.* 20, 349–354.
- Maymon, R., Czernobilsky, B., Lifschitz-Mercer, B., Schneider, D., Bukovsky, I., David, A., 1996. Metastatic breast carcinoma manifesting as postmenopausal uterine bleeding in a patient on tamoxifen therapy. *Eur. J. Gynecol. Oncol.* 17, 319–321.
- Mazur, M.T., Hsueh, S., Gersell, D.J., 1984. Metastases to the female genital tract. Analysis of 325 cases. *Cancer* 53, 1978–1984.
- Piura, Benjamin, Yanai-Inbar, Ilana, Rabinovich, Alex, Zalmanov, Svetlana, Goldstein, Jed, 1999. Abnormal uterine bleeding as a presenting sign of metastases to the uterine corpus, cervix and vagina in a breast cancer patient on tamoxifen therapy. *Eur. J. Obstet. Gynecol. Reprod. Biol.* 83 (1), 57–61 (1 March, ISSN 0301–2115, 10.1016/S0301-2115(98)00268-1).