



# Endoscopic Endonasal Odontoidectomy Preserving Atlantoaxial Stability: a Pediatric Case

Pierlorenzo Veiceschi<sup>1</sup> Fabio Pozzi<sup>1</sup> Francesco Restelli<sup>1</sup> Tommaso Alfiero<sup>1</sup> Paolo Castelnuovo<sup>2</sup>  
Davide Locatelli<sup>3</sup>

<sup>1</sup>Department of Neurosurgery, Ospedale di Circolo Fondazione Macchi, Varese, Italy

<sup>2</sup>Department of Otorhinolaryngology, University of Insubria, Ospedale di Circolo Fondazione Macchi, Varese, Italy

<sup>3</sup>Department of Neurosurgery, University of Insubria, Ospedale di Circolo Fondazione Macchi, Varese, Italy

**Address for correspondence** Pierlorenzo Veiceschi, MD, Department of Neurosurgery, Ospedale di Circolo Fondazione Macchi, Via Guicciardini 9, 21100 Varese, Italy (e-mail: pierloveiceschi@gmail.com).

J Neurol Surg B 2021;82(suppl S1):S2–S3.

## Abstract

**Objectives** We illustrate endoscopic endonasal odontoidectomy for the Chiari-I malformation respecting craniovertebral junction (CVJ) stability.

**Design** Case report of a 12-year-old girl affected by the Chiari-I malformation. Magnetic resonance imaging (MRI) showed tonsillar herniation, basilar invagination, and dental retroversion, causing angulation and compression of the bulbomedullary junction. Patient underwent endoscopic third ventriculostomy (ETV) with reduction of ventricular size and resolution of gait disturbances, but she complained the Valsalva-induced headaches, hiccup, and dyesthesias in the lower limbs. Endoscopic endonasal odontoidectomy was chosen to decompress the cervicomedullary junction.

**Setting** The research was conducted at University Hospital “Ospedale di Circolo,” Department of Neurosurgery at Varese in Italy.

**Participants** Patients were from neurosurgical and ENT (ear, nose, and throat) skull base team.

## Keywords

- ▶ craniocervical junction
- ▶ odontoidectomy
- ▶ basilar invagination
- ▶ Chiari I
- ▶ endoscopic skull base

**Main Outcome Measures** A bilateral parasseptal approach was performed, using a four-hand technique. After resection of posterior edge of the nasal septum, the choana is entered and a rhinopharynx muscle–mucosal flap is dissected subperiosteal and transposed in oral cavity. The CVJ is exposed and, using neuronavigation and neuro-monitoring, odontoidectomy is fulfilled until dura is reached, preserving the anterior arch of C1. Reconstruction is obtained suturing the flap previously harvested.



## Conflict of Interest

None declared.

[www.thieme.com/skullbasevideos](http://www.thieme.com/skullbasevideos)

[www.thieme.com/jnlsbvideos](http://www.thieme.com/jnlsbvideos)

received  
March 1, 2019  
**accepted after revision**  
September 29, 2019  
**published online**  
March 4, 2020

DOI <https://doi.org/10.1055/s-0039-3402797>.  
ISSN 2193-6331.

© 2020. The Author(s).

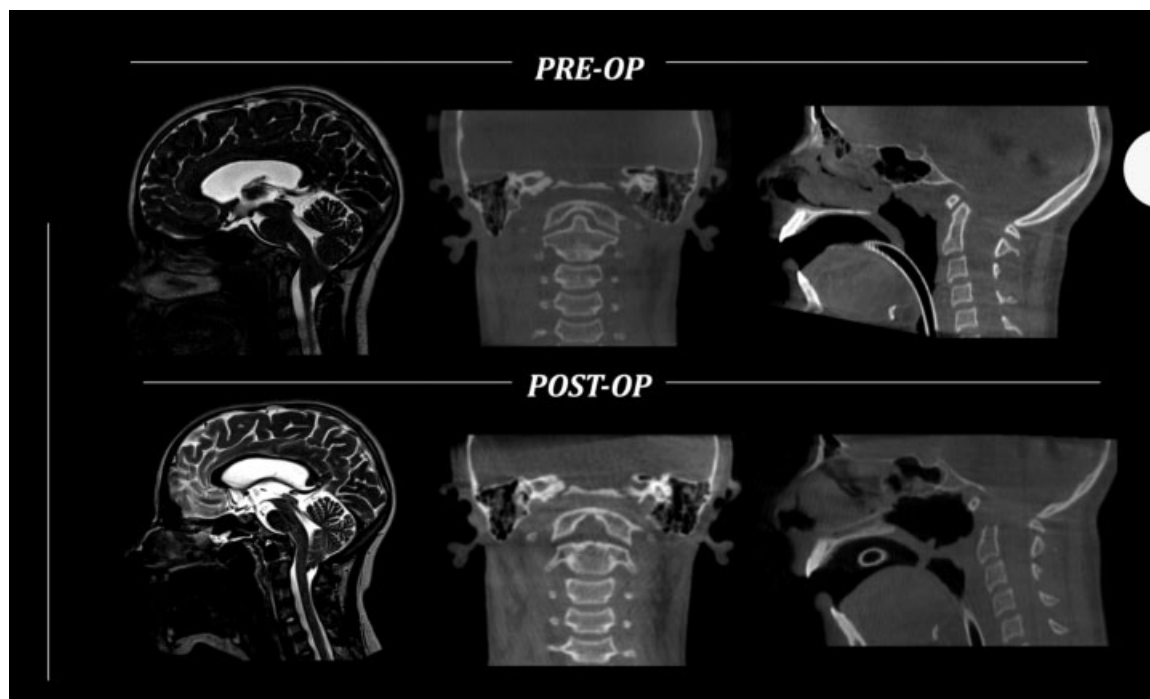
This is an open access article published by Thieme under the terms of the Creative Commons Attribution-NonDerivative-NonCommercial-License, permitting copying and reproduction so long as the original work is given appropriate credit. Contents may not be used for commercial purposes, or adapted, remixed, transformed or built upon. (<https://creativecommons.org/licenses/by-nc-nd/4.0/>)

Georg Thieme Verlag KG, Rüdigerstraße 14, 70469 Stuttgart, Germany

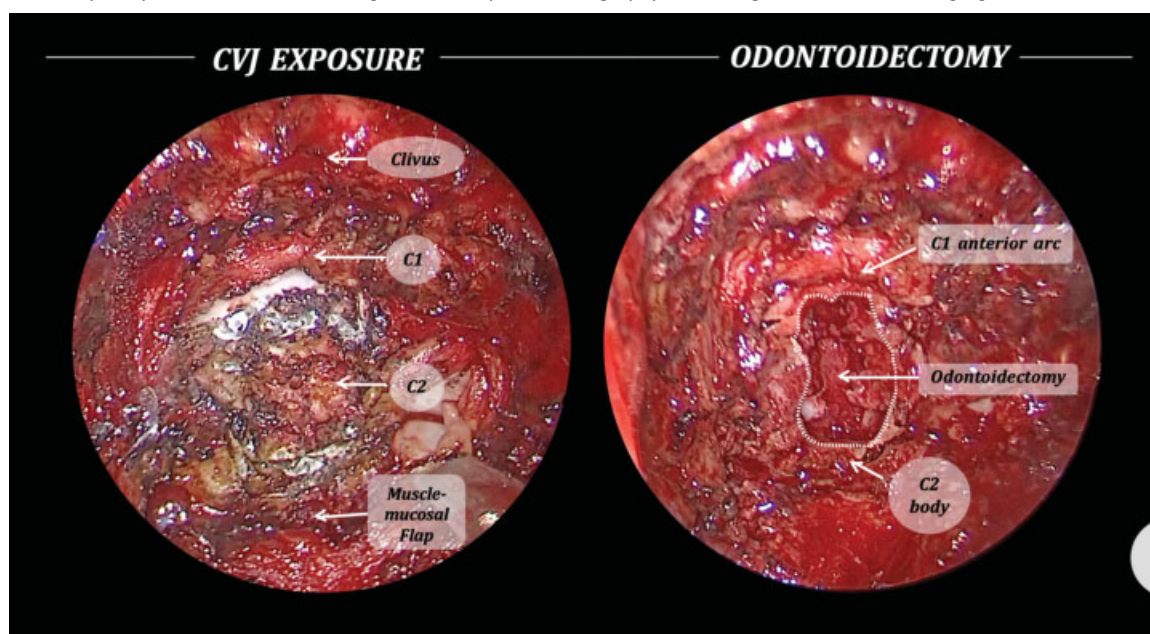
**Results** Postoperative course was unremarkable and the patient experienced improvement of symptoms. Postoperative MRI documented the appearance of tight cerebrospinal fluid (CSF) film anterior to bulbomedullary junction and in retrotonsillar spaces, opening of the bulbomedullary angle, and slight tonsils reduction. No CVJ instability was occurred with any need of posterior fixation.

**Conclusion** Endoscopic endonasal odontoidectomy is a feasible approach for CVJ malformation. In this case, bulbar decompression was achieved preserving CVJ stability and avoiding posterior fixation.

The link to the video can be found at: <https://youtu.be/VlobochfCuc>.



**Fig. 1** Pre- and postoperative MRI and CT images. CT, computed tomography; MRI, magnetic resonance imaging.



**Fig. 2** Intraoperative images of the surgical field before and after the odontoidectomy. CVJ, craniovertebral junction.