



Review

Acanthamoeba keratitis – Clinical signs, differential diagnosis and treatment

Nóra Szentmáry^{a,b,*}, Loay Daas^a, Lei Shi^a, Kornelia Lenke Laurik^a, Sabine Lepper^a, Georgia Milioti^a, Berthold Seitz^a

^a Department of Ophthalmology, Saarland University Medical Center, UKS, Homburg, Saar, Germany

^b Department of Ophthalmology, Semmelweis University, Budapest, Hungary

Received 15 August 2018; revised 10 September 2018; accepted 26 September 2018

Available online 19 October 2018

Abstract

Purpose: To summarize actual literature data on clinical signs, differential diagnosis, and treatment of acanthamoeba keratitis.

Methods: Review of literature.

Results: Clinical signs of acanthamoeba keratitis are in early stages grey-dirty epithelium, pseudodendritiformic epitheliopathy, perineuritis, multifocal stromal infiltrates, ring infiltrate and in later stages scleritis, iris atrophy, anterior synechiae, secondary glaucoma, mature cataract, and chorioretinitis. As conservative treatment, we use up to one year triple-topical therapy (polyhexamethylene-biguanide, propamidine-isectionate, neomycin). In therapy resistant cases, surgical treatment options such as corneal cryotherapy, amniotic membrane transplantation, riboflavin-UVA cross-linking, and penetrating keratoplasty are applied.

Conclusion: With early diagnosis and conservative or surgical treatment, acanthamoeba keratitis heals in most cases.

Copyright © 2018, Iranian Society of Ophthalmology. Production and hosting by Elsevier B.V. This is an open access article under the CC BY-NC-ND license (<http://creativecommons.org/licenses/by-nc-nd/4.0/>).

Keywords: Acanthamoeba; Keratitis; Cornea; Contact lens

Introduction

Acanthamoeba keratitis is a rare but potentially devastating ocular infection, occurring mostly in contact lens wearers. Acanthamoeba are ubiquitous, free-living protozoa, present in air, soil, dust, drinking water, and also sea water. There is a dormant resilient cyst and an infective trophozoite form.

Acanthamoeba keratitis is often misdiagnosed and treated as herpetic, bacterial, or mycotic keratitis, as many signs and symptoms may look similar to other kinds of keratitis. It is challenging for an ophthalmologist to find the right

diagnosis^{1,2}; therefore, diagnosis is often delayed and ophthalmologists tend to observe a heterogeneous and protracted clinical course.

Acanthamoeba physiology and life cycle

Acanthamoeba is present in two forms: trophozoites and cysts.

The so-called vegetative form, or trophozoite, has a size of 25–40 µms, and it feeds on bacteria, algae, and yeasts. Enterobacteria are especially preferred through acanthamoeba but some acanthamoeba species house bacteria as endosymbionts.³

The double-walled cysts have a 13–20 µm size and survive antibiotics, low temperatures (for example 15 months at –15 °C), high doses of UV-light, and γ-radiation. In case of

Conflict of interest: None.

* Corresponding author. Klinik für Augenheilkunde, Universität des Saarlandes, Kirrberger Straße 100, 66424, Homburg, Saar, Germany.

E-mail address: nora.szentmary@uks.eu (N. Szentmáry).

Peer review under responsibility of the Iranian Society of Ophthalmology.

<https://doi.org/10.1016/j.joco.2018.09.008>

2452-2325/Copyright © 2018, Iranian Society of Ophthalmology. Production and hosting by Elsevier B.V. This is an open access article under the CC BY-NC-ND license (<http://creativecommons.org/licenses/by-nc-nd/4.0/>).

adverse conditions, acanthamoeba trophozoites form cysts which may survive over 24 years.

Acanthamoeba are classified through their rDNA-sequence-types (T1–T12) (Stothard). Acanthamoeba keratitis most often occurs through the T4 genotype.^{4–10}

Acanthamoeba keratitis pathophysiology

In case of a corneal infection, as a first step, acanthamoeba are attached to the corneal epithelial cells through the Mannose-binding Protein. This binding supports secretion of metalloproteinase, serin- and cysteine proteinase through acanthamoeba, which results in cytotoxic effects on human corneal epithelial cells and keratocytes and supports deeper corneal penetration of acanthamoeba.^{11–13}

Acanthamoeba may also migrate along corneal nerves and damage these.^{14,15}

Epidemiology, risk factors, and prevention

The first reports on acanthamoeba keratitis were published in the seventies.^{16,17} With increasing use of contact lenses, its incidence already increased in the 80s,^{18–20} and it was 1/30.000 contact lens wearers in the 90s (Great-Britain, Hong Kong).²¹ Nowadays, about 5% of contact-lens-associated keratitis is caused by acanthamoeba.^{22,23}

The main risk factors are extended use of contact lenses (therefore, daily lenses have a lower risk),^{24–26} use of contact lenses during bath, and cleaning them with tap water.²⁷ Additional risk factors are corneal surface damage, exposition to contaminated water, and low socioeconomic status.^{28,29}

A study has proven that only hydrogen-peroxide-containing contact lens cleaners are effective against all acanthamoeba strains.³⁰

Acanthamoeba keratitis diagnostics

In the case of clinical signs of acanthamoeba keratitis, diagnostics always have to be performed. We use in vivo confocal microscopy and as in vitro diagnostics, polymerase-chain-reaction (PCR), histopathological examination, or microbiological culture.^{31–35} All diagnostic methods, including the analyzed material and the sensitivity of the method are summarized at Table 1.

As a first step, we recognized clinical signs of acanthamoeba keratitis to use the appropriate diagnostic methods. These are summarized below.

PCR of corneal scrapings has with 84–100% the highest sensitivity and may give a result within 60 min.^{36–39} However, PCR may have the disadvantage that also not living acanthamoeba genome may give a positive result.³

In vivo confocal microscopy has more than 90% sensitivity in experienced hands; however, only acanthamoeba cysts are well recognized using this method.^{33–35}

In vitro culture may have 0–70% sensitivity. This technique uses the fact the acanthamoeba grows well on *Escherichia coli* (*E. coli*), and acanthamoeba forms lines in an E.

coli-covered plate. This method has the disadvantage of giving results within 3 weeks.^{40–42}

Presence of acanthamoeba may also be verified through *histopathological analysis*, with 31–65% sensitivity. Corneal scrapings or excision or explanted tissue from keratoplasty may be analyzed using periodic acid Schiff, Masson, Gram, Giemsa, Grocott-methenamine-silver, or calcofluor-white stainings.^{36,43,44}

Clinical symptoms

In early stages of the disease, about 75–90% of all patients are misdiagnosed, as typical acanthamoeba keratitis symptoms are difficult to associate.^{5,9} Analysis of the German Acanthamoeba Keratitis Registry have shown that in 47.6% herpetic, in 25.2% mycotic, and in 3.9% bacterial keratitis was erroneously diagnosed by ophthalmologist in acanthamoeba keratitis patients.³³ Patients had the correct acanthamoeba keratitis diagnosis not before 2.8 ± 4.0 months (range, 0–23 months) after appearance of the first clinical symptoms, in Germany.³³

In about 23% of the cases,^{2,31,44–46} a mixed infection with virus, bacteria, or fungi is present.

Clinical signs of acanthamoeba keratitis are the following^{44–55} (Table 2):

- Chameleon-like epithelial changes ("dirty epithelium", pseudodendritiformic epitheliopathy, epithelial micro-erosions, and microcysts) (Fig. 1A)
- Multifocal stromal infiltrates (Fig. 2A)
- Ring infiltrate ("Wessely immune ring") (Figs. 1B and 2A)
- Peripheral perineurial infiltrate (Fig. 3)
- Common complications: broad-based anterior synechiae, secondary glaucoma, iris atrophy, mature cataract (Fig. 4), persistent endothelial defect
- Rare complications: sterile anterior uveitis, scleritis (Fig. 4)
- Very rare complications: chorioretinitis and retinal vasculitis

Table 1

We use in vivo confocal microscopy and as in vitro diagnostics polymerase-chain-reaction (PCR), histopathological examination, or microbiological culture in acanthamoeba keratitis.^{2,31–34}

Diagnostic method	Analyzed material	Sensitivity
In-vivo confocal microscopy	In vivo corneal examination	Above 90% with experienced examiner
Polymerase-chain reaction (PCR)	Corneal scrapings (epithelium) or corneal biopsy + contact lense case and cleaning solution	84–100%
In-vitro culture	Corneal scrapings (epithelium) or corneal biopsy + contact lense case and cleaning solution	0–77%
Histopathological analysis	Corneal scrapings or excision or explanted tissue from keratoplasty	31–65%

Table 2
Clinical symptoms and their timely presentation in acanthamoeba keratitis.

Clinical symptom	Time	Special properties
Chameleon-like epithelial changes (“dirty epithelium”) (Fig. 1A)	Within the first 2 weeks in 50% of the patients	Grey epithelial opacities, pseudodendritiform epitheliopathy, epithelial microerosions or microcysts
Multifocal stromal infiltrates (Fig. 2A)	Within the first 2 weeks	Mostly central and paracentral
Ringinfiltrate/Wessely immune ring (Figs. 1B and 2A)	In the first month in 20% of the patients	From polymorphonuclear leukocytes, antigen-antibody-komplex and complement; incidence increases with time
Perineural infiltrate (Fig. 3)	In the first month of the disease in 2.5–63% of the patients	Radial, from limbus to middle stroma, results in loss of corneal nerve fibers
Sterile anterior uveitis, scleritis, broad-based anterior synechiae, secondary glaucoma, iris atrophie, mature cataract (Fig. 4), chorioretinitis, retinal vasculitis	Late symptoms, following months	Rare Reason unknown (treatment or disease?). ^{56,57}

Differential diagnosis

“Dirty epithelium” and pseudodendritiform epitheliopathy have to be differentiated from an epithelial *herpetic* keratitis (dendritic or geographic). These do not have round spot-like widenings at the endings of the epithelial erosions, unlike herpetic epithelial keratitis.

In absence of bacterial or mycotic superinfection of an acanthamoeba keratitis, the stromal infiltrates in acanthamoeba keratitis are multifocal, dot-like (like unsharp-edged stromal stars), and in part transparent in an early stage of the disease. In contrast, *bacterial* or *mycotic* stromal infiltrates are thicker and typically monofocal. Nevertheless, satellite infiltrates in fungal keratitis may imitate multifocal stromal infiltrates of acanthamoeba keratitis.

The Wessely immune ring may be present in bacterial, mycotic, or acanthamoeba keratitis. The clinical image of the stromal infiltrates at the same time differentiates these clinical entities.

Acanthamoeba keratitis treatment

There are only case series on safety and effectivity of medical and surgical treatment of acanthamoeba keratitis, and there are no randomized, controlled, clinical studies to date.

Conservative treatment

Diamidine and biguanide

Diamidines, such as propamide-isethionate (Brolene), hexamidine-diisethionate (Hexacyl), and dibromopropamide

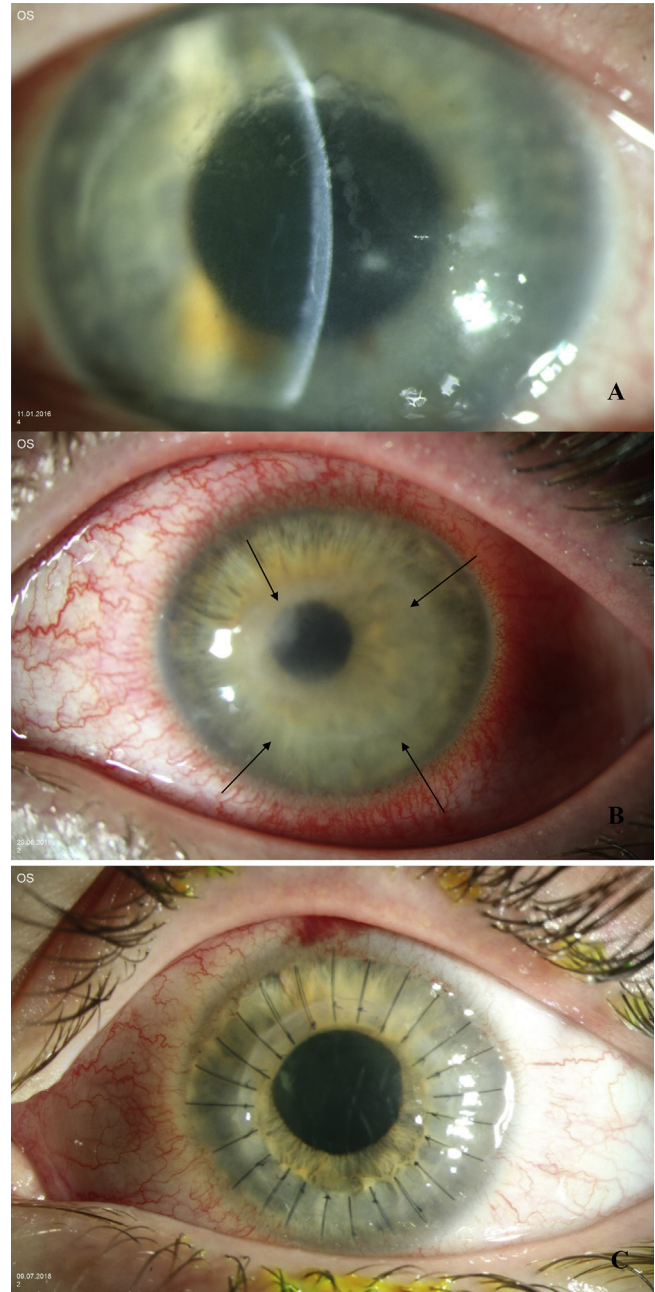


Fig. 1. “Dirty epithelium” (A), ring infiltrate (arrows) (B), and six months later excimer laser penetrating keratoplasty with interrupted sutures (C), in acanthamoeba keratitis.

(Golden Eye) are used in 0.1% concentration.^{58–60} *Biguanides*, such as polyhexamethylene-biguanide (polyhexanid) (Lavasept), and chlorhexidine (Curasept) are applied in 0.02% concentration.²

The concentration dependent effect of diamidines and biguanides on human epithelial cells, keratocytes, and endothelial cells have already been described, and propamide-isethionate as diamidine and chlorhexidine as biguanide seem to be the least cytotoxic. However, these may reduce proliferation and migration of human corneal cells more than other diamidines and biguanides.⁶¹

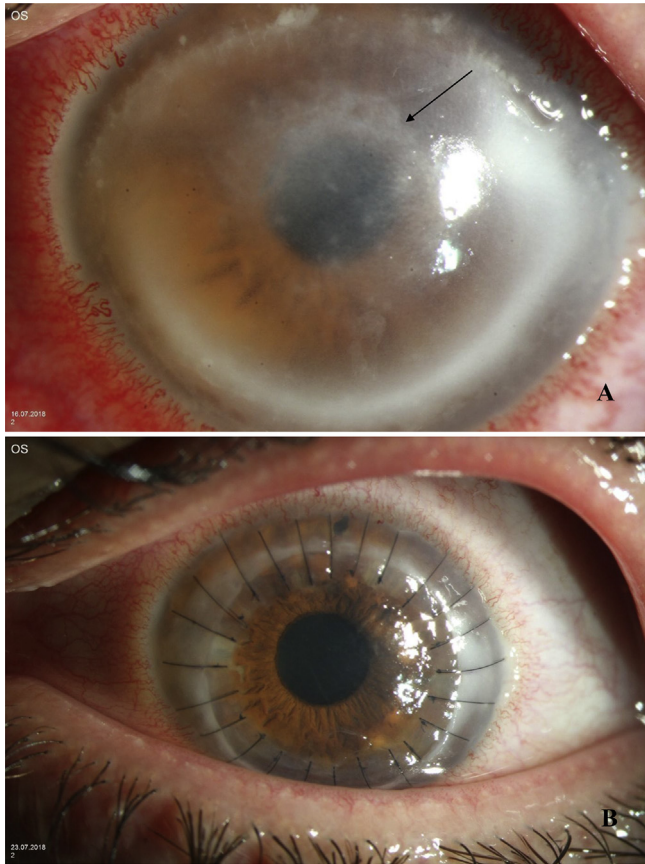


Fig. 2. Incomplete ring infiltrate (arrow) and multifocal stromal infiltrates in acanthamoeba keratitis (A). One week later excimer laser penetrating keratoplasty with interrupted sutures (B).

Antibiotics

Neomycin kills trophozoites, prevents bacterial superinfection,⁶² and reduces bacterial load, as a food source for acanthamoeba.²

Povidone-iodine and miltefosine

An in vitro experiment reported on a better anticystic effect of 1% povidone-iodine as propamidine-isethionate or polyhexanide. However, clinical studies did not verify these results.⁶³

Miltefosine was effective against acanthamoeba in vitro.⁶⁴

Steroids

Topical use of steroids may mask clinical signs of acanthamoeba keratitis as long as these are used. Their disadvantage is that they support encystment and an increase in number of trophozoites. However, a patient with acanthamoeba keratitis and severe inflammation may also benefit from their use. Steroids should never be used without additional topical antiseptics and should never be applied at early stages of acanthamoeba keratitis treatment (never in the first week even after appropriate diagnosis).^{65,66} In the case of stopping topical steroids, a Wessely immune ring may develop within 2 days in patients with acanthamoeba keratitis.

Antifungals

Miconazole and clotrimazole have been previously used as topical treatment of acanthamoeba keratitis.^{67,68} In addition, there are reports on local and systemic voriconazole use in these patients.^{67–69} An in vitro study described better anticystic effects using natamycin in contrast to propamidine-isethionate or polyhexamethylene-biguanide.⁶³ However, data on clinical use of natamycin in acanthamoeba keratitis patients is not available.

In Germany, we suggest topical application of polyhexamethylene-biguanide, propamidine-isethionate, and neomycin as triple-therapy in case of acanthamoeba keratitis.² To date, there is no randomized controlled clinical trial on safety and efficacy of conservative treatment in acanthamoeba keratitis.

During the first two days a “surprise attack” or “flash war” is initiated with polyhexamethylene-biguanide and propamidine-isethionate every quarter to half and hour day and night. Then until the sixth day, polyhexamethylene-biguanide and propamidine-isethionate are applied every hour and only over the day (6:00–24:00). The following 4 weeks, eyedrop use is reduced to every 2 h. Additionally, neomycin 5× a day is also applied.⁶² In therapy resistant cases, we may change polyhexamethylene-biguanide to chlorhexidine, or increase concentration (for polyhexamethylene-biguanide to 0.06%, for chlorhexidine to 0.2%).

To the best of our actual knowledge, combination therapy using diamidine, biguanide, and antibiotics should be continued in descending doses for 1 year. However, in case of non-healing epithelial defects after penetrating keratoplasty, we may reduce use of diamidine and biguanide with 1 drop every two months.

Surgical treatment

Through diagnostic and therapeutic epithelial abrasion, we remove microorganisms and get a better penetration of topical medication.⁷⁰ If topical conservative treatment does not improve clinical signs and symptoms, a corneal cryotherapy, amniotic membrane transplantation, or penetrating keratoplasty may be performed. In therapy resistant cases, a cross-linking treatment as photodynamic therapy maybe used, in some cases repeatedly.

Corneal cryotherapy is an adjuvant treatment of topical therapy. The infected corneal areas or the recipient area before penetrating keratoplasty will be treated using a Cold Cryoprobe 2–3 times (“freeze-thaw-freeze”) until ice crystals are formed in the corneal stroma.⁷¹ As part of a penetrating keratoplasty, cryotherapy is circularly used (about 2 s at –80 °C to the recipient bed) before recipient trephination. The effect of this type of cryotherapy on limbal epithelial stem cells has not been clarified to date.

An *amniotic membrane transplantation* (AMT) may be used, especially for persistent epithelial defects or ulcers as “Patch”, “Graft”, or “Sandwich” and may help reach a quiet stage of the eye.⁷² In many cases, AMT has to be repeated several times to reach epithelial closure.

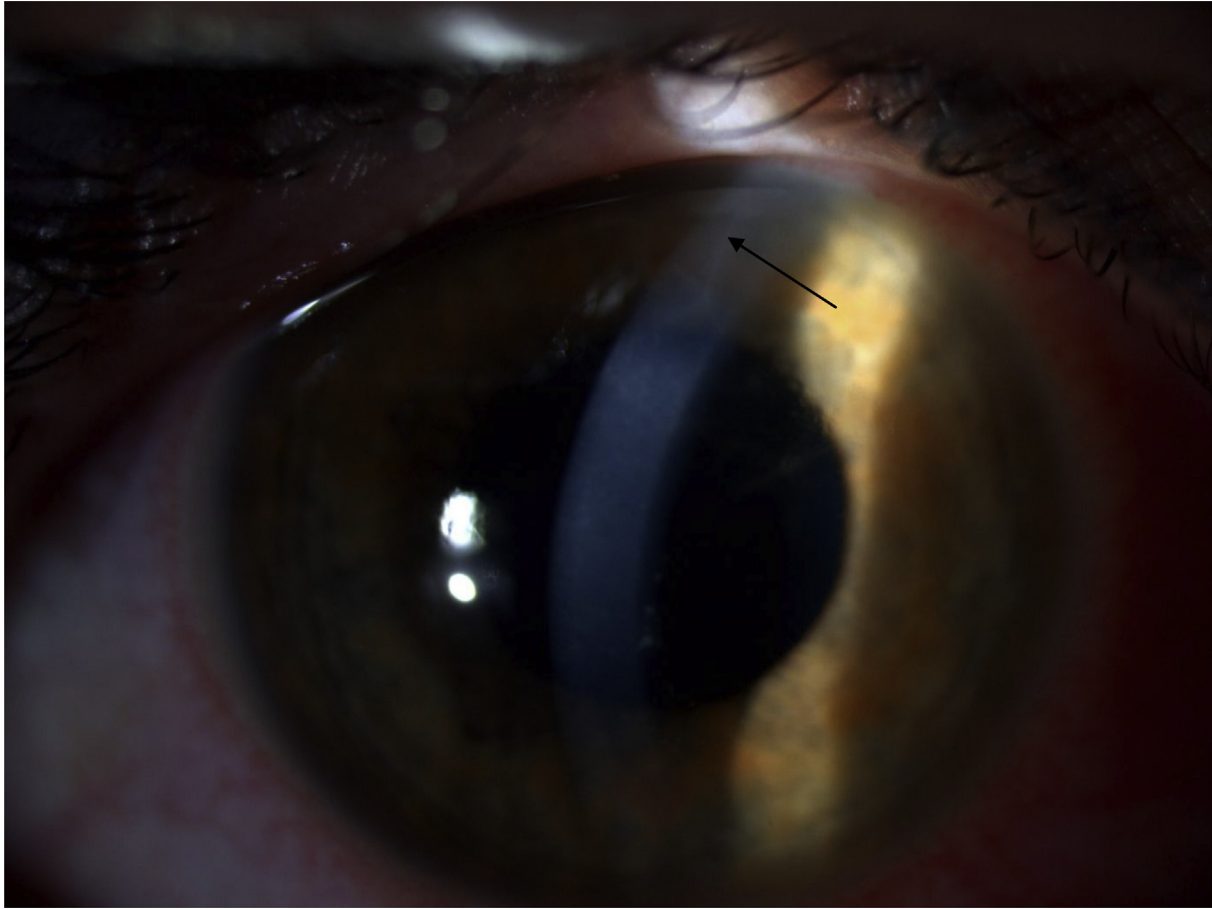


Fig. 3. Perineuritis in acanthamoeba keratitis (arrow), 4 weeks after first symptoms (contact lens wearer).

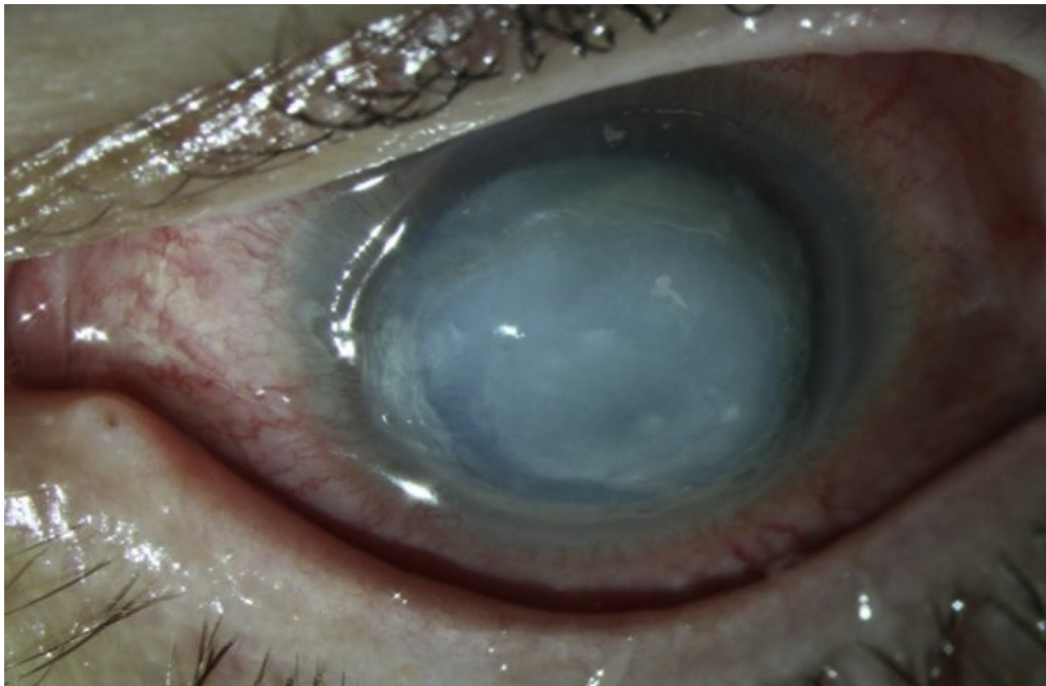


Fig. 4. Scleritis, corneal ulcer, iris atrophy, persistent mydriasis, and mature cataract in severe acanthamoeba keratitis.

Photodynamic therapy (PDT) may be an alternative treatment option in therapy resistant infectious keratitis.⁷³ The successful use of riboflavin-UVA cross-linking in acanthamoeba keratitis has been summarized in a case series in 2011.⁷⁴ Nevertheless, in case of stromal infiltrates, UVA-light penetration to the corneal stroma may be reduced. An accelerated cross-linking in acanthamoeba keratitis is not suggested.

In the case of acanthamoeba keratitis expansion in direction of the corneoscleral limbus, an early penetrating keratoplasty has to be done in order to perform the excision in uninfected corneal tissue. In the case of progressive, therapy-resistant ulceration over weeks and months with peripheral reparative neovascularization, we suggest an early (<5 months disease course) à chaud penetrating keratoplasty⁷⁵ (Figs. 1C and 2B). The origin of frequent therapy-resistant epithelial defects at the transplanted tissue after penetrating keratoplasty has not been clarified yet. Potential treatment options of these epithelial defects are (1) autologous serum, (2) AMT, (3) Cacicol or, (4) Neurotrophic Growth Factor (NGF).

Following penetrating keratoplasty, we continue the use of the above-described topical treatment up to 1 year.^{2,76} However, there are also no controlled clinical trials related to this topic. Perhaps local therapy may be stopped earlier, in order to avoid persistent epithelial defects, peripheral anterior synechiae, and mature cataract. Confocal microscopy may be useful in diagnosis of acanthamoeba keratitis recurrences.³²

In the case of perforated corneal ulcers, a non-mechanical, excimer laser keratoplasty is best performed.⁷⁷ Using an elliptical excimer laser trephination with metal masks, we may remove the infected corneal area with a more homogeneous distance from the limbal vessels, especially in typically elliptical-shaped acanthamoeba keratitis.⁷⁸

Some authors suggest at least a 3 month long observation period without inflammatory signs, following discontinuation of conservative therapy, before planning an elective penetrating keratoplasty, following acanthamoeba keratitis. In such elective penetrating keratoplasties, transplantate survival may be 100% after 5 years and 67% after 10 years.^{75,79}

In summary, acanthamoeba keratitis presents in early stages with grey-dirty epithelium, pseudodendritiform epitheliopathy, perineuritis, multifocal stromal infiltrates, ring infiltrates, and in later stages with scleritis, iris atrophy, anterior synechiae, secondary glaucoma, mature cataract, and chorioretinitis. As conservative treatment, we use up to one year triple-topical therapy (polyhexamethylene-biguanide, propamidine-ithionate, neomycin). In therapy resistant cases, surgical treatment options such as corneal cryotherapy, amniotic membrane transplantation, riboflavin-UVA cross-linking, and penetrating keratoplasty may be applied.

References

- Meltendorf C, Duncker G. Acanthamoeba keratitis. *Klin Monatsbl Augenheilkd.* 2011;228(3):R29–R43 [Article in German].
- Szentmáry N, Göbels S, Matoula P, Schirra F, Seitz B. Acanthamoeba keratitis – a rare and often late diagnosed disease. *Klin Monbl Augenheilkd.* 2012;229(5):521–528 [Article in German].
- Weekers PH, Bodelier PL, Wijen JP, Vogels GD. Effects of grazing by the free-living soil amoebae *Acanthamoeba castellanii*, *Acanthamoeba polyphaga*, and *Hartmannella vermiformis* on various bacteria. *Appl Environ Microbiol.* 1993;59(7):2317–2319.
- Gupta S, Das SR. Stock cultures of free-living amoebae: effect of temperature on viability and pathogenicity. *J Parasitol.* 1999;85(1):137–139.
- De Jonckheere J, van de Voorde H. Differences in destruction of cysts of pathogenic and nonpathogenic *Naegleria* and *Acanthamoeba* by chlorine. *Appl Environ Microbiol.* 1976;31(2):294–297.
- Khunkitti W, Lloyd D, Furr JR, Russell AD. *Acanthamoeba castellanii*: growth, encystment, excystment and biocide susceptibility. *J Infect Dis.* 1998;36(1):43–48.
- Brown TJ, Cursons RT. Pathogenic free-living amoebae (PFLA) from frozen swimming areas in Oslo, Norway. *Scand J Infect Dis.* 1977;9(3):237–240.
- Aksozek A, McClellan K, Howard K, Niederkorn JY, Alizadeh H. Resistance of *Acanthamoeba castellanii* cysts to physical, chemical, and radiological conditions. *J Parasitol.* 2002;88(3):621–623.
- Mazur T, Hadas E, Iwanicka I. The duration of the cyst stage and the viability and virulence of *Acanthamoeba* isolates. *Trop Med Parasitol.* 1995;46(2):106–108.
- Stothard DR, Hay J, Schroeder-Deidrich JM, Seal DV, Byers TJ. Fluorescent oligonucleotide probes for clinical and environmental detection of *Acanthamoeba* and the T4 18S rRNA gene sequence type. *J Clin Microbiol.* 1999;37(8):2687–2693.
- Panjwani N. Pathogenesis of acanthamoeba keratitis. *Ocul Surf.* 2010;8(2):70–79.
- Clarke DW, Niederkorn JY. The pathophysiology of *Acanthamoeba* keratitis. *Trends Parasitol.* 2006;22(4):175–180.
- Hadas E, Mazur T. Proteolytic enzymes of pathogenic and non-pathogenic strains of *Acanthamoeba* spp. *Trop Med Parasitol.* 1993;44(3):197–200.
- Moore MB, McCulley JP, Kaufman HE, Robin JB. Radial keratoneuritis as a presenting sign in *Acanthamoeba* keratitis. *Ophthalmology.* 1986;93(10):1310–1315.
- Alfawaz A. Radial keratoneuritis as a presenting sign in *Acanthamoeba* keratitis. *Middle East Afr J Ophthalmol.* 2011;18(3):252–255.
- Naginton J, Watson PG, Payfair TJ, McGill J, Jones BR, Steele AD. Amoebic infection of the eye. *Lancet.* 1974;2(7896):1537–1540.
- Jones DB, Visvesvara GS, Robinson NM. *Acanthamoeba polyphaga* keratitis and *Acanthamoeba* uveitis associated with fatal meningoencephalitis. *Trans Ophthalmol Soc U K.* 1975;95(2):221–232.
- Ku JY, Chan FM, Beckingsale P. *Acanthamoeba* keratitis cluster: and increase in *Acanthamoeba* keratitis in Australia. *Clin Exp Ophthalmol.* 2009;37(2):181–190.
- Moore MB, McCulley JP, Newton C, et al. *Acanthamoeba* keratitis. A growing problem in soft and hard contact lens wearers. *Ophthalmology.* 1987;94(12):1654–1661.
- Schaumberg DA, Snow KK, Dana MR. The epidemic of *Acanthamoeba* keratitis: where do we stand? *Cornea.* 1998;17(1):3–10.
- Seal DV. *Acanthamoeba* keratitis update – incidence, molecular epidemiology and new drugs for treatment. *Eye (Lond).* 2003;17(8):893–905.
- Butler TK, Males JJ, Robinson LP, et al. Six-year review of *acanthamoeba* keratitis in new south wales, Australia: 1997–2002. *Clin Exp Ophthalmol.* 2005;33(1):41–46.
- Acharya NR, Lietman TM, Margolis TP. Parasites on the rise: a new epidemic of *Acanthamoeba* keratitis. *Am J Ophthalmol.* 2007;144(2):292–293.
- McAllum P, Bahar I, Kaiserman I, Srinivasan S, Slomovic A, Rootman D. Temporal and seasonal trends in *Acanthamoeba* keratitis. *Cornea.* 2009;28(1):7–10.
- Radford CF, Lehmann OJ, Dart JK. National *acanthamoeba* keratitis study group. *Acanthamoeba* keratitis: multicentre survey in England 1992–1996. *Br J Ophthalmol.* 1998;82(12):1387–1392.
- Chew HF, Yildiz EH, Hammersmith KM, et al. Clinical outcomes and prognostic factors associated with *acanthamoeba* keratitis. *Cornea.* 2011;30(4):435–441.
- Hammersmith KM. Diagnosis and management of *Acanthamoeba* keratitis. *Curr Opin Ophthalmol.* 2006;17(4):327–331.

28. Stehr-Green JK, Bailey TM, Visvesvara GS. The epidemiology of Acanthamoeba keratitis in the United States. *Am J Ophthalmol.* 1989; 107(4):331–336.
29. Sharma S, Garg P, Rao GN. Patient characteristics, diagnosis, and treatment of non-contact lens related Acanthamoeba keratitis. *Br J Ophthalmol.* 2000;84(10):1103–1108.
30. Johnston SP, Sriram R, Qvarnstrom Y, et al. Resistance of Acanthamoeba cysts to disinfection in multiple contact lens solutions. *J Clin Microbiol.* 2009;47(7):2040–2045.
31. Dart JK, Saw VP, Kilvington S. Acanthamoeba keratitis: diagnosis and treatment update 2009. *Am J Ophthalmol.* 2009;148(4):487–499.
32. Daas L, Viestenz A, Schnabel P, et al. Confocal microscopy in acanthamoeba keratitis as an early relapse-marker. *Clin Anat.* 2018;31(1):60–63.
33. Daas L, Szentmáry N, Eppig T, et al. The German acanthamoeba keratitis register: initial results of a multicenter study. *Ophthalmologie.* 2015; 112(9):752–763 [Article in German].
34. Pfister DR, Cameron JD, Krachmer JH, Holland EJ. Confocal microscopy findings of Acanthamoeba keratitis. *Am J Ophthalmol.* 1996;121(2): 119–128.
35. Duguid IG, Dart JK, Morlet N, et al. Outcome of acanthamoeba keratitis treated with polyhexamethyl biguanide and propamidine. *Ophthalmology.* 1997;104(10):1587–1592.
36. Lehmann OJ, Green SM, Morlet N, et al. Polymerase chain reaction analysis of corneal epithelial and tear samples in the diagnosis of Acanthamoeba keratitis. *Invest Ophthalmol Vis Sci.* 1998;39(7):1261–1265.
37. Qvarnstrom Y, Visvesvara GS, Sriram R, da Silva AJ. Multiplex real-time PCR assay for simultaneous detection of Acanthamoeba spp., Balamuthia mandrillaris, and Naegleria fowleri. *J Clin Microbiol.* 2006;44(10): 3589–3595.
38. Thompson PP, Kowalski RP, Shanks RM, Gordon YJ. Validation of real-time PCR for laboratory diagnosis of Acanthamoeba keratitis. *J Clin Microbiol.* 2008;46(10):3232–3236.
39. Mathers WD, Sutphin JE, Folberg R, Meier PA, Wenzel RP, Elgin RG. Outbreak of keratitis presumed to be caused by Acanthamoeba. *Am J Ophthalmol.* 1996;121(2):129–142.
40. Reinhard T, Behrens-Baumann W. Anti-infective drug therapy in ophthalmology – part 4: acanthamoeba keratitis. *Klin Monatsbl Augenheilkd.* 2006;223(6):485–491.
41. Aspöck H. Grundzüge der Diagnostik. In: Hiepe T, Lucius R, Gottstein B, eds. *Allgemeine Parasitologie mit den Grundzügen der Immunologie, Diagnostik und Bekämpfung.* Stuttgart: Parey in MVS Medizinverlage; 2006:339–457.
42. Bacon AS, Frazer DG, Dart JK, Matheson M, Ficker LA, Wright P. A review of 72 consecutive cases of Acanthamoeba keratitis, 1984–1992. *Eye (Lond).* 1993;7(Pt. 6):719–725.
43. Sharma S, Athmanathan S, Atha-Ur-Rasheed M, Garg P, Rao GN. Evaluation of immunoperoxidase staining technique in the diagnosis of Acanthamoeba keratitis. *Indian J Ophthalmol.* 2001;49(3):181–186.
44. Claerhout I, Goeghebuer A, Van Den Broecke C, Kestelyn P. Delay in diagnosis and outcome of Acanthamoeba keratitis. *Graefes Arch Clin Exp Ophthalmol.* 2004;42(8):648–653.
45. Awwad ST, Petroll WM, McCulley JP, Cavanagh HD. Updates in acanthamoeba keratitis. *Eye Contact Lens.* 2007;33(1):1–8.
46. Perry HD, Donnenfeld ED, Foulks GN, Moadel K, Kanellopoulos AJ. Decreased corneal sensation as an initial feature of Acanthamoeba keratitis. *Ophthalmology.* 1995;102(10):1565–1568.
47. Patel DV, McGhee CN. Acanthamoeba keratitis: a comprehensive photographic reference of common and uncommon signs. *Clin Exp Ophthalmol.* 2009;37(2):232–238.
48. Papatianassiou M, Gartry D. Steril corneal ulcer with ring infiltrate and hypopyon after recurrent erosions. *Eye.* 2007;21(1):124–126.
49. Thomas KE, Purcell TL, Tanzer DJ, Schanzlin DJ. Delayed diagnosis of microsporidial stromal keratitis: unusual Wessely ring presentation and partial treatment with medications against Acanthamoeba. *BMJ Case Rep.* 2011 Feb 24;2011. <https://doi.org/10.1136/bcr.08.2010.3233>. bcr0820103233.
50. Kremer I, Cohen EJ, Eagle Jr RC, Udell I, Laibson PR. Histopathologic evaluation of stromal inflammation in Acanthamoeba keratitis. *CLAO J.* 1994;20(1):45–48.
51. Clarke DW, Alizadeh H, Niederkorn JY. Failure of Acanthamoeba castellanii to produce intraocular infections. *Invest Ophthalmol Vis Sci.* 2005; 46(7):2472–2478.
52. Shigeyasu C, Shimazaki J. Ocular surface reconstruction after exposure to high concentrations of antiseptic solutions. *Cornea.* 2012;31(1):59–65.
53. Awwad ST, Heilman M, Hogan RN, et al. Severe reactive ischemic posterior segment inflammation in acanthamoeba keratitis: a new potentially blinding syndrome. *Ophthalmology.* 2007;114(2):313–320.
54. Herz NL, Matoba AY, Wilhelmus KR. Rapidly progressive cataract and iris atrophy during treatment of Acanthamoeba keratitis. *Ophthalmology.* 2008;115(5):866–869.
55. Kelley PS, Dossey AP, Patel D, Whitson JT, Hogan RN, Cavanagh HD. Secondary glaucoma associated with advanced acanthamoeba keratitis. *Eye Contact Lens.* 2006;32(4):178–182.
56. Ehlers N, Hjordtal J. Are cataract and iris atrophy toxic complications of medical treatment of acanthamoeba keratitis? *Acta Ophthalmol Scand.* 2004;82(2):228–231.
57. Iovieno A, Gore DM, Carnt N, Dart JK. Acanthamoeba sclerokeratitis: epidemiology, clinical features and treatment outcomes. *Ophthalmology.* 2014;121(12):2340–2347.
58. Larkin DF, Kilvington S, Dart JK. Treatment of Acanthamoeba keratitis with polyhexamethylene biguanide. *Ophthalmology.* 1992;99(2): 185–191.
59. Ficker L, Seal D, Warhurst D, Wright P. Acanthamoeba keratitis – resistance to medical therapy. *Eye (Lond).* 1990;4(Pt. 6):835–838.
60. Wright P, Warhurst D, Jones BR. Acanthamoeba keratitis successfully treated medically. *Br J Ophthalmol.* 1985;69(10):778–782.
61. Shi L, Stachon T, Seitz B, Wagenpfeil S, Langenbacher A, Szentmáry N. The effect of anti-amoebic agents on viability, proliferation and migration of human epithelial cells, keratocytes and endothelial cells, in vitro. *Curr Eye Res.* 2018;43(6):725–733.
62. Elder MJ, Kilvington S, Dart JK. A clinicopathologic study of in vitro sensitivity testing and Acanthamoeba keratitis. *Invest Ophthalmol Vis Sci.* 1994;35(3):1059–1064.
63. Sunada A, Kimura K, Nishi K, et al. In vitro evaluations of topical agents to treat acanthamoeba keratitis. *Ophthalmology.* 2014;121(10): 2059–2065.
64. Polat ZA, Walochnik J, Obwaller A, Vural A, Dursun A, Arici MK. Miltefosine and polyhexamethylene biguanide: a new drug combination for the treatment of Acanthamoeba keratitis. *Clin Exp Ophthalmol.* 2014; 42(2):151–158.
65. McClellan K, Howard K, Niederkorn JY, Alizadeh H. Effect of steroids on Acanthamoeba cysts and trophozoites. *Invest Ophthalmol Vis Sci.* 2001; 42(12):2885–2893.
66. Carnt N, Optom B, Robaei D, Minassian DC, Dart JK. The impact of topical corticosteroids used in conjunction with anti-amoebic therapy on the outcome of acanthamoeba keratitis. *Ophthalmology.* 2016;123(5): 984–990.
67. D'Aversa G, Stern GA, Driebe Jr WT. Diagnosis and successful medical treatment of Acanthamoeba keratitis. *Arch Ophthalmol.* 1995;113(9): 1120–1123.
68. Amoils SP, Heney C. Acanthamoeba keratitis with live isolates treated with cryosurgery and fluconazole. *Am J Ophthalmol.* 1999;127(6): 718–720.
69. Oldenburg CE, Acharya NR, Tu EZ, et al. Practice patterns and opinions in the treatment of acanthamoeba keratitis. *Cornea.* 2011;30(12):1363–1368.
70. Brooks Jr JG, Coster DJ, Badenoch PR. Acanthamoeba keratitis. Resolution after epithelial debridement. *Cornea.* 1994;13(2):186–189.
71. Klüppel M, Reinhard T, Sundmacher R, Daicker B. Therapy of advanced amoeba keratitis with keratoplasty à chaud and adjuvant cryotherapy. *Ophthalmologie.* 1997;94(2):99–103 [Article in German].
72. Seitz B, Resch MD, Schlötzer-Schrehardt U, Hofmann-Rummelt C, Sauer R, Kruse FE. Histopathology and ultrastructure of human corneas after amniotic membrane transplantation. *Arch Ophthalmol.* 2006; 124(10):1487–1490.
73. Szentmáry N, Goebels S, Bischoff M, Seitz B. Photodynamic therapy (PDT) for infectious keratitis. *Ophthalmologie.* 2012;109(2):165–170 [Article in German].

74. Khan YA, Kashiwabuchi RT, Martins SA, et al. Riboflavin and ultraviolet light a therapy as an adjuvant treatment for medically refractive Acanthamoeba keratitis: report of 3 cases. *Ophthalmology*. 2011;118(2):324–331.
75. Laurik KL, Szentmáry N, Daas L, et al. *Penetrating keratoplasty à chaud in acute acanthamoeba keratitis*. 2016 [ARVO abstract].
76. Hager T, Hasenbusch A, Stachon T, Seitz B, Szentmáry N. Crosslinking and corneal cryotherapy in acanthamoeba keratitis – a histological study. *Graefes Arch Clin Exp Ophthalmol*. 2016;254(1):149–153.
77. Seitz B, Langenbucher A, Kus MM, Kühle M, Naumann GO. Nonmechanical corneal trephination with the excimer laser improves outcome after penetrating keratoplasty. *Ophthalmology*. 1999;106(6):1556–1564.
78. Szentmáry N, Langenbucher A, Kus MM, Naumann GO, Seitz B. Elliptical nonmechanical corneal trephination - intraoperative complications and long-term outcome of 42 consecutive penetrating keratoplasties. *Cornea*. 2007;26(4):414–420.
79. Robaei D, Carnt N, Minassian DC, Dart JK. Therapeutic and optical keratoplasty in the management of Acanthamoeba keratitis: risk factors, outcomes, and summary of the literature. *Ophthalmology*. 2015;122(1):17–24.