



Contents lists available at ScienceDirect

## International Journal of Surgery Case Reports

journal homepage: [www.casereports.com](http://www.casereports.com)

## Duodeno-colic fistula as a rare presentation of lung cancer – surgical treatment of a stage IV oligometastatic lung disease



Vitor Nunes<sup>a</sup>, Inês Santiago<sup>b</sup>, Rui Marinho<sup>a</sup>, David Pires<sup>a</sup>, Rita Theias<sup>c</sup>, António Gomes<sup>a,\*</sup>, Nuno Pignatelli<sup>a</sup>

<sup>a</sup> B Surgery Department, Hospital Fernando Fonseca, 2720-276 Amadora, Portugal

<sup>b</sup> Radiology Department, Hospital Fernando Fonseca, 2720-276 Amadora, Portugal

<sup>c</sup> Surgical Pathology Department, Hospital Fernando Fonseca, 2720-276 Amadora, Portugal

## ARTICLE INFO

## Article history:

Received 2 March 2015

Received in revised form 30 June 2015

Accepted 30 June 2015

Available online 9 July 2015

## Keywords:

Adenosquamous carcinoma

Lung cancer

Intestinal metastasis

Oligometastatic disease

## ABSTRACT

**INTRODUCTION:** Rare adenosquamous carcinomas have no defined standard approach given their low incidence. They present with nonspecific imaging characteristics and are described as having worse prognosis than other lung malignancies, with greater likelihood of local invasion and early metastasis. **PRESENTATION OF CASE:** Male caucasian patient, 43 years, 26 pack-year smoking history, presented with watery diarrhea, early emesis and loss of 25% body weight (20 kg) in four weeks. Colonoscopy identified a left colonic mass. Abdominal CT/ultrasound showed a large fistulous lesion between the 4th portion of the duodenum and left colon. CT showed a solid mass in the right upper lung lobe. Endoscopy and transthoracic biopsy were inconclusive. En bloc D3 and D4 duodenectomy, proximal enterectomy and left hemicolectomy were performed, with inconclusive histology of the specimen. Three months later, a right upper lung lobectomy with lymphadenectomy was performed, revealing an adenosquamous carcinoma of lung origin, R0, staged as pT2pN0pM1b. Six months later, a single dural metastasis in the left cerebellopontine angle was detected and resected, with subsequent holocranial radiotherapy and systemic adjuvant chemotherapy. Patient is currently with 18 months follow-up, in good general health and with no evidence of recurrent disease.

**DISCUSSION:** There are no specific guidelines to treat oligometastatic adenosquamous lung carcinoma. Our approach was abdominal surgery as a life-saving procedure and, months later, oncological resection of primary lung tumor and metachronous metastasis to the brain.

**CONCLUSION:** A systematic, patient-oriented, patient-shared, multidisciplinary approach is particularly relevant when dealing with atypical presentations of rare diseases in young patients.

© 2015 The Authors. Published by Elsevier Ltd. on behalf of Surgical Associates Ltd. This is an open access article under the CC BY-NC-ND license (<http://creativecommons.org/licenses/by-nc-nd/4.0/>).

### 1. Introduction

According to the WHO definition, an adenosquamous carcinoma is a tumor with adenocarcinoma differentiation and squamous cell carcinoma differentiation, each accounting for more than 10% of the tumor volume [1]. These are rare tumors [2–4], with a reported incidence between 0.3% and 5% of primary non-small cell lung tumors [2]. The described cases seem to show a preferential distribution in males and smokers [5], with a more often peripheral location [6].

Clinical presentation and imaging characteristics are nonspecific, although they seem to present as lobulated peripheral lesions, with intratumoral necrosis [7]. However, pulmonary carcinoid tumors, neuroendocrine tumors and pleomorphic tumors also

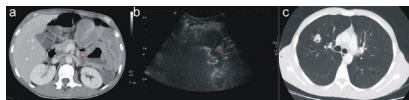
show this CT presentation [6,8–10]. Gastrointestinal symptoms are common in advanced cancer. They usually represent systemic deterioration or medication side effects [11]. Lung cancer initially presenting with gastrointestinal complaints is a rare situation, generally the direct effect of unusual metastatic sites [12].

The prognosis is traditionally described as poor compared to adenocarcinoma or squamous cell carcinoma [3,4,6,13], particularly in early stages for which surgical resection with curative intent is performed. Lymph node metastases, male sex, advanced tumor stage, tumor size above 5 cm and CT findings of inflammatory changes surrounding the tumor seem to be associated with a poor prognosis [6], although these data are based on a small number of single center studies.

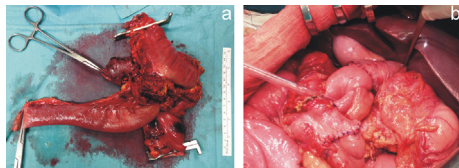
### 2. Presentation of case

Male patient, 43 years old, caucasian, with no relevant clinical history except for a 26 pack-year smoking history. The patient was

\* Corresponding author at: B Surgery Department Hospital, Prof. Doutor Fernando Fonseca Estrada, IC-19 2720-276 Amadora, Portugal. Fax: +351 21 434 55 66.  
E-mail address: [apsgomes@gmail.com](mailto:apsgomes@gmail.com) (A. Gomes).



**Fig. 1.** a. Axial MDCT image of the upper abdomen; b. Sagittal oblique US image of the upper abdomen; c. Axial MDCT image of the thorax.



**Fig. 2.** a. Surgical specimen. b. Surgical reconstruction with end-to-end handsewn duodenojejunosotomy and colorectal anastomosis.

admitted to the Emergency Room due to watery diarrhea with two weeks of evolution associated with early emesis and loss of 25% of body weight (20 kg) in four weeks. Blood analysis showed a ferropenic anemia, thrombocytosis, and mild CRP elevation. Analytical and microbiological studies were inconclusive regarding the etiology of the diarrhea. Colonoscopy revealed an ulcerated lesion in the splenic flexure with unsurpassable stenosis. Immunohistochemistry was suggestive of a poorly differentiated carcinoma, likely of gastric origin. Upper gastrointestinal endoscopy was normal. Abdominal and pelvic CT revealed a difficult to characterize mass of the proximal small intestine with infiltrative involvement of the left colon. Ultrasound of the upper abdomen with water administration per os showed involvement of the splenic flexure and 4th portion of the duodenum with fistulous track. There seemed to be no invasion of the third portion of the duodenum. Involvement of the pancreatic tail was difficult to assess. A single solid lesion in the right inferior lung lobe was suggestive of primary lung cancer (Fig. 1). Transthoracic needle biopsy revealed a poorly differentiated malignant neoplasm, inconclusive regarding the etiology: primary lesion of colon or prostate were excluded, but of the stomach, pancreas, kidney or lung could not be excluded. Bronchofibroscopy showed no significant changes. After a multidisciplinary meeting, laparotomy was chosen. Intraoperatively, an exophytic lesion involving the left colon and distal duodenum was found. An *en bloc* D3 and D4 duodenectomy, proximal enterectomy and left colectomy, with primary anastomosis were performed (Fig. 2). There were no surgical complications.

Histology of the surgical specimen revealed a poorly differentiated carcinoma with transmural involvement and fistulization, positive for CK7 and CK5 and negative for TTF1, Napsin and CK20 (Fig. 3). Despite the negativity for Napsin and TTF1, a malignancy of

lung origin with squamous differentiation could not be excluded. There was no vascular or perineural invasion, surgical margins were negative (R0), and all of 17 isolated nodes were negative for malignancy.

Three months after surgery, a positron emission tomography (PET) scan confirmed the previously describe single lung nodule in the right upper lobe, and the patient underwent right upper lobectomy. Histological study revealed positivity for CK7, CK5 and p63, and an adenosquamous carcinoma of the lung was diagnosed. All of the 8 isolated nodes were negative for malignancy. Complete resection of an adenosquamous carcinoma of the lung without lymph node involvement, staged as pT2pN0pM1b – R0, was confirmed. There were no surgical complications. The patient continued follow-up in the Oncology Department and was offered chemotherapy, which he declined.

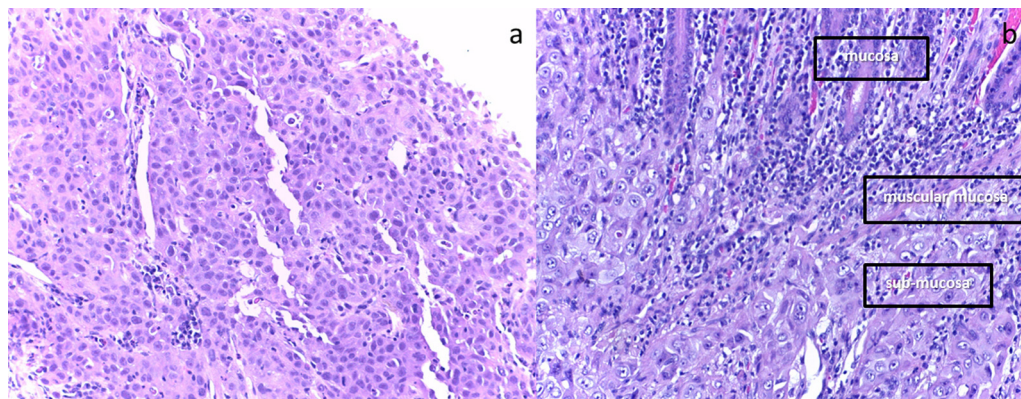
Six months after resection of the primary tumor, the patient was admitted to the ER due to dizziness, vomiting, and Romberg's test with deviation to the right. Cranioencephalic MRI showed a single dural metastasis in the left cerebellopontine angle (Fig. 4). Re-staging abdominopelvic CT showed no other metastatic sites. Brain metastasis was completely resected. Patient underwent subsequent holocraneal radiotherapy with 30 Gy/10 fractions, and systemic adjuvant paclitaxel and carboplatin, having performed four cycles.

Lung cancer patients at our Institution are usually evaluated every 3–6 months with clinical examination, biochemical work-up and contrast-enhanced CT of the thorax. In this patient, follow-up was adapted to clinical presentation, namely neurological and musculoskeletal symptoms.

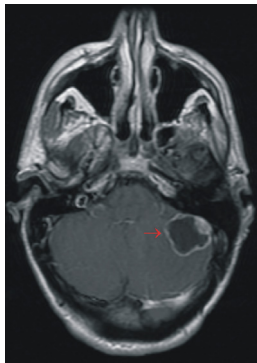
Currently with 18 months of follow-up, patient has no evidence of abdominal, thoracic or brain relapse, being asymptomatic and in good general health.

**3. Discussion**

Adenosquamous carcinomas are rare tumors [2–4], with non-specific clinical presentation and imaging characteristics [6–10]. Our patient presented with severe ion depleting diarrhea and rapid weight loss due to a large solid fistulous mass spanning between the 4th portion of the duodenum and the splenic flexure of the colon. Analytical and microbiological studies were inconclusive regarding diarrhea etiology. Immunohistochemistry was suggestive of a poorly differentiated carcinoma, likely of gastric origin. Axial CT images of the upper abdomen showed an 8 cm soft tissue mass in the left upper quadrant of the abdomen. It had a central necrotic area with an air-fluid level, spanning between the 4th part of the



**Fig. 3.** a. Pulmonary biopsy occupied by a solid tumor characterized by pleomorphic cells with irregular nucleus and prominent nucleol. b. Surgical specimen (small intestine) with a solid tumor in the submucosa which invades focally the mucosa.



**Fig. 4.** MR T1-weighted image of the brain after IV administration of paramagnetic contrast.

duodenum and the splenic flexure of the colon. Ultrasonography after oral administration of water revealed a large communication between the distal duodenum and the splenic flexure. Axial CT images of the thorax showed a 21 mm lung nodule with irregular, spiculated margins, and central lucencies in the upper right lung lobe, highly suspicious of a primary lung malignancy.

After a multidisciplinary meeting, and given the patient's age and rapidly declining previous excellent general condition, an *en bloc* resection of the proximal small intestine and left colon was performed, allowing symptomatic control and nutritional recovery.

Three months after surgery and due to the previously described lung nodule in the right upper lobe, the patient underwent a right upper lobectomy with lymphadenectomy. This surgery was not performed before because the patient's general health condition did not allow it. Histological study revealed positivity for CK7, CK5 and p63, and an adenosquamous carcinoma of the lung was diagnosed. Although paclitaxel and carboplatin are among the recommended regimens for the treatment of stage IV lung cancer, their relation to the timing of surgery is controversial, and their use is not supported by any guideline or recommendation. Nevertheless, and since this is the most used chemotherapy approach, the patient was offered this regimen as adjuvant chemotherapy for the primary lesion, which he declined.

Epidemiologically, our patient is in accordance with what is described in the literature for stage IV adenosquamous disease: male, smoker and peripheral lesion location [5,6]. The absence of lymph node metastasis is controversial, having been described as both common [5] and unusual [14] for similar cases. The majority of these patients appear to have a solitary metastasis preferentially to the brain [14]. In our case, 6 months after resection of the primary tumor, a single brain metastasis was detected in MRI. This brain metastasis was managed based on what is established: R0 tumor resection and holocranial radiotherapy.

Therefore, our patient had an atypical presentation of stage IV oligometastatic disease, with intra-abdominal metastasis to the small intestine and subsequently with brain metastasis.

There are no specific guidelines for the surgical treatment of primary and oligometastatic lung cancer [13], or for this particular histology situation with specific biological behavior, although patients without lymph node involvement should be considered as surgical candidates [14,15]. Therefore, common sense must prevail, together with information and decision sharing with the patient.

Given the atypical presentation of a rare disease, we emphasize the importance of a systematic, goal-oriented diagnosis in a multidisciplinary context. In this case, the first goal was symptomatic relief and life saving: stop the diarrhea and reverse the nutritional status, with subsequent primary tumor resection.

Currently with 18 months follow-up, the patient has no evidence of brain, thoracic, abdominal or pelvic relapse. There are no major sequelae and the patient has an acceptable quality of life.

#### 4. Conclusion

A systematic, goal-oriented, interdisciplinary approach followed by shared decision-making may result in exceptional solutions to rare problems with atypical presentation, which affects life and quality of life of a young active adult individual, seems to benefit the patient and influence the success of the outcome.

#### Conflicts of interest

None of the authors has any conflicts of interest regarding this paper.

#### Funding

No funding was received for this research. None of the authors has any financial, personal, or professional interests that could be construed to have influenced the paper.

#### Consent

The procedures followed were in accordance with the ethical standards of the Helsinki Declaration of the World Medical Association. The patient's written consent was obtained. The work has been approved by Hospital Professor Doutor Fernando da Fonseca ethical committee.

#### Acknowledgements

There are no acknowledgements regarding this paper.

#### References

- [1] W.D. Travis, T.V. Colby, B. Corrin, Y. Shimosato, E. Brambilla, L.H. Sobbin, Histological Typing of Lung and Pleural Tumours, in collaboration with L.B. Sobin and pathologists from 14 countries, 3rd ed., Springer Verlag, Berlin, 1999, Published on behalf of the World Health Organization.
- [2] D.T. Cooke, D.V. Nguyen, Y. Yang, S.L. Chen, C. Yu, R.F. Calhoun, Survival comparison of adenosquamous, squamous cell, and adenocarcinoma of the lung after lobectomy, *Ann. Thorac. Surg.* 90 (3) (2010) 943–948.
- [3] H. Maeda, A. Matsumura, T. Kawabata, T. Suito, O. Kawashima, T. Watanabe, et al., Adenosquamous carcinoma of the lung: surgical results as compared with squamous cell and adenocarcinoma cases, *Eur. J. Cardiothorac. Surg.* 41 (2) (2012) 357–361.
- [4] P.L. Filosso, E. Ruffini, S. Asioli, R. Giobbe, L. Macri, M.C. Bruna, et al., Adenosquamous lung carcinomas: a histologic subtype with poor prognosis, *Lung Cancer* 74 (1) (2011) 25–29.
- [5] T. Mukaida, M. Aoe, M. Yamashita, H. Date, K. Hara, A. Andoh, et al., A clinicopathological study of adenosquamous carcinoma of the lung, *Kyobu Geka* 49 (12) (1996) 975–979, Discussion 9–81.
- [6] Y. Watanabe, K. Tsuta, M. Kusumoto, A. Yoshida, K. Suzuki, H. Asamura, et al., Clinicopathologic features and computed tomographic findings of 52 surgically resected adenosquamous carcinomas of the lung, *Ann. Thorac. Surg.* 97 (1) (2014) 245–251.
- [7] J.Q. Yu, Z.G. Yang, J.H. Austin, Y.K. Guo, S.F. Zhang, Adenosquamous carcinoma of the lung: CT-pathological correlation, *Clin. Radiol.* 60 (3) (2005) 364–369.
- [8] Q.C. Meisinger, J.S. Klein, K.J. Butner, S. Gentsch, B.J. Leavitt, CT features of peripheral pulmonary carcinoid tumors, *AJR Am. J. Roentgenol.* 197 (5) (2011) 1073–1080.
- [9] T.H. Kim, S.J. Kim, Y.H. Ryu, H.J. Lee, J.M. Goo, J.G. Im, et al., Pleomorphic carcinoma of lung: comparison of CT features and pathologic findings, *Radiology* 232 (2) (2004) 554–559.
- [10] Y. Oshiro, M. Kusumoto, Y. Matsuno, H. Asamura, R. Tsuchiya, H. Terasaki, et al., CT findings of surgically resected large cell neuroendocrine carcinoma of the lung in 38 patients, *AJR Am. J. Roentgenol.* 182 (1) (2004) 87–91.
- [11] P. Amy Abernethy, L. Jane Wheeler, S. Yousuf Zafar, Management of gastrointestinal symptoms in advanced cancer patients: The rapid learning cancer clinic model, *Curr. Opin. Support Palliat Care* 4 (1) (2010) 36–45.
- [12] D. Gulati, M. Tama, M. Mutchnick, Unusual cause of upper GI bleed in a patient with lung cancer, *Gastroenterology* 147 (August (2)) (2014) 287–288.

- [13] J. Gawrychowski, K. Brulinski, E. Malinowski, B. Papla, Prognosis and survival after radical resection of primary adenosquamous lung carcinoma, *Eur. J. Cardiothorac Surg.* 27 (4) (2005) 686–692.
- [14] G.H. Griffioen, D. Toguri, M. Dahele, A. Warner, P.F. de Haan, G.B. Rodrigues, et al., Radical treatment of synchronous oligometastatic non-small cell lung carcinoma (NSCLC): patient outcomes and prognostic factors, *Lung Cancer* 82 (1) (2013) 95–102.
- [15] M. Tonnies, J. Pfannschmidt, T.T. Bauer, J. Kollmeier, S. Tonnies, D. Kaiser, Metastasectomy for synchronous solitary non-small cell lung cancer metastases, *Ann. Thorac. Surg.* 98 (1) (2014) 249–256.

#### Open Access

This article is published Open Access at [sciedirect.com](http://sciedirect.com). It is distributed under the [IJSCR Supplemental terms and conditions](#), which permits unrestricted non commercial use, distribution, and reproduction in any medium, provided the original authors and source are credited.