

# Atypical Carpal Tunnel Syndrome in a Holt Oram Patient: A Case Report and Literature Review

James Mace<sup>\*</sup>, Srikanth Reddy and Randeep Mohil

Department of Trauma and Orthopaedics, Royal Blackburn Hospital, East Lancashire Hospitals NHS Trust, Haslingden Road, Blackburn, Lancashire, BB2 3HH, UK

**Abstract:** We present a case report of a patient diagnosed with Holt-Oram syndrome (HOS) presenting with clinical and electrophysiologically confirmed carpal tunnel syndrome. Pre-operative Magnetic resonance imaging revealed an abnormal course of the median nerve; as such an atypical incision and approach were carried out to decompress the nerve to excellent post operative clinical effect. To our knowledge this is the first description of abnormal nervous course in a patient with HOS leading to peripheral entrapment. A literature surrounding the important aspects of HOS to the orthopaedic surgeon is presented concomitantly.

**Keywords:** Carpal tunnel syndrome, congenital hand deformity, holt oram syndrome, median nerve variation, radial deficiency, thumb hypoplasia.

## CASE REPORT

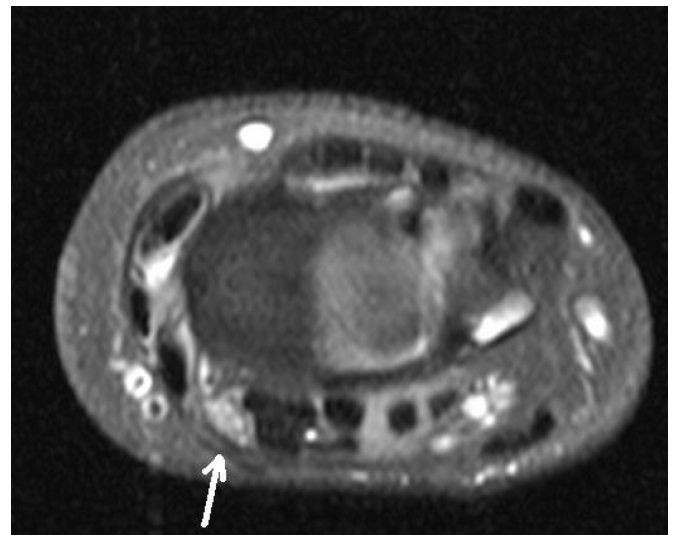
A 27 year old gentleman presented to orthopaedic outpatient clinic with the principal complaint of paraesthesia over the right index finger, worse overnight and causing sleep disturbance. In addition he had noted a recent reduction in grip strength. His past medical history was that of congenital bilateral thumb hypoplasia, for which he had undergone left index finger pollicisation and excision of the rudimentary thumb to his right hand. Both his mother and maternal grandfather had been diagnosed with HOS.

Examination revealed decreased sensation over the index finger and hypoplasia of the thenar eminence. Provocation with Tinnel's test over the carpal tunnel and with a modified Phalen's test were both negative. He was referred for electrophysiologic nerve examination, which revealed marked conduction abnormalities of the median nerve. In light of his abnormal provocative tests and anatomy a magnetic resonance imaging (MRI) scan was requested to delineate the carpal tunnel and median nerve anatomy.

The MRI scan revealed a very radial lying median nerve within the carpal tunnel and scaphoid hypoplasia, it was postulated that the abnormal lie of the median nerve could be in relation to the observed scaphoid hypoplasia (Fig. 1).

The patient underwent carpal tunnel decompression under general anesthesia with a more radial incision. The transverse carpal ligament was released and the nerve explored, where it was found to be located radially within the tunnel and illustrated signs of chronic compression.

At review, 3 months post operatively the patient's symptoms had dramatically improved with a resultant high satisfaction with the outcome of surgery.



**Fig. (1).** Magnetic resonance scan detailing radially located median nerve.

## LITERATURE REVIEW

In 1960, Holt and Oram published their description of family members over 4 generations with 9 affected subjects, describing upper limb abnormalities in conjunction with congenital heart abnormalities [1]. Knowledge and understanding of Holt-Oram syndrome (HOS), or Heart-Hand syndrome, has progressed; its diagnosis should be a consideration in the assessment of all patients presenting with radial longitudinal deficiencies [2].

## INCIDENCE AND PATHOGENESIS

Population studies reveal congenital hand anomalies have an overall incidence of between 19.7 - 21.5 per 10,000. HOS is still uncommon, estimated to affect 1 in 100 000 live births, shows autosomal dominant inheritance (40% sporadic

<sup>\*</sup>Address correspondence to this author at the Department of Trauma and Orthopaedics, Royal Blackburn Hospital, East Lancashire Hospitals NHS Trust, Haslingden Road, Blackburn, Lancashire, BB2 3HH, UK; Tel: 07795 081623; E-mail: [Jamesmace100@gmail.com](mailto:Jamesmace100@gmail.com)

**Table 1. Common causes of radial deficiencies.**

Syndrome	Inheritance	Associated Conditions	Diagnosis
Thrombocytopenia absent radius	Complex Autosomal Recessive [13, 14]	Absent radius with normal thumb Thrombocytopenia and anaemia (improves in first year of life)	Absent radii, thumbs present and platelet count < 50x10 <sup>9</sup> /L
Fanconi's Anaemia	Autosomal Recessive	Pancytopenia between 5-10y of age	Early diagnosis can be made using chromosomal breakage studies (diepoxybutane or mitomycin C)
VACTERL	Sporadic	V → Vertebral A → Anal atresia C → Cardiac anomalies TE → Tracheoesophageal fistula R → Renal agenesis L → Limb anomalies	Clinical Exclusion of overlapping syndromes [15]
Holt-Oram	Autosomal dominant	Cardiac conduction or structural anomalies Generalised upper limb anomalies	Clinical (TBX5 genotyping (Ch12)*)

\*Up to 74% sensitivity reported [9].

new mutation), variable expression and near complete penetrance [3-8]. Strict clinical criteria are required to reduce the, frequently reported, risk of incorrect or missed diagnosis [4, 9]. Basson *et al.* described, and validated, diagnostic phenotypes as the presence of pre axial radial ray malformation of at least one upper limb along with a personal or family history of septation defects and/or atrioventricular disease, these criteria are widely supported [8-11]. There are several syndromes presenting commonly with preaxial radial malformation patterns, they are summarised in Table 1. It is recommended that all patients should undergo coordination with the patient's physician/paediatrician a full blood count, renal ultrasound and echocardiogram once a radial longitudinal deficiency is noted [2, 4, 12].

The underlying genetic driver of HOS has been linked to the TBX5 gene of the Chromosome 12q2 region [3, 8-10, 16]. TBX5 is a part of the T-box gene family which serves to encode a number of transcription factors important during embryonic development; in particular the differentiation of cardiomyocytes where it aids the formation of electrical conduction pathways. Alongside this is the regulation of patterning and morphogenesis within the upper limb [3, 9, 10]. Through noting differing phenotypes in monozygotic twins Huang has suggested the relationship of HOS to this gene site may be complex and subject to other, as yet identified, factors ultimately giving rise to individual phenotypic expression [8].

## PRESENTATION AND TYPICAL FEATURES OF HOS

The classical presentation is that of a triphalngeal thumb with a secundum atrial septal defect (ASD) [17]; however, the syndrome yields wide phenotypic variability, as previously stated unusually even in monozygotic twins [8]. Upper limb abnormalities can involve the entire extremity, are often bilateral but may not be symmetrical [9, 18]. Abnormal shoulder girdle function, phocomelia, hypoplasia

of pectoralis major, clavicular defects, hypoplasia of the humerus, radius, ulnar, metacarpals, syndactyly, carpal anomalies and digital malformations ranging from dysplasia to absence have all been described in the literature [3, 19-23]. The thumb remains the most commonly affected digit, in their 70 year analysis of 77 patients with thumb hypoplasia James *et al.* found an incidence of HOS in this population of 16% [24]. A series of 55 HOS patients reported by Newbury-Ecob *et al.* yielded salient clinical observations, they described an 84% rate of thumb abnormality, found ulnar sided defects only in the presence of concomitant radial pathology, stated proximal reduction defects occurred only when associated with distal, with the exception of the shoulder girdle, in which abnormalities were common (77%) [18]. The characteristic shoulder pattern observed is that of narrow sloping shoulders, caused by hypoplasia of the humeral head, clavicle and surrounding musculature [18, 25].

Cardiac abnormalities range from the most common ASD, to include conduction defects and the Teratology of Fallot [8, 18, 26, 27]; often there is no correlation in the severity of cardiac and upper limb abnormalities [26]. Bruneau *et al.* categorised the cardiac defects in a series of 240 patients; they found 58% of patients had an atrial septal defect, 28% a ventricular septal defect and conduction defects in 18% [16], less common pathologies (including tetralogy of Fallot, truncus arteriosus, mitral valve defects and patent ductus arteriosus) were also present. These often complex cardiac manifestations may require cardiac catheterisation to fully define and subsequent multi-disciplinary management prior to considering administration of anaesthesia and subsequent operative intervention [4, 8].

## NON SKELETAL AND CARDIAC CONSIDERATIONS

With the majority of literature reporting skeletal upper limb anomalies one must not assume all the soft tissues are normal; muscular deficiencies, nerve anomalies (hypertrophic median nerve) and vascular anomalies have all

been associated with radial longitudinal deficiencies [2]. Frota Filho *et al.* [28] reported a case of HOS with absent radial and ulnar pulses, but good hand perfusion. In reporting the outcomes of 74 patients undergoing index finger pollicization Lochner *et al.* reported a higher occurrence of physeal arrest in HOS (46%) compared to the entire group (25%); they speculated the vascularity of these digits were at greater risk due to potential aberrant size or location of digital vessels [29]. Shono *et al.* noted hypoplastic vasculature during femoral venous cannulation and recommended this be performed under ultrasound guidance [21]. These feelings were reinforced by Sing *et al.* who also cautioned of the reliability of non invasive blood pressure monitoring in the face of abnormal vasculature [30].

There has been only one case report we have found in the literature describing carpal tunnel syndrome in association of HOS, occurring as a result of an aberrant FDS muscle belly found within the carpal tunnel at decompression [31]. Thenar hypoplasia has been noted to occur in HOS in the absence of clinical median nerve dysfunction [18, 25]. Spranger *et al.* [25] investigated upper limb muscle morphology in 13 patients with HOS using MRI and conducted electrophysiological testing on 4. All patients had normal serum muscle enzyme levels. Whilst clinically observed pattern of muscle weakness varied, paresis of thumb opposition and abduction was universal. MRI scanning revealed isolated hypoplasia, but normal structural pattern in muscles correlating with clinical weakness. In addition normal electrophysiological testing results were reported in the muscles observed to be weak, supporting their clinical use for detecting peripheral compression in the setting of abnormal anatomy and function.

## DISCUSSION

Holt Oram syndrome remains rare; the anatomical variations encountered in this population should alert the treating clinicians to be mindful of the often abnormal anatomy. In our case preoperative MRI scanning proved invaluable at demonstrating atypical anatomy of the median nerve and allowed for alteration of usual surgical incisions, approach and prompted the use of general anaesthesia to facilitate prolonged exposure of the median nerve had it become necessary. MRI has been used to define the normal anatomy and variation of the median nerve in 194 patients by Pierre-Jerome *et al.*, they did not report the variation we present [32]. Lindley and Kleinert presented their findings of median nerve anatomy from 526 elective carpal tunnel decompressions, and again did not report a course of the median nerve similar to that observed in our case [33]. Thus we would recommend any patient with Holt Oram syndrome presenting with symptoms of upper limb peripheral nerve entrapment undergo electrophysiological evaluation to clearly define the location of nerve dysfunction, followed by MRI evaluation of the area to define the anatomy prior to surgical intervention. Should general anaesthesia be employed there are extra considerations and demands of the anaesthetic.

## CONFLICT OF INTEREST

The authors confirm that this article content has no conflict of interest.

## ACKNOWLEDGEMENTS

Declared none.

## REFERENCES

- [1] Holt M, Oram S. Familial heart disease with skeletal malformations. *Br Heart J* 1960; 22(2): 236-42.
- [2] Maschke SD, Seitz W, Lawton J. Radial longitudinal deficiency. *J Am Acad Orthop Surg* 2007; 15(1): 41-52.
- [3] Lichiardopol C, Militaru C, Popescu B, Hila G, Mixich F. Holt-Oram syndrome. *Rom J Morphol Embryol* 2007; 48(1): 67-70.
- [4] Goldfarb CA, Wall L, Manske PR. Radial longitudinal deficiency: the incidence of associated medical and musculoskeletal conditions. *J Hand Surg Am* 2006; 31(7): 1176-82.
- [5] Goldfarb CA. Congenital hand anomalies: A review of the literature, 2009-2012. *J Hand Surg Am* 2013; 38A(9): 1854-9.
- [6] Ekblom AG, Laurell T, Arner M. Epidemiology of Congenital Upper Limb Anomalies in 562 Children Born in 1997-2002: A Total Population Study from Stockholm, Sweden. *J Hand Surg Am* 2010; 35A(11): 1742-54.
- [7] Giele H, Giele C, Bower C, Allison M. The incidence and epidemiology of congenital upper limb anomalies: a total population study. *J Hand Surg Am* 2001; 26A(4): 628-34.
- [8] Huang T. Current advances in Holt-Oram syndrome. *Curr Opin Pediatr* 2002; 14(6): 691-5.
- [9] McDermott DA, Bressan MC, He J, *et al.* TBX5 genetic testing validates strict clinical criteria for Holt-Oram syndrome. *Pediatr Res* 2005; 58(5): 981-6.
- [10] Basson CT, Huang T, Lin RC, *et al.* Different TBX5 interactions in heart and limb defined by Holt-Oram syndrome mutations. *Proc Natl Acad Sci USA* 1999; 96(6): 2919-24.
- [11] Basson CT, Cowley GS, Solomon SD, *et al.* The clinical and genetic spectrum of the Holt-Oram syndrome (heart-hand syndrome). *N Engl J Med* 1994; 330(13): 885-91.
- [12] Kozin SH. Upper Extremity Congenital anomalies. *J Bone Joint Surg Am* 2003; 85-A(8): 1564-76.
- [13] Albers CA, Paul DS, Schulze H, *et al.* Compound inheritance of a low-frequency regulatory SNP and a rare null mutation in exon-junction complex subunit RBM8A causes TAR syndrome. *Nat Genet* 2012; 44(4): 435-9, S1-2.
- [14] Klopocki E, Schulze H, Strauss G, *et al.* Complex inheritance pattern resembling autosomal recessive inheritance involving a microdeletion in thrombocytopenia-absent radius syndrome. *Am J Hum Genet* 2007; 80(2): 232-40.
- [15] Solomon BD. VACTERL/VATER Association. *Orphanet J Rare Dis* 2011; (6): 56.
- [16] Bruneau BG, Logan M, Davis N, *et al.* Chamber-specific cardiac expression of Tbx5 and heart defects in Holt-Oram syndrome. *Dev Biol* 1999; 211(1): 100-8.
- [17] Hurst JA, Hall CM, Baraitser M. The Holt-Oram syndrome. *J Med Genet* 1991; 28(6): 406-10.
- [18] Newbury-Ecob RA, Leauge R, Raeburn JA, Young ID. Holt-Oram syndrome: a clinical genetic study. *J Med Genet* 1996; 33(4): 300-7.
- [19] Saura D, Campos JV, Villegas M, Pico F, de la Morena G, Valdes-Chavarri M. Heart-hand syndrome. *Int J Cardiol* 2008; 129(1): e7-9.
- [20] Nourzad G, Baghersiroodi M. A case report on holt-oram syndrome (heart-hand). *ARYA Atheroscler* 2012; 7(2): 87-92.
- [21] Shono S, Higa K, Kumano K, Dan K. Holt-Oram syndrome. *Br J Anaesth* 1998; 80(6): 856-7.
- [22] Brockhoff CJ, Kober H, Tsilimingas N, Dapper F, Munzel T, Meinertz T. Holt-Oram syndrome. *Circulation* 1999; 99(10): 1395-6.

- [23] Bohm M. Holt-Oram syndrome. *Circulation* 1998; 98(23): 2636-7.
- [24] James MA, McCarroll HR, Jr., Manske PR. Characteristics of patients with hypoplastic thumbs. *J Hand Surg Am* 1996; 21(1): 104-13.
- [25] Spranger S, Ulmer H, Troger J, *et al.* Muscular involvement in the Holt-Oram syndrome. *J Med Genet* 1997; 34(12): 978-81.
- [26] Cross SJ, Ching YH, Li QY, *et al.* The mutation spectrum in Holt-Oram syndrome. *J Med Genet* 2000; 37(10): 785-7.
- [27] Kumar V, Agrawal V, Jain D, Shankar O. Tetralogy of Fallot with Holt-Oram Syndrome. *Indian Heart J* 2012; 64(1): 95-8.
- [28] Frota Filho JD, Pereira W, Leiria TL, *et al.* Holt-Oram syndrome revisited. Two patients in the same family. *Arq Bras Cardiol* 1999; 73(5): 429-34.
- [29] Lochner HV, Oishi S, Ezaki M, Malungpaishrope K, Moore RB. The fate of the index metacarpophalangeal joint following pollicization. *J Hand Surg Am* 2012; 37(8): 1672-6.
- [30] Singh A, Pathania VS, Girotra S, Iyer KS. Anesthetic implications in Holt-Oram Syndrome. *Ann Card Anaesth* 2013; 16(2): 157-8.
- [31] Robati S, Tayton E, Hashem T. Carpal tunnel syndrome in a Holt-Oram patient. *J Hand Surg Eur Vol* 2009; 34(6): 805-6.
- [32] Pierre-Jerome C, Smitson RD, Jr., Shah RK, Moncayo V, Abdelnoor M, Terk MR. MRI of the median nerve and median artery in the carpal tunnel: prevalence of their anatomical variations and clinical significance. *Surg Radiol Anat* 2009; 32(3): 315-22.
- [33] Lindley SG, Kleinert JM. Prevalence of anatomic variations encountered in elective carpal tunnel release. *J Hand Surg Am* 2003; 28(5): 849-55.

---

Received: August 28, 2014

Revised: November 16, 2014

Accepted: November 23, 2014

© Mace *et al.*; Licensee Bentham Open.

This is an open access article licensed under the terms of the Creative Commons Attribution Non-Commercial License (<http://creativecommons.org/licenses/by-nc/3.0/>) which permits unrestricted, non-commercial use, distribution and reproduction in any medium, provided the work is properly cited.