



Innervated breast reconstruction: a narrative review of neurotization techniques and outcomes

Joseph M. Escandón¹, Jessica Mroueh², Christopher M. Reid³, Devinder Singh⁴, Keith Sweitzer¹, Pedro Ciudad⁵, Rahim Nazerali⁶, Antonio J. Forte⁷, Oscar J. Manrique¹

¹Division of Plastic and Reconstructive Surgery, Strong Memorial Hospital, University of Rochester Medical Center, Rochester, NY, USA; ²American University of Beirut Faculty of Medicine, Beirut, Lebanon; ³Division of Plastic Surgery, Department of Surgery, University of California San Diego, San Diego, CA, USA; ⁴Division of Plastic and Reconstructive Surgery, University of Miami, Miami, FL, USA; ⁵Department of Plastic and Reconstructive, Arzobispo Loayza National Hospital, Lima, Peru; ⁶Division of Plastic and Reconstructive Surgery, Stanford University School of Medicine, Stanford, CA, USA; ⁷Division of Plastic Surgery, Mayo Clinic, Jacksonville, FL, USA

Contributions: (I) Conception and design: JM Escandón; (II) Administrative support: JM Escandón; (III) Provision of study materials or patients: J Mroueh, JM Escandón; (IV) Collection and assembly of data: J Mroueh, JM Escandón; (V) Data analysis and interpretation: J Mroueh, JM Escandón; (VI) Manuscript writing: All authors; (VII) Final approval of manuscript: All authors.

Correspondence to: Oscar J. Manrique, MD, FACS. Division of Plastic and Reconstructive Surgery, Strong Memorial Hospital, University of Rochester Medical Center, 601 Elmwood Ave, Rochester, NY 14642, USA. Email: oscarj.manrique@gmail.com.

Background and Objective: While significant sensation recovery improvements in neurotized breasts following reconstruction have been reported, sensation testing methods and surgical techniques have been widely variable. This narrative review aims to summarize available literature on current neurotization practices and sensory recovery outcomes in patients undergoing innervated breast reconstruction.

Methods: A comprehensive literature search of PubMed Medline, Web of Science, and Embase was conducted to identify all studies reporting outcomes of neurotization in breast reconstruction surgeries. Data analyzed included operative times, neurotization techniques, sensory outcomes, and methods as well as patient reported outcomes.

Key Content and Findings: Despite the heterogeneity of various studies reviewed, all forms of neurotization achieved earlier and superior sensory recovery throughout the reconstructed breast skin compared to non-innervated breasts. In absence of randomized controlled trials or high-quality comparative studies, further evidence is required to objectively confirm this technique offers better sensory recovery.

Conclusions: Neurotization at the time of breast reconstruction may lead to improved sensation and patient reported outcomes delineating improved quality of life compared to non-innervated breasts. Future studies need to standardize the way that breast sensation is measured and determine pre-operative variables leading to expected changes in final sensation recovery to help manage surgical outcome expectations of both the surgeon and the patient.

Keywords: Female; treatment outcome; breast; nerve regeneration

Submitted Feb 02, 2023. Accepted for publication Jun 09, 2023. Published online Jun 27, 2023.

doi: 10.21037/atm-23-504

View this article at: <https://dx.doi.org/10.21037/atm-23-504>

Introduction

Advancements in microsurgery have led to marked improvements in the techniques and outcomes of peripheral nerve repair (1,2). The evolution of peripheral nerve surgery has led to the expansion of different types and

configurations of nerve repair that can be performed. Apart from the common primary end-to-end neurotization, newer techniques include end-to-side neurotization and the use of nerve grafts, nerve conduits, and nerve transfer in cases where a nerve gap is present (3,4). The global

understanding and research on the functional outcomes of nerve repair have paved the way for the evaluation of its applicability in various cases or fields of surgery such as breast reconstruction (5).

Breast cancer is one of the most common cancers diagnosed in women worldwide (6,7). Approximately, 264,121 women in the US were diagnosed with breast cancer in 2019 (8). As advancements in breast surgical oncology continue to improve, yielding a 5-year survival rate of 90% or more, most efforts have been directed toward reducing morbidity associated with breast cancer reconstruction. New technologies and innovations have been developed to improve reconstructive techniques to enhance functional and aesthetic outcomes, both of which play a substantial role in patients' quality of life and psychological well-being (6,9-12). One major cause of patient dissatisfaction has been the significant decrease in sensation after mastectomy. Although well documented, spontaneous return of sensation following non-innervated autologous breast reconstruction remains variable and uncertain (13,14). As such, nerve repair at the time of a breast reconstruction surgery has gained significant importance and has become a subject of debate requiring investigation (12,15-17).

Most reconstructive surgeons do not prioritize breast reinnervation due to the time-consuming and unpredictable nature of neurotization (18). Additionally, as some sensation can be regained through nerve regeneration from adjacent post-mastectomy skin, surgeons may feel that the added time and complexity of neurotization is not worth it (18). The traditional nerve used for breast flap neurotization—the lateral cutaneous branch of the fourth intercostal nerve—is often damaged during mastectomy and located in a separate microsurgical field, further complicating the procedure (18,19). Because there is usually no undamaged recipient nerve readily available, routine innervation is limited (18). On this matter, the implementation of the anterior cutaneous branch of the third intercostal nerve as a recipient nerve for coaptation, advancements in microsurgery and supermicrosurgery, and the use of nerve allografts and conduits, have improved outcomes in innervated breast reconstruction (2,18,20). Therefore, this review aimed to summarize the available literature on current neurotization practices and sensory recovery outcomes in patients undergoing innervated breast reconstruction. We present this article in accordance with the Narrative Review reporting checklist (available at <https://atm.amegroups.com/article/view/10.21037/atm-23-504/rc>).

Methods

We performed a narrative review with a systematic search to identify current literature on surgical outcomes of neurotization following innervated breast reconstruction (Table 1). Source references were identified through PubMed Medline, Web of Science (*Clarivate Analytics*), and Embase (*Elsevier*) to identify English-written abstracts and articles published between database inception and April 2023. The following terms were used in different combinations: “Deep inferior epigastric perforator”, “DIEP/DIEAP”, “Latissimus dorsi”, “Implant”, “Expander”, “Flap”, “Microsurgery”, “Breast”, “Mammoplasty”, “Reconstruction”, “Reinnervation”, “Neurotization”, “Neurotization”, “Neurotization”, “Neurotization”, “Neurotization”, “Anastomosis”, “Sensation”, “Axogen”, “Neuromatrix”, “Avance”, “Neuromed”, and “Neuroflex”.

Results

Innervation of the female breast and nipple

The breast skin receives bilateral innervation from lateral cutaneous branches and anterior cutaneous branches of multiple intercostal nerves (21). Several studies have shown that the sensory input to the breast skin mainly comes from the lateral cutaneous branches of the second, third, and sixth intercostal nerves, as well as the anterior cutaneous branches of the second through sixth intercostal nerves (Figure 1) (21-27). One of the most constant findings of studies evaluating the anatomy of breast is that the lateral cutaneous branches of the fourth and fifth intercostal nerves contribute to breast skin innervation (21-27). On the other hand, the anterior cutaneous branches and lateral cutaneous branches of the first and seventh intercostal nerves are often not traced to their final destination in the breast skin (21-26). There have been studies indicating that the cutaneous branches of the supraclavicular nerves play a role in providing sensation to the upper part of the breast, but none of these studies have provided specific information about the extent of their involvement (21,24,26,27). Regarding the fourth intercostal nerve, the anterior and lateral cutaneous branches on average supply the largest surface area of the breast skin (17.5% and 19.2%, respectively) (21,25). Currently, no conclusive data exist indicating whether the anterior cutaneous branches or the lateral cutaneous branches contribute more to the cutaneous innervation of the breast (21,25,26).

Similar to the breast skin, the nipple and nipple-areola complex are innervated by the anterior cutaneous branches and lateral cutaneous branches of multiple intercostal

Table 1 The search strategy summary

Items	Specification
Date of search	April 25th, 2023
Databases and other sources searched	PubMed Medline, Web of Science (<i>Clarivate Analytics</i>), Embase (<i>Elsevier</i>)
Search terms used	“Deep inferior epigastric perforator”, “DIEP/DIEAP”, “Latissimus dorsi”, “Implant”, “Expander”, “Flap”, “Microsurgery”, “Breast”, “Mammoplasty”, “Reconstruction”, “Reinnervation”, “Neurotization” “Neurorraphy”, “Anastomosis”, “Sensation”, “Axogen”, “Neuromatrix”, “Avance”, “Neuromed”, and “Neuroflex”
Timeframe	Database inception through April 2023
Inclusion criteria	English-written abstracts and articles
Selection process	Two reviewers simultaneously searched for research articles using 3 databases
Any additional considerations, if applicable	The reference lists of included studies were also reviewed to search for additional potential research studies

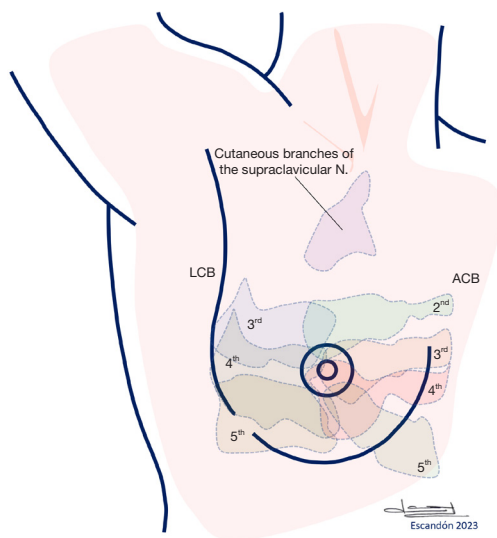


Figure 1 Dispersion of the course of nerve branches innervating the breast and NAC in the frontal plane according to Tuinder *et al.* (21). LCB, lateral cutaneous branches; ACB, anterior cutaneous branches; NAC, nipple-areola complex.

nerve (21). On a previous meta-analytic model, the authors determined that the lateral cutaneous branch of the fourth intercostal nerve was the most prevalent source of innervation for the NAC (pooled rate 89%; 95% CI, 80–94%) (21,25, 27-32). Studies evaluating the role of the anterior cutaneous branches of the second to fifth intercostal nerves and lateral cutaneous branches of the third and fifth intercostal nerves in breast innervation have shown significant variability in their findings (21). According to Jaspars *et al.*, the anterior

cutaneous branch and lateral cutaneous branch of the fourth intercostal nerve innervate the largest surface area of the nipple and nipple-areola complex on average (35.5% and 29.8%, respectively) (21,25).

Different trajectories have been reported regarding the course of intercostal nerves innervating the NAC. Some reports have described the nerve trajectory as mainly superficial via the subcutaneous tissue, predominantly involving the anterior cutaneous branches (21,25,26,29). Other studies have described a predominant deep subcutaneous course followed by a sharp (sometimes 90°) change of direction toward the surface of the breast (21,26,28,29,33). An “S-shaped” (logistic growth curve) course starting with an originally deep subcutaneous trajectory followed by a steady change of direction toward the breast surface has also been described in multiple studies (21,24,25,32,34). Finally, a bifid course where nerves are divided into two branches has also been reported, one of them traveling deep course through the gland and another traveling superficially through the subcutis (21-23,27). This type of nerve course is characteristic of anterior cutaneous branches and lateral cutaneous branches of the fourth and fifth intercostal nerves.

Sensory testing methods

To evaluate sensory recovery, sensory testing usually includes a (I) sensory modality or device, (II) the skin areas being tested, and (III) the way calculations are done. Unfortunately, testing for sensory recovery after neurotization during breast reconstruction has been inconsistent in the literature. Tactile pressure seems to be the only modality widely and

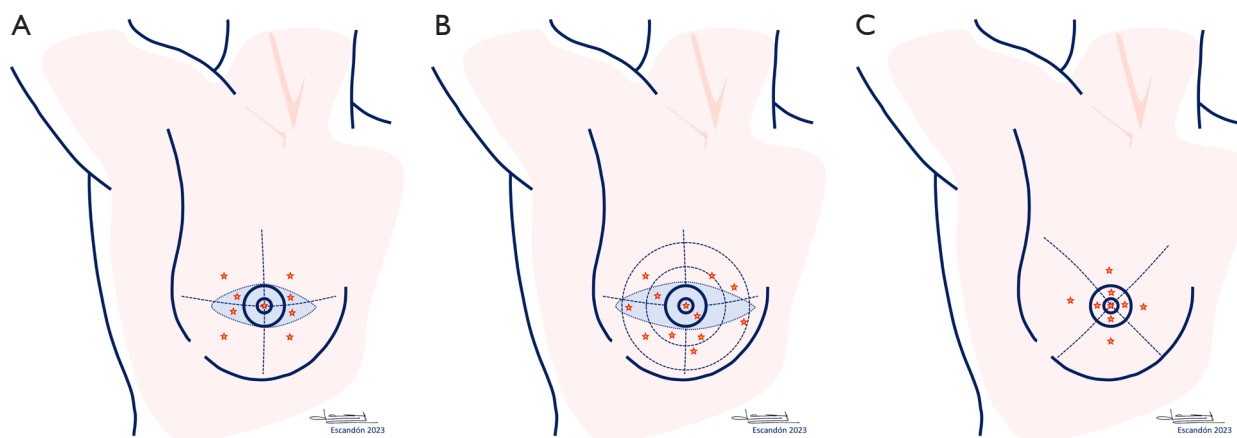


Figure 2 Different methods to assess sensation in the breast (blue shadow: flap's skin paddle). (A) Assessment of sensation according to Magarakis *et al.* (47); (B) assessment of sensation according to Yap *et al.* (49); (C) assessment of sensation according to Mori & Okazaki (40).

homogeneously employed, almost reaching a consensus. Although traditional physical examination such as finger touch can be used for that purpose, as Doncatto *et al.* (35) and Peled *et al.* (36) indicated, many more studies have used the Semmes-Weinstein monofilaments (SWS) to test for pressure sensation. For instance, Isenberg *et al.* (37,38), Yano *et al.* (39), Mori *et al.* (40), Cornelissen *et al.* (41), Beugels *et al.* (16,42), Bijkerk *et al.* (43), and Puonti *et al.* (44,45) all used SWS to test for tactile pressure sensation. Another study also added an enhanced version of the SWS, the WEST device (46). A third way to test for pressure, although less common, is using the pressure-specified sensory device (PSSD). Magarakis *et al.* (47), Spiegel *et al.* (18), and Djohan *et al.* all tested for pressure using this device (48).

The other but less common modality to test for sensory recovery can be temperature discrimination. Several studies by Yano *et al.* (39), Isenberg *et al.* (37,38), Yap *et al.* (49), Mori *et al.* (40), and Puonti *et al.* (44,45,50) used a thermoesthesiometer or probe with different temperatures, while two other studies used hot/cold water-filled test tubes (12,35). Another tactile sensation modality is two-point discrimination, which is usually tested using a DiskCriminator. Several studies have used this modality as one way to examine sensation recovery (36-38,44-46,50,51). Many other sensation tests like vibration, pain, and sharp or blunt sensation can also be used; however, their implementation has been highly heterogeneous and not systematic (35,40,44,45,50).

To assess for sensory recovery, the breast skin (native breast skin, flap skin, or the opposite untouched breast skin) is mainly divided into four quadrants and a central

area (i.e., the nipple-areola complex) (Figure 2). Magarakis *et al.* (47) and Beugels *et al.* (16) examined the LUQ, LLQ, RUQ, RLQ, and the central areas of the flaps' skin (tissue transfer) and the same four quadrants on the native breast skin. An additive to this design is to examine the quadrants on two or three different radii outward from the center, as Yap *et al.* (49), Cornelissen *et al.* (41) and Bijkerk *et al.* (43) described in their series. Another similar design previously described would incorporate the division of the breast into the nipple, areola, superior, inferior, lateral, and medial areas (40,48).

As such, there is no consensus amongst studies in terms of the number and the designed locations of the skin areas to be tested for sensory function, as well as examining the flap's skin only or the native breast skin too. The number of areas tested also changes in some studies depending on the sensory testing modality. For example, Puonti *et al.* tested for pressure, sharp or blunt sensation, and vibration sensation in five different areas, while they tested for 2-point discrimination in only two areas (50).

In addition, methods used to calculate the results of the sensory tests are very much inconsistent across the studies that were evaluated. Cornelissen *et al.* tested each area three times and calculated the mean (41), Magarakis *et al.* tested five times every area and calculated the mean of the middle three values (47), Beugels *et al.* (42) and Bijkerk *et al.* (43) tested three times per area and chose the lowest value, while Djohan *et al.* and Spiegel *et al.* recorded a threshold (18,48). Furthermore, there are inconsistent definitions to which the patient was blinded to the intervention. On this matter, an ideal test requires the patient to be unable to see the area being tested.

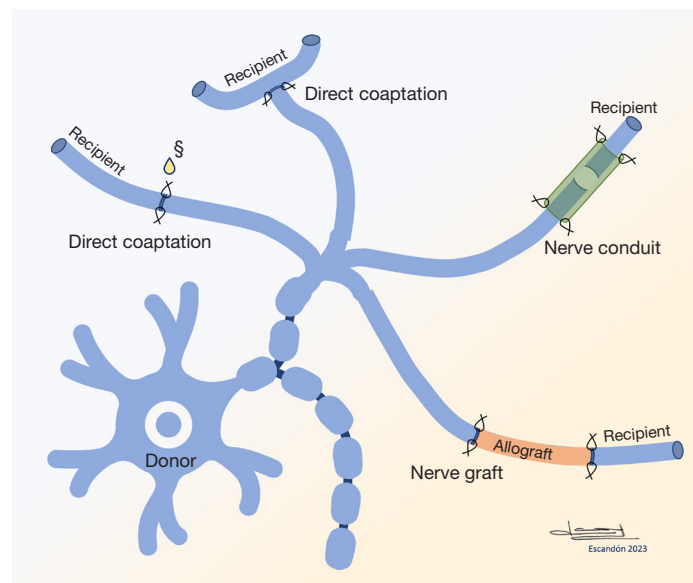


Figure 3 Methods of neurotization utilized in innervated breast reconstruction. §, tissue glue or fibrin sealant.

Techniques for neurotization

Several types of nerve repair are utilized during innervated breast reconstruction. These include direct end-to-end repair, end-to-side repair, nerve conduits, and nerve grafts (Figure 3) (52). Typically, nerve coaptations are carried out with two to four epineural or perineural sutures using 8-0 to 10-0 nylon sutures. In two studies by Temple *et al.* (12,46), the authors reported using 9-0 nylon sutures for two to three epineural sutures, while two other studies by Puonti *et al.* mentioned the use of perineural sutures (44,45). Puonti *et al.* also used three to four sutures in some cases (45).

Some authors have also described that tissue glue or fibrin sealant can be applied to the repair. For instance, Beugels *et al.* and Bijkerk *et al.* used 9-0 nylon sutures as well but added a drop of tissue glue and fibrin sealant, respectively (16,43). Cornelissen *et al.* used 10-0 nylon sutures and added tissue glue (41). Despite being a sophisticated and resourceful technique, the effect of tissue glue or fibrin sealant on better outcomes for innervated breast reconstruction requires further examination.

Direct end-to-end or end-to-side coaptation

Innervated breast reconstruction using direct coaptation appears to improve the likelihood of obtaining higher-quality sensory recovery. Many studies have reported higher sensitivity, or decreased sensory threshold for

pressure, vibration, temperature discrimination, and pain in innervated breasts with direct coaptation for neurotization than non-innervated breast reconstruction. Also, innervated breasts may sustain not only an earlier but also a more widespread sensory recovery throughout the flap. In several studies evaluating the role of innervated autologous breast reconstruction, Temple *et al.* (46) [transverse rectus abdominis myocutaneous (TRAM)], Puonti *et al.* (50) (TRAM), Yano *et al.* (39,53) [latissimus dorsi flap (LDF)], Bijkerk *et al.* (43) [lateral thigh perforator flap (LTP) & DIEP], and Yap *et al.* (49) (TRAM) reported that sensory recovery in non-innervated breasts started at the periphery and was the poorest centrally, while in the innervated breasts, return of sensation began in the center and expanded throughout the whole flap. On this matter, further studies are required to assess sensory recovery in flaps that are de-epithelialized compared to flaps that are partially de-epithelialized or are not de-epithelialized at all.

The most commonly utilized technique for direct coaptation is a direct end-to-end repair. In a prospective study by Beugels *et al.*, forty-eight innervated deep inferior epigastric perforator (DIEP) flaps were performed in 36 patients using the end-to-end neurotization method and were compared to patients who underwent non-innervated DIEP flap breast reconstruction (16). Nerve coaptation was significantly associated with lower monofilament values in all areas of the reconstructed breasts ($P < 0.001$), indicating that sensory recovery was significantly worst

in non-innervated DIEP flaps compared with innervated DIEP flaps (16). The authors also demonstrated that for each additional month of follow-up, the mean monofilament value of the total skin decreased by 0.012 in non-innervated flaps and 0.083 in innervated flaps ($P < 0.001$), demonstrating faster sensory recovery in innervated reconstructed breasts (16).

Bijkerk *et al.* carried out a retrospective study on 15 patients who underwent bilateral autologous breast reconstruction using DIEP or lateral thigh perforator (LTP) flaps with unilateral end-to-end sensory nerve coaptation (43). Sensory measurements 12 months after breast reconstruction demonstrated that sensation in the innervated breasts reached near normal levels in almost half of the breast (44.4%; four of five areas), in both the native skin and the flap skin, while sensation was significantly impaired after non-innervated breast reconstruction in most areas (88.9%) (43).

Several studies have also used the DIEP flap for autologous breast reconstruction and neurotization with direct coaptation obtaining favorable results. For instance, Blondeel *et al.* had 24 breasts in 23 patients reconstructed with DIEP flaps with an end-to-end nerve repair (54). Pilot studies by Magarakis *et al.* and Cornelissen *et al.* evaluated 5 DIEP flaps and 18 patients who had DIEP flaps, respectively, both using a direct end-to-end nerve repair (41,47).

Delayed-immediate autologous breast reconstruction is a common practice when DIEP flaps are used (55,56). However, some surgeons interested in innervated breast reconstruction may opt for immediate DIEP flap transfer to avoid worse outcomes regarding sensory recovery. On this matter, recent reports have demonstrated that sensory recovery is comparable with autologous reconstruction and neurotization using either an immediate or delayed-immediate approach (57). Otterburn *et al.* evaluated the postoperative outcomes of 46 delayed-immediate breast reconstructions and 120 immediate reconstructions with DIEP flaps (57). Reconstructions in the delayed-immediate group underwent the final-stage neurotized flap reconstruction 12 months after initial tissue expander placement, on average (57). At an 18-month follow-up after mastectomy (6 months after DIEP), delayed-immediate reconstructions had comparable sensory outcomes as immediate DIEP flap reconstructions in all regions of the breast ($P > 0.05$) (57). Twenty-four months after surgery, cutaneous thresholds of delayed-immediate procedures were comparable to baseline (preoperative) sensory measures in all regions of the breast ($P > 0.05$), except the inner inferior region. This sensory recovery pattern was similar to the one

of immediate DIEP flap reconstructions (57).

Other studies have evaluated the role of the TRAM flap for innervated breast reconstruction. For instance, Mori *et al.* (40) and seven other research groups presented the outcomes of TRAM flap breast reconstruction with end-to-end nerve coaptation for neurotization (12,37,38,46,49,51,53). Initial reports indicated that the innervated TRAM flaps provided better quality of life (12), temperature differentiation ($P = 0.02$), and sensitivity to fine touch in the flap skin ($P = 0.003$) and in the non-flap skin (mastectomy flap; $P = 0.037$) compared with non-innervated TRAM flaps ($P < 0.001$) (49). It must be highlighted, that the type of mastectomy and the amount of mastectomy flaps left *in situ* can significantly affect the postoperative outcomes of innervated TRAM flap for breast reconstruction (40). For instance, while Mori *et al.* reported that non-innervated flaps showed worst recovery of touch and pain sensations than innervated flaps when a conventional mastectomy was performed, comparisons between the non-innervated and innervated groups showed no significant difference when nipple-sparing or skin-sparing mastectomies were used (40).

Several other flaps have been used for innervated autologous breast reconstruction. Blondeel *et al.* gathered data on free S-GAP (superior gluteal artery perforator) flaps used on 20 breast reconstructions where end-to-end nerve repair was utilized in two reconstructions and provided an early sensory recovery (58). Beugels *et al.* conducted a prospective study on patients undergoing non-innervated versus innervated LTP flap breast reconstruction along with direct nerve repair (42). Other authors have evaluated the latissimus dorsi (LD) myocutaneous flap for breast reconstruction accompanied by end-to-end neurotization, demonstrating that regional flaps are also a valuable alternative for neurotization (39). Using the lateral cutaneous branch of the dorsal primary division of the 7th thoracic nerve as a donor nerve for innervated LD flaps, Yano *et al.* obtained a faster recovery and near baseline sensory perception compared to reconstructions that did not undergo innervated breast reconstruction, where sensory recovery was poor (39).

Regarding the length of peripheral nerves for coaptation, to create a tensionless repair in any of the sensate breast reconstruction types, efforts are made to dissect and transect nerves at a maximal length with the least damage to the donor or recipient sites. Yano *et al.* reported transecting a donor nerve of greater than ten centimeters in one study and a minimum of seven centimeters in another (39,53), and a recipient nerve length of six to seven centimeters in both

(39,53). Other surgeons were more conservative and used shorter nerves. In two studies by Blondeel *et al.*, the authors described that the harvested donor nerve length ranged between three and nine centimeters (54,58). An additional primary aim of an appropriate nerve length, is to allow for adequate inset of the flap that maintains standard aesthetic goals whilst not compromising pedicle safety.

Objective evidence of an earlier return of sensation in neurotized breasts is manifested at an average of six months following reconstruction. Two studies by Yano *et al.* reported earlier signs of recovery starting at six months after LDF transfer or reconstruction with TRAM flap (39,53). Another study by Blondeel *et al.* showed earlier signs of sensory recovery beginning between five and seven months after the operation (58), while recovery in a study by Yap *et al.* began four to six months after reconstruction with neurotized TRAM flap (49). On the other hand, non-innervated breasts may take at least a year before sensation can start to recover. Yano *et al.* indicated that sensory recovery in non-innervated breasts took more than a year to kick in (39), while their other previous study described a lengthier recovery starting more than 2 years after surgery (53). Furthermore, Yap *et al.* reported that recovery in non-neurotized breasts started 12 to 14 months after surgery (49).

Interestingly, although neurotized breasts reach greater levels of sensory recovery (e.g., protective sensation) compared to non-innervated ones and sensation does get closer to reference values of non-operated breasts, it does not completely achieve baseline values (16,42,43). Additionally, there is no consensus regarding the follow-up of patients to evaluate sensation; therefore, times of sensory evaluation between studies have been inconsistent and may affect the accuracy of some data. On this matter, two studies have shown that the magnitude of sensory recovery positively correlates with the length of follow-up in both the flap and native skin, in innervated and non-innervated breasts (16,43).

On the other hand, the end-to-side neurotization approach is sometimes preferred during innervated autologous breast reconstruction. An end-to-side technique for neurotization has had promising results on sensitive and motor reinnervation in different fields of surgery as it allows using a recipient nerve without denervation of its target structures (35,44,45,50,59,60). Donatto *et al.* (35) and three studies by Puonti *et al.* utilized this technique for the lateral side of flaps that needed dual innervations (44,45,50).

An end-to-side neurotization may offer a safer and more effective profile for sensation recovery as it enables the surgeon to utilize a recipient nerve without jeopardizing its

native function. Doncatto *et al.* used this technique during TRAM flap breast reconstruction and innervation obtaining optimal results in terms of sensation recovery of the flap (35). Of the innervated reconstructions, 46.15% were performed with a single neurotization while the other 53.85% were performed with double neurotization (35). Ninety-two percent of the innervated TRAM flaps had superficial sensation, while only 7.6% of non-innervated TRAM flaps achieved superficial sensation ($P < 0.001$).

Puonti *et al.* also demonstrated that using an end-to-side neurotization for direct nerve coaptation did not affect the sensory function of any available recipient nerve, and yielded adequate sensation to the TRAM flap and the reconstructed breast (50). Interestingly, the authors did not find any difference regarding sensibility of the nipple between the neuro-TRAM group and standard-TRAM group ($P = 0.200$) (50). Furthermore, sensory testing did not show major differences between the type of anastomosis, different nerve repair techniques, and recipient nerves (50).

Direct coaptation with conduit

In some cases, nerve conduits and grafts can be better alternatives to direct coaptation. A nerve gap of a maximum of three centimeters can be solved with the use of a nerve conduit. The conduit helps to align regenerating axons in a natural environment with abundant neurotrophic factors (61). It also supports the coaptation in cases of size mismatch between the donor and recipient nerves, which minimizes scar formation inherent to anastomoses of nerves and acts as a physical guide for axonal regrowth (18). It is important to highlight that the use of nerve conduits is associated with increased healthcare-related costs.

Puonti *et al.* assessed the postoperative sensory outcomes of neuro muscle-sparing TRAM (ms-TRAM) flap breast reconstructions using single or dual neurotization wrapped with a NeuraGen tube compared with non-innervated breast reconstruction (44,45). The authors determined that not only sensory recovery was better in the innervated breasts, but also that a dual innervation resulted in even greater overall sensory outcomes compared to single innervation (44,45). Dually innervated breasts showed around 60% sensation of that of unoperated breasts, while single-innervated reconstructions had an average of 45%. Thus, the authors recommended using nerve conduits and dual neurotization when available, as both improve sensory recovery after breast reconstruction and the latter also widens the total skin area for sensory recovery (44,45).

Spiegel *et al.* performed neurotization on 33 DIEP flaps using 40-mm polyglycolic acid nerve conduits (NeuroTube; Synovis, St. Paul, MN) (18). The authors compared the sensory outcomes of DIEP flap reconstructions using direct coaptation with or without a nerve conduit and found that breasts that underwent neurotization with conduits had lower thresholds for pressure sensation and greater sensory recovery than those that underwent direct coaptation only at an average of 111 weeks postoperative ($P < 0.01$) (18). Furthermore, postoperative sensibility in DIEP flaps neurotized by direct coaptation was significantly worse (higher threshold) than that in the corresponding areas of DIEP flaps neurotized using the nerve conduit ($P < 0.01$) (18).

Regarding the length of peripheral nerves for coaptation, Spiegel *et al.* mentioned that both the donor and recipient nerves were harvested at the longest length possible without further specifications (18). Furthermore the authors made remarks on how the suitable nerves for coaptation were usually located in the inferior half of the flap, and also, on how the sensory components of the intercostal nerves follow the same course as the perforating vessels to innervate the abdominal skin after piercing the rectus abdominus (62,63).

Nerve allograft

Nerve gaps of more than three centimeters may best be dealt with nerve grafts. To prevent excessive donor site morbidity secondary to extensive dissections when attempting to harvest a flap with a greater donor nerve length, nerve grafts are utilized to provide the needed length for coaptation of the donor and recipient nerves with the least amount of tension possible (13). Furthermore, in instances of implant-based reconstruction after total mastectomy, this is the only mechanism to bridge the gap. Nerve grafts can also be used during nipple-sparing mastectomies when nerves cannot be preserved for oncological safety. They minimize the need for extensive dissections and offer promising results regarding to improved sensory recovery post-operatively. They are used as connectors between the donor's fourth intercostal nerve and the nipple-areola complex in most instances. The primary downside of this approach is the significant cost of cadaveric nerve grafts, which represent around 5× the direct consumable cost of a standard autologous reconstruction.

Most studies using this technique have demonstrated better sensation thresholds in graft-based innervated breasts in most of the areas tested (36,48). Peled and Peled performed neurotization and implant-based breast

reconstructions following nipple-sparing mastectomies on 31 breasts (36). They performed the coaptation of the transected fourth or fifth lateral intercostal nerves with the subareolar nerves using six- to seven-centimeter Avance nerve allografts (Axogen, Jacksonville, FL) to obtain a tensionless repair (36). The authors described that all patients reported intact gross and light sensation over the majority of the reconstructed neurotized breasts (36).

Similarly, Djohan *et al.* performed sensate implant-based reconstructions on 15 patients with the use of seven-centimeter-nerve allografts linking the fourth intercostal nerve with the nipple-areola complex (48). Innervated breasts had better thresholds in the majority of areas compared to non-innervated breasts in two patients who underwent bilateral implant-based reconstructions with only a unilateral neurotization (48). They also mentioned that for the patients who were available for another test at a second time-point, both the nerve graft-based reconstructed and the non-innervated breasts had sensory recovery. However, the breasts with the nerve grafts had better sensation improvement (48).

A very recent and unique study by Djohan *et al.* reported on sensory outcomes of neurotization during autologous breast reconstruction using both nerve allograft (Avance Nerve Graft; AxoGen, Inc., Alachua, FL, USA) and conduits (AxoGard Nerve Protector; AxoGen) simultaneously (20). The authors found that the pattern of sensory recovery in the non-neurotized group was irregular. Also, they reported that patients who underwent neurotization had lower dynamic test thresholds when examined for sensory function 12 months after surgery compared to those in the non-neurotized group (20).

Quality-of-life

Many have attempted to evaluate quality-of-life of patients after undergoing breast reconstruction with or without nerve repair besides the objective testing of sensory outcomes. There is still no consensus among studies regarding which validated standardized tool can best assess the influence of innervated breast reconstruction on quality-of-life. Nonetheless, the BREAST-Q has been found suitable to measure patient-reported outcomes after breast reconstruction in most clinical scenarios. For future reports, specific analysis of the data pertaining to the BREAST-Q Sensation Module is required (64,65).

Some studies have used quantitative questionnaires such as score-based surveys or rating scales. Temple *et al.* utilized

three validated questionnaires evaluating quality-of-life mainly concerning breast cancer (12). Cornelissen *et al.* used the BREAST-Q questionnaire and added five other Likert-Scale questions referring to breast skin sensation (41). Magarakis *et al.* also utilized a five-point Likert-Scale questionnaire regarding the perception of breast sensation (47). Three studies by Puonti *et al.* (44,45,50) used 10-point scales; two had questions that pertained to breast sensation, while the latter addressed patient satisfaction. Overall, the majority of the questions inquired about pain, numbness, abnormal sensation, hypersensitivity, breast skin feeling natural, cosmetic outcomes, and patient satisfaction. Other studies have simply used subjective open-ended questions about the patients' experience and overall sensation satisfaction after breast reconstruction (36,37,51,54).

Most of these studies reported the quality-of-life assessments to be better in patients who have undergone sensate breast reconstructions (12,36,37,41,54). On another hand, Puonti *et al.* found that patient satisfaction was good in both the innervated and non-innervated groups (44,50). In a third study by Puonti *et al.*, the authors highlighted that slightly greater patient satisfaction was evident after dual innervation breast reconstruction compared to single innervation breast reconstruction (45).

Surgical time

Neurotization has been shown to have a relatively short additional operative duration. Several studies have reported the dedicated time that was required for neurotization, which ranged from 8 to 38 minutes for a single or dual neurotization. Spiegel *et al.* reported the neural component to last between 8 and 15 minutes (18). Djohan *et al.* had it for 10 minutes (48). In two studies by Beugels *et al.* (16,42) and another one by Cornelissen *et al.* (41) the neural component took 15 minutes. Isenberg *et al.* mentioned a duration of 35 minutes (38), while reporting in another study a range between 22 and 38 minutes (37). A consistent factor not included in the previous reports is the additional time spent dissecting and preparing donor and recipient nerves. As such, the reported times are significant underestimates of actual additive operative time, taken on the whole.

Surgical complications

As with any surgical procedure, neurotization in breast reconstruction can be associated with some complications. One challenge is the anatomical variation of nerves and

vessels between the chest and the flap. In two studies by Puonti *et al.*, a single nerve pedicle was chosen to be used due to the spatial anatomy of nerves in the chest (44,45). Spiegel *et al.* and Cornelissen *et al.* also had technical difficulties due to anatomical and spatial relationships between vessels and nerves (18,41). Other challenges can be the damage and irretrievability of the recipient nerve as mentioned by Blondeel (58), and issues identifying the nerve at the time of mastectomy (48). Sometimes surgeons can face multiple challenges at once, including unfavorable flap orientation along with excessive scarring/post-radiation effect, and insufficient donor/recipient nerve and vessel lengths. Bijkerk *et al.* mentioned all these complications as potential causes of unsuccessful neurotization (43). A primary takeaway from these reports is that neurotization should not take precedence over successful reconstruction or minimizing possible complications.

Recent studies evaluating the postoperative outcomes of neurotization using the American College of Surgeons (ACS) National Surgical Quality Improvement Program (NSQIP) data, demonstrated that innervated breast reconstruction does not increase the 30-day complication rates or 30-day readmission rates. Furthermore, neurotization was not associated with prolonged length of stay (66,67). No studies have reported the incidence of neuromas or any other complications directly associated with neurotization. Therefore, the literature has shown that innervated breast reconstruction has a outstanding safety profile, is a fairly straightforward procedure for a microsurgeon, and does not add significant donor or recipient site morbidity (17,63,66).

Limitations

Neurotization during breast reconstruction appears to have a satisfactory success rate. Most studies that implemented neurotization in breast reconstruction mentioned that the rate of neurotization was highly successful, ranging between 85% and 100% (16,18,41-45,48,52). However, there are significant limitations to the reported studies. Studies presenting outcomes of breast neurotization with randomized trials are lacking and most reports are comparative or single-cohort retrospective studies (68). Most studies have a limited sample size, and cohorts are not comparable for certain baseline parameters.

There is limited evidence (biopsy) that indicates grafts are not affected by ischemia and that blocked axonal regeneration does not occur, especially when acellular

dermal matrix products are used (69). Due to the inherent variability in surgical technique between surgical oncologists and plastic surgeons, and inconsistency in follow-up, it is unclear if the sensation recorded at the first clinic visit was in part due to preserved sensation (69). Selective reporting of outcomes and the economic support from companies providing funds may affect the results presented in several studies. The additional cost of nerve allografts and conduits may restrict the systematic incorporation of nerve allografts and limit the external validity of the outcomes presented in series using this technique. As different tools were used to assess quality-of-life between the available studies and several of these tools are not validated, comparison of patient-reported outcomes between surgical techniques and approaches may be limited.

Conclusions

Sensation recovery following mastectomy and breast reconstruction is essential as it has a protective role against injuries and helps in detecting tissue damage through pain and temperature sensation (20). Some cases of thermal injuries to insensitive autologous reconstructed breasts have previously been described (70,71). Its absence can also have debilitating effects on patients' quality-of-life (41). One of the greatest determinants of women's post-surgical satisfaction is whether their new breasts feel like their own (72). However, achieving this goal is challenging if no sensation is restored despite the aesthetically appealing or pleasing results (41). This is backed up by the several studies included in this review that demonstrated better quality-of-life after innervated versus non-innervated breast reconstructions (12,36,37,41,54).

Spontaneous sensory recovery can be observed after autologous or implant-based breast reconstruction; however, its pattern and timing are typically unpredictable and limited (54,58). In this regard, it is important to take into consideration the timing of sensory evaluation after neurotization and autologous breast reconstruction, as it may be an important factor generating heterogeneity of outcomes among published articles (15). Although this review demonstrated improved outcomes following neurotization compared to non-neurotized breast reconstruction amongst studies, its implementation as the standard of care in breast reconstruction remains inconclusive as many studies had a level of evidence of III and IV.

Due to the limited number of publications discussing

the challenges and complications that surgeons face during neurotization (18,41,43-45,48,54), in addition to a relatively limited number of studies available, there is an urgency for additional prospective comparative studies to be conducted investigating challenges and solutions to neurotization. Despite methods of sensory outcomes testing (including modality, areas tested, and calculations), follow-up times, and quality-of-life assessments being greatly variable in the literature, some impressions can still be outlined.

First, sensory recovery starts earlier and with greater amplitude in neurotized breast reconstructions compared to those without nerve repair. Second, in non-innervated breasts, sensory recovery starts at the periphery and is poorest centrally, while in innervated breasts, the return of sensation begins in the center and expands throughout the whole flap. Interestingly, although neurotized breasts reach greater levels of sensory recovery than non-neurotized ones, sensation gets closer to reference values of non-operated breasts but does not completely achieve baseline reference values. Also, the use of nerve conduits potentially improves sensory restoration further by providing an optimal and natural environment for axonal regeneration, while dual neurotization not only improves the degree of sensory recovery but also the total breast skin areas covered. Ultimately, quality-of-life seems to be better in patients undergoing breast reconstruction with nerve repair compared to those without.

These presumptions, despite being far from definitive conclusions, offer promising outcomes of neurotization. Not only do they guide future studies to confirm the importance of standardizing nerve repair at the time of breast reconstruction, but also highlight the discussion of future directives concerning on how to improve surgical techniques, standardizing methods of sensory testing, follow-up, and assessments of patients' quality-of-life and satisfaction.

Lastly, a recent study by Djohan *et al.* has featured some factors such as high body mass index, diabetes, radiation, and hormonal therapy that could affect outcomes of neurotization by negatively interfering with nerve regeneration (20). Other future studies need to identify such factors as their preoperative identification helps in managing surgical outcome expectations of both the surgeon and the patient.

Acknowledgments

Funding: None.

Footnote

Provenance and Peer Review: This article was commissioned by the editorial office, *Annals of Translational Medicine* for the series “Breast Reconstruction”. The article has undergone external peer review.

Reporting Checklist: The authors have completed the Narrative Review reporting checklist. Available at <https://atm.amegroups.com/article/view/10.21037/atm-23-504/rc>

Peer Review File: Available at <https://atm.amegroups.com/article/view/10.21037/atm-23-504/prf>

Conflicts of Interest: All authors have completed the ICMJE uniform disclosure form (available at <https://atm.amegroups.com/article/view/10.21037/atm-23-504/coif>). The series “Breast Reconstruction” was commissioned by the editorial office without any funding or sponsorship. O.J.M. served as the unpaid Guest Editor of the series and serves as an unpaid editorial board member of *Annals of Translational Medicine* from July 2022 to June 2024. The authors have no other conflicts of interest to declare.

Ethical Statement: The authors are accountable for all aspects of the work in ensuring that questions related to the accuracy or integrity of any part of the work are appropriately investigated and resolved.

Open Access Statement: This is an Open Access article distributed in accordance with the Creative Commons Attribution-NonCommercial-NoDerivs 4.0 International License (CC BY-NC-ND 4.0), which permits the non-commercial replication and distribution of the article with the strict proviso that no changes or edits are made and the original work is properly cited (including links to both the formal publication through the relevant DOI and the license). See: <https://creativecommons.org/licenses/by-nc-nd/4.0/>.

References

- Dvali L, Mackinnon S. The role of microsurgery in nerve repair and nerve grafting. *Hand Clin* 2007;23:73-81.
- Escandón JM, Ciudad P, Poore SO, et al. Experimental Models and Practical Simulators for Supermicrosurgery: An Updated Systematic Review and Meta-Analysis. *Plast Reconstr Surg* 2023;151:775e-803e.
- Liao WC, Chen JR, Wang YJ, et al. The efficacy of end-to-end and end-to-side nerve repair (neurorrhaphy) in the rat brachial plexus. *J Anat* 2009;215:506-21.
- Beris A, Gkiatas I, Gelalis I, et al. Current concepts in peripheral nerve surgery. *Eur J Orthop Surg Traumatol* 2019;29:263-9.
- Grinsell D, Keating CP. Peripheral nerve reconstruction after injury: a review of clinical and experimental therapies. *Biomed Res Int* 2014;2014:698256.
- Escandón JM, Sweitzer K, Christiano JG, et al. Subpectoral versus prepectoral two-stage breast reconstruction: A propensity score-matched analysis of 30-day morbidity and long-term outcomes. *J Plast Reconstr Aesthet Surg* 2023;76:76-87.
- Escandón JM, Christiano JG, Gooch JC, et al. Two-Stage Implant-Based Breast Reconstruction Using Intraoperative Fluorescence Imaging: A Propensity Score-Matched Analysis. *Plast Reconstr Surg* 2024;153:291-303.
- U.S. Cancer Statistics Working Group. U.S. Cancer Statistics Data Visualizations Tool, based on 2021 submission data (1999-2019) [cited 2023 May 27]. Available online: <https://gis.cdc.gov/Cancer/USCS/#/AtAGlance/>
- Escandón JM, Escandón L, Ahmed A, et al. Breast reconstruction using the Latissimus Dorsi Flap and Immediate Fat Transfer (LIFT): A systematic review and meta-analysis. *J Plast Reconstr Aesthet Surg* 2022;75:4106-16.
- Phillips BT, Wang ED, Mirrer J, et al. Current practice among plastic surgeons of antibiotic prophylaxis and closed-suction drains in breast reconstruction: experience, evidence, and implications for postoperative care. *Ann Plast Surg* 2011;66:460-5.
- Escandón JM, Ali-Khan S, Christiano JG, et al. Simultaneous Fat Grafting During Tissue Expander-to-Implant Exchange: A Propensity Score-Matched Analysis. *Aesthetic Plast Surg* 2023;47:1695-706.
- Temple CLF, Ross DC, Kim S, et al. Sensibility following innervated free TRAM flap for breast reconstruction: Part II. Innervation improves patient-rated quality of life. *Plast Reconstr Surg* 2009;124:1419-25.
- Carrau D, Del Pinto Z, Carraher A, et al. Breast reinnervation—the next frontier in autologous breast reconstruction: a review of early results. *Ann Breast Surg* 2022;6:14.
- Escandón JM, Nazerali R, Ciudad P, et al. Minimally invasive harvest of the latissimus dorsi flap for breast reconstruction: A systematic review. *Int J Med Robot* 2022;18:e2446.

15. Beugels J, Cornelissen AJM, Spiegel AJ, et al. Sensory recovery of the breast after innervated and non-innervated autologous breast reconstructions: A systematic review. *J Plast Reconstr Aesthet Surg* 2017;70:1229-41.
16. Beugels J, Cornelissen AJM, van Kuijk SMJ, et al. Sensory Recovery of the Breast following Innervated and Noninnervated DIEP Flap Breast Reconstruction. *Plast Reconstr Surg* 2019;144:178e-88e.
17. Beugels J, Bijkerk E, Lataster A, et al. Nerve Coaptation Improves the Sensory Recovery of the Breast in DIEP Flap Breast Reconstruction. *Plast Reconstr Surg* 2021;148:273-84.
18. Spiegel AJ, Menn ZK, Eldor L, et al. Breast Reinnervation: DIEP Neurotization Using the Third Anterior Intercostal Nerve. *Plast Reconstr Surg Glob Open* 2013;1:e72.
19. Spiegel AJ, Salazar-Reyes H, Izaddoost S, et al. A novel method for neurotization of deep inferior epigastric perforator and superficial inferior epigastric artery flaps. *Plast Reconstr Surg* 2009;123:29e-30e.
20. Djohan R, Scomacao I, Duraes EFR, et al. Sensory Restoration in Abdominally Based Free Flaps for Breast Reconstruction Using Nerve Allograft. *Plast Reconstr Surg* 2023;151:25-33.
21. Smeele HP, Bijkerk E, van Kuijk SMJ, et al. Innervation of the Female Breast and Nipple: A Systematic Review and Meta-Analysis of Anatomical Dissection Studies. *Plast Reconstr Surg* 2022;150:243-55.
22. Cooper AP. On the Anatomy of the Breast 1840. London: Longman, Orme, Green, Brown, and Longmans. Available online: <https://jdc.jefferson.edu/cooper/60/>
23. Eckhard C. Die Nerven der weiblichen Brustdrüse und ihr Einfluß auf die Milchsekretion. *Beitr Anat Physiol* 1851;1:1-9.
24. Jaeger K, Schneider B. Die Innervation und Durchblutung der Mamille im Hinblick auf der perimamilläre Incision. *Chirurg* 1982;53:525-7.
25. Jaspars JJ, Posma AN, van Immerseel AA, et al. The cutaneous innervation of the female breast and nipple-areola complex: implications for surgery. *Br J Plast Surg* 1997;50:249-59.
26. Ricbourg B. Anatomie appliquée du sein. *Ann Chir Plast Esthet* 1992;37:603-20.
27. Sarhadi NS, Shaw Dunn J, Lee FD, et al. An anatomical study of the nerve supply of the breast, including the nipple and areola. *Br J Plast Surg* 1996;49:156-64.
28. Sykes PA. The innervation of the human nipple. *Manch Med Gaz* 1970;49:21-3.
29. Schlenz I, Kuzbari R, Gruber H, et al. The sensitivity of the nipple-areola complex: an anatomic study. *Plast Reconstr Surg* 2000;105:905-9.
30. Li X, Feng-chun L. Approaches of application anatomy of innervation in nipple and areola of breast. *Anat Clin* 2003;8:13-5.
31. Riccio CA, Zeiderman MR, Chowdhry S, et al. Plastic Surgery of the Breast: Keeping the Nipple Sensitive. *Eplasty* 2015;15:e28.
32. Würinger E, Mader N, Posch E, et al. Nerve and vessel supplying ligamentous suspension of the mammary gland. *Plast Reconstr Surg* 1998;101:1486-93.
33. Edwards EA. Surgical anatomy of the breast. In: Goldwyn RM, ed. *Plastic and Reconstructive Surgery of the Breast*. Boston, MA: Little, Brown; 1976:53-73.
34. Farina MA, Newby BG, Alani HM. Innervation of the nipple-areola complex. *Plast Reconstr Surg* 1980;66:497-501.
35. Doncatto L, Hochberg J, Caleffi M. Breast Reconstruction with Sensitive TRAM Flap Reinnervation. *Breast J* 1997;3:345-9.
36. Peled AW, Peled ZM. Nerve Preservation and Allografting for Sensory Innervation Following Immediate Implant Breast Reconstruction. *Plast Reconstr Surg Glob Open* 2019;7:e2332.
37. Isenberg JS. Sense and sensibility: breast reconstruction with innervated TRAM flaps. *J Reconstr Microsurg* 2002;18:23-8.
38. Isenberg JS, Spinelli H. Further experience with innervated autologous flaps in postoncologic breast reconstruction. *Ann Plast Surg* 2004;52:448-51; discussion 451.
39. Yano K, Hosokawa K, Takagi S, et al. Breast reconstruction using the sensate latissimus dorsi musculocutaneous flap. *Plast Reconstr Surg* 2002;109:1897-902; discussion 1903.
40. Mori H, Okazaki M. Is the sensitivity of skin-sparing mastectomy or nipple-sparing mastectomy superior to conventional mastectomy with innervated flap? *Microsurgery* 2011;31:428-33.
41. Cornelissen AJM, Beugels J, van Kuijk SMJ, et al. Sensation of the autologous reconstructed breast improves quality of life: a pilot study. *Breast Cancer Res Treat* 2018;167:687-95.
42. Beugels J, van Kuijk SMJ, Lataster A, et al. Sensory Recovery of the Breast following Innervated and Noninnervated Lateral Thigh Perforator Flap Breast Reconstruction. *Plast Reconstr Surg* 2021;147:281-92.
43. Bijkerk E, van Kuijk SMJ, Lataster A, et al. Breast sensibility in bilateral autologous breast reconstruction with unilateral sensory nerve coaptation. *Breast Cancer*

- Res Treat 2020;181:599-610.
44. Puonti HK, Broth TA, Soinila SO, et al. How to Assess Sensory Recovery After Breast Reconstruction Surgery? Clin Breast Cancer 2017;17:471-85.
 45. Puonti HK, Jääskeläinen SK, Hallikainen HK, et al. Improved sensory recovery with a novel dual neurotomy technique for breast reconstruction with free muscle sparing TRAM flap technique. Microsurgery 2017;37:21-8.
 46. Temple CL, Tse R, Bettger-Hahn M, et al. Sensibility following innervated free TRAM flap for breast reconstruction. Plast Reconstr Surg 2006;117:2119-27; discussion 2128-30.
 47. Magarakis M, Venkat R, Dellon AL, et al. Pilot study of breast sensation after breast reconstruction: evaluating the effects of radiation therapy and perforator flap neurotization on sensory recovery. Microsurgery 2013;33:421-31.
 48. Djohan R, Scomacao I, Knackstedt R, et al. Neurotization of the Nipple-Areola Complex during Implant-Based Reconstruction: Evaluation of Early Sensation Recovery. Plast Reconstr Surg 2020;146:250-4.
 49. Yap LH, Whiten SC, Forster A, et al. Sensory recovery in the sensate free transverse rectus abdominis myocutaneous flap. Plast Reconstr Surg 2005;115:1280-8.
 50. Puonti HK, Jääskeläinen SK, Hallikainen HK, et al. A new approach to microneurovascular TRAM-flap breast reconstruction--a pilot study. J Plast Reconstr Aesthet Surg 2011;64:346-52.
 51. Slezak S, McGibbon B, Dellon AL. The sensate transverse rectus abdominis musculocutaneous (TRAM) flap: return of sensibility after TRAM breast reconstruction. Ann Plast Surg 1992;28:210-7.
 52. Shiah E, Laikhter E, Comer CD, et al. Neurotization in Innervated Breast Reconstruction: A Systematic Review of Techniques and Outcomes. J Plast Reconstr Aesthet Surg 2022;75:2890-913.
 53. Yano K, Matsuo Y, Hosokawa K. Breast reconstruction by means of innervated rectus abdominis myocutaneous flap. Plast Reconstr Surg 1998;102:1452-60.
 54. Blondeel PN, Demuyneck M, Mete D, et al. Sensory nerve repair in perforator flaps for autologous breast reconstruction: sensate or senseless? Br J Plast Surg 1999;52:37-44.
 55. Ciudad P, Bolletta A, Kaciulyte J, et al. The Breast Cancer-Related Lymphedema Multidisciplinary Approach (B-LYMA): Algorithm for Conservative and Multimodal Surgical Treatment. Microsurgery 2023;43:427-36.
 56. Zavlin D, Jubbal KT, Ellsworth WA 4th, et al. Breast reconstruction with DIEP and SIEA flaps in patients with prior abdominal liposuction. Microsurgery 2018;38:413-8.
 57. Lu Wang M, Qin N, Chen Y, et al. A Comparative Analysis of Sensory Return in Delayed-Immediate Versus Immediate Neurotized Deep Inferior Epigastric Perforator Flap Breast Reconstruction. Ann Plast Surg 2023. [Epub ahead of print]. doi: 10.1097/SAP.0000000000003533.
 58. Blondeel PN. The sensate free superior gluteal artery perforator (S-GAP) flap: a valuable alternative in autologous breast reconstruction. Br J Plast Surg 1999;52:185-93.
 59. Viterbo F, Palhares A, Franciosi LF. Restoration of sensitivity after removal of the sural nerve. A new application of latero-terminal neurotomy. Sao Paulo Med J 1994;112:658-60.
 60. Viterbo F, Franciosi LF, Palhares A. Nerve graftings and end-to-side neurotomy connecting the phrenic nerve to the brachial plexus. Plast Reconstr Surg 1995;96:494-5.
 61. Rebowe R, Rogers A, Yang X, et al. Nerve Repair with Nerve Conduits: Problems, Solutions, and Future Directions. J Hand Microsurg 2018;10:61-5.
 62. Mori H, Akita K, Hata Y. Anatomical study of innervated transverse rectus abdominis musculocutaneous and deep inferior epigastric perforator flaps. Surg Radiol Anat 2007;29:149-54.
 63. Hamilton KL, Kania KE, Spiegel AJ. Post-mastectomy sensory recovery and restoration. Gland Surg 2021;10:494-7.
 64. Kaur MN, Chan S, Bordeleau L, et al. Re-examining content validity of the BREAST-Q more than a decade later to determine relevance and comprehensiveness. J Patient Rep Outcomes 2023;7:37.
 65. Momeni A, Meyer S, Shefren K, et al. Flap Neurotization in Breast Reconstruction with Nerve Allografts: 1-year Clinical Outcomes. Plast Reconstr Surg Glob Open 2021;9:e3328.
 66. O'Neill RC, Spiegel AJ. Modern Approaches to Breast Neurotization. Clin Plast Surg 2023;50:347-55.
 67. Laikhter E, Shiah E, Manstein SM, et al. Trends and characteristics of neurotization during breast reconstruction: perioperative outcomes using the American College of Surgeons National Surgical Quality Improvement Program (ACS-NSQIP). J Plast Surg Hand Surg 2022;56:291-7.
 68. Manrique OJ, Escandón JM. Breast reconstruction in the era of evidence-based medicine. Ann Transl Med 2023;11:341.
 69. Burns JR, Polyak TS, Pereira CT. Neurotization of

- the Nipple-Areola Complex during Implant-Based Reconstruction: Evaluation of Early Sensation Recovery. *Plast Reconstr Surg* 2021;148:143e-4e.
70. Enajat M, Rozen WM, Audolfsson T, et al. Thermal injuries in the insensate deep inferior epigastric artery perforator flap: case series and literature review on mechanisms of injury. *Microsurgery* 2009;29:214-7.
71. Faulkner HR, Colwell AS, Liao EC, et al. Thermal Injury to Reconstructed Breasts from Commonly Used Warming Devices: A Risk for Reconstructive Failure. *Plast Reconstr Surg Glob Open* 2016;4:e1033.
72. Damen TH, Timman R, Kunst EH, et al. High satisfaction rates in women after DIEP flap breast reconstruction. *J Plast Reconstr Aesthet Surg* 2010;63:93-100.

Cite this article as: Escandón JM, Mroueh J, Reid CM, Singh D, Sweitzer K, Ciudad P, Nazerali R, Forte AJ, Manrique OJ. Innervated breast reconstruction: a narrative review of neurotization techniques and outcomes. *Ann Transl Med* 2024;12(4):76. doi: 10.21037/atm-23-504