

Case Report

Glandular Odontogenic Cyst in Dentigerous Relationship: An Uncommon Case Report

Jean Carlos Barbosa Ferreira,¹ Eneida Franco Vêncio,² Rodrigo Tavares de Sá ¹,
and Giovanni Gasperini ¹

¹Department of Oral and Maxillofacial Surgery, Clinical Hospital, Federal University of Goiás, Goiânia, Brazil

²Department of Oral Medicine (Oral Pathology), Dental School, Federal University of Goiás, Goiânia, Brazil

Correspondence should be addressed to Giovanni Gasperini; gasperinibuco@gmail.com

Received 5 May 2019; Accepted 3 June 2019; Published 4 July 2019

Academic Editor: Roberto Sacco

Copyright © 2019 Jean Carlos Barbosa Ferreira et al. This is an open access article distributed under the Creative Commons Attribution License, which permits unrestricted use, distribution, and reproduction in any medium, provided the original work is properly cited.

Glandular odontogenic cyst (GOC) is an uncommon cyst of the jaw. Less than 200 cases are reported in the literature, and only 22 cases are associated with an unerupted tooth (dentigerous relationship). Although it is an asymptomatic lesion, it can be destructive and has high recurrence rates. The diagnosis can be especially challenging due to the lack of distinct diagnostic clinic-radiological criteria and nonspecific microscopic features, mimicking benign and malignant lesions. Conservative surgical treatment has been the choice for most surgeons, but marginal or partial jaw resection has been reported. This report describes a rare case of GOC in a dentigerous relationship, which was treated with enucleation and peripheral osteotomy.

1. Introduction

Glandular odontogenic cysts (GOCs) are uncommon jawbone cysts of odontogenic origin which were firstly described in 1987 by Padayachee and Van Wyk [1] as a “botryoid” odontogenic cyst with glandular component and denominated “sialo-odontogenic cyst.” Gardner et al. [2] in 1988 established this cyst as a distinct entity-denominated glandular odontogenic cyst, which was classified as an odontogenic cyst by the WHO in 1992 [3].

To the best of our knowledge, there are 196 GOCs in the English literature [4–14]. Clinically, GOCs are small and usually appear as an asymptomatic swelling, though a few cases have presented with pain and paresthesia. The most common site is the mandible, particularly the anterior region. The cyst shows no sex predilection and mostly affects middle-aged individuals, between 45 and 50 years old; however, there are also reports in pediatric patients [4, 15]. According to Kaplan et al. [16], its

recurrence rate is around 35.9%, particularly when conservative surgical treatment is chosen.

Radiographically, it presents as a uni- or multilocular cystic lesion, with well-defined margins, though some lesions exhibit scalloped borders. Other findings include loss of cortical integrity, root resorption, and association with unerupted teeth [15]. Some cases show a dentigerous, lateral periodontal, and “globulomaxillary” relationship [17].

Microscopically, the diagnosis of GOC can be challenging, given the rarity of the lesion and the fact that the differential diagnosis includes benign and malignant lesions, such as botryoid cysts, surgical ciliated cysts, radicular or dentigerous cysts with metaplastic changes, and low-grade mucoepidermoid carcinoma (MEC) [14, 16, 17]. Histopathological features for the GOC have been described, but the exact microscopic criteria necessary for diagnosis have not been universally accepted. These features include a nonkeratinized stratified squamous lining epithelium with focal thickening (plaques) in the cystic lining, eosinophilic

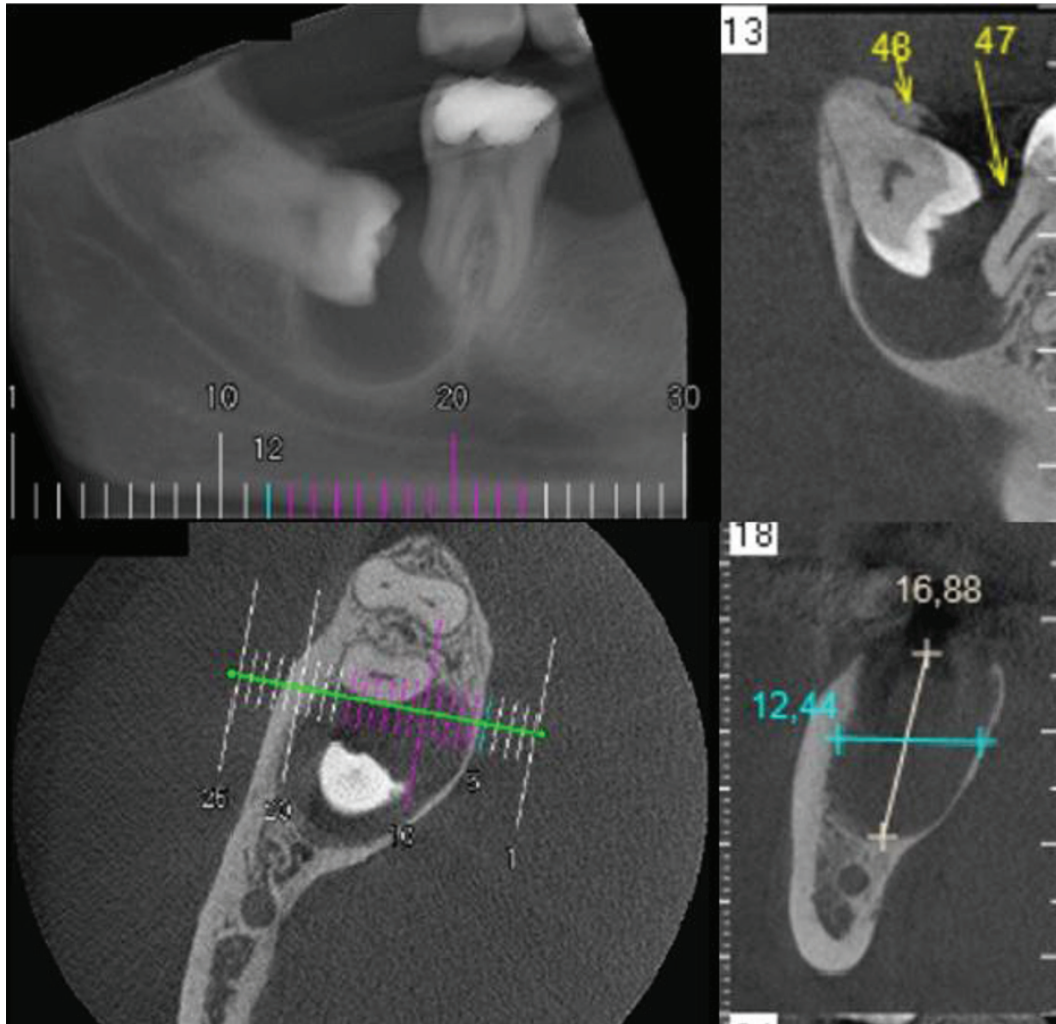


FIGURE 1: Preoperative CBCT showing well-defined unilocular radiolucency associated with an impacted right third molar extending to the distal root of the second molar.

cuboidal or ciliated columnar cells, mucous cells, and interepithelial gland-like structures [1–3, 16].

Several treatment modalities have been indicated for the GOCs, including conservative approaches, such as enucleation with or without curettage, marsupialization, peripheral osteotomy and chemical cauterization with Carnoy's solution, and marginal resection/partial jaw resection [4]. This report documents an uncommon case of GOC in a dentigerous relationship (GOC-DR), which was treated with enucleation and peripheral osteotomy.

2. Case Report

A 36-year-old male, with no medical history, was referred to the Clinical Hospital of the Federal University of Goiás, Goiânia, Goiás, Brazil, for evaluation of an asymptomatic radiolucent lesion in the posterior mandible region. Cone-beam computed tomography (CBCT) scan showed a well-defined unilocular radiolucency associated with an impacted right third molar, extending to the distal root of the second

molar, measuring 17×12.5 mm (Figure 1). Intraoral examination revealed signs of healthy gingiva; absence of teeth 16, 36, 37, and 46; and absence of bone expansion. However, clinical attachment loss in the distal root of tooth 47 with pulp vitality was verified. Previous aspiration was negative and previous diagnosis of dentigerous cyst was made. Due to the small size of the lesion, the treatment choice included tooth removal, enucleation, and peripheral osteotomy. A thick cystic wall was evident during the surgical procedures.

The histopathological examination revealed cyst wall lining by nonkeratinized stratified squamous epithelium with varied thickness (Figure 2(a)). Duct-like structures surrounded by cuboidal cells and numerous mucous cells were also identified (Figures 2(b) and 2(c)). The superficial layer of the epithelium showed columnar ciliated and eosinophilic cuboidal cells, also called "hobnail cells" (Figure 2(d)).

Glycogen-rich and mucin-secreting cells were highlighted by periodic acid-Schiff (PAS), periodic acid-Schiff diastase

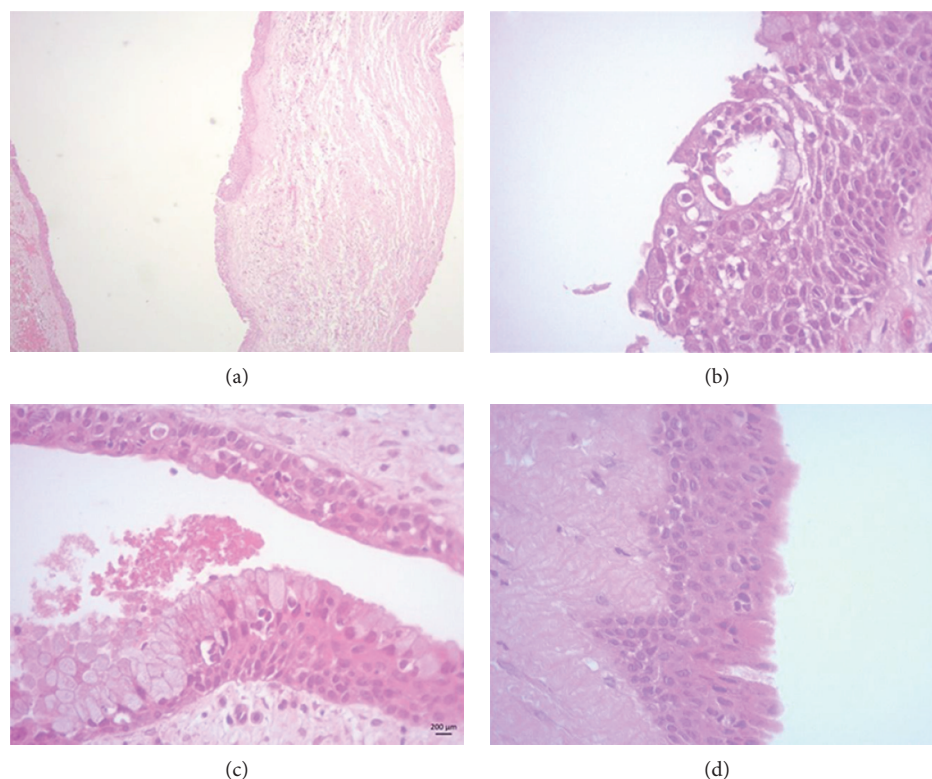


FIGURE 2: Microscopic features of the GOC. (a) Cystic cavity lined by nonkeratinized stratified squamous epithelium of varying thickness. (b) Duct-like structures observed in the cystic lining. (c) Presence of numerous goblet cells. (d) Note the presence of eosinophilic cuboidal cells. Slides stained with haematoxylin and eosin. Original magnifications: 50x and 400x.

(PAS-D) (Figures 3(a)–3(c)), and mucicarmine staining (Figure 3(d)). A final diagnosis of GOC was made following the criteria established by Fowler et al. [17]. The postoperative orthopantomogram (OPG) revealed no recurrence one year postsurgery (Figure 4).

3. Discussion

Our study reports an uncommon case of GOC associated with an unerupted third molar mimicking a dentigerous cyst. This characteristic was defined by Fowler et al. [17] as a “dentigerous relationship.” In the English literature, only 22 similar cases have been documented [18–22].

Table 1 [17–27] summarizes previous published cases of GOC-DR. Complete clinical data was not be available in all cases. Males were more often affected (male:female ratio, 3:1) and age ranged from 21 to 62 years old (mean 38 years old). The mandible was affected in 53.8% of cases, in which 57.1% involved the unerupted third molar and 42.8% the canine. Swelling was the most common clinical presentation with 85.7%, followed by pain (28.5%), and numbness (14.2%). Unilocular radiolucency was described in 10 cases (76.9%). Half of the cases were treated with enucleation, followed by curettage (41.6%) and block resection (8.3%). In the present case, a 36-year-old male presented an asymptomatic mandibular lesion detected incidentally by routine radiological examination treated with enucleation and

peripheral osteotomy [4, 16, 18, 21, 22]. It should be noted that unlike classic GOC, GOC-DR has a strong predilection for the male sex and posterior mandible.

Clinical diagnosis of GOC is challenging. The differential diagnosis includes radicular and dentigerous cysts, odontogenic keratocysts, and ameloblastoma. Although Krishnamurthy et al. [19] suggest that a preoperative aspiration biopsy may be helpful in diagnosing GOC, in our case, it was negative, as reported by Momeni Roochi et al. [23]. Distinct fluids have been reported in the literature, including clear with low viscosity, creamy high-viscosity, and brownish-red liquids [19, 23, 28, 29]. Another interesting clinical finding in our case was the presence of a thick cystic wall, contrary to findings shown by Thor et al. [30].

The histopathological diagnosis of GOC also remains a challenge. Microscopic features include focal epithelial thickening, epithelial plaques, and glycogen-rich epithelial cells, which are also observed in botryoid and lateral periodontal cysts. The presence of ciliated epithelium and duct-like spaces with mucous cells and eosinophilic cuboidal cells located in the epithelial surface support the diagnosis of GOC [17, 31]. According to Fowler et al. [17], the presence of microcysts, clear cells, and epithelial spheres may be helpful in distinguishing GOC-DR from dentigerous cyst with metaplastic changes. The most important and difficult distinction according to Kaplan et al. [16] is the differentiation of low-grade MEC from GOC, especially its multicystic

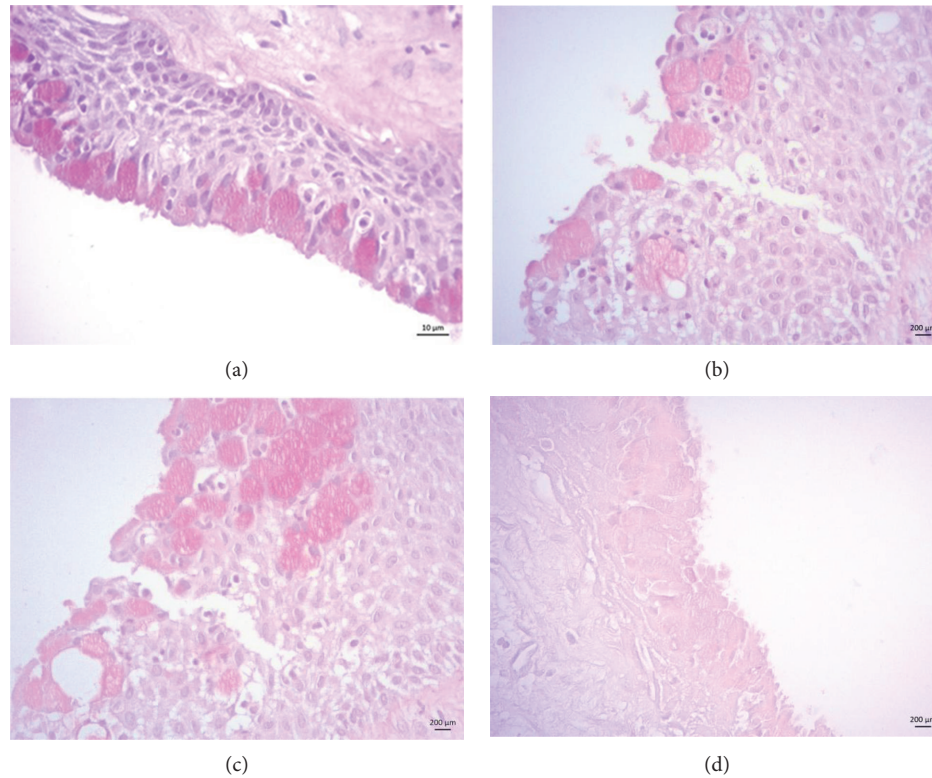


FIGURE 3: Special stains for GOC. (a, b) Periodic acid-Schiff- (PAS-) and periodic acid-Schiff diastase- (PAS-D-) positive goblet cells showing glycogen-rich cells. (c) Note the glandular-like structure stained by PAS-D. Mucin-secreting cells were also identified.

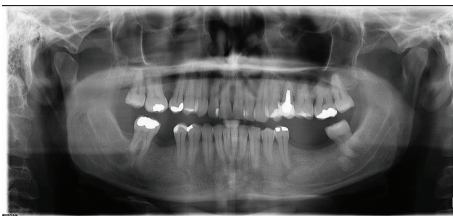

FIGURE 4: Patient's orthopantomogram (OPG) showing bone healing after a 2-year follow-up.

variant. Ciliated cells, superficial cuboidal cells, epithelial whorls, and intraepithelial microcyst or duct-like structures are not typical for low-grade MEC, which can help in the differentiation. Immunostain for MASPIN, Ki-67, and CKs 18 and 19 may be helpful to distinguish GOC from low-grade MEC [14].

Due to the overlapping of histological features with others lesions, Fowler et al. [17] suggested 10 microscopic parameters for diagnosing GOC: surface eosinophilic cuboidal cells or "hobnail cells", intraepithelial microcysts or duct-like spaces lined by a single layer of cuboidal to columnar cells, apocrine snouting of hobnail cells, clear or vacuolated cells, variable thickness in the cyst lining, papillary projections or "tufting" into the cyst lumen, mucous goblet cells, epithelial spheres, or plaque-like thickening cilia, and multiple compartments. According

to the authors, the presence of seven or more microscopic parameters is highly predictive of a diagnosis of GOC. In our case, only multiple compartments and papillary projections were not evidenced.

Minor surgical procedures, such as enucleation with or without curettage and peripheral ostectomy, are the most common treatment modalities reported in the literature [4, 32]. In this study, enucleation associated with peripheral osteotomy was performed due to three factors: patient choice, clinical and radiological diagnosis of a dentigerous cyst, and lesion size (17×12.5 mm). On the other hand, radical treatments, such as marginal resection, can sometimes be considered due to the biological behavior of GCO, particularly due to local aggressiveness and recurrence rates around 21-55% [15, 19, 33]. Some reports suggest that recurrence is more common in larger lesions, with cortical bone perforation and multilocular radiographic appearance [30, 32]. In the present case, neither of these characteristics was evident and no recurrence was detected after two years follow-up.

4. Conclusion

This report describes an uncommon case of GOC-DR mimicking other lesions in the oral cavity. These lesions tend to most commonly affect the posterior mandible and younger male patients.

TABLE 1: Clinical and radiological data of GOC in dentigerous relationship.

| Year | Author | Number of cases | Age/gender | Site | Clinical presentation | Radiologic features | Treatment | Follow-up (year) |
|------|----------------------------|-----------------|--|---|--|---|---|------------------|
| 2019 | Ferreira et al. (our case) | 1 | 36/M | Mandibular right third molar | Asymptomatic | Unilocular radiolucency | Enucleation/peripheral osteotomy | 1 |
| 2015 | Momeni Roochi et al. [23] | 1 | 62/M | Mandibular right canine impacted | Swelling | Unilocular radiolucency | Enucleation | 3 |
| 2012 | Cano et al. [18] | 1 | 54/M | Mandibular right third molar (ramus/body) | Swelling | Multilocular radiolucent, large and well-defined | Enucleation and curettage, reconstruction | 3 |
| 2011 | Fowler et al. [17] | 8 | NS | NS | NS | NS | NS | NS |
| 2009 | Krishnamurthy et al. [19] | 1 | 21/M | Mandibular left third molar | Swelling | Multilocular radiolucency | En bloc resection | 2 |
| 2006 | Kasaboglu et al. [24] | 1 | 45/M | Mandibular left canine | Swelling and numbness | Unilocular radiolucency with a well-defined border | Enucleation | 0.5 |
| 2006 | Shen et al. [25] | 2 | Case 1: 40/M; case 2: NS | Case 1: maxillary tooth-like structures; case 2: NS | Case 1: NS; case 2: NS | Case 1: unilocular radiolucency; case 2: NS | Case 1: NS; case 2: NS | NS |
| 2006 | Yoon et al. [20] | 1 | 66/F | Mandibular right third molar | Swelling and painful | Unilocular radiolucency, thin sclerotic margin, root resorption | Enucleation | 1 |
| 2005 | Qin et al. [26] | 5* | Case 1: 28/M; case 2: 40/M; case 3: 25/M; case 4: 22/M; case 5: 52/F | Case 1: maxilla L (21-27); case 2: maxilla R (11-16); case 3: maxilla R (13-16); case 4: maxilla L (21-23); case 5: maxilla (16-25) | Case 1: NS; case 2: NS; case 3: NS; case 4: NS; case 5: NS | Case 1: unilocular radiolucency; case 2: unilocular radiolucency, irregular borders; case 3: unilocular radiolucency, irregular borders; case 4: unilocular radiolucency; case 5: multilocular radiolucency | Case 1: curettage; case 2: curettage; case 3: curettage; case 4: curettage; case 5: curettage | NS |
| 2005 | Kaplan et al. [21, 22] | 1 | 49/M | Mandibular left third molar | Swelling and painless | Unilocular radiolucency | Enucleation, peripheral osteotomy, reconstruction with iliac crest & alloplast bone graft | 4 |
| 1996 | Ide et al. [27] | 1 | 54/F | Mandibular right canine | Asymptomatic | Unilocular radiolucent definite contained the crown of the horizontally impacted right canine | Enucleation | 1 |

Legend: NS: not specified; M: male; F: female; L: left; R: right. * Case 2 shown in the work of Shen et al. [25].

Consent

The patient has given his consent for the use of his pictures in this article.

Conflicts of Interest

The authors declare that there is no conflict of interest regarding the publication of this paper.

Acknowledgments

This report was funded by Coordenação de Aperfeiçoamento de Pessoal de Nível Superior (CAPES/BRASIL; process number: 88887.295564/2018-00) and Fundação de Amparo à Pesquisa do Estado de Goiás (FAPEG).

References

- [1] A. Padayachee and C. W. Van Wyk, "Two cystic lesions with features of both the botryoid odontogenic cyst and the central mucoepidermoid tumour: sialo-odontogenic cyst?," *Journal of Oral Pathology and Medicine*, vol. 16, no. 10, pp. 499–504, 1987.
- [2] D. G. Gardner, H. P. Kessler, R. Morency, and D. L. Schaffner, "The glandular odontogenic cyst: an apparent entity," *Journal of Oral Pathology and Medicine*, vol. 17, no. 8, pp. 359–366, 1988.
- [3] I. R. H. Kramer, J. J. Pindborg, and M. Shear, "The WHO histological typing of odontogenic tumors. A commentary on the second edition," *Cancer*, vol. 70, no. 12, pp. 2988–2994, 1992.
- [4] M. Faisal, S. A. Ahmad, and U. Ansari, "Glandular odontogenic cyst – literature review and report of a paediatric case," *Journal of Oral Biology and Craniofacial Research*, vol. 5, no. 3, pp. 219–225, 2015.
- [5] B. Chandolia, M. Bajpai, and M. Arora, "Glandular odontogenic cyst," *Journal of the College of Physicians Surgeons Pakistan*, vol. 27, no. 3, pp. 23–25, 2017.
- [6] M. Alaeddini, N. Eshghyar, and S. Etamad-Moghadam, "Expression of podoplanin and TGF-beta in glandular odontogenic cyst and its comparison with developmental and inflammatory odontogenic cystic lesions," *Journal of Oral Pathology & Medicine*, vol. 46, no. 1, pp. 76–80, 2017.
- [7] İ. Akkaş, O. Toptaş, F. Özkan, and F. Yılmaz, "Bilateral glandular odontogenic cyst of mandible: a rare occurrence," *Journal of Maxillofacial and Oral Surgery*, vol. 14, no. S1, pp. 443–447, 2015.
- [8] N. R. Figueiredo, A. D. Dinkar, and M. M. Khorate, "Glandular odontogenic cyst of the maxilla: a case report and literature review," *The Pan African Medical Journal*, vol. 25, p. 116, 2016.
- [9] A. A. Shah, A. Sangle, S. Bussari, and A. V. Koshy, "Glandular odontogenic cyst: a diagnostic dilemma," *Indian Journal of Dentistry*, vol. 7, no. 1, pp. 38–43, 2016.
- [10] K. L. S. Kumar, S. Manuel, B. J. Nair, and S. Vinod Nair, "An ambiguous asymptomatic swelling in the maxillary anterior region - a case report," *International Journal of Surgery Case Report*, vol. 23, pp. 65–69, 2016.
- [11] E. Bulut, B. Baş, D. Dinçer, and Ö. Günhan, "Treatment of maxillary glandular odontogenic cyst involving the same place of previously treated traumatic bone cyst," *Journal of Craniofacial Surgery*, vol. 27, no. 2, pp. e150–e153, 2016.
- [12] S. Chandra, E. S. Reddy, K. Sah, and A. Srivastava, "Maxillary glandular odontogenic cyst: an uncommon entity at an unusual site," *Archives of Iranian Medicine*, vol. 19, no. 3, pp. 221–224, 2016.
- [13] A. Mittal, V. Narang, G. Kaur, and N. Sood, "Glandular odontogenic cyst of mandible: a rare entity," *Journal of Clinical and Diagnostic Research*, vol. 9, no. 12, pp. 9–10, 2015.
- [14] M. Mascitti, A. Santarelli, A. Sabatucci et al., "Glandular odontogenic cyst: review of literature and report of a new case with cytokeratin-19 expression," *The Open Dentistry Journal*, vol. 8, no. 1, pp. 1–12, 2014.
- [15] J. A. Regezi, "Odontogenic cysts, odontogenic tumors, fibrous and giant cell lesions of the jaws," *Modern Pathology*, vol. 15, no. 3, pp. 331–341, 2002.
- [16] I. Kaplan, Y. Anavi, and A. Hirshberg, "Glandular odontogenic cyst: a challenge in diagnosis and treatment," *Oral Diseases*, vol. 14, no. 7, pp. 575–581, 2008.
- [17] C. B. Fowler, R. B. Brannon, H. P. Kessler, J. T. Castle, and M. A. Kahn, "Glandular odontogenic cyst: analysis of 46 cases with special emphasis on microscopic criteria for diagnosis," *Head and Neck Pathology*, vol. 5, no. 4, pp. 364–375, 2011.
- [18] J. Cano, D. M. Benito, J. Montáns, J. F. Rodríguez-Vázquez, J. Campo, and C. Colmenero, "Glandular odontogenic cyst: two high-risk cases treated with conservative approaches," *Journal of Cranio-Maxillofacial Surgery*, vol. 40, no. 5, pp. e131–e136, 2012.
- [19] A. Krishnamurthy, H. J. Sherlin, K. Ramalingam et al., "Glandular odontogenic cyst: report of two cases and review of literature," *Head and Neck Pathology*, vol. 3, no. 2, pp. 153–158, 2009.
- [20] J. H. Yoon, S. G. Ahn, S. G. Kim, and J. Kim, "An unusual odontogenic cyst with diverse histologic features," *Yonsei Medical Journal*, vol. 47, no. 1, pp. 122–125, 2006.
- [21] I. Kaplan, Y. Anavi, R. Manor, J. Sulkes, and S. Calderon, "The use of molecular markers as an aid in the diagnosis of glandular odontogenic cyst," *Oral Oncology*, vol. 41, no. 9, pp. 895–902, 2006.
- [22] I. Kaplan, G. Gal, Y. Anavi, R. Manor, and S. Calderon, "Glandular odontogenic cyst: treatment and recurrence," *Journal of Oral and Maxillofacial Surgery*, vol. 63, no. 4, pp. 435–441, 2005.
- [23] M. Momeni Roochi, I. Tavakoli, F. M. Ghazi, and A. Tavakoli, "Case series and review of glandular odontogenic cyst with emphasis on treatment modalities," *Journal of Cranio-Maxillofacial Surgery*, vol. 43, no. 6, pp. 746–750, 2015.
- [24] O. Kasaboglu, Z. Basal, and A. Usubütün, "Glandular odontogenic cyst presenting as a dentigerous cyst: a case report," *Journal of Oral and Maxillofacial Surgery*, vol. 64, no. 4, pp. 731–733, 2006.
- [25] J. Shen, M. Fan, X. Chen, S. Wang, L. Wang, and Y. Li, "Glandular odontogenic cyst in China: report of 12 cases and immunohistochemical study," *Journal of Oral Pathology & Medicine*, vol. 35, no. 3, pp. 175–182, 2006.
- [26] X.-N. Qin, J.-R. Li, X.-M. Chen, and X. Long, "The glandular odontogenic cyst: clinicopathologic features and treatment of 14 cases," *Journal of Oral and Maxillofacial Surgery*, vol. 63, no. 5, pp. 694–699, 2005.
- [27] F. Ide, T. Shimoyama, and N. Horie, "Glandular odontogenic cyst with hyaline bodies: an unusual dentigerous presentation," *Journal of Oral Pathology & Medicine*, vol. 25, no. 7, pp. 401–404, 1996.

- [28] H. H. Araújo de Moraes, R. José de Holanda Vasconcellos, T. de Santana Santos, L. M. Guedes Queiroz, and É. J. Dantas da Silveira, "Glandular odontogenic cyst: case report and review of diagnostic criteria," *Journal of Cranio-Maxillofacial Surgery*, vol. 40, no. 2, pp. e46–e50, 2012.
- [29] H. S. Koppang, S. Johannessen, L. K. Haugen, H. R. Haanaes, T. Solheim, and K. Donath, "Glandular odontogenic cyst (sialo-odontogenic cyst): report of two cases and literature review of 45 previously reported cases," *Journal of Oral Pathology & Medicine*, vol. 27, no. 9, pp. 455–462, 1998.
- [30] A. Thor, G. Warfvinge, and R. Fernandes, "The course of a long-standing glandular odontogenic cyst: marginal resection and reconstruction with particulated bone graft, platelet-rich plasma, and additional vertical alveolar distraction," *Journal of Oral and Maxillofacial Surgery*, vol. 64, no. 7, pp. 1121–1128, 2006.
- [31] P. Speinght, C. B. Fowler, and H. Kessler, "Odontogenic and non-odontogenic developmental cysts," in *WHO Classification of Head and Neck Tumours*, A. K. El-Naggar, C. JKC, J. R. Grandis, T. Takata, and P. J. Slootweg, Eds., Reed IARC, Lyon, 4th edition, 2017.
- [32] P. Boffano, E. Cassarino, E. Zavattoni, P. Campisi, and P. Garzino-Demo, "Surgical treatment of glandular odontogenic cysts," *Journal of Craniofacial Surgery*, vol. 21, no. 3, pp. 776–780, 2010.
- [33] M. C. N. Lyrio, A. F. de Assis, A. R. Germano, and M. de Moraes, "Treatment of mandibular glandular odontogenic cyst with immediate reconstruction: case report and 5-year follow-up," *British Journal of Oral & Maxillofacial Surgery*, vol. 48, no. 8, pp. 651–653, 2010.