



Review Article

## Perioperative dual antiplatelet therapy for patients undergoing spine surgery soon after drug eluting stent placement

Sophie M. Peeters<sup>1</sup>, Daniel Nagasawa<sup>2</sup>, Bilwaj Gaonkar<sup>1</sup>, Tianyi Niu<sup>3</sup>, Alexander Tucker<sup>4</sup>, Mark Attiah<sup>1</sup>, Diana Babayan<sup>1</sup>, Natalie Moreland<sup>5</sup>, Isaac Yang<sup>1</sup>, Marcela Calfon Press<sup>6</sup>, Luke Macyszyn<sup>1</sup>

<sup>1</sup>Department of Neurosurgery, University of California Los Angeles, Los Angeles, <sup>2</sup>Department of Neurosurgery, Providence Saint John's Health Center, Santa Monica, California, <sup>3</sup>Department of Neurosurgery, Brown University, Providence, Rhode Island, <sup>4</sup>Department of Neurosurgery, Children's Hospital of Philadelphia, Philadelphia, Pennsylvania, Departments of <sup>5</sup>Anesthesiology, <sup>6</sup>Cardiology, University of California Los Angeles, Los Angeles, California, United States.

E-mail: Sophie M. Peeters - speeters@mednet.ucla.edu; Daniel Nagasawa - nagasawamd@gmail.com; Bilwaj Gaonkar - bgaonkar@mednet.ucla.edu; Tianyi Niu - tniu85420@gmail.com; Alexander Tucker - tuckeram@email.chop.edu; Mark Attiah - mattiah@mednet.ucla.edu; Diana Babayan - dbabayan@mednet.ucla.edu; Natalie Moreland - nmoreland@mednet.ucla.edu; Isaac Yang - iyang@mednet.ucla.edu; Marcela Calfon Press - mcalfonpress@mednet.ucla.edu; \*Luke Macyszyn - lmacyszyn@mednet.ucla.edu



**\*Corresponding author:**

Luke Macyszyn,  
Department of Neurosurgery,  
University of California  
Los Angeles, Los Angeles,  
California, United States.

lmacyszyn@mednet.ucla.edu

Received : 06 April 2021

Accepted : 06 May 2021

Published : 28 June 2021

DOI

10.25259/SNI\_337\_2021

Quick Response Code:



### ABSTRACT

**Background:** Performing emergent spinal surgery within 6 months of percutaneous placement of drug-eluting coronary stent (DES) is complex. The risks of spinal bleeding in a "closed space" must be compared with the risks of stent thrombosis or major cardiac event from dual antiplatelet therapy (DAPT) interruption.

**Methods:** Eighty relevant English language papers published in PubMed were reviewed in detail.

**Results:** Variables considered regarding surgery in patients on DAPT for DES included: (1) surgical indications, (2) percutaneous cardiac intervention (PCI) type (balloon angioplasty vs. stenting), (3) stent type (drug-eluting vs. balloon mechanical stent), and (4) PCI to noncardiac surgery interval. The highest complication rate was observed within 6 weeks of stent placement, this corresponds to the endothelialization phase. Few studies document how to manage patients with critical spinal disease warranting operative intervention within 6 months of their PCI for DES placement.

**Conclusion:** The treatment of patients requiring urgent or emergent spinal surgery within 6 months of undergoing a PCI for DES placement is challenging. As early interruption of DAPT may have catastrophic consequences, we hereby proposed a novel protocol involving stopping clopidogrel 5 days before and aspirin 3 days before spinal surgery, and bridging the interval with a reversible P2Y12 inhibitor until surgery. Moreover, postoperatively, aspirin could be started on postoperative day 1 and clopidogrel on day 2. Nevertheless, this treatment strategy may not be appropriate for all patients, and multidisciplinary approval of perioperative antiplatelet therapy management protocols is essential.

**Keywords:** Cangrelor, Drug-eluting stent, Dual antiplatelet therapy, Emergent spine surgery, P2Y12 inhibitor

### INTRODUCTION

At least 6–12 months of dual antiplatelet therapy (DAPT) are routinely utilized after placement of drug-eluting coronary stents (DES).<sup>[7]</sup> For patients requiring urgent or emergent spinal surgery within

6 months of cardiac stent placement, the risks of continuing (i.e. perioperative spinal hemorrhage resulting in severe disability or even death) versus stopping (i.e., acute stent thrombosis or even death) DAPT must be carefully weighed.<sup>[9]</sup>

Here, we reviewed the literature regarding the feasibility and safety of performing urgent spinal surgery for patients on DAPT soon after DES placement utilizing a novel approach. The latter involves cessation of clopidogrel (5 days) and aspirin (3 days) preoperatively with postoperative reinstatement of aspirin (postoperative day 1) and clopidogrel (postoperative day 2).

**MATERIALS AND METHODS**

Important variables when considering surgery in a patient on DAPT for recent cardiac stent placement: (1) the urgency of the surgery, (2) the type of percutaneous cardiac intervention (PCI) (balloon angioplasty vs. stenting), (3) the stent type (drug-eluting vs. balloon mechanical stent), and (4) the PCI to noncardiac surgery time interval.<sup>[10]</sup>

A thorough PubMed search yielded 510 papers on the topic. Critical variables studied included: outcomes of post-PCI patients undergoing emergent spine surgery while on DAPT, perioperative anticoagulation guidelines, and alternative drugs that lessen the risk of bleeding without increasing the risk of stent thrombosis.

**RESULTS**

**Guidelines for DAPT and timing of noncardiac surgery after PCI [Table 1]**

The American College of Cardiology, American Heart Association, and European Society of Cardiology have relatively congruent guidelines regarding the necessity of DAPT for patients with acute coronary syndrome who have undergone PCI with the placement of DES.<sup>[4,7,9,10]</sup> However, the duration of treatment remains controversial. Most current guidelines require 6–12 months of DAPT with aspirin and clopidogrel after PCI revascularization, with continuation of aspirin recommended indefinitely [Table 1].

The guidelines currently recommend waiting at least 1 year before any noncardiac surgery after DES placement, to allow sufficient time for endothelialization.<sup>[10]</sup> Notably, the highest risk for stent thrombosis is within the first 6 weeks after stent placement.<sup>[9]</sup>

**Urgent surgical treatment for cervical spondylotic myelopathy (CSM): indications and management**

With rapidly progressing CSM, postponing surgery risks permanent severe disability. Treatment options for CSM include corpectomy and fusion, anterior cervical discectomy and fusion, posterior cervical decompression (with or without fusion), or any combination thereof.<sup>[8,13]</sup> Alternatively, if the patient is only minimally symptomatic, delaying surgery is a more reasonable option.<sup>[6]</sup>

**Table 1:** Summary of current evidence-based data regarding DAPT and timing of noncardiac surgery after PCI.

Reference(s)	Findings
Dimitrova et al., 2012 <sup>[4]</sup> , Roth et al., 2012 <sup>[9]</sup> , Singla et al., 2012 <sup>[10]</sup>	Current DAPT guidelines and practice: 6-12 mos DAPT with aspirin and clopidogrel after PCI, aspirin indefinitely
Levine et al., 2016 <sup>[7]</sup>	RCTs demonstrate no significant difference in MACEs between short (3-6 mos) and long-term (12 mos) DAPT
Vankuijk et al. Timing of noncardiac surgery after coronary artery stenting with bare metal or drug-eluting stents. Am J Cardiol 2009; 104:1229-3	Study demonstrating no appreciable difference in MACEs between 6-12 mos and > 12 mos DAPT
Roth et al., 2012 <sup>[9]</sup>	Highest complication rate during first 6 weeks after stent placement (mainly stent thrombosis)
Roth et al., 2012 <sup>[9]</sup>	Higher risk of stent thrombosis with EF<50%, renal insufficiency, diabetes, malignancy, or bifurcated stented vessel
Gurbel PA, DiChiara J, Tantry US. Antiplatelet Therapy After Implantation of Drug-Eluting Stents: Duration, Resistance, Alternatives, and Management of Surgical Patients. American Journal of Cardiology 2007; 100:S18-25	Interindividual variance for many antiplatelet agents (i.e., clopidogrel)
Roth et al., 2012 <sup>[9]</sup>	Sudden cessation of DAPT can cause a reflex prothrombotic state contributing to stent thrombosis secondary to upregulation of platelet biomarkers and a pro-inflammatory response
Singla et al., 2012 <sup>[10]</sup>	Wait at least 1 year before any noncardiac surgery after DES placement

DAPT: Dual antiplatelet therapy, DES: Drug-eluting stent, EF: Ejection fraction, MACEs: Major adverse cardiac events, PCI: Percutaneous cardiac intervention, RCT: Randomized control trial

**Perioperative management of DAPT for major noncardiac surgery soon after PCI [Table 2]**

The Clopidogrel in Unstable Angina to Prevent Recurrent Events study and others concluded that patients on both aspirin and clopidogrel are more likely to have major bleeding events and bleeding complications with surgical interventions (3.4-fold) than those solely on aspirin (1.5-fold) [Table 2].<sup>[5,9]</sup> This bleeding risk is particularly concerning

for spinal operations where any hemorrhage may result in catastrophic disability.

However, as the sudden cessation of DAPT can cause a reflex prothrombotic state possibly contributing to stent thrombosis, an antiplatelet “bridge” is recommended perioperatively.<sup>[9]</sup>

**Bridging protocol recommendations [Table 3]**

No standard of care exists regarding perioperative management of patients with DES on DAPT undergoing

**Table 2:** Summary of current evidence-based data regarding perioperative DAPT in major noncardiac surgery soon after PCI.

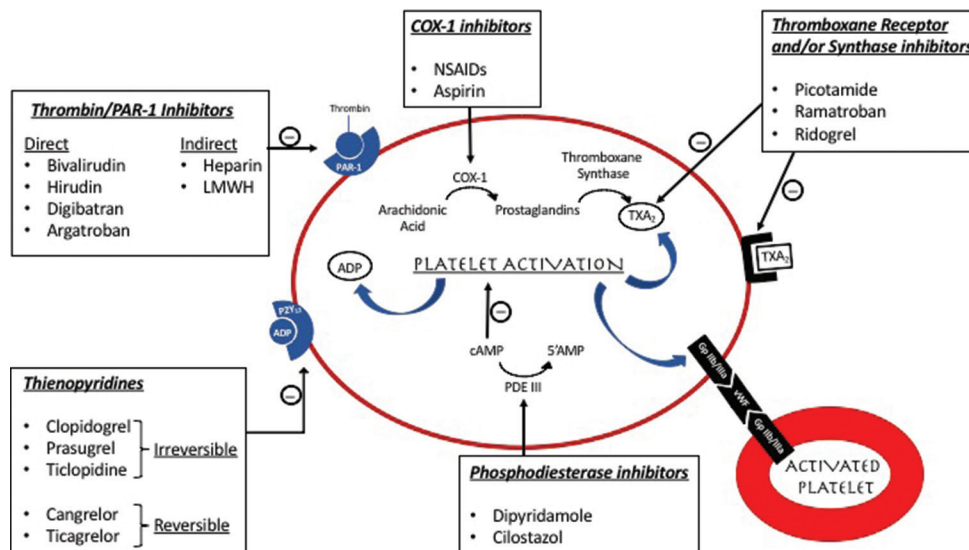
Reference(s)	Findings
Singla et al., 2012 <sup>[10]</sup>	Continuing aspirin during spinal surgery did not show a significant increase in bleeding, operation time, or postoperative blood transfusion compared to no perioperative antiplatelet therapy
Akhavan-Sigari R, Rohde V, Abili M. Continuation of medically necessary platelet aggregation inhibitors - acetylsalicylic acid and clopidogrel - during surgery for spinal degenerative disorders: Results in 100 patients. Surg Neurol Int 2014; 5:S376-9	No increased risk of bleeding in patients undergoing elective spinal surgery and receiving aspirin and clopidogrel compared to aspirin alone before surgery
Gerschutz and Bhatt, 2002 <sup>[5]</sup>	Patients on aspirin and clopidogrel are more likely to have major bleeding events with surgical interventions than those on aspirin alone

spine surgery. Some recommend holding DAPT up to five half-lives before surgery and starting a bridging agent within 12 months of the PCI to minimize ischemic cardiac events.<sup>[9]</sup> When selecting a bridging agent, critical characteristics to consider include reversibility and a short half-life.<sup>[9]</sup>

Bridging agents include GP IIb/IIIa receptor inhibitors which interfere with fibrinogen, oral irreversible P2Y12 receptor inhibitors, and thrombin protease-activated receptor inhibitors. Postoperatively, both aspirin and clopidogrel can be safely restarted on postoperative day 1 or 2 with loading doses [Table 3].<sup>[2]</sup> Interestingly, one study showed that bridging with low-molecular-weight heparin was linked to more major adverse cardiac and cerebrovascular events and bleeding complications versus remaining on DAPT perioperatively.<sup>[3]</sup>

**Promise of cangrelor**

Cangrelor, a reversible, intravenous P2Y12 inhibitor with rapid onset and return to baseline platelet function when discontinued may be considered as a new bridging agent [Figure 1].<sup>[1,11]</sup> Its safety and efficacy as a bridging agent have been established in the BRIDGE trial for patients undergoing coronary artery bypass grafting.<sup>[11]</sup> They found no excessive bleeding or significant increase in ischemic events.<sup>[11]</sup> The Cangrelor versus Standard Therapy to Achieve Optimal Management of Platelet Inhibition trials demonstrated reduced stent thrombosis in the cangrelor group and comparable bleeding rates relative to the clopidogrel group.<sup>[11]</sup> Nonetheless, a drug application for the use of cangrelor in post-PCI patients as a bridging therapy in noncardiac surgeries was initially denied by the FDA in 2014; however, the drug was recently approved in 2016 for pretreatment in PCI patients only.<sup>[12]</sup>



**Figure 1:** Illustration of the mechanism of action of the various groups of antiplatelet agents.

**Table 3:** Recommended bridging protocol.

Preoperative	Intraoperative	Postoperative
Hold aspirin 3 days before surgery	Consider IV P2Y <sub>12</sub> inhibitor (i.e., cangrelor)	Restart aspirin postoperative day 1
Hold clopidogrel 5 days before surgery		Restart clopidogrel postoperative day 2

## CONCLUSION

There is a great concern regarding the lack of clear guidelines for perioperative antiplatelet therapy for patients requiring urgent or emergent spine surgery within 6 months of PCI with DES implantation. We propose a novel protocol in which clopidogrel and aspirin are stopped 5 and 3 days before surgery, respectively, a reversible P2Y<sub>12</sub> inhibitor such as cangrelor is used as bridging agent until the time of surgery, and postoperatively, aspirin and clopidogrel may be restarted on postoperative day 1 and 2, respectively.

## Ethical approval

This article does not contain any studies with human participants or animals performed by any of the authors. For this type of study, formal consent is not required.

## Declaration of patient consent

Patient's consent not required as there are no patients in this study.

## Financial support and sponsorship

Nil.

## Conflicts of interest

There are no conflicts of interest.

## REFERENCES

- Bhatt DL, Stone GW, Mahaffey KW, Gibson CM, Steg PG, Hamm CW, *et al.* Effect of platelet inhibition with cangrelor during PCI on ischemic events. *N Engl J Med* 2013;368:1303-13.
- Broad L, Lee T, Conroy M, Bolsin S, Orford N, Black A, *et al.* Successful management of patients with a drug-eluting coronary stent presenting for elective, non-cardiac surgery. *Br J Anaesth* 2007;98:19-22.
- Capodanno D, Musumeci G, Lettieri C, Limbruno U, Senni M, Guagliumi G, *et al.* Impact of bridging with perioperative low-molecular-weight heparin on cardiac and bleeding outcomes of stented patients undergoing non-cardiac surgery. *Thromb Haemost* 2015;114:423-31.
- Dimitrova G, Tulman DB, Bergese SD. Perioperative management of antiplatelet therapy in patients with drug-eluting stents. *HSR Proc Intensive Care Cardiovasc Anesth* 2012;4:153-67.
- Gerschutz GP, Bhatt DL. The CURE trial: Using clopidogrel in acute coronary syndromes without ST-segment elevation. *Cleve Clin J Med* 2002;69:377-8, 380, 382.
- Kadaňka Z, Bednařík J, Vohánka S, Vlach O, Stejskal L, Chaloupka R, *et al.* Conservative treatment versus surgery in spondylotic cervical myelopathy: A prospective randomised study. *Eur Spine J* 2000;9:538-44.
- Levine GN, Bates ER, Bittl JA, Brindis RG, Fihn SD, Fleisher LA, *et al.* 2016 ACC/AHA guideline focused update on duration of dual antiplatelet therapy in patients with coronary artery disease: A report of the American college of cardiology/American heart association task force on clinical practice guidelines. *J Thorac Cardiovasc Surg* 2016;152:1243-75.
- Liu JM, Peng HW, Liu ZL, Long XH, Yu YQ, Huang SH. Hybrid decompression technique versus anterior cervical corpectomy and fusion for treating multilevel cervical spondylotic myelopathy: Which one is better? *World Neurosurg* 2015;84:2022-9.
- Roth E, Purnell C, Shabalov O, Mogueillansky D, Hernandez CA, Elnicki M. Perioperative management of a patient with recently placed drug-eluting stents requiring urgent spinal surgery. *J Gen Intern Med* 2012;27:1080-3.
- Singla S, Sachdeva R, Uretsky BF. The risk of adverse cardiac and bleeding events following noncardiac surgery relative to antiplatelet therapy in patients with prior percutaneous coronary intervention. *J Am Coll Cardiol* 2012;60:2005-16.
- Voeltz MD, Manoukian SV. Cangrelor in patients undergoing cardiac surgery: The BRIDGE study. *Expert Rev Cardiovasc Ther* 2013;11:811-6.
- Waite LH, Phan YL, Spinler SA. Cangrelor: A novel intravenous antiplatelet agent with a questionable future. *Pharmacotherapy* 2014;34:1061-76.
- Wang T, Wang H, Liu S, An HD, Liu H, Ding WY. Anterior cervical discectomy and fusion versus anterior cervical corpectomy and fusion in multilevel cervical spondylotic myelopathy: A meta-analysis. *Medicine (Baltimore)* 2016;95:e5437.

**How to cite this article:** Peeters SM, Nagasawa D, Gaonkar B, Niu T, Tucker A, Attiah M, *et al.* Perioperative dual antiplatelet therapy for patients undergoing spine surgery soon after drug eluting stent placement. *Surg Neurol Int* 2021;12:302.