



Contents lists available at ScienceDirect

## American Journal of Ophthalmology Case Reports

journal homepage: <http://www.ajocasereports.com/>

## Case report

## Shingles as the underlying cause of orbital myositis in an adolescent: A case report



Christopher D. Conrady\*, Richard M. Feist Jr., Alison Crum

Department of Ophthalmology, University of Utah, Salt Lake City, UT 84112, USA

## ARTICLE INFO

## Article history:

Received 6 August 2016

Received in revised form

9 December 2016

Accepted 28 December 2016

Available online 30 December 2016

## Keywords:

Varicella zoster

Orbital myositis

Pediatric

## ABSTRACT

**Purpose:** Orbital myositis is characterized by pain with eye movements, gaze restriction, diplopia, and enlargement of extraocular muscles on imaging. Varicella zoster virus (VZV) is an extremely rare cause of the disease in the elderly and has never been reported in a patient younger than forty-five years old such as the adolescent described herein. We present this case to raise awareness of an entity that will likely become more prevalent due to current vaccine strategies.

**Observation:** We present the case of a 13-year-old girl with VZV-associated orbital myositis and meningitis that had a quick and complete recovery following IV acyclovir and oral steroids.

**Conclusions and importance:** In conclusion, orbital myositis is an extremely rare complication of facial VZV infections. Our case highlights the importance of prompt detection and treatment in the pediatric population.

Published by Elsevier Inc. This is an open access article under the CC BY-NC-ND license (<http://creativecommons.org/licenses/by-nc-nd/4.0/>).

## 1. Introduction

Varicella zoster virus (VZV) is a  $\alpha$ -Herpesviridae family member that causes a disease entity known as chickenpox during primary infections and then, like other herpes viruses, establishes latency within host neural ganglia.<sup>1</sup> Orbital involvement outside the globe such as orbital myositis is an extremely rare complication of zoster in adults. There have been no described cases of patients under forty-five years old and only a total of thirteen case reports in the literature with a recent retrospective case series examining several of these patients.<sup>2–11</sup> Furthermore, zoster is felt to be a disease predominately of the aging population. In the case described herein, we describe the first adolescent patient with orbital myositis secondary to VZV.

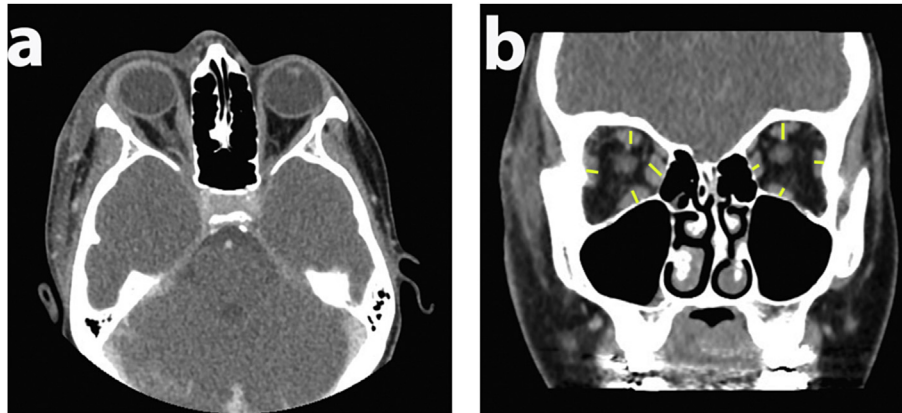
## 2. Case report

A previously healthy 13-year-old girl with up-to-date vaccinations (including Varivax at age 1 after developing chickenpox at 7 months of age) developed an upper respiratory tract infection 10 days prior to initial presentation. She was feeling well for several

days after resolution of the upper respiratory infection until she began to develop severe right-sided headaches causing her to miss school. Over the next few days she became lethargic and subsequently developed a rash overlying the right side of her face. She initially sought care at an urgent care clinic and was given a diagnosis of acne before being discharged home. However, over the next twenty-four hours the rash erupted into vesicles, prompting a second visit to an urgent care clinic, at which time she was started on 800 mg of acyclovir five times per day for presumed zoster infection. Despite multiple doses of acyclovir, she awoke the next morning with swelling of the right upper and lower eyelids, and complained of pain with eye movements, most severe in upgaze and abduction of the right eye. The rash continued to progress and involve both the right V1 and V2 distribution of the trigeminal nerve. The patient was eventually taken to the emergency department by her parents. Due to persistent pain with eye movements and severe lethargy, underwent computed tomography (CT) imaging of the orbits. Radiology staff reported right periorbital swelling and asymmetric enlargement of the right inferior and medial rectus muscles. They noted a mild amount of tendinous involvement compared to left (Fig. 1). No abscess was identified; however the medial and inferior rectus muscles were found to be nearly twice the size of those in the fellow eye. Due to these findings, the ophthalmology service was then consulted for further evaluation of pain with eye movements without radiographic signs of orbital cellulitis.

\* Corresponding author.

E-mail addresses: [Christopher.conrady@hsc.utah.edu](mailto:Christopher.conrady@hsc.utah.edu) (C.D. Conrady), [richard.feist@hsc.utah.edu](mailto:richard.feist@hsc.utah.edu) (R.M. Feist), [alison.crum@hsc.utah.edu](mailto:alison.crum@hsc.utah.edu) (A. Crum).



**Fig. 1.** Medial and inferior rectus enlargement during orbital myositis. Computed tomography with and without intravenous contrast was performed upon the patient's initial presentation to the emergency department. (a) Axial image. (b) Coronal image; yellow lines are the width of the respective rectus muscles at their thickest points. (For interpretation of the references to colour in this figure legend, the reader is referred to the web version of this article.)

On initial examination, the patient had a vesicular rash of the V1 and V2 dermatomes and a positive Hutchinson sign, consistent with shingles. Visual acuity was 20/20 and 20/30 of the right and left eye respectively. She had no relative afferent pupillary defect, and intraocular pressure was noted to be 23 mmHg and 15 mmHg in the right and left eye respectively. She had no red desaturation, and no apparent proptosis on bedside exam. While extraocular movements were full in all directions at time of presentation, right gaze elicited severe periorbital pain. Anterior segment and dilated fundus examination was unremarkable with the exception of significant temporal conjunctival chemosis in the right eye.

Due to the unusual presentation, including lethargy and a workup including normal thyroid labs, it was felt that the rectus involvement was due to orbital myositis secondary to VZV (Table 1). The ophthalmology service also requested the ER do a lumbar puncture to work up lethargy and photophobia. PCR of fluid obtained from lumbar puncture confirmed the presence of VZV DNA within the CSF space, and a lymphocytic pleocytosis consistent with a diagnosis of meningitis (Table 2). The patient was admitted for treatment with intravenous acyclovir (500mg/m<sup>2</sup>/dose every 8 hours). After two days of intravenous acyclovir, twenty milligrams of oral prednisone was added to the treatment regimen to expedite healing based off prior reports of orbital myositis in adults.<sup>2</sup> Due to acute renal failure due to the IV acyclovir, the patient was transitioned to oral (1 g three times daily) valacyclovir on hospital day three. After aggressive treatment with IV fluids, the renal dysfunction fully resolved.

Magnetic resonance imaging (MRI) seven days into disease, and five days into therapy, showed resolution of asymmetric rectus enlargement (Fig. 2) and the patient was discharged home in good

**Table 2**

Cerebrospinal fluid lab results.

	Patient's values	Normal values
HSV PCR	Not Detected	
EBV PCR	Not Detected	
VZV PCR	<b>Detected</b>	
VZV IgM	0.36	<0.90
WBC	94	0–5
Glucose	58	40 to70
Protein	54	12 to 60

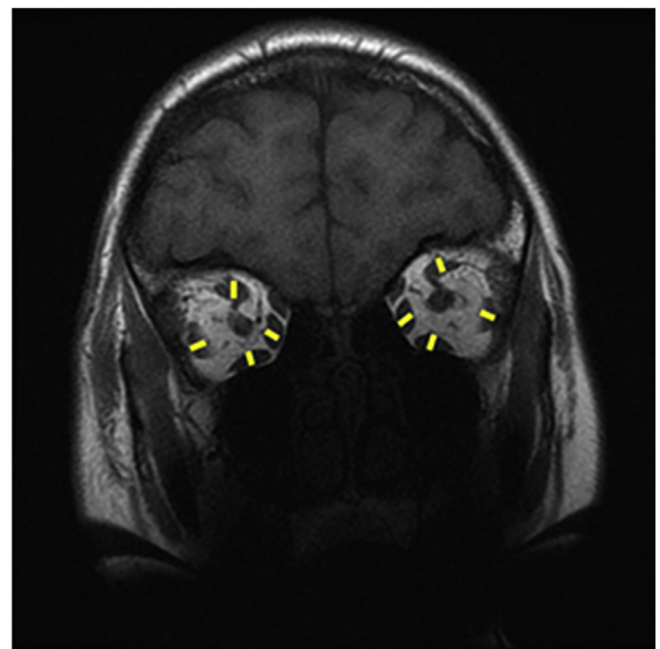
Abbreviations: EBV, Epstein-Barr virus; HSV, herpes simplex virus; PCR, polymerase chain reaction; VZV, varicella zoster virus; WBC, white blood cell count.

**Table 1**

Serum lab results upon arrival to emergency department.

	Patient's values	Normal values
TSH	0.87	0.50–4.40
T4	0.94	0.59–2.03
ESR	10	0–20
CRP	0.2	<0.8
WBC	4.3	4.5–13.5
Hgb	14.2	12.0–16.0
Plts	170	150–400

Abbreviations: CRP, C-reactive protein; T4, free thyroxine; ESR, erythrocyte sedimentation rate; Hgb, hemoglobin; Plts, platelets; TSH, thyroid stimulating hormone; WBC, white blood cell count.



**Fig. 2.** Resolution of rectus enlargement. Magnetic resonance imaging of the brain and orbit of the patient seven days into disease process. Coronal image; yellow lines are the width of the respective rectus muscles at their thickest points. (For interpretation of the references to colour in this figure legend, the reader is referred to the web version of this article.)

condition to complete a ten-day course of antiviral therapy, and a full seven days of prednisone. Five days after discharge the patient's rash and pain with extraocular movements had both completely resolved.

### 3. Discussion

To the best of our knowledge, the patient presented here is unique as an adolescent with orbital myositis secondary to VZV has never been reported. Significant time and resources have been dedicated to vaccine development to help stymie the health and economic repercussions of morbidity associated with herpes zoster, beginning with the introduction of Varivax (Merck & Co) in 1995 for children and Zostavax (Merck & Co) for those older than 60 years old in 2006.<sup>1</sup> Retrospective studies have shown a decrease in average age of incidence of HZO hypothesized to be due to current vaccine strategies.<sup>1</sup> As such, clinicians should keep a high index of suspicion for zoster-related complications in younger patients, even those in their adolescence.

Enlargement of the extraocular muscles is known to occur in thyroid eye disease, orbital myositis, neoplasms of the muscles, systemic lupus erythematosus (SLE), sarcoidosis, idiopathic orbital inflammation, or vascular malformations. The lack of a butterfly rash and no obvious mass within or consuming the muscle bellies suggested etiologies other than a neoplastic process, sarcoidosis, or SLE. This reduced the differential diagnosis to thyroid orbitopathy, idiopathic orbital inflammation, or orbital myositis. Serum thyroid function tests were normal. As such, orbital myositis was the working diagnosis and was clinically confirmed with a rapid resolution with antiviral and steroid therapy.

In zoster-related orbital myositis, the literature is unclear as to whether steroids should be considered in treatment to aide in clinical recovery. Our patient's presentation was complicated by VZV meningitis. Due to this fact, we refrained from starting corticosteroids at original presentation; steroids cause systemic immunosuppression and have a controversial role in the management of meningo-encephalitis for  $\alpha$ -herpesviruses. The use of steroids is currently under investigation as part of the German trial of acyclovir and corticosteroids in Herpes-simplex-encephalitis. While steroids have aided in recovery of previous VZV-associated myositis, no randomized control trials have been pursued to clarify the exact role of steroids.<sup>5</sup> Consequently, the addition of corticosteroids to the treatment regimen should be pursued with caution.

In the previously reported cases of orbital myositis from VZV, several cases of orbital myositis preceded vesicular eruption, while others,<sup>3,5</sup> as in our patient's case, followed the development of the rash.<sup>7,9</sup> Interestingly, several cases were not isolated to HZO and myositis but included dacryoadenitis, orbital apex syndrome, and trigeminal nerve involvement.<sup>3,4,7,8</sup> Our patient's presentation was clouded by ongoing meningitis and the need to initiate early and aggressive treatment to minimize the well known long term complications of herpes infections of the central nervous system. Thus, it seems that the sole finding of orbital myositis from VZV should raise clinical suspicion for other ongoing problems related to viral pathogenesis such as lethal complications like viral meningitis.

In conclusion, this case report might represent a shift towards significantly younger patients presenting with zoster-related complications from ongoing vaccination strategies.<sup>1</sup> Unfortunately

in regards to orbital myositis, the typical VZV rash is not always a precursor to what is to come but may actually lag behind more significant pathology. Consequently, the differential diagnosis of orbital myositis must contain VZV in all age groups. Also, photophobia and lethargy, not typical signs of myositis, should be evaluated separately to confirm systemic/CNS involvement.

### 4. Patient consent

Written informed consent was obtained from the patient for publication of this case report and any accompanying images. A copy of the written consent is available for review by the Editor of this journal. The study in its entirety is HIPAA compliant.

### Funding

This work was supported in part by an unrestricted grant from the Research to Prevent Blindness to the University of Utah Department of Ophthalmology and the ARCS Foundation.

### Authorship

All authors attest that they meet the current ICMJE criteria for Authorship.

### Conflict of interest

The following authors have no financial disclosures: CDC, RMF, and AC.

### Acknowledgements

None.

### References

- Chan AY, Conrady CD, Ding K, Dvorak JD, Stone DU. Factors associated with age of onset of herpes zoster ophthalmicus. *Cornea*. May 2015;34:535–540.
- Kawasaki A, Borruat FX. An unusual presentation of herpes zoster ophthalmicus: orbital myositis preceding vesicular eruption. *Am J Ophthalmol*. Sep 2003;136:574–575.
- Patheja RS, Weaver T, Morris S. Unique case of orbital myositis and dacryoadenitis preceding the vesicular rash of herpes zoster ophthalmicus. *Clin Exp Ophthalmol*. Mar 2016;44:138–140.
- Paraskevas GP, Anagnostou E, Vassilopoulou S, Spengos K. Painful ophthalmoplegia with simultaneous orbital myositis, optic and oculomotor nerve inflammation and trigeminal nucleus involvement in a patient with herpes zoster ophthalmicus. *BMJ case Rep*. 2012;2012.
- Badilla J, Dolman PJ. Orbital myositis involving the oblique muscles associated with herpes zoster ophthalmicus. *Ophthalmic plastic Reconstr Surg*. Sep-Oct 2007;23:411–413.
- Volpe NJ, Shore JW. Orbital myositis associated with herpes zoster. *Arch Ophthalmol*. Apr 1991;109:471–472.
- Lee CY, Tsai HC, Lee SS, Chen YS. Orbital apex syndrome: an unusual complication of herpes zoster ophthalmicus. *BMC Infect Dis*. 2015;15:33.
- Merino-Iglesias A, Montero JA, Calabuig-Goena M, Giraldo-Agudelo LF. Orbital apex syndrome secondary to herpes zoster virus infection. *BMJ case Rep*. 2014;2014.
- Kim JH, Lee SJ, Kim M. External ophthalmoplegia with orbital myositis in an adult patient after chickenpox infection. *BMJ case Rep*. 2014;2014.
- Krasnianski M, Sievert M, Bau V, Zierz S. External ophthalmoplegia due to ocular myositis in a patient with ophthalmic herpes zoster. *Neuromuscular disorders*. *NMD*. Jul 2004;14:438–441.
- Temnogorod J, Pointdujour-Lim R, Mancini R, Chang SH, Allen RC, Shinder R. Acute orbital syndrome in herpes zoster ophthalmicus: clinical features of 7 cases. *Ophthalmic plastic Reconstr Surg*. Apr 4 2016.