

Received: 2014.01.16
Accepted: 2014.05.28
Published: 2014.09.08

ISSN 1941-5923
© Am J Case Rep, 2014; 15: 382-387
DOI: 10.12659/AJCR.890380

Isolated Hepatic Artery Thrombosis Leading to Multiple Liver Infarcts in a Non-transplant Patient

Authors' Contribution:
Study Design A
Data Collection B
Statistical Analysis C
Data Interpretation D
Manuscript Preparation E
Literature Search F
Funds Collection G

DEF 1 **Tarek Almouradi**
E 2 **Paul Co**
E 1 **William Riles**
E 1 **Bashar Attar**

1 Division of Gastroenterology and Hepatology, Department of Medicine, John H. Stroger Hospital of Cook County, Chicago, IL, U.S.A.
2 Department of Medicine, John H. Stroger Hospital of Cook County, Chicago, IL, U.S.A.

Corresponding Author: Tarek Almouradi, e-mail: tarekmuradi@hotmail.com
Conflict of interest: None declared

Patient: Female, 62
Final Diagnosis: Hepatic artery thrombosis
Symptoms: Abdominal pain • Nausea • Vomiting
Medication: —
Clinical Procedure: —
Specialty: Surgery

Objective: Rare disease
Background: Isolated hepatic artery thrombosis is an extremely rare condition with only a few cases reported in the literature.
Case Report: A 62-year-old woman presented with a 5-day history of right upper quadrant abdominal pain associated with nausea and vomiting. Physical examination revealed right upper quadrant tenderness. Her initial laboratory work was significant for elevated aspartate aminotransferase and alanine aminotransferase levels (745 and 431 U/L, respectively). A computed tomography of her abdomen showed a thrombus within the hepatic artery, with multiple hepatic infarcts but no evidence of portal vein thrombosis. Hypercoagulability workup was unremarkable; she did not have any evidence of atrial fibrillation on ECG or telemetry. She was treated with subcutaneous low molecular weight heparin. Over the course of her hospitalization, her AST and ALT levels peaked to 2065 and 1217 U/L respectively, and trended down thereafter.

Conclusions: We believe that our case is unique for 2 reasons: 1) Our patient did not undergo any procedure that may have precipitated hepatic artery thrombosis and 2) Despite the absence of concurrent portal vein thrombosis, she had biochemical and imaging findings of hepatic ischemia.

MeSH keywords: Ischemic Hepatitis • Liver Infarct • Hepatic Artery Thrombosis

Full-text PDF: <http://www.amjcaserep.com/abstract/index/idArt/890380>



1748



4



2



20



Background

Hepatic artery thrombosis is a common complication of liver transplantation [1,2]; it is a rare complication of various intra-abdominal procedures [3–9], but spontaneous hepatic artery thrombosis is an extremely rare disorder, with only a few cases reported in the literature.

We report a case of spontaneous hepatic artery thrombosis leading to multiple hepatic infarcts in an elderly patient.

Case Report

A 62-year-old African-American woman with a medical history of hypertension, diabetes, chronic kidney disease, and treated stage 3 breast cancer, presented with a 5-day history of constant right upper quadrant abdominal pain, nausea and non-bloody vomiting. Her pain had no relation to food intake, nor was it associated with fever, urinary symptoms, or alterations

in bowel habits. She endorsed no history of prior episodes or recent trauma.

Her physical examination revealed a soft abdomen with normoactive bowel sounds, and right upper quadrant tenderness with no evidence of rebound or guarding. There was no hepatosplenomegaly or ascites. The rest of her exam results were unremarkable.

Her initial laboratory work was significant for a hepatocellular process as evidenced by her elevated AST and ALT levels (745 and 431 units per liter, respectively). Her initial liver function tests along with baseline and peak levels are presented in Table 1.

Her CBC was normal, but her BMP showed baseline creatinine of 1.2 mg/dL, and no evidence of electrolyte abnormalities (Tables 2 and 3).

Her coagulation profile on presentation showed slight prolongation in PT to 15.7 seconds, INR of 1.31, and normal PTT (Table 4).

Table 1. Liver function tests.

Test	Two days prior	At presentation	Peak value	Reference range
Albumin	4.00	3.8	NA	3.8–5.2
Total bilirubin	0.6	0.9	1.3	0.2–1.2
AST	22	745	2065	0–40
ALT	25	431	1217	5–35
ALP	135	174	486	50–120
GGT	159	181	256	3–60
LDH	181	300	2283	85–210

Table 2. Basic metabolic panel.

Basic metabolic panel	
Sodium	137
Potassium	3.3
Chloride	101
Bicarbonate	26
Blood urea nitrogen	25
Creatinin	1.2
Calcium	8
Magnesium	1.7

Table 3. Complete blood count.

Complete blood count	
WBC	9.8
Hemoglobin	11.8
MCV	75.7
Platelets count	193

Table 4. Coagulation panel.

Coagulation panel	
PT	15.7
PTT	33.5
INR	1.3

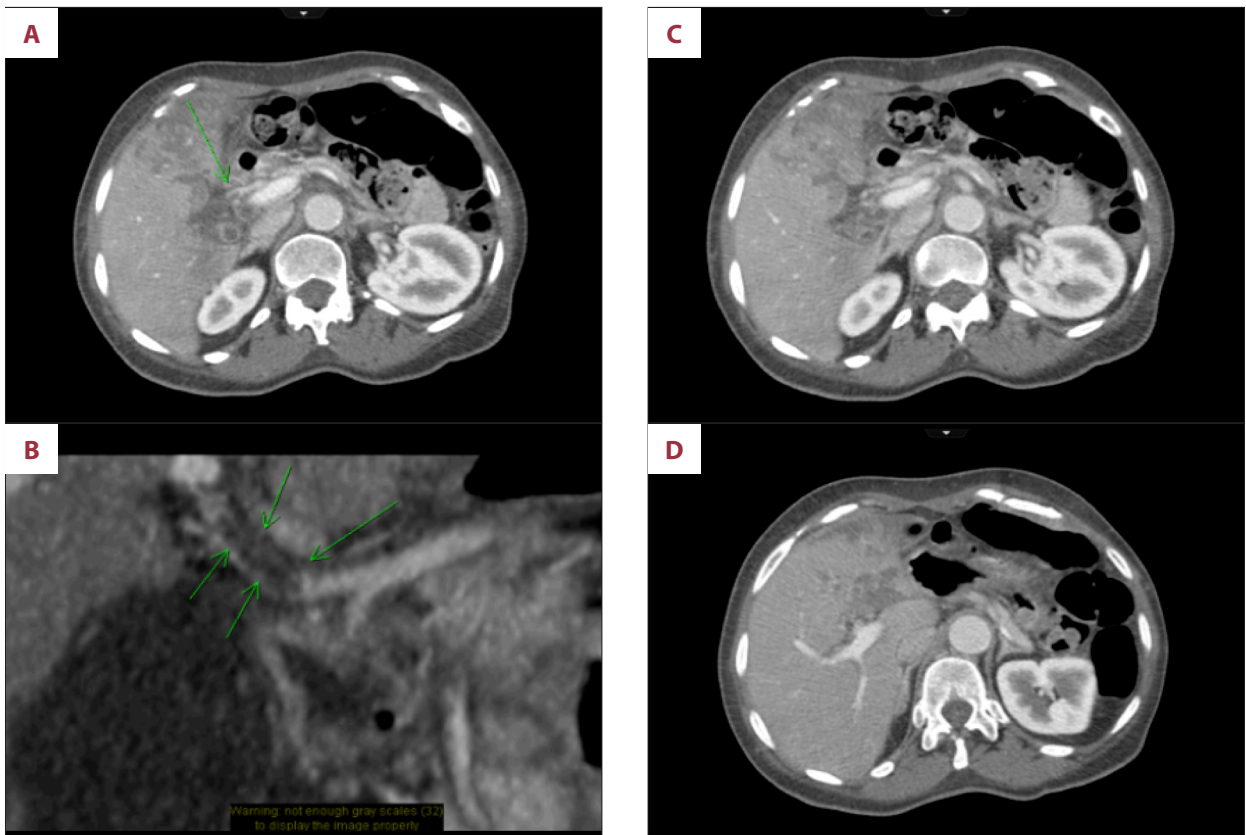


Figure 1. Computed tomography showing hepatic artery thrombosis with multiple peripheral hepatic infarcts. (A) Thrombus noted in proper hepatic artery as pointed by green arrow. (B) Magnified image of clot noted within hepatic artery. (C) Multiple peripheral low-attenuating irregular areas compatible with hepatic infarcts. (D) Evidence of peripheral infarcts in the liver, mostly over left hepatic lobe.

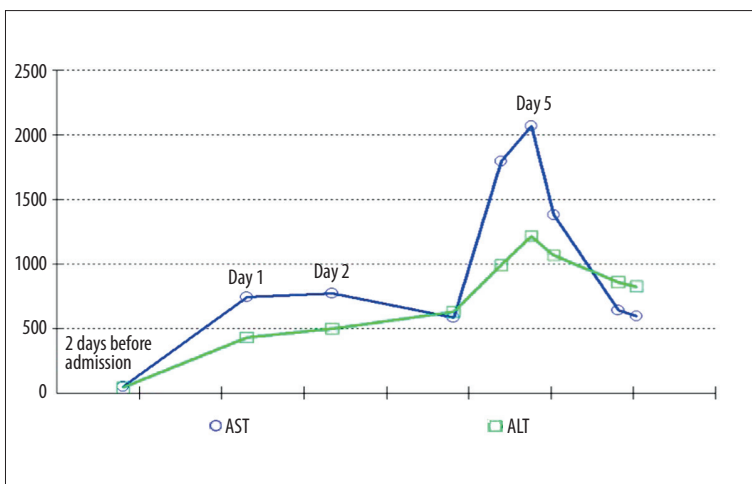


Figure 2. Trend of transaminases during hospital course.

An EKG was done and showed sinus tachycardia and left ventricular hypertrophy. She had no history of atrial fibrillation.

Because of her laboratory findings and persistent abdominal pain, a CT scan of her abdomen with contrast was done. This revealed a thrombus within the hepatic artery, with multiple

low attenuating areas present within the liver, which were most compatible with hepatic infarcts. She had no evidence of portal vein thrombosis (Figure 1).

She was started on anticoagulation with subcutaneous enoxaparin.

During her hospital stay, her AST and ALT levels peaked at 2065 and 1217 U/L, respectively, but started trending down thereafter (Figure 2). A workup for underlying chronic liver disease was negative (ANA, anti-smooth muscle antibodies, anti-mitochondrial antibodies, viral hepatitis panel, iron panel, and ceruloplasmin levels).

She also underwent a transthoracic and transesophageal echocardiogram, which did not show a thrombus or vegetation as a possible embolic source.

At this point, she was thought to have spontaneous hepatic artery thrombosis with resultant hepatic infarcts. A hypercoagulability workup was initiated and showed slightly low levels of protein C, protein S, and anti-thrombin III levels (which were difficult to interpret in the setting of an acute thrombus). A D-dimer was elevated at 7.87 fibrinogen equivalent units (FEU), while her fibrinogen levels were also elevated to 840 mg/dL.

Her clinical course, however, continued to deteriorate and on the fifth day of hospitalization, she became lethargic and developed severe inflammatory response syndrome (SIRS). Her lab results showed increasing leukocytosis, acute kidney injury, and a new right lower lobe opacity on her chest imaging. She was transferred to the intensive care unit where she was started on broad-spectrum antibiotics for possible hospital-acquired pneumonia leading to severe sepsis.

Shortly thereafter, she suffered a sudden cardiac arrest. Cardiopulmonary resuscitation was not performed as she had already signed DNR/DNI forms prior to her admission. Her family denied permission for autopsy.

Discussion

Hepatic infarcts following hepatic artery compromise are very rare because of the dual blood supply from the portal vein and the hepatic artery, along with the extensive hepatic arterial collateral system. However, localized hepatic infarcts following thrombosis or compression of an intrahepatic branch of the hepatic artery by various etiologies have been described, and typically lead to a transient increase in transaminases (AST, ALT), without compromising the hepatic synthetic function [10].

The vast majority of cases of hepatic artery thrombosis are reported as complications of orthotopic liver transplantation, with incidence rates of 3% to 9% [2]. It is a leading cause of graft loss and mortality during the immediate postoperative period [1].

Multiple risk factors have been identified and include technical difficulties during surgery, older donor age, lack of ABO

compatibility, cigarette smoking, hypercoagulable states, preservation damages, regrafts, and a donor positive for cytomegalovirus in a CMV-negative recipient [2,11–14].

The clinical presentation varies depending on the timing of the thrombosis. Early hepatic artery thrombosis (within 4 weeks) may present with acute graft failure, sepsis/liver abscess, and biliary leak/stricture [15].

On the other hand, late hepatic artery thrombosis (after 4 weeks) can be clinically silent, with altered liver function tests. It can also present with biliary complications such as cholangitis with hepatic abscesses, bile leak, biliary strictures, and, eventually, progressive graft failure [16].

Besides liver transplantation, hepatic artery thrombosis has been reported to complicate various other procedures.

Jia et al. reported a case of right hepatic artery thrombosis following debridement and T-tube drainage of the common bile duct for severe pancreatitis and acute suppurative obstructive cholangitis in a patient with polycythemia vera [3]. The patient developed an unexplained rise of ALT and AST levels more than 30 days postoperatively. CT angiography confirmed the diagnosis of right hepatic artery thrombosis.

In 2009, Herrera Melero et al. reported a case of hepatic artery thrombosis and portal vein thrombosis complicating the postoperative course of a patient with Klatskin's tumor, who underwent left hepatectomy, cholecystectomy, and roux en y cholangiojejunostomy [4].

In their case report published in 2004, Poggi et al. described the development of a massive hepatic infarction following an ultrasound-guided percutaneous radiofrequency thermal ablation of hepatocellular carcinoma. Color Doppler US revealed right portal vein thrombosis and right hepatic artery occlusion, confirmed by abdominal computed tomography [5].

Other procedures reported to lead to hepatic artery thrombosis include:

1. Placement of hepatic catheters/Port systems for intra-arterial chemotherapy of liver tumors [6–8].
2. Hepatic artery reconstruction following ablative surgery for hepatobiliary and pancreatic malignancies [9].

Our review of the literature revealed only 2 case reports of hepatic artery thrombosis in the absence of a recent abdominal intervention.

O'Connor et al. reported the first case of "spontaneous hepatic artery thrombosis with infarction of the liver" in 1976 [17].

Their patient presented with symptoms of congestive heart failure and bronchitis. His hospital stay was complicated by left lower extremity gangrene, requiring an above-the-knee amputation. Two weeks later, he developed fever and right upper quadrant pain; his laboratory work was remarkable for SGOT (serum glutamic oxaloacetic transaminase) of 3500 mU/ml, which peaked to 5100 U/ml, then slowly trended down to 250 U/ml 9 days later, when the patient suffered a myocardial infarction and died.

Autopsy showed thrombosis of the celiac trunk with extension to splenic, common hepatic, and right and left hepatic arteries.

In 2004, Francque et al. reported a case of left hepatic artery and portal vein thrombosis leading to hepatic infarction in a 73-year-old patient who suffered blunt abdominal trauma; his liver function tests were remarkable for massive elevations of AST and ALT (2518 U/L and 1334 U/L, respectively) with slight elevation in the levels of alkaline phosphatase, gamma glutamyltransferase, and bilirubin.

Doppler ultrasound disclosed a heterogeneous area in the left lobe and thrombosis of the left branch of the portal vein. No arterial signal

could be recorded in the left lobe. Computerized tomography scan showed a well-marginated, peripheral perfusion defect without visualization of a left arterial branch or a left portal branch. Angiography confirmed the above findings.

The levels of transaminases decreased slowly and eventually normalized 3 months later [18].

In the absence of a recent surgical intervention or trauma, a workup for an underlying hypercoagulable state is essential as this may determine the course of management. Although there are no guidelines in the management of isolated hepatic artery thrombosis, the duration of anticoagulation may be influenced based on the precipitating event. Two important factors that may have played a role in the development of spontaneous thrombosis in this patient are a history of advanced cancer and sepsis.

In the case of cancer, a hypercoagulable or prothrombotic state occurs due to the ability of tumor cells to activate the coagulation system. It has been estimated that hypercoagulation accounts for a significant percentage of mortality and morbidity in cancer patients. Prothrombotic factors in cancer include the ability of tumor cells to produce and secrete procoagulant/fibrinolytic substances and inflammatory cytokines, and the physical interaction between tumor cells and blood (monocytes, platelets, neutrophils) or vascular cells. Other mechanisms of thrombus promotion in malignancy include nonspecific factors

such as the generation of acute phase reactants and necrosis (e.g., inflammation), abnormal protein metabolism (e.g., paraproteinemia), and hemodynamic compromise (e.g., stasis). In addition, anticancer therapy (e.g., surgery/chemotherapy/hormone therapy) may significantly increase the risk of thromboembolic events by similar mechanisms, such as procoagulant release, endothelial damage, or stimulation of tissue factor production by host cells. However, not all of the mechanisms for the production of a hypercoagulable state of cancer are entirely understood [19].

On the other hand, sepsis is often associated with hemostatic changes ranging from subclinical activation of blood coagulation (hypercoagulability), which may contribute to localized venous thromboembolism, to acute disseminated intravascular coagulation (DIC), characterized by widespread microvascular thrombosis and subsequent consumption of platelets and coagulation proteins, eventually causing bleeding manifestations. The key event underlying this life-threatening complication is the overwhelming inflammatory host response to the infectious agent, leading to the overexpression of inflammatory mediators. The latter, along with the micro-organism and its derivatives, are now believed to drive the major changes responsible for massive thrombin formation and fibrin deposition, namely: 1) the aberrant expression of the TF by different cells (especially monocytes-macrophages), 2) the impairment of physiological anticoagulant pathways, orchestrated mainly by dysfunctional endothelial cells (ECs), and 3) the suppression of fibrinolysis due to overproduction of plasminogen activator inhibitor-1 (PAI-1) by ECs and likely also to thrombin-mediated activation of thrombin-activatable fibrinolysis inhibitor (TAFI) [20].

Conclusions

Hepatic artery thrombosis in the absence of a recent intra-abdominal surgical intervention is rare. There are very few cases of spontaneous hepatic artery thrombosis reported in the medical literature.

We believe that our case is unique for 2 reasons:

1. Our patient did not undergo any procedure that may have precipitated hepatic artery thrombosis.
2. Despite the absence of concurrent portal vein thrombosis, she had biochemical and imaging findings of hepatic ischemia.

We believe the precipitating factor of her presentation was malignancy-related hypercoagulability. However, it is felt that her frustrating outcome was not directly related to hepatic artery thrombosis, but rather to severe sepsis in an unfortunate patient with multiple co-morbidities.

References:

1. Wozney P, Zajko AB, Bron KM et al: Vascular complications after liver transplantation: A 5-year experience. *Am J Roentgenol*, 1986; 147: 657
2. Pareja E, Cortes M, Navarro R et al: Vascular Complications After Orthotopic Liver Transplantation: Hepatic Artery Thrombosis. *Transplant Proc*, 2010; 42(8): 2970–72
3. Jia C, Chen Y, Hu Z, Lu X: Right hepatic artery thrombosis in an essential polycythemia vera patient following pancreato-biliary surgery for severe pancreatitis. *J Thromb Thrombolysis*, 2012; 34(1): 135–38
4. Herrera Melero MC, Porras López FM, Egea Guerrero JJ: Portal and hepatic artery thrombosis after surgery of bile duct junction tumor. *Med Intensiva*, 2009; 33(8): 411–12
5. Poggi G, Teragni C, Gazzaruso C, Bernado G: Massive hepatic infarction complicating ultrasound-guided percutaneous radiofrequency thermal ablation. *Liver Int*, 2004; 24(6): 704–5
6. Benhaim L, Goéré D, Deschamps F et al: Placement of an arterial hepatic catheter after a major hepatectomy for colorectal liver metastases: Is this safe? *Eur J Surg Oncol*, 2013; 39(6): 640–47
7. Ricke J, Hildebrandt B, Miersch A et al: Hepatic arterial port systems for treatment of liver metastases: factors affecting patency and adverse events. *J Vasc Interv Radiol*, 2004; 15(8): 825–33
8. Venturini M, Angeli E, Salvioni M et al: Complications after percutaneous transaxillary implantation of a catheter for intraarterial chemotherapy of liver tumors: clinical relevance and management in 204 patients. *Am J Roentgenol*, 2004; 182(6): 1417–26
9. Sakuraba M, Miyamoto S, Nagamatsu S et al: Hepatic artery reconstruction following ablative surgery for hepatobiliary and pancreatic malignancies. *Eur J Surg Oncol*, 2012; 38(7): 580–85
10. Crawford JM: Vascular disorders of the liver. *Clin Liver Dis*, 2010; 14(4): 635–50
11. Proposito D, Loinaz Segurolo C, Garcia Garcia I et al: Assessment of risk factors in the incidence of hepatic artery thrombosis in a consecutive series of 687 liver transplantations. *Ann Ital Chir*, 2001; 72: 187–205
12. Oh CK, Pelletier SJ, Sawyer RG et al: Uni- and multi-variate analysis of risk factors for early and late hepatic artery thrombosis after liver transplantation. *Transplantation*, 2001; 71(6): 767–72
13. Silva MA, Jambulingam PS, Gunson BK et al: Hepatic artery thrombosis following orthotopic liver transplantation: 10-year experience from a single centre in the United Kingdom. *Liver Transpl*, 2006; 12(1): 146–51
14. Pastacaldi S, Teixeira R, Montalto P et al: Hepatic Artery Thrombosis After Orthotopic Liver Transplantation: A Review of Nonsurgical Causes. *Liver Transpl*, 2001; 7(2): 75–81
15. Stange BJ, Glanemann M, Nuessler NC et al: Hepatic artery thrombosis after adult liver transplantation. *Liver Transpl*, 2003; 9(6): 612–20
16. Bhattacharjya S, Gunson BK, Mirza DF et al: Delayed hepatic artery thrombosis in adult orthotopic liver transplantation—a 12-year experience. *Transplantation*, 2001; 71(11): 1592–96
17. O'Connor PJ, Buhac I, Balint JA: Spontaneous hepatic artery thrombosis with infarction of the liver. *Gastroenterology*, 1976; 70(4): 599–601
18. Francque S, Condat B, Asselah T et al: Multifactorial aetiology of hepatic infarction: a case report with literature review. *Eur J Gastroenterol Hepatol*, 2004; 16(4): 411–15
19. Caine GJ, Stonelake PS, Lip GY, Kehoe ST: The hypercoagulable state of malignancy: pathogenesis and current debate. *Neoplasia*, 2002; 4(6): 465–473
20. Semeraro N, Ammollo CT, Semeraro F, Colucci M: Sepsis, thrombosis, and organ dysfunction. *Thromb Res*, 2012; 129(3): 290–95