

A Review and Case Study of Genital and Extragenital Human Papillomavirus Type 6 and 11 Infections in Men Who Have Sex with Men Accompanied by Human Immunodeficiency Virus Infection

Pati Aji Achdiat¹, Rita Septharina¹, Rasmia Rowawi¹, Hartati Purbo Dharmadji¹,
Diah Puspitosari¹, Hermin Aminah Usman², Retno Hesty Maharani¹

¹Department of Dermatology and Venereology, Faculty of Medicine, Universitas Padjadjaran–Dr. Hasan Sadikin General Hospital, Bandung, West Java, Indonesia;

²Department of Anatomy Pathology, Faculty of Medicine, Universitas Padjadjaran–Dr. Hasan Sadikin General Hospital, Bandung, West Java, Indonesia

Correspondence: Pati Aji Achdiat, Department of Dermatology and Venereology, Faculty of Medicine, Universitas Padjadjaran–Dr. Hasan Sadikin General Hospital, Jl. Pasteur 38, Bandung, West Java, 40161, Indonesia, Tel +6281322750101, Email pati.aji.achdiat@unpad.ac.id

Abstract: Extragenital warts caused by HPV types 6 and 11 are rarely reported. However, major risk factors for anogenital warts (AGW) include men who have sex with men (MSM) and Human Immunodeficiency Virus (HIV) infection. The incidence of extragenital warts among these populations has not been reported. This study presented a case report of a 33-year-old male with high-risk sexual behavior who showed symptoms of flesh-colored and hyperpigmentation papules. Furthermore, verrucous surfaces were observed at genital and extragenital. The patient had a history of using the same razor for pubic and armpit hair, bathing with a mesh scrub, and scratching the anal area. The histopathological result showed koilocytes, while polymerase chain reaction (PCR) examination for both genital and extragenital lesions confirmed HPV type 6 and 11. This represented the first reported case describing the incidence of extragenital and AGW caused by HPV types 6 and 11. The transmission of extragenital warts was facilitated through fomites autoinoculation, particularly in the immunocompromised condition induced by HIV, which was common among MSM. Extragenital warty-like lesions were considered as warts caused by HPV type 6/11, in HIV-infected persons, specifically MSM.

Keywords: anogenital warts, extragenital warts, human papillomavirus type 6, human papillomavirus type 11, human immunodeficiency virus

Introduction

Human Papillomavirus (HPV), specifically strains 6 and 11, is the etiology of anogenital warts (AGW), which are infections contracted mostly through sexual contact. This disease typically manifests as either benign proliferative lesions or fibroepithelioma on genital skin.^{1,2} AGW consists of 4 morphological types, namely condyloma acuminata, papular, keratotic, and flat-topped.³ Among these types, condyloma acuminata is the most prevalent, characterized by lesions in the form of a papule with a variegated surface resembling cauliflower. This lesion can develop into a more severe clinical form of HPV infection, known as Buschke-Lowenstein tumor (BLT), also termed giant condyloma acuminatum (GCA). BLT manifests as a slowly growing, locally destructive tumor that does not metastasize.⁴

AGW is one of the most prevalent sexually transmitted infections worldwide. It is experienced by two-thirds of the individuals who have sexual contact with HPV-infection patients showing lesions.⁵ Anogenital HPV infection is common with a global incidence of all genotypes reaching 11.7%. The incidence of AGW yearly is 160–289 for every 100,000 persons worldwide.^{1,2} Approximately 30 million of the 630 million new HPV infections occurring annually result in AGW.⁶ Based on study data conducted in 12 teaching hospitals in Indonesia in 2007–2011, this disease was ranked third among STDs.⁷

HPV infection is generally transmitted through sexual contact, which can affect genital and anus.⁸ Cases of condyloma acuminata type extragenital warts induced by HPV types 6 and 11 are limited, and the exact cause remains unknown.⁹ Transmission of the virus from genital to extragenital was suspected to occur due to contaminated objects. Hsu et al¹⁰ reported a case of condyloma acuminata type extragenital warts affecting the axillary region in a 30-year-old male patient, caused by HPV types 6 and 11. The risk factors for the development of AGW include men who have sex with males (MSM) and Human Immunodeficiency Virus (HIV) infection. The patient with HIV is at an elevated risk of HPV infection, attributed to immune insufficiency. This compromised immune state correlates with an increased frequency of AGW, often leading to more extensive, numerous lesions that are less responsive to therapy and can develop into GCA.³ HIV infection is a major factor in the development of AGW, but the role in extragenital warts caused by HPV type 6 and 11 remains undescribed. The purpose of this case report is to describe the occurrence of condyloma acuminata extragenital warts caused by HPV type 6 and 11 in MSM, HIV-infected patients.

Cases

A 33-year-old Sundanese Muslim man with a high school diploma and unmarried was subjected to treatment at Venereology Clinic, Dr. Hasan Sadikin Hospital, Bandung. The complaints presented included skin-colored nodules and blackness in armpits, right arm, pubis, buttocks, thighs, genitals, and perianal lumps, without experiencing pain and itching.

Approximately 3 years before seeking treatment at the clinic, the symptoms include 3 skin-colored papules located on the perianal region, with an uneven surface and size similar to corn kernels. These initial lesions did not cause pain or itching.

Over 2 years before enrolling at the clinic, the perianal lesions were increasing in number, size, and started merging, forming a mass comparable in size to a ping pong ball. Additionally, the patient reported an 8 kg weight loss during this period. Consultation with a dermatologist in Pekanbaru resulted in a diagnosis of genital warts and HIV infection was conducted. The patient was prescribed ARV duviral[®] and nevirapine tablets to be taken once daily and subsequently referred to a surgeon for perianal wart surgery.

A year before seeking treatment at the clinic, the reappearance of skin-colored and black papules in the perianal area was experienced, with subsequent spread to the penis, pubis, both thighs, armpits, and right arm without itching, pain, odor, or bleeding. Over the course of a month before presenting to the clinic, the skin-colored and blackish papules on the right arm, pubis, buttocks, both thighs, genitals, and lumps on the edge of the anus grew larger. The patient received medical attention from a dermatologist at Nurhayati Garut Hospital where diagnosis of genital warts was conducted and was referred to Venereology Clinic, Dr. Hasan Sadikin Hospital.

The unmarried patient disclosed a history of initial sexual activity (coitarche) at the age of 16 with a male partner, engaging in both anal and oral sex without using a condom. A history of multiple partners, including boyfriends and male casual friends, engaging in both anal and oral sex without condom usage, assuming roles of both the “top” and “bottom”, was acknowledged. A report of using the same razor for pubic and underarm hair was presented. Additionally, the habit of bathing with a mesh scrub and unconscious scratching of skin disorders in the anus, often neglecting to wash the hands immediately was admitted. The patient denied any history of underarm sexual intercourse.

During a physical examination, vital signs and general status were observed to be within normal limits. Dermatological evaluation showed multiple lesions with a regional distribution in the right armpit, right arm, and both thighs. The lesions varied in size from 0.1×0.1×0.1 cm to 1×0.5×0.5 cm, indicating clear boundaries, raised, dry, hyperpigmented papular appearance, some of which were confluent. Upon venereological examination of the penis, pubis, and perianal area, multiple lesions were observed. The lesions, measuring 0.1×0.2×0.1 cm to 3×2×3 cm, had firm boundaries and raised, skin-colored, verrucous surface papules. Some were confluent and resembled a cauliflower with a bumpy surface texture (Figure 1). The consistency of the lesions was described as springy, with some being movable from the base and no reported tenderness. Furthermore, acetowhite examination was positive in axillary, penile, and perianal lesions. The patient was subjected to a punch biopsy on the axillary and inguinal lesions, as well as a shave biopsy on the perianal lesion for histopathological and PCR HPV genotyping examination.

Histopathological examination of the axillary biopsy preparation showed stratified squamous epithelium, papillomatous keratin, acanthotic cells, cell nuclei in normal limits, and koilocytosis. In the subepithelial region, fibro-collagen connective tissue stroma is visible and lightly polluted by lymphocyte inflammatory cells. The skin adnexa appeared to

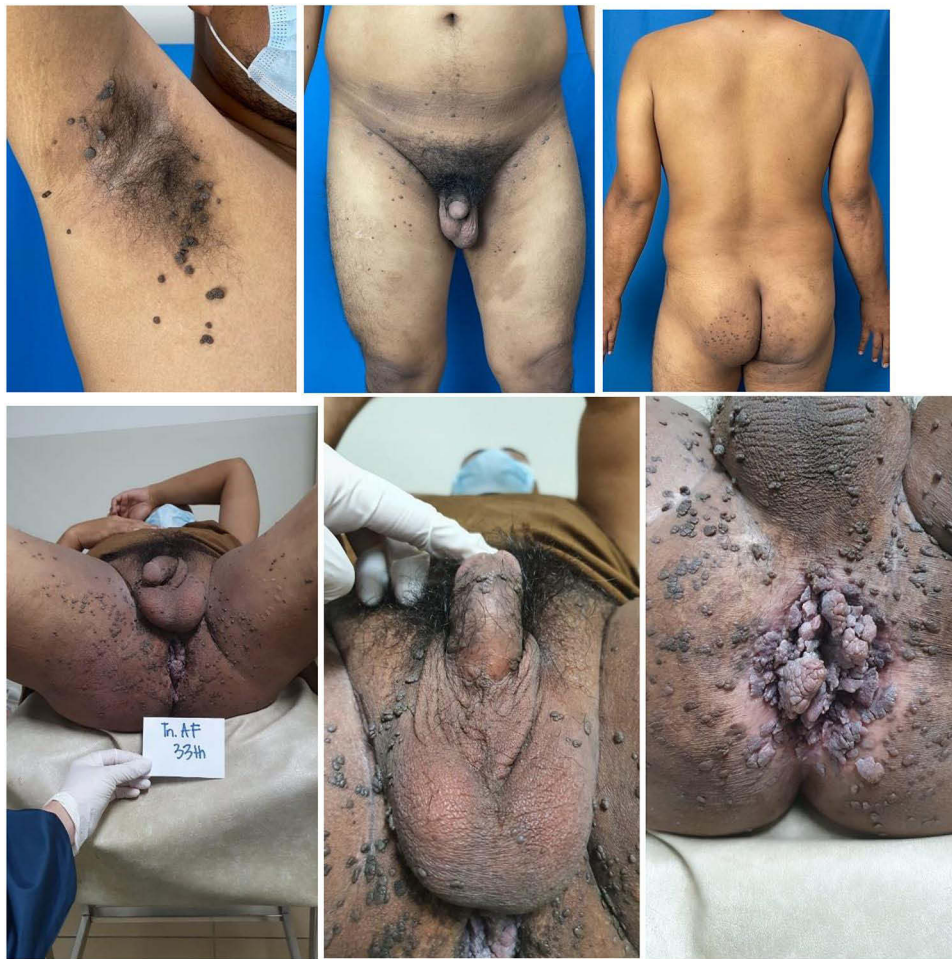

Figure 1 Patient's clinical figure at the initial visit.

consist of hair follicles and sudoriferous glands (sweat glands) in normal limits. There were no visible signs of malignancy. Furthermore, inguinal and perianal biopsy preparations provided a picture of the epidermis lined with stratified squamous epithelium, papillomatous keratinized, acanthotic, and nuclei in normal limits, with some showing koilocytosis. The dermis consisted of dilated blood vessels and an abundance of inflammatory cells, including lymphocytes, and histiocytes, coexisting with the fibrocollagen connective tissue stroma. Based on observation, the skin adnexa consists of hair follicles, as well as sebaceous and sudoriferous glands (sweat glands) (Figure 2).

The entire lesions in the anal area were removed by surgery, while those on the penis and the pubis were treated with 80% trichloroacetic acid (TCA) once a week for 4 cycles. Clinical improvement was observed, with some lesions decreasing in size following the treatment regimen, as presented in Figure 3.

Discussion

HPV, a non-enveloped, double-stranded DNA virus, is a member of Papillomaviridae family, which can be classified into mucosal and cutaneous forms. The cutaneous type is epidermotrophic and infects the surface of the keratinized skin, while the mucosal type infects various mucosae, including the anogenital epithelium. With over 150 identified types of HPV, approximately 40 were mucosal types. These include types 6, 11, 16, 18, 30, 31, 34, 35, 39, 40, 42, 43, 44, 45, 51, 52, 53, 54, 55, 56, 58, 59, 64, 66, 67, 68, 70, 71, 72, 73, 74, 81, 83, 84, 85, 86, 87, 89, 90, 91. Based on the nucleotide sequence of genes, particularly the gene producing the L1 protein, which affects HPV tropism, the different papillomavirus kinds were distinguished.^{10,11} HPV types are further categorized into high-risk (HR-HPV) and low-risk (LR-HPV) groups.^{12,13} Efforts are needed to better classify patients with HPV using PCR examination to provide useful information

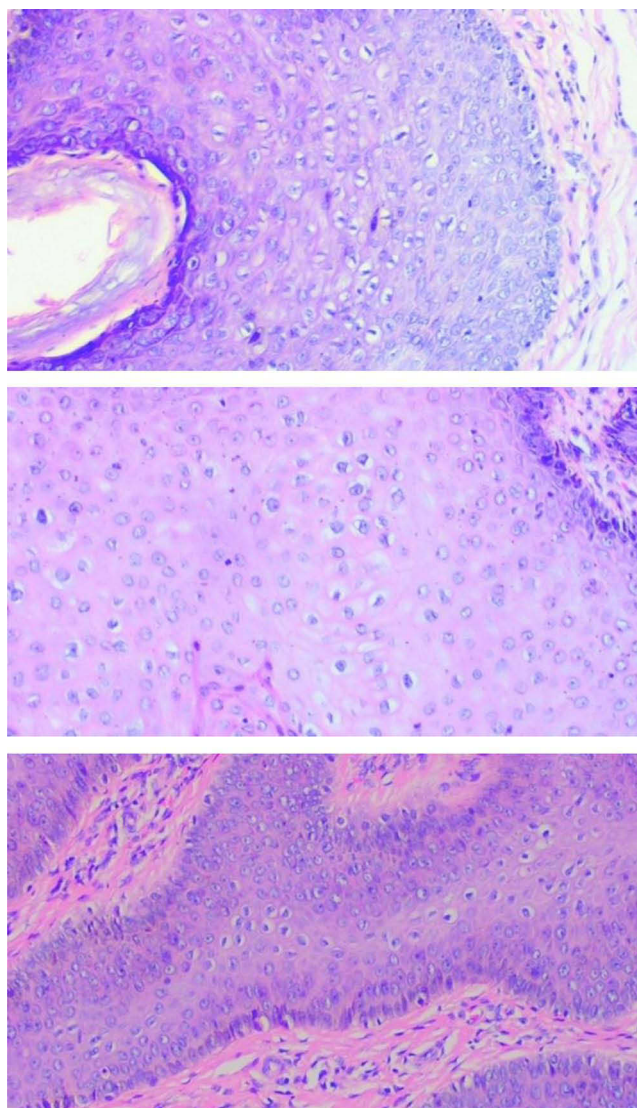


Figure 2 Histopathological examination of the AGW lesion.

for prognosticating and appropriately tailoring surveillance.¹⁴ HPV types 16, 18, 26, 31, 33, 35, 39, 45, 51–53, 56, 58, 66–70, 73, 82, 85, and 97 are included in the HR-HPV group and are known to cause malignant anogenital tumors, which include cancer of the cervix, vulva, vagina, anus, and penis.^{12,13} Before turning into cancer, it also developed into a precancerous lesion as high-grade dysplasia of the cervix, which can recur and persist. The persistence of the lesion is correlated with the risk of developing the recurrent disease.¹⁵ On the other hand, HPV types 6, 11, 40, 42, 44, and 54, included in the LR-HPV group, tend to cause benign tumors such as AGW.^{12,13}

AGW can develop as a result of several variables, including MSM and immunocompromised conditions.^{3,12} HPV seroprevalence increases 2- to 6-fold in MSM compared with heterosexuals.¹⁶ According to a retrospective study by Clanner-Engelshofen et al¹⁷ 83.9% out of a total of 1124 AGW patients, were men. The several risk factors associated with the prevalence of anogenital HPV infection in MSM include age, coitarche, number of partners, history of AGW in partners, history of insertive sexual relations, receptive or versatile in anogenital sexual intercourse, and lack of condom use.¹⁸

Immunocompromised conditions including HIV infection increase the risk of AGW as numerous studies have consistently demonstrated a high prevalence of HPV infection among this group. The immunosuppression induced by HIV may contribute to the reactivation of viruses, which would otherwise remain dormant.³ Immunocompromised

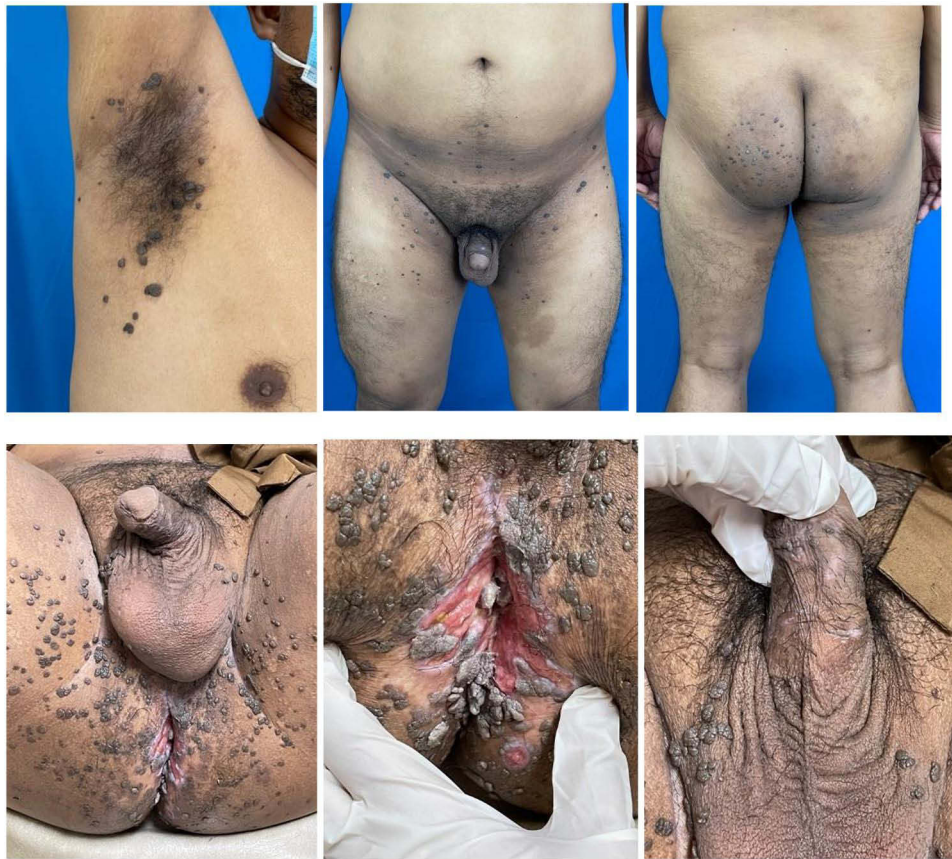

Figure 3 Progress of patient's clinical figure after 4 cycles of TCA.

patients could have compromised host recognition and HPV clearance, leading to concurrent infection perpetuation and viral immune evasion tactics.¹⁹

AGW lesions that appear in immunocompromised conditions can be multiple, extensive, severe, multifocal, less responsive/resistant to therapy, and refractory.^{3,19} Latent HPV infections may reactivate as a result of HIV infection, which weakens the cellular immune response.^{3,20} In HIV infection, proinflammatory cytokines such as interleukin (IL)-6, IL-1, and TNF-alpha can also be induced. These cytokines can increase HPV transcription, thereby raising the number of HPV viruses.²¹ In 2013, Hu et al²² showed an 82.1% rate of HPV infection in 212 MSM patients who were HIV positive, and 57.5% in 459 MSM patients who were HIV negative. This result is in accordance with the case, where AGW occurred in MSM and HIV infection was the main risk factor.

Extragenital warts of the condyloma acuminata type caused by HPV types 6 and 11 have been rarely reported.^{9,23} Previously, there were 4 documented case reports of extragenital warts caused by HPV type 6. These include the study by Hsu et al¹⁰ where a 30-year-old male presented with numerous cerebriform and verrucous pedunculated papule on the axilla, forming a 2-cm plaque. The patient denied any history of oral or genital lesions, no genital lesions were observed during examination, and HIV status was unknown. Another case was reported by Blauvelt et al⁹ where extragenital warts of the condyloma acuminata type, were caused by HPV type 6, in a 9-year-old child. A history of atopic dermatitis and recurrent asthma, alongside a negative HIV status, was stated. External genital examination by a pediatric gynecologist showed no evidence of AGW or sexual abuse. Nassiri et al²³ described a case of extragenital warts caused by HPV type 6, where a 58-year-old man presented with two giant condyloma acuminatum (GCA) lesions on the neck and one on the back. The patient also had a genital lesion, but all serological results were negative for HIV. Additionally, Jovic et al²⁴ reported a rare instance of linear GCA type extragenital warts caused by HPV type 6 in a 70-year-old Caucasian man, presenting as a linear verrucous plaque (20 x 2 cm) on the abdomen with a few solitary reddish satellite papules. Despite

the previous experience of 30 kg weight loss in 8 months, the HIV test result conducted was negative. A particular cytopathic effect of HPV namely koilocytes causes squamous cells in the upper layer of the epidermis to have a visible perinuclear zone, or halo, indicative of condyloma acuminata. Acanthosis, papillomatosis, thicker and longer rete ridges, hyperkeratosis, parakeratosis, hypergranulosis, hyperplasia in basal cells, and vacuolization in the cytoplasm were among the characteristics of AGW discovered through histological examination.²⁵ In all cases, the histopathological result is in accordance with AGW, showing koilocytes alongside other characteristic features such as papillomatosis, acanthosis, and hyperkeratosis. Additionally, PCR results confirmed the presence of HPV type 6 in all lesions,^{9,10,23,24} with a case also testing positive for HPV type 11.¹⁰ The lesions tend to develop approximately 3 years before admission.^{9,10,23} This case was the first to describe extragenital and genital warts caused by HPV type 6 and 11 in MSM, HIV-infected patients.

According to previous studies, the transmission of genital-type HPV to non-genital areas occurs through various means, including contaminated tools such as razors used for shaving multiple body locations. This practice can lead to autoinoculation, where the virus is transferred from the genital area to the axilla, maschalgia (armpit fetishism). Other potential transmission routes include contact with towels, toiletries, and transmission during vaginal delivery, particularly in the late onset of clinical disease.¹⁰ Additionally, individuals with a history of atopy or friction-induced microtrauma to the skin may be more prone to infection.^{9,23,24} Transmission is further elevated by immunocompromised conditions, increasing the chances of infection manifesting as extragenital warts.²⁴ The viruses can endure on surfaces, apparel, frequently used gynecological equipment, and fomites for several days.²⁶ They were also discovered to have similar resistance to desiccation, keeping 50% infectivity after 3 days at room temperature. This evidence establishes the possibility of HPV infection spreading through non-sexual contact.²⁷

In the case under consideration, a history of HIV infection, significant weight loss, and a habit of using the same razor for pubic and armpit hair, alongside bathing with a mesh scrub, and frequent scratching of skin disorders in the anus, are identified as potential risk factors for transmission of the virus from genital to extragenital areas. The limitation of this study is the inability to prove the existence of HPV either on the razor, mesh scrub, or nail of the patient due to the possibility that the exposure occurred over a long period, resulting in a negative result. Additionally, the lack of CD4 data hinders the comprehensive understanding of the immunological status of the patient.

There is currently no ideal treatment for AGW, and no treatment has demonstrated superiority over others. Without treatment, AGW may spontaneously resolve in 16 weeks to 2 years, remain unchanged, or potentially proliferate further.^{8,28} The various therapy modalities were broken down into those suitable for patient self-admiration, such as podoflox 0.5% solution and imiquimod 5% cream, despite not being approved for wart in mucous areas. Medical professionals adopted a range of modalities including cryotherapy, podophyllin resin, trichloroacetic acid (TCA), curettage, electrosurgery, laser vaporization, surgical excision, and interferon or 5-fluorouracil/epinephrine gel implants.^{3,29} TCA therapy is one of the AGW treatment modalities with the most evidence, particularly 1A.^{2,30} Podophyllin is less preferred due to the unstable shelf life, need for post-application washing, and higher chances of causing systemic toxicity such as bone marrow depression.³ While retrospective data suggested a potential protective effect of HPV vaccination on the patient subjected to treatment for HPV-related diseases, further studies were necessary to confirm the preliminary outcome.³¹

TCA is a corrosive substance,^{8,22} that burns and breaks the skin and mucosa at a concentration of 80–90%. Health professionals use a cotton tip applicator to apply this substance to the surface of the wart during therapy. TCA solution is meant to be administered once every week for a maximum of 8–10 weeks.³⁰ Furthermore, the therapy was indicated for external AGW lesions (penis, groin, scrotum, vulva, perineum, external anus, and perianal), including the cervix, vagina, and internal anus.⁸ In this case report, the patient was given TCA 80% spot applied once a week for 4 cycles to treat AGW lesions on the penis and pubis, resulting in clinical improvement, as presented in [Figure 2](#).

GCA cases are uncommon and lack an established effective treatment method. Surgical excision, when compared to non-surgical therapies, yields the most promising outcomes, with reported effectiveness ranging from 63–91% and recurrence rates of 50%.³² Wide local excision or abdominoperineal resection are among the surgical methods commonly adopted.³³ In the case under consideration, the patient was subjected to a large local surgical excision. On the 14th day after surgery, papules with a verrucous surface persisted, but no new skin abnormalities had been identified.

Conclusion

In conclusion, immunocompromised conditions including HIV infection which commonly occurred in MSM had a higher risk for the development of AGW lesions in unusual locations. The lesions were often transmitted from the genital area through the sharing of contaminated tools, such as razors, towels, and toiletries. Additionally, the transmission occurred as a result of autoinoculation, namely maschalgia (armpit fetishism), or scratching.

Ethical Statement

The inclusion of figures was conducted with explicit consent obtained from the patient for publication of the case. This study adhered to ethical standards and received clearance from the Research Ethics Committee of Padjadjaran University. Ethical number DP.04.03/D.XIV.6.5/70/2024.

Consent Statement

The authors attested to be in the position of all necessary patient permission paperwork. A consent form allowing the release of the case data and figures was signed.

Acknowledgments

The authors are grateful to the personnel of the Departments of Dermatology and Venereology at the Faculty of Medicine, Universitas Padjadjaran - Dr. Hasan Sadikin General Hospital.

Disclosure

The authors declare no conflicts of interest in this work.

References

1. Sharma N, Sharma S, Singhal C. A comparative study of liquid nitrogen cryotherapy as monotherapy versus in combination with podophyllin in the treatment of condyloma acuminata. *J Clin Diagn Res.* 2017;11(3):1.
2. Gilson R, Nugent D, Werner R, Ballesteros J, Ross J. IUSTI-Europe guideline for the management of anogenital warts. *J Eur Acad Dermatol Venereol.* 2020;34(8):1644–1653. doi:10.1111/jdv.16522
3. Winer RL, Koutsky LA. Genital human papillomavirus infection. In: Holmes KK, Sparling PF, Stamm WE, Piot P, Wasserheit JN, Corey L, editors. *Sexually Transmitted Diseases.* 4th ed. New York: McGraw- Hill; 2008:489–508.
4. Atkinson AL, Pursell N, Sisay A. Case Report: the giant condyloma (Buschke- Lowenstein Tumor) in the immunocompromised patient. *Case Rep Obstet Gynecol.* 2014;14:1–3.
5. Freire MP, Pires D, Forjaz R, et al. Genital prevalence of HPV types and co-infection in men. *Int Braz J Urol.* 2014;40(1):67–71. doi:10.1590/S1677-5538.IBJU.2014.01.10
6. Manga MM, Fowotade A, Yahaya M. Human papillomavirus (HPV) infection in males: a need for more awareness. *Current Perspect Human Papillom.* 2019;2019:93.
7. Silvia W, Anum Q. Difference of human papillomavirus type between human immunodeficiency virus positive and negative in anogenital condyloma acuminata patients. *Period Dermatol Venereol.* 2019;31(2):130–136.
8. Incidence, prevalence, and cost of sexually transmitted infections in the United States 2013. Atlanta: Centers for Disease Control and Prevention; 2019. Available from: <https://www.cdc.gov/std/stats/STI-Estimates-Fact-Sheet.Feb.2013.pdf>. Accessed March 9, 2020.
9. Blauvelt A, Duarte AM, Pruksachatkunakorn C, Leonardi CL, Schachner LA. Human papillomavirus type 6 infection involving cutaneous nongenital sites. *J Am Acad Dermatol.* 1992;27(5):876–879. doi:10.1016/0190-9622(92)70271-G
10. Hsu T, Nahmias ZP, Rosman IS, Sheinbein D. Extragenital condyloma acuminatum in the left axillary vault. *J Am Acad Dermatol.* 2018;4(9):947–949.
11. Egawa N, Egawa K, Griffin H, Doorbar J. Human papillomaviruses; epithelial tropisms, and the development of neoplasia. *Viruses.* 2015;7:3863–3890. doi:10.3390/v7072802
12. Al-Azmi H, Hanafy H. Human papillomavirus: manifestations, prevention and treatment: an overview. *Gulf J Dermatol Venereol.* 2012;19(1):1–28.
13. Ebrahimi A, Moradi MR, Rezaei M, et al. Comparison of the risk factors and HPV types in males with anogenital warts with and without involvement of the urethral meatus in western Iran. *Acta Dermatovenerol APA.* 2017;26(3):55–58. doi:10.15570/actaapa.2017.18
14. Bogani G, Sopracordevole F, Ciavattini A, et al. HPV persistence after cervical surgical excision of high-grade cervical lesions. *Cancer Cytopathol.* 2023;2023:1. PMID: 37747763. doi:10.1002/cncy.22760
15. Bogani G, Sopracordevole F, Ciavattini A, et al. Italian Society of Colposcopy and Cervico-Vaginal Pathology (SICPCV); The Investigators of the Italian HPV study group (iHPV study group). Duration of human papillomavirus persistence and its relationship with recurrent cervical dysplasia. *Eur J Cancer Prev.* 2023;32(6):525–532. PMID: 37401466. doi:10.1097/CEJ.0000000000000822
16. Blas MM, Brown B, Menacho L, Alva IE, Silva-Santisteban A, Carcamo C. HPV prevalence in multiple anatomical sites among men who have sex with men in Peru. *PLoS One.* 2015;10:1–9.17. doi:10.1371/journal.pone.0139524

17. Clanner-Engelshofen BM, Marsela E, Engelsberger N, et al. Condylomata acuminata: a retrospective analysis on clinical characteristics and treatment options. *Heliyon*. 2020;6(3):3547. doi:10.1016/j.heliyon.2020.e03547
18. Laprise C, Trottier H. Epidemiology of anogenital human papillomavirus infections. In: Broek DV editor. *Human Papillomavirus and Related Disease- from Bench to Bedside a Diagnostic and Preventive Perspective*. BoD-Books on Demand; 2013:231–265. doi:10.5772/56594
19. Zampella J, Cohen B. Consideration of underlying immunodeficiency in refractory or recalcitrant warts: a review of the literature. *Skin Health Dis*. 2022;2(1):e98. doi:10.1002/ski2.98
20. Gao L, Zhou F, Li X, Yang Y, Ruan Y, Jin Q. Anal HPV infection in HIV- Positive men who have sex with men from China. *PLoS One*. 2010;5(12):1–6. doi:10.1371/journal.pone.0015256
21. Palefsky J. Biology of HPV in HIV infection. *Adv Dent Res*. 2006;19(1):99–105. doi:10.1177/154407370601900120
22. Hu Y, Qian HZ, Sun J, et al. Anal human papillomavirus infection among HIV-infected and uninfected men who have sex with men in Beijing, China. *JAIDS*. 2013;64(1):103–114. doi:10.1097/QAI.0b013e31829b6298
23. Nassiri A, Aqil N, Baybay H, et al. Extra genital HPV-6. *Our Dermatol Online*. 2019;10:71–73. doi:10.7241/ourd.20191.19
24. Jovic A, Kocic H, Damiani G, et al. Unusual clinical presentation of giant extragenital condyloma. *Acta Dermatovenerol Croat*. 2020;28(4):240–241.
25. Khiari R, Ichaoui H, Raboudi M, et al. Condylomata acuminata of the urethral meatus: successful combination therapy. *Int J Biomed Sci*. 2018;13(1):32–35. doi:10.59566/IJBS.2018.14032
26. Petca A, Borislavski A, Zvanca ME, Petca RC, Sandru F, Dumitrascu MC. Non-sexual HPV transmission and role of vaccination for a better future (Review). *Exp Ther Med*. 2020;20(6):186. doi:10.3892/etm.2020.9316
27. Ryndock EJ, Meyers C. A risk for non-sexual transmission of human papillomavirus? *Exp Rev Anti-Infective Ther*. 2014;12(1):1165–1170. doi:10.1586/14787210.2014.959497
28. Thappa D, Senthilkumar M, Laxmisha C. Anogenital warts-an overview. *Indian J Sex Transm Dis*. 2004;25(2):55–66.
29. Patel H, Wagner M, Singhal P, Kothari S. Systemic review of the incidence and prevalence of genital warts. *BMC Infect Dis*. 2013;13(39):1–14. doi:10.1186/1471-2334-13-39
30. Lacey CJN, Woodhall SC, Wikstrom A, Ross J. European guideline for the management of anogenital warts. *J Eur Acad Dermatol*. 2012;27(3):e263–70.
31. Bogani G, Sopracordevole F, Ciavattini A, et al. HPV-related lesions after hysterectomy for high-grade cervical intraepithelial neoplasia and early-stage cervical cancer: a focus on the potential role of vaccination. *Tumori*. 2023;17:3008916231208344. PMID: 37978580. doi:10.1177/03008916231208344
32. Gholam P, Enk A, Hartschuh W. Successful surgical management of giant condyloma acuminatum (Buschke-Löwenstein tumor) in the genitoanal region: a case report and evaluation of current therapies. *Dermatology*. 2009;218(1):56–59. doi:10.1159/000165359
33. Paraskevas KI, Kyriakos E, Poullos EE, Stathopoulos V, Tzouvaras AA, Briana DD. Surgical management of giant condyloma acuminatum (Buschke-Loewenstein Tumor) of the perianal region. *Dermatol Surg*. 2007;33(5):638. doi:10.1111/j.1524-4725.2007.33125.x

HIV/AIDS - Research and Palliative Care

Dovepress

Publish your work in this journal

HIV/AIDS - Research and Palliative Care is an international, peer-reviewed open-access journal focusing on advances in research in HIV, its clinical progression and management options including antiviral treatment, palliative care and public healthcare policies to control viral spread. The manuscript management system is completely online and includes a very quick and fair peer-review system, which is all easy to use. Visit <http://www.dovepress.com/testimonials.php> to read real quotes from published authors.

Submit your manuscript here: <https://www.dovepress.com/hiv-aids—research-and-palliative-care-journal>