

## Xanthogranulomatous Oophoritis: A Rare Case Report

Kaneeka Bhatnagar<sup>1\*</sup>, Vikram Narang<sup>2</sup>, Bhavna Garg<sup>2</sup>, Neena Sood<sup>2</sup>

1. Senior Resident, Dept of Pathology, Dayanand Medical College and Hospital, Ludhiana, India
2. Dept. of Pathology, Dayanand Medical College and Hospital, Ludhiana, India

KEYWORDS	ABSTRACT
Xanthogranulomatous, oophoritis, histiocytes	Xanthogranulomatous oophoritis is an uncommon, non-neoplastic, chronic process in which the affected organ is destroyed by massive cellular infiltration of foamy histiocytes admixed with multinucleated giant cells, plasma cells, fibroblasts, neutrophils, and foci of necrosis. The etiology of this entity is unknown, but it shares histopathological findings similar to those of xanthogranulomatous change occurring in various organs, including the gallbladder and kidney.
<b>Article Info</b> Received 06 May 2017; Accepted 18 Aug 2018; Published Online 12 Sep 2018;	The current case was a 20-year-old female presenting with a tubo-ovarian mass with suspicion of malignancy on clinicoradiological findings and final diagnosis of xanthogranulomatous oophoritis established on histopathology. Clinically and radiologically, xanthogranulomatous oophoritis mimics tumor of the ovary and fallopian tube, thereby making it an important entity. A vigilant histopathological evaluation is important to diagnose the disease.
<b>Corresponding information:</b>	Kaneeka Bhatnagar, Senior resident, Dept of Pathology, Dayanand Medical College and Hospital, Ludhiana, India

Copyright © 2018, IRANIAN JOURNAL OF PATHOLOGY. This is an open-access article distributed under the terms of the Creative Commons Attribution-non-commercial 4.0 International License which permits copy and redistribute the material just in noncommercial usages, provided the original work is properly cited.

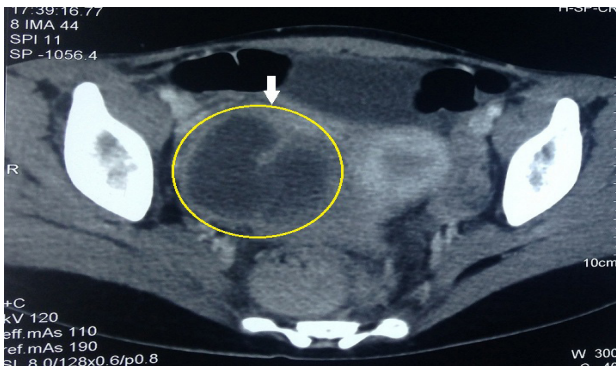
### Introduction

Xanthogranulomatous inflammation is an uncommon form of chronic inflammatory process that is destructive to normal histology of involved organs (1). The most commonly affected organs are the kidney and gallbladder, followed by anorectal area, bone, stomach, and testis (2). If the inflammation occurs in female genital tract, it more commonly affects the endometrium but vagina, cervix, fallopian tube, and ovary can also be affected (3). The ovarian involvement is rare and is characterized by a massive infiltration of the tissues by lipid-laden histiocytes admixed with lymphocytes, plasma cells, and polymorphonuclear leukocytes (3). Few cases are reported in literature of this entity and the current case was reported in view of its rarity (4).

### Case report

A 20-year-old unmarried female referred to the Outpatient Department of Gynecology at Dayanand Medical College and Hospital, Ludhiana, India with complaints of intermittent fever since two months and abdominal pain since 10 days. Her menstrual history was normal with regular periods and was in the secretory phase of the cycle at the time of admission. On examination, abdomen was tender in the right iliac fossa region and was distended. Routine investigations showed hemoglobin (Hb) of 9.3g/dL, total leucocytes count (TLC) of  $14.3 \times 10^9$  /L, and erythrocyte sedimentation rate (ESR) 60 mm/hour. Urine routine revealed 10-15 pus cell/hpf (high power field). Raised beta HCG (human chorionic gonadotropin) levels of 10.85 mIU/mL (normal range >1 in females) and CA-125 (cancer antigen 125) of 38.70 U/mL (normal range 0-35 U/mL) were noted. Serum

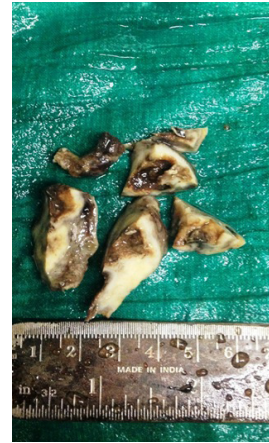amylase and serum lipase levels were within normal limits. A possibility of malignancy could not be ruled out and an ultrasound and multidetector computed tomography (MDCT) scan were performed to know the extent of the disease. Ultrasound of the abdomen revealed a thick walled cystic hyperechoic mass in the right pelvic region measuring 9.7 x 7.8 x 5.7 cm and right ovary was not visualized separately. There was a possibility of right adnexal mass as well as a ruptured abscess. Gross hydronephrosis of right kidney with parenchymal thinning was also noted. Triphasic MDCT scan was performed after injecting a non-ionic contrast dye intravenously. It showed a large irregular thick walled peripherally enhancing cystic lesion with partial septations measuring approximately 8 x 4.6 x 4.4 cm in the right adnexal region (Figure 1).



**Figure 1.** Triphasic Multi-Detector Computed Tomography (MDCT) showing a peripherally enhancing cystic lesion with partial septations in the right adnexal region

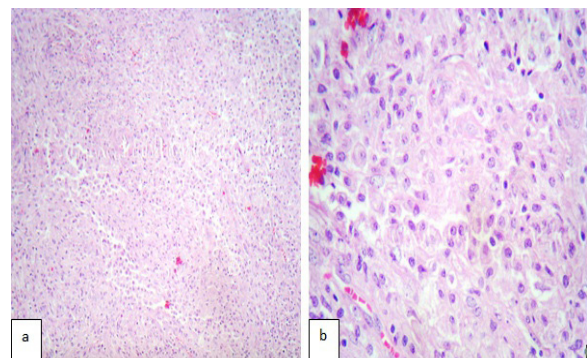
The right ovary was not visualized. Distal ileal loops on the right side of pelvis were matted together with slightly thickened walls and stranding in the surrounding mesentery. Small right kidney measuring 6.4 cm in length with dilatation of pelvicalyceal system was visualized on CT scan, which was thought to represent either an inflammatory process or ovarian neoplasm. The patient was taken up for exploratory laparotomy with a clinicoradiological suspicion of tubo-ovarian malignancy. Adhesionolysis, tubo-ovarian mass was noticed, which was densely adhered to ileal loops and appendix with pus posterior to the right tubo-ovarian mass. Adhesiolysis, right oophorectomy, appendectomy with loop ileostomy and left ovarian debulking was performed, although left ovary was normal in size and shape on MDCT. Approximately

500 mL of cloudy foul smelling material was drained. The excised mass was sent for histopathological examination and was received in the Department of Pathology of the institution as multiple soft tissue pieces that together measured 7 x 4 x 3 cm. The cut surface was partly solid and partly cystic with yellowish tinge (Figure 2).



**Figure 2.** Gross appearance of the ovarian mass received in multiple bits. The mass is partly solid and partly cystic. The yellow discoloration of the tissue is evident.

Microscopic examination of the ovarian tissue showed dense infiltration of the ovarian stroma by an infiltrate comprising of sheets and nodules of foamy macrophages, many histiocytes, lymphocytes and neutrophils. Dense fibrosis was also noted. These findings were suggestive of a xanthogranulomatous inflammation of the ovary (Figure 3).



**Figure 3.** Photomicrograph showing infiltration and replacement of ovarian stroma by foamy histiocytes a) low power view (H&E staining; 100X), b) high power view (H&E staining; 400X)

No tumor cells/epithelioid cell granuloma were identified. Ziehl-Neelsen staining technique was employed for AFB (acid-fast bacteria) and PAS (periodic acid-Schiff) stain for fungus as negative. Gram stain

showed presence of Gram-positive cocci.

According to the histopathological, clinical, and radiological findings, the diagnosis of xanthogranulomatous oophoritis was confirmed. The follow-up was uneventful and the patient was discharged in good health conditions.

### Discussion

Xanthogranulomatous inflammation of the female genital tract, also known by different terminologies such as xanthogranulomatous salpingitis and ovarian fibroxanthoma, is an unusual and rare form of chronic oophoritis essentially limited to the endometrium (1, 4). It affects fallopian tubes or ovaries focally or entirely, which clinically forms mass-like lesion in the pelvic cavity and invades the surrounding tissues (4). Only 15 cases involving the female genital tract are reported till date with few cases involving the ovary and reported from India. Kunakemakorn in 1976 was the first to report a case of xanthogranulomatous inflammation of serosa of the uterus, left fallopian tube and ovary (5).

Most commonly, females of reproductive age group 23-72 years are effected, however, a case of two-year-old female with xanthogranulomatous oophoritis is reported (5, 6). A long-standing history of pelvic inflammatory disease and symptoms such as anorexia, fever, suprapubic pain, menorrhagia, or vaginal bleeding, adnexal tenderness and a pelvic mass are the usual chief complaints (7, 8). The exact etiology is still unknown and remains a mystery; however, an association with infection, ineffective antibiotic therapy leading to ineffective clearance of bacteria by phagocytes, endometriosis, intrauterine contraceptive device, pelvic inflammatory disease, and drugs (antibiotics) is suggested. Microorganisms such as *Escherichia coli*, *Proteus* spp., *Staphylococcus aureus*, *Bacteriodes fragilis*, *Salmonella typhi*, *Actinomyces*, *Streptococcus (Enterococcus) faecalis*, viridans streptococci, *Torulopsis (Candida) glabrata*, and group B streptococci are implicated (6). Punia et al., described xanthogranulomatous oophoritis and salpingitis as a late sequelae of inadequately treated pelvic inflammatory disease caused by *Staphylococcus* spp.(10).

Similarly, Shukla et al., suggested an association of this entity with primary infertility and endometriosis in their case report (11). The importance lies in the fact that this type of inflammation can present as a lump or tumor and can even mimic malignancy (3). The clinico radiological findings along with macroscopic examination can mimic xanthogranulomatous oophoritis as ovarian malignancy. A number of reported cases in the past were misdiagnosed as ovarian cancers (9). Hence, gynecologists need to be aware of this entity and be able to differentiate it from endometrial, ovarian, or tubal malignancy. The mass may grow large in size up to 3-7cm in maximum dimension and inflammation when extends to the neighboring organs; pelvic structures and peritoneum can present as adhesions further raising the suspicion of malignancy (12). Grossly, the mass has clear borders with no intact capsule; it is solid, fragile, and accompanied by areas of hemorrhage, necrosis, and cystic degeneration due to liquefactive necrosis (4). Histomorphologically, the normal ovarian structure is destroyed and replaced by chronic inflammatory cell infiltrate admixed with focal or sheets of foam cells, fibroplasia, and vascular proliferation, which give the pseudotumoral appearance grossly (7, 12). The current case was similar to other reported cases in its presentation, radiological findings, history of infection and histopathological findings as described, favoring a diagnosis of xanthogranulomatous oophoritis. Chronic urinary tract infection leading to hydronephrosis of the kidney and Gram-positive cocci seem to be the causative factor in this case.

Presence of foam cells makes malakoplakia an important differential diagnosis as suggested by Walther et al., which is then distinguished from xanthogranulomatous oophoritis by the presence of basophilic Michaelis-Gutmann bodies, which are absent in the latter (13). The inflammatory conditions that come under differential diagnosis include tuberculosis and fungal infections, which are ruled out by special stains and culture studies (14). In the current study, Ziehl-Neelsen stain for AFB and PAS stain was negative; thus, ruling out these possibilities.

Secondary lymphoma/leukemia, when lymphocytes are scattered focally, malignant small round cell tumor with stromal leutinisation when lymphocytes are distributed diffusely and have a paucity of foam cells, sclerosing tumor when areas of fibrosis are noted can mimic this condition and be misdiagnosed as tumor (9). Frozen section can be performed in order to rule out malignancy and also an extensive surgery, but it was not performed in the current case (7). Immunohistochemical stains can be helpful to establish the diagnosis with CD68 (foam cells positive), CD3 (T-lymphocyte marker), CD20 (B-lymphocyte marker), and  $\kappa$  and  $\lambda$  (both positive in polyclonal B-lymphocytes) (4). However, they are not often used owing to the unique histopathological features of this entity as in the current case and thereby were not used. Xanthogranulomatous inflammation is also reported to be lethal by causing systemic inflammation. Hence, aggressive treatment in the form of surgery should be

strongly considered, if diagnosed pre-operatively (3).

### Conclusions

Xanthogranulomatous oophoritis is a rare condition, which can often be a diagnostic challenge for the clinicians as the clinicoradiological presentation often mimics malignancy. However, the pathologists need to be aware of this entity and should be vigilant before giving a diagnosis to prevent a misdiagnosis of malignancy and avoid radical surgery. Gynecologists and surgeons dealing with patients of infertility, endometriosis, pelvic inflammatory disease, IUD (intrauterine device) use, and chronic infections should keep this condition in mind and put these patients on regular follow-up since they are more likely to be affected by such conditions.

### Conflict of interest

The authors declare that there was no conflict of interest.

### References

- Jung SE, Lee JM, Lee KY, Han KT, Hahn ST. Xanthogranulomatous Oophoritis:MR Imaging findings with Pathologic Correlation.AJR 2002 ;178:749-51. <https://doi.org/10.2214/ajr.178.3.1780749> PMID:11856712
- Bindu SM, Mahajan MS. Xanthogranulomatous oophoritis: A case report with review of literature. Int J Health Allied Sci 2014;3:187-9. <https://doi.org/10.4103/2278-344X.138604>
- Gami N, Mundhra R, Guleria K, Arora VK, Garg S. Recurrent pyometra and xanthogranulomatous salpingitis: A rare pathologic association in a postmenopausal lady. J Mid-life Health 2014;5:156-8. <https://doi.org/10.4103/0976-7800.141227> PMID:25317003
- Zhang XS, Dong HY, Zhang LL, Desouki MM, Zhao C. Xanthogranulomatous inflammation of the female genital tract: report of three cases. J Cancer 2013; 3:100-6. PMID:22393333
- Tanwar H, Joshi A, Wagaskar V, Kini S, Bachhav M. Xanthogranulomatous Salpingoophoritis: The Youngest Documented Case Report. Case Rep Obstet Gynecol. 2015.
- Gray Y, Libbey NP. Xanthogranulomatous salpingitis and oophoritis: a case report and review of the literature. Arch Pathol Lab Med 2001; 125:260-3. PMID:11175647
- Khan B, Aziz AB, Ahmed R. Case of Xanthogranulomatous Oophritis.J Ayub Med Coll Abbottabad 2017; 29:162-4. PMID:28712201
- Karigoudar MH, Kushtagi AV, Karigoudar RM, Sirasagi A. Xanthogranulomatous oophoritis - A Rare inflammatory lesion. J Krishna Inst Med Sci Univ 2013; 2:111-5.
- Kalloli M, Bafna UD, Mukherjee G, Devi UK, Gurubasavangouda, Rathod PS. A Rare Xanthogranulomatous oophoritis presenting as ovarian cancer. Online J Health Allied Sci 2012; 11:1-2.
- Punia RS, Aggarwal R, Amanjit, Mohan H. Xanthogranulomatous oophoritis and salpingitis: late sequelae of inadequately treated staphylococcal PID. Indian J Pathol Microbiol 2003; 46:80. PMID:15027734
- Shukla S, Pujani M, Singh SK, Pujani M. Xanthogranulomatous oophoritis associated with primary infertility and endometriosis. Indian J Pathol Microbiol 2010; 53:197-

8. <https://doi.org/10.4103/0377-4929.59240>  
PMID: [20090279](https://pubmed.ncbi.nlm.nih.gov/20090279/)
12. Naik M, Madiwale C, Vaideeswar P. Xanthogranulomatous oophoritis - A case report. Indian J Pathol Microbiol 1999; 42:89-91. PMID: [10420690](https://pubmed.ncbi.nlm.nih.gov/10420690/)
13. Kishore SH, Rajshri OP, Dravid NV. Xanthogranulomatous oophoritis mimicking as an ovarian neoplasm. J Case Reports. 2014;4: 100-3. <https://doi.org/10.17659/01.2014.0025>
14. Tripathy S, Santhamani PM Xanthogranulomatous oophoritis: a rare chronic inflammatory non-neoplastic ovarian pseudotumor. Int J Reprod Contracept Obstet Gynecol 2016;5:3616-8. <https://doi.org/10.18203/2320-1770.ijrcog20163457>

#### How to Cite This Article

Bhatnagar K, Narang V, Garg B, Sood N. Xanthogranulomatous Oophoritis: A Rare entity: CaseReport. Iranian Journal of Pathology, 2018; 13(3): 372-376