


CASE REPORT

Malnutrition from anorexia nervosa triggers severe complications of hereditary spherocytosis in an adolescent girl: A case report

Aditi M. Trivedi¹  | Zephyr D. Dworsky² | Jenny Kim³ | Jennifer C. Yu³ | Maya M. Kumar⁴

¹Department of Pediatrics, Rady Children's Hospital San Diego, University of California San Diego, San Diego, California, USA

²Division of Pediatric Hospital Medicine, Department of Pediatrics, University of California San Diego and Rady Children's Hospital of San Diego, San Diego, California, USA

³Division of Pediatric Hematology/Oncology, Department of Pediatrics, University of California San Diego and Rady Children's Hospital of San Diego, San Diego, California, USA

⁴Division of Adolescent and Young Adult Medicine, Department of Pediatrics, University of California, San Diego and Rady Children's Hospital of San Diego, San Diego, California, USA

Correspondence

Aditi M. Trivedi, Department of Pediatrics, Rady Children's Hospital San Diego, University of California San Diego, San Diego, California, USA.
Email: atrivedi@health.ucsd.edu

Funding information

None

Abstract

Hemolytic crises and aplastic crises in hereditary spherocytosis (HS) are most commonly triggered by viral infections. We present the case of an adolescent girl with HS who developed unexpected and life-threatening complications of her inherited hemolytic anemia as a consequence of anorexia nervosa and severe malnutrition.

KEYWORDS

adolescent, anorexia nervosa, bone marrow diseases, chronic disease, feeding and eating disorders, hemolysis, hemolytic anemia, malnutrition, nutrition disorders, weight loss

1 | INTRODUCTION

Hereditary spherocytosis (HS) is the most common inherited cause of hemolytic anemia.¹ It is characterized by an erythrocyte membrane defect leading to chronic normocytic hemolytic anemia and, if moderate or severe,

jaundice and/or splenomegaly. Most patients with HS have elevated reticulocytes at baseline as a compensatory mechanism for ongoing hemolysis. If reticulocytosis in the bone marrow is suppressed, serious aplastic crises may occur. The most common triggers for hemolytic and aplastic crises are viral infections.¹ Since viral infections resolve

This is an open access article under the terms of the [Creative Commons Attribution-NonCommercial-NoDerivs](https://creativecommons.org/licenses/by-nc-nd/4.0/) License, which permits use and distribution in any medium, provided the original work is properly cited, the use is non-commercial and no modifications or adaptations are made.

© 2022 The Authors. *Clinical Case Reports* published by John Wiley & Sons Ltd.

relatively quickly, most hemolytic and aplastic crises can be managed conservatively with only occasional need for blood transfusions in severe cases.

In this report, we describe the case of an adolescent girl with HS who presented with an aplastic crisis from an unusual trigger: severe malnutrition and copper deficiency associated with anorexia nervosa (AN). This resulted in prolonged bone marrow suppression and severe uncompensated hemolytic anemia that complicated the treatment of her eating disorder. This is the first report that we are aware of which describes the unusual and significant repercussions that eating disorders and severe malnutrition can have on patients with underlying hemolytic anemias. This case also suggests that youth with chronic health conditions may face increased risk of more serious complications if they develop eating disorders.

2 | CLINICAL OBSERVATION

A 14-year-old girl with a history of moderate HS was admitted to an eating disorder inpatient unit with severe malnutrition, dehydration, fatigue, headache, dizziness, and 18 kg of weight loss. Her weight loss began 18 months before admission but was more precipitous immediately prior to admission. At the time of her admission, she had a severely restricted non-vegetarian diet and was consuming less than 500 calories per day, which was only 20% of her estimated nutritional needs. She had been afebrile without any rhinorrhea, cough, diarrhea, vomiting, or any other symptoms suggestive of viral illnesses for months prior to admission. She had been previously evaluated for organic causes of weight loss including celiac disease, thyroid disease, malignancy, gallbladder disease, and systemic inflammatory conditions, without any contributors identified. Her social and familial situations had been

stable without any acute stressors and she had maintained good academic performance. She reported an intentional dietary restriction to lose weight, fear of weight gain, and poor body image. Psychopathology was consistent with anorexia nervosa restrictive subtype. Her expected body weight (EBW) was 56.1 kg using the 75th percentile body mass index (BMI) for her age and sex, consistent with her premorbid growth curve (Figure 1). Her admission weight was 31 kg, which was 55.5% of her EBW. She presented with symptomatic orthostatic hypotension and tachycardia, with blood pressure dropping from 107/60 to 81/51 and heart rate increasing from 57 bpm to 91 bpm when she changed positions from supine to standing.

She had been diagnosed with HS as a newborn when she presented with neonatal jaundice and hemolytic anemia. There was a known family history of HS in her father and paternal relatives. In infancy, she had required several packed red blood cell (pRBC) transfusions for aplastic or hemolytic crises thought to be induced by viral infections. After the newborn period until the time of her admission, she had required only two additional transfusions at age 11 years and 13 years when she experienced hemolytic and aplastic crises, also associated with viral infections. In each of these cases, she required only a single blood transfusion resulting in rapid symptomatic improvement without the need for hospitalization. She neither had history of gallstones, nor had she required splenectomy. She was followed by a pediatric hematologist. Her only home medication was folic acid to prevent megaloblastic anemia.

When she was admitted to the inpatient eating disorder unit, in addition to appearing pale and emaciated with cold extremities, she was found to have scleral icterus and worsening splenomegaly. The initial laboratory testing revealed macrocytic anemia, neutropenia, leukopenia, and unconjugated hyperbilirubinemia (Table 1). Her reticulocyte count was suppressed at 2.8%, significantly

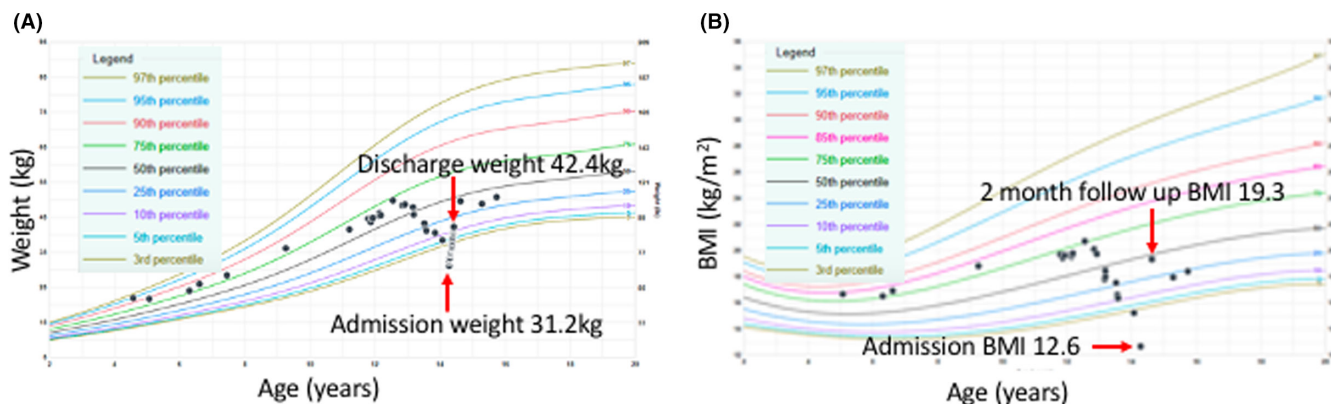


FIGURE 1 This patient's growth curves illustrate a precipitous decline in weight (A) and body mass index (BMI) (B) at the time of admission, followed by recovery throughout hospitalization and at subsequent outpatient follow up visits. Source: Center for Disease Control and Prevention (CDC), 2000

TABLE 1 Comparison of patient's admission and baseline laboratory results for nutritional and hematologic studies

Test (units)	Admission values (normal range)	Baseline values
Hematologic studies		
WBC (TH/ μ l)	2.0 (4.0–10.5)	5.2
RBC (TH/ μ l)	2.12 (4.10–5.3)	3.18
Hemoglobin (g/dl)	8.1 (12.5–15.0)	10.2
Hematocrit (%)	22.0 (35–45)	28.0
MCV (fl)	103.6 (78–95)	88.0
RDW (RDW Unit)	23.3 (11.5–14)	20.8
Platelets (TH/ μ l)	206 (104–440)	212
Absolute neutrophil count (ANC) (TH/ μ l)	1.27 (2.00–7.5)	3.13
Absolute lymphocytes (TH/ μ l)	0.6 (1.1–3.0)	1.4
Absolute monocytes (TH/ μ l)	0.1 (0.3–1.0)	0.3
Reticulocytes (%)	2.8 (0.5–1.5)	9.0
Reticulocyte count absolute (MIL/ μ l)	0.059 (0.02–0.096)	NA
Total bilirubin (mg/dl)	5.5 (0.1–1.0)	2.7
Direct bilirubin (mg/dl)	<0.1 (0.0–0.3)	Unknown
Indirect bilirubin (mg/dl)	4.6 (0.0–1.1)	Unknown
Nutritional studies		
Prealbumin (mg/dl)	11.0 (17.6–36.0)	Unknown
Estradiol (pg/ml)	<2	Unknown
Copper (mcg/dl)	50 (75–187)	Unknown
B12 (pg/ml)	989 (200–946)	Unknown
Folate (ng/ml)	>80.0 (\geq 7.0)	Unknown
Methylmalonic acid (nmol/L)	120 (87–318)	Unknown

lower than her baseline of 9% and lower than it had ever been during previous hemolytic crises. Inflammatory markers (erythrocyte sedimentation rate and C-reactive protein) were normal upon admission. Additionally, her electrolytes, renal function, and urinalysis were normal. A serum copper level was obtained, as copper deficiency has been associated with cytopenias.² She was found to have copper deficiency (Table 1), presumed to be from inadequate dietary intake, and was started on oral copper supplementation.

Due to worsening anemia and hemodynamic instability, she was transfused with one unit of pRBCs. Unlike previous transfusions which had resulted in rapid symptomatic improvement, this transfusion provided only minimal relief of her fatigue and dizziness. Over the following days, her hemoglobin gradually trended down and reticulocytes remained suppressed. One week after she was

admitted, when her hemoglobin had dropped to 7.0 g/dl, and her symptoms worsened further, she required a second pRBC transfusion. The patient's reticulocytopenia gradually improved with nutritional rehabilitation and copper supplementation, with reticulocytes eventually reaching baseline values by hospital day 23 and ultimately reaching as high as 12.9% by the day of discharge (hospital day 55). Her fatigue and dizziness also improved as her weight normalized.

Throughout her hospitalization, she received a multi-disciplinary treatment approach for her eating disorder. This involved participating in medically supervised nutritional rehabilitation programs, as well as undergoing individual and family therapy. She was started on the psychotropic medication fluoxetine for associated anxiety and depression and was frequently evaluated by the team psychologists and psychiatrists. During her hospital stay, she and her parents received education from her treatment team about how her underlying HS predisposed her to more severe complications of malnutrition from her eating disorder. The patient identified this as a major motivating factor to recover from anorexia nervosa.

After a 55-day hospitalization, she had gained 11.4 kg, achieved hemodynamic stability, had resolution of neutropenia and leukopenia, and her hemoglobin had returned to her baseline. She was discharged to a residential eating disorder treatment program. At the time of her hospital discharge, her weight was 42.4 kg (76% EBW), hemoglobin was 8.9 g/dl, and serum copper had normalized to 78 mcg/dl. She has continued to maintain adequate weight and has not had any further hemolytic or aplastic crises.

3 | DISCUSSION

We present the case of an adolescent with moderate HS who developed a prolonged hemolytic and aplastic crisis that appeared to be triggered by severe malnutrition and dietary copper deficiency associated with anorexia nervosa.

The hemolytic crisis described in this report differed from our patient's previous crises in several ways. First, while previous crises had been triggered by viral illnesses (the most common precipitant of hemolytic crises in individuals with HS), this reported hemolytic crisis was triggered by a state of severe malnutrition from months of restricted eating associated with anorexia nervosa. The patient did not have any recent clinical symptoms suggestive of a viral illness prior to admission, her inflammatory markers were within normal limits, and she was not immunocompromised in a way that might suppress her clinical or biochemical immune response to a viral illness.

She was consistently afebrile at recent clinic visits and throughout her hospitalization. Second, while previous crises had only occasionally required a single pRBC transfusion, which had resulted in rapid symptomatic improvement, this crisis required multiple pRBC transfusions that did not significantly improve her symptoms of dizziness and fatigue. Third, previous crises resolved within several days, but this episode was associated with more profound reticulocytopenia that took weeks to resolve. Finally, previous crises were not associated with other cytopenias, whereas this crisis was associated with leukopenia and neutropenia.

As reported in studies of hematologic manifestations of restrictive eating disorders, we hypothesize that her starvation state triggered an aplastic crisis by causing chronic bone marrow suppression resulting in reticulocyte suppression and other cytopenias.³ The resulting cytopenias were not easily reversible and took weeks of aggressive nutritional rehabilitation to resolve. She was also found to have copper deficiency, a relatively uncommon micronutrient deficiency that is associated with leukopenia, neutropenia, and anemia.²⁻⁵ Copper deficiency has previously been reported in association with anorexia nervosa and presents with hematologic findings including anemia and neutropenia.⁶ The cause of her cytopenias was likely multifactorial. With nutritional rehabilitation, her cytopenias eventually gradually resolved, and her reticulocytes finally rose sufficiently to adequately compensate for her hemolysis.

To our knowledge, this is the first reported case of a hemolytic crisis in a patient with HS that was triggered by malnutrition associated with an eating disorder. Adolescents with chronic health conditions may be more likely to experience body image concerns and appear to engage in disordered eating more frequently than their peers.⁷⁻⁹ At the same time, they may be at higher risk for more severe complications from malnutrition. Many previous studies have described an association between anorexia nervosa and chronic health conditions such as cystic fibrosis, diabetes mellitus, inflammatory bowel disease, and celiac disease.^{10,11} Conditions that require dietary changes as part of the treatment particularly increase the risk of developing an eating disorder. However, even with chronic health conditions that do not necessitate dietary changes, such as hemolytic anemias, dietary restriction may still be used as a mechanism to cope with the stress related to living with the condition. As we report in this case, the resulting malnutrition could have a catastrophic disease-specific consequences. Providers who treat adolescents with any chronic health conditions should consider regular screening for body image concerns and disordered eating behaviors to mitigate these consequences. They should also provide anticipatory

guidance about condition-specific complications that may result from disordered eating behaviors, just as they would counsel about condition-specific complications that could arise from other risk behaviors such as substance use or unsafe sexual practices.

In summary, this case highlights how adolescents with chronic health conditions who develop eating disorders may experience more severe complications of malnutrition than their peers. Providers should consider universal screening for body image issues and disordered eating behaviors among all adolescents but especially in this population and provide anticipatory guidance about condition-specific complications that could arise from disordered eating behaviors.

AUTHOR CONTRIBUTIONS

AMT contributed to direct patient care, preparation, writing, editing and submission of manuscript. ZDD, JK, and JCY contributed to direct patient care, manuscript writing, editing and submission guidance. MMK contributed to direct patient care, manuscript writing and editing, submission guidance, and final approval.

ACKNOWLEDGMENTS

We thank the patient and her family.

CONFLICT OF INTEREST

The authors have no conflicts of interest to declare.

DATA AVAILABILITY STATEMENT

All patient data used for this report was taken from the Rady Children's Hospital San Diego medical records.

CONSENT

Written informed consent was obtained from the patient's guardian to publish this report in accordance with the journal's patient consent policy.

ORCID

Aditi M. Trivedi  <https://orcid.org/0000-0001-6598-4846>

REFERENCES

1. Eber S, Lux S. Hereditary spherocytosis – defects in proteins that connect the membrane skeleton to the lipid bilayer. *Semin Hematol.* 2004;41(2):118-141.
2. Kharel P, Gnanapandithan K, Pandey RK, Jha S, Grimshaw A, Giri S. Copper deficiency and cytopenias: a systematic review. *Blood.* 2019;134(Supplement 1):5025.
3. Abella E, Feliu E, Granada I, et al. Bone marrow changes in anorexia nervosa are correlated with amount of weight loss and not with any other clinical findings. *Am J Clin Pathol.* 2002;118:582-588.
4. Myint ZW, Oo TH, Thein KZ, Saeed H. Copper deficiency anemia: a review article. *Ann Hematol.* 2018;97:1527-1534.

5. Yu J, Shliakhtsitsava K, Wang YM, et al. Hematologic manifestations of nutritional deficiencies: early recognition is essential to prevent serious complications. *J Pediatr Hematol Oncol*. 2019;41(3):e182-e185.
6. Russo V. An evaluation of trace metal levels in patients with anorexia nervosa. *Prog Nutr*. 2012;14(3):219-221.
7. Miller CA, Golden NH. An introduction to eating disorders: clinical presentation, epidemiology, and prognosis. *Nutr Clin Pract*. 2010;25(2):110-115.
8. Neumark-Sztainer D, Story M, Falkner NH, Beuhring T, Resnick MD. Disordered eating among adolescents with chronic illness and disability: the role of family and other social factors. *Arch Pediatr Adolesc Med*. 1998;152(9):871-878.
9. Schlundt D, Rowe S, Pichert J, Plant D. What are the eating cognitions of children whose chronic diseases do and do not require attention to diet? *Patient Educ Couns*. 1999;36:279-286.
10. Quick VM, Byrd-Bredbenner C, Neumark-Sztainer D. Chronic illness and disordered eating: a discussion of the literature. *Adv Nutr*. 2013;4(3):277-286.
11. Rome ES, Ammerman S. Medical complications of eating disorders: an update. *J Adolesc Health*. 2003;33:418-426.

How to cite this article: Trivedi AM, Dworsky ZD, Kim J, Yu JC, Kumar MM. Malnutrition from anorexia nervosa triggers severe complications of hereditary spherocytosis in an adolescent girl: A case report. *Clin Case Rep*. 2022;10:e05841. doi:[10.1002/ccr3.5841](https://doi.org/10.1002/ccr3.5841)