

# Ectopic gall bladder: A case report

SAGE Open Medical Case Reports  
Volume 9: 1–3  
© The Author(s) 2021  
Article reuse guidelines:  
sagepub.com/journals-permissions  
DOI: 10.1177/2050313X211036777  
journals.sagepub.com/home/sco



Amitabh Yadav<sup>1</sup>, Samrat Ray and Samiran Nundy

## Abstract

Ectopic gall bladder under the left lobe of liver is a rare congenital anomaly of the position of gall bladder, which is mostly detected during surgery and causes technical difficulty at the time of operation. We operated a 64-year-old male who presented with gall stone disease and pre-operative ultrasound did not report any abnormality in position. On laparoscopy, it was found to be attached on the left side of falciform ligament under segment III. It was a true ectopic gall bladder without situs inversus. Early division of the falciform ligament and a careful and complete dissection of the gall bladder are advocated before clipping the cystic artery and duct to avoid complications. The present case report discusses about this rare anomaly and the available literature on the subject.

## Keywords

Left-sided gall bladder, ectopic gall bladder, laparoscopic cholecystectomy

Date received: 8 March 2021; accepted: 13 July 2021

## Introduction

Various congenital anomalies of the gall bladder are described in the literature regarding its location, size, number, and forms.<sup>1</sup> Gall bladder is normally located in the gall bladder fossa under the right lobe between segment IV and V of the liver, on the von Rex-Cantlie line which is a vertical plane extending from the middle of the gall bladder fossa anteriorly to the inferior vena cava (IVC) posteriorly.<sup>2</sup> Gall bladder found at any other position apart from this, is called as ectopic or aberrant gall bladder. It can be seen in patients with or without situs inversus. In patient without situs inversus, ectopic gall bladder can be categorized into two types: (1) a true left-sided gall bladder and (2) it may appear to be left-sided because of the abnormally placed falciform ligament.<sup>3</sup>

True left-sided gall bladder, also called as sinistroposition, is a more common anomaly<sup>2</sup> and is defined when it is placed under left lobe of the liver and is attached to the left side of falciform ligament and ligamentum teres.<sup>4,5</sup> In majority of cases, the pre-operative ultrasound (USG) is unable to detect the anomaly and the advanced radiological investigations like computed tomographic (CT) scan and magnetic resonance cholangiopancreatography (MRCP) are seldomly performed in uncomplicated gall stone disease. The present case report is about a 64-year-old male with a true ectopic gall bladder which was detected incidentally during surgery.

## Case report

A 64-year-old, diabetic and hypothyroid, male patient presented with a history of dyspepsia for 2 months. Blood tests were within normal limits and USG revealed cholelithiasis. It did not comment about the position of the abnormally placed gall bladder.

He was planned for elective surgery and the laparoscopy from the umbilical port revealed that the gall bladder was not present in its usual fossa but was seen attached to the left of the falciform ligament under the left lobe of liver (Image 1). There were no other associated abnormalities noted on careful laparoscopy and thus, based on our vast institutional expertise in HPB procedures, the surgery was proceeded.

The 10-mm epigastric port was created in the epigastrium and the falciform ligament was divided with the energy source as the gall bladder was more medially placed. Gall bladder was dissected according to the Strasberg critical view of safety, to reduce the incidence of injury to the bile duct. This consisted of freeing the Calot's triangle from fat and fibrous tissue and to dissect the gall bladder neck from

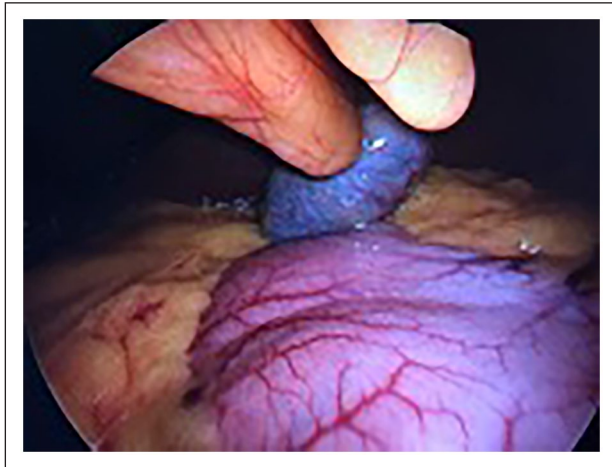Department of Surgical Gastroenterology and Liver Transplant, Sir Ganga Ram Hospital, New Delhi, India

### Corresponding Author:

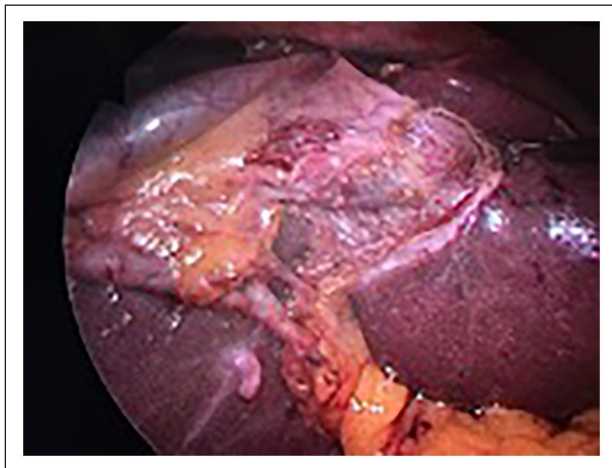
Amitabh Yadav, Department of Surgical Gastroenterology and Liver Transplant, Sir Ganga Ram Hospital, New Delhi 110060, India.  
Email: amitabhyadav99@gmail.com



Creative Commons Non Commercial CC BY-NC: This article is distributed under the terms of the Creative Commons Attribution-NonCommercial 4.0 License (<https://creativecommons.org/licenses/by-nc/4.0/>) which permits non-commercial use, reproduction and distribution of the work without further permission provided the original work is attributed as specified on the SAGE and Open Access pages (<https://us.sagepub.com/en-us/nam/open-access-at-sage>).



**Image 1.** Intra-operative picture on laparoscopy—gall bladder is seen on the left side of the falciform ligament.



**Image 2.** Intra-operative picture after dissecting the gall bladder—cystic duct connected on the left side of bile duct.

the cystic plate, in turn clearly revealing two structures (the cystic duct and artery) entering the gall bladder.<sup>5,6</sup> The junction of the cystic duct and bile duct was clearly defined, and there was no hairpin bend was found in front of the bile duct. The cystic duct was found to be joining the bile duct on its left side (Image 2).

Post-operative course was uneventful, and he was discharged the next day of surgery.

## Discussion

The position of the gall bladder depends upon the position of the liver, but sometimes it may be ectopically placed while the liver lies in its normal position. Various explanations exist regarding the development of the left-sided gall bladder. (1) Gall bladder develops at its normal position, but it moves under the left lobe of liver. In these cases, the

cystic duct is long, and it enters the bile duct from right after curving from medial to lateral side. (2) It develops abnormally from the left duct and the cystic duct enters the bile duct on its left side. (3) It is normal in location but appears abnormally placed due to anomalous falciform ligament, called as right left-sided gall bladder. The cystic duct origin from right side of common bile duct was noticed in 77.3%.<sup>3</sup> In our case, the hairpin bend was not found, and the cystic duct entered the bile duct from the left side.

Old classification for this anomaly described positions like: left-sided, transverse, retro displaced, and intrahepatic. The other abnormal positions for the gall bladder are supra-hepatic (located in the falciform ligament) and the floating gall bladder (located in the anterior abdominal wall).<sup>1,7</sup> A new classification describes three abnormal positions of gall bladder: (1) left-sided gall bladder associated with situs inversus, (2) true left-sided gall bladder; most common variety, and (3) right left-sided gall bladder.<sup>3,8</sup>

The incidence rate of 83% has been reported for the true left-sided gall bladder and 16% due to abnormally placed falciform ligament, in a study done on patients with left-sided gall bladder without situs inversus.<sup>3</sup> In our case, it was true left-sided and was ectopically placed under segment III of liver.

The rare anomaly was published for the first time in 1886 by Hochstetter and about 150 cases are reported so far.<sup>2,3</sup> The incidence varies from 0.04% to 1.1%.<sup>1,5,8–10</sup> with a mean age of  $51 \pm 17$  years and the sex ratio of 2:1. The majority of cases are reported from Australia and Japan.<sup>3</sup> It may be associated with other biliary and portal venous anomalies and the most common associated anomaly is atrophied quadrate lobe.<sup>3</sup>

It is of clinical significance as it may be undiagnosed pre-operatively and poses a technical difficulty during surgery. The reported incidence of confirmed pre-operative diagnosis on USG is up to 16.3%,<sup>3</sup> but was unable to detect in our case. In cases of doubtful anatomy, further investigations like CT scan and MRCP should be done.<sup>11</sup>

Change in port sites had also been advocated with little lateral placement of the dissecting ports, which reduces the difficulty during dissection.<sup>12</sup> We had not changed the port positions in our case but divided the falciform ligament early which created more room for dissection. The similar observation is reported earlier also.<sup>13</sup>

Awareness about these anomalies improves the success rates of safe laparoscopic surgery (reported incidence = 79.6%). The incidence of biliary injuries up to 7.3% is noted. The implications of this anomaly are considerable if liver resection/transplantation is planned.<sup>2</sup> Majority of case report suggested antegrade techniques of cholecystectomy and the retrograde method is reported to be used in 16.7% cases in one study.<sup>3</sup> Antegrade dissection and intra-operative cholangiogram are advocated to avoid chances of biliary injury.<sup>14</sup> It is also suggested that the use of energy source should be limited, and any tubular structure should be carefully inspected before division.<sup>15</sup>

## Conclusion

Awareness about the anomaly and the safe operative techniques reduces the chances of complications in laparoscopic surgery for left-sided gall bladder. Gall bladder should be completely dissected free from its fossa before clipping any tubular structure. Division of the falciform ligament before dissecting gall bladder also aids into creating more room for surgery.

## Declaration of conflicting interests

The author(s) declared no potential conflicts of interest with respect to the research, authorship, and/or publication of this article.

## Ethical approval

Our institution does not require ethical approval for reporting individual cases or case series.

## Funding

The author(s) received no financial support for the research, authorship, and/or publication of this article.

## Informed consent

Written informed consent was obtained from the patient(s) for their anonymized information to be published in this article.

## ORCID iD

Amitabh Yadav  <https://orcid.org/0000-0002-8718-1718>

## References

1. Rafailidis V, Varelas S, Kotsidis N, et al. Two congenital anomalies in one: an ectopic gallbladder with phrygian cap deformity. *Case Rep Radiol* 2014; 2014: 246476.
2. Nguyen TH, Nguyen TS, Van Nguyen PD, et al. Sinistroposition: a case report of true left-sided gallbladder in a Vietnamese patient. *Int J Surg Case Rep* 2018; 51: 82–85.
3. Abongwa HK, De Simone B, Alberici L, et al. Implications of left-sided gallbladder in the emergency setting: retrospective review and top tips for safe laparoscopic cholecystectomy. *Surg Laparosc Endosc Percutan Tech* 2017; 27(4): 220–227.
4. Dhulkotia A, Kumar S, Kabra V, et al. Aberrant gallbladder situated beneath the left lobe of liver. *HPB* 2002; 4(1): 39–42.
5. Banchini F, Ekpo E, Conti L, et al. Left side gallbladder with agenesis of right anterior sector and absence of right hepatic duct: a case report. *Int J Surg Case Rep* 2019; 60: 249–252.
6. Agha R, Borrelli M, Farwana R, et al. The SCARE 2018 statement: updating consensus surgical case report (SCARE) guidelines. *Int J Surg* 2018; 60: 132–136.
7. Mattone E, Latteri S, Teodoro M, et al. Dystopic retrohepatic gallbladder and cholecysto-choledocholithiasis: the rendez-vous and indocyanine green fluorescence. *Clin Case Rep* 2018; 6(3): 522–526.
8. Saafan T, Hu JY, Mahfouz AE, et al. True left-sided gallbladder: a case report and comparison with the literature for the different techniques of laparoscopic cholecystectomy for such anomalies. *Int J Surg Case Rep* 2018; 42: 280–286.
9. Popli MB, Popli V and Solanki Y. Ectopic gall bladder: a rare case. *Saudi J Gastroenterol* 2010; 16(1): 50
10. Iskandar ME, Radzio A, Krikhely M, et al. Laparoscopic cholecystectomy for a left-sided gallbladder. *World J Gastroenterol* 2013; 19(35): 5925–5928.
11. Faure JP, Doucet C, Scepi M, et al. Abnormalities of the gallbladder, clinical effects. *Surg Radiol Anat* 2008; 30: 285–290.
12. Mohammed AA and Arif SH. Midline gallbladder makes a challenge for surgeons during laparoscopic cholecystectomy; case series of 6 patients. *Ann Med Surg* 2019; 40: 14–17.
13. Idu M, Jakimowicz J, Iuppa A, et al. Hepatobiliary anatomy in patients with transposition of the gallbladder: implications for safe laparoscopic cholecystectomy. *Br J Surg* 1996; 83(10): 1442–1443.
14. Zoulamoglou M, Flessas I, Zarokosta M, et al. Left-sided gallbladder (Sinistroposition) encountered during laparoscopic cholecystectomy: a rare case report and review of the literature. *Int J Surg Case Rep* 2017; 31: 65–67.
15. Chrungoo RK, Kachroo SL, Sharma AK, et al. Left-sided gall bladder: report of two cases. *J Minim Access Surg* 2007; 3(3): 108–110.