



Case report

A rare case of huge intrathoracic lipomatosis filling the right pleural cavity removed by open thoracic surgery: A case report

Samuel Tesfaye^{a,b}, Bethlehem Abera^b, Abebe Bezabeh^c, Yoseph Solomon Bezabih^{d,*}, Workneh Tesfaye^{a,b}

^a Jimma University, Ethiopia

^b Addis Ababa University, Collage of Health Sciences, Ethiopia

^c General and Cardiothoracic Surgery at Addis Ababa University, Collage of Health Sciences, Ethiopia

^d Debre Markos University, School of Medicine, Department of Surgery, PO Box 269, FCS-ECSA, Debre Markos, Ethiopia



ARTICLE INFO

Keywords:

Lipoma
Lipomatosis
Liposarcoma
Open thoracic surgery
Case report
Ethiopia

ABSTRACT

Introduction and importance: Lipoma is a benign tumor that arises from adipose tissue; subcutaneous fat is the most common site. It is the most common soft tissue tumor in adulthood. They are usually curable with simple excision. They are slow growing and can rarely become cancerous. Lipomatosis is when there are multiple lipomas with different pedicles. Lipomas arising from the thoracic pleura are rare and intrathoracic lipomatosis is exceptionally rare. Here we report a case of huge lipomatosis removed from the right pleural cavity in a 65 years old man.

Case presentation: A 65 years old male from southern region of Ethiopia, presented with shortness of breath associated with chest pain, productive cough, easy fatigability, and dyspnea on exertion. On exams, he had dullness on chest percussion and absent air entry on the right hemichest on auscultation. He had a history of treatment for pulmonary tuberculosis seven years back. Chest CT showed huge lobulated heterogeneous mass in the right pleural space with significant mediastinal shift to the left. All the large and small masses were removed by a thoracotomy and the specimen was subjected to histopathology examination which revealed myxoid lipoma.

Discussion: Lipoma is a benign tumor with no risk of malignant transformation. Intrathoracic lipoma is quite rare that we don't really find much reported cases.

Conclusion: Intrathoracic lipomatosis is a rare condition that progresses without symptoms until it reaches a big size, at which point compressive symptoms appear. The primary approach for both diagnostic and therapeutic purposes continues to be surgical resection.

1. Background

Lipoma is a benign soft tissue tumor that arises from adipose tissue. Subcutaneous fat is the most common site of lipoma development, but pleura are rare sites of origin [1]. Intrathoracic lipoma remains asymptomatic until it is very large to cause a compression effect on adjacent structures. Nevertheless, it can also be identified incidentally with a chest x-ray or CT scan done for other purposes. Resection of intrathoracic lipoma must be made to relieve symptoms from the compression effects as well as for a definitive diagnosis to be made with a histopathologic study [2].

Below we present a 65 years old male who presented with shortness of breath associated with chest pain, productive cough, easy fatigability,

and dyspnea on exertion. A contrast-enhanced chest CT scan revealed a huge intrathoracic mass filling the right pleural cavity. The mass was resected using a right-side open thoracotomy. This case is reported in line with the SCARE criteria [3]. We believe that by sharing this report, surgeons will be better informed about a rare intrathoracic mass that they may encounter in practice. We will go through the role of imaging in the diagnosis of intrathoracic lipoma, and treatment of intrathoracic lipoma in affected patients.

2. Case presentation

The patient is a 65 years old male farmer from the southern region of Ethiopia who presented with shortness of breath of one-year duration

* Corresponding author.

E-mail address: josephsol87@gmail.com (Y.S. Bezabih).

<https://doi.org/10.1016/j.ijscr.2022.107565>

Received 5 August 2022; Received in revised form 16 August 2022; Accepted 25 August 2022

Available online 1 September 2022

2210-2612/© 2022 The Author(s). Published by Elsevier Ltd on behalf of IJS Publishing Group Ltd. This is an open access article under the CC BY-NC-ND license (<http://creativecommons.org/licenses/by-nc-nd/4.0/>).

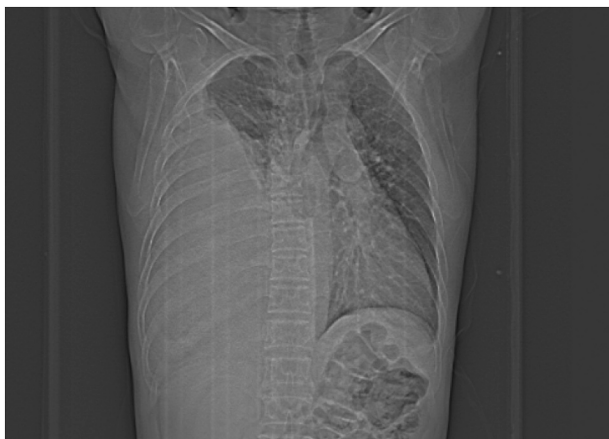

Fig. 1. Plain film showing huge opacity of the right hemi-chest.

that was associated with chest pain, productive cough and easy fatigability. He was comfortable as long as he is resting and not on exertion. He was treated for pulmonary tuberculosis seven years back. On exams his vital signs were within the normal range. Examination of the chest revealed stony dullness percussion note accompanied by absent air entry on right hemi-chest upon auscultation. Otherwise other systemic examinations were unremarkable.

His complete blood count and comprehensive metabolic panel parameters were all within the normal range. Echocardiography was also done and it was normal. A chest CT was recommended for a more accurate description of the finding after a plain chest x-ray revealed a significant opacification over the left hemi-chest (Fig. 1). Chest CT showed a huge lobulated heterogeneous mass predominantly fat attenuating with areas of internal solid components in the right pleural space. Mass effect causing significant mediastinal shift and right middle lobe compressive atelectasis were noted (Fig. 2).

The patient was admitted to the surgical ward following informed written consent. He underwent a pre-anesthetic assessment, an ICU bed was reserved, and then he was taken to the operation theater. An epidural catheter was inserted for the administration of analgesics. He was given general anesthesia and intubated with a double lumen endotracheal tube. After having an arterial line and central line inserted, the patient was then placed in the left lateral position. The right pleural

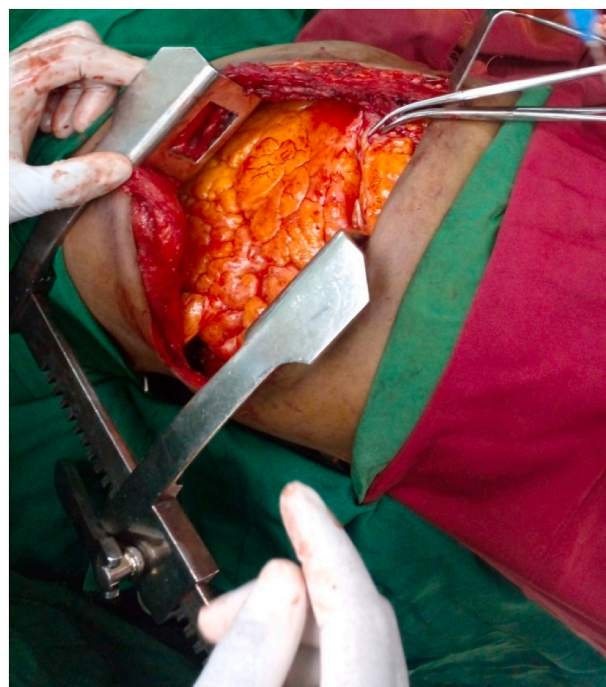

Fig. 3. Intraoperative picture showing the mass in the right pleural cavity.

cavity was approached through a right postero-lateral thoracotomy. The intraoperative finding was a large fatty mass that filled the whole right pleural cavity which put a pressure on the lung and mediastinum (Fig. 3), along with numerous small-sized lipomas that were dispersed throughout the parietal and visceral pleura. The largest mass had a pedicle attached to the costal part of parietal pleura just lateral to the sternum; around 7th intercostal space (Fig. 4).

The main mass was detached from the pleura by dividing its pedicle (Fig. 5), and the smaller masses were removed without difficulty (Fig. 6). During surgery, it was seen that the right lung was expanding after the removal of the huge mass, except for the right lower lobe, which had developed compressive atelectasis. There was no feature that nearby structures had been infiltrated by the mass. The chest was closed and the specimen was sent for histopathology.

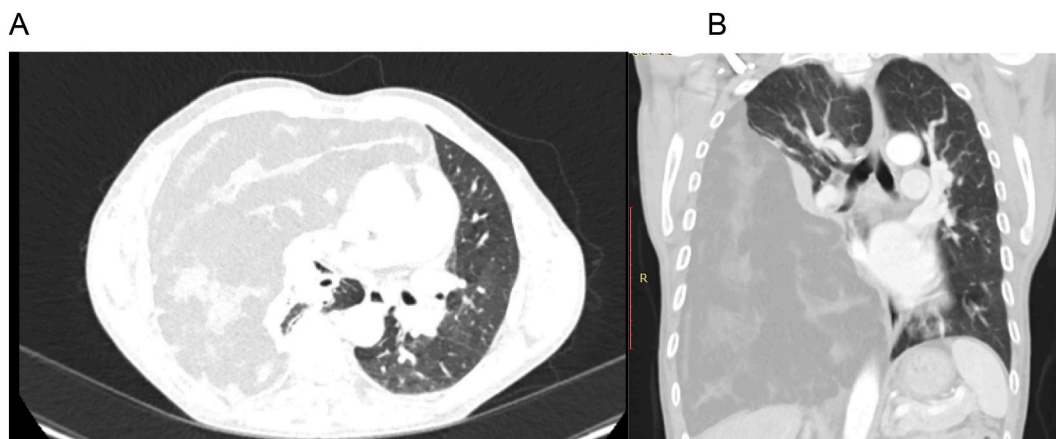


Fig. 2. Contrast chest CT showing large fat attenuating mass filling the right pleural cavity with significant mediastinal shift: A- axial view and B- coronal view.

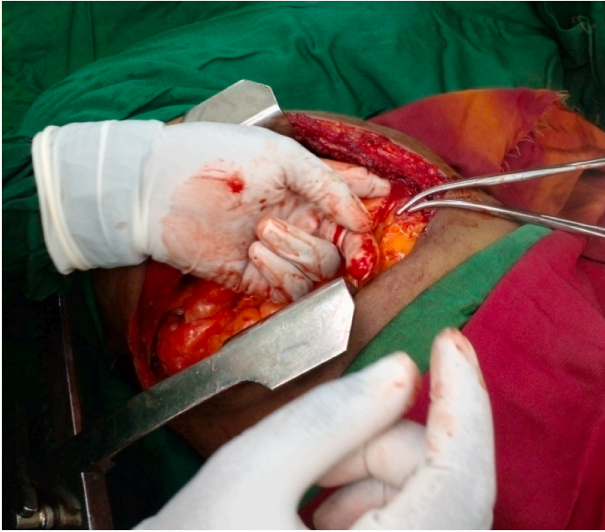


Fig. 4. Intraoperative picture showing the pedicle of the largest lipoma.

The postoperative recovery process was uneventful. After being monitored for 5 days, the patient was sent home after showing improvement. He was examined in the follow-up clinic a few weeks after being discharged, and he was doing well. He experienced neither shortness of breath nor easy fatigability, and his recovery went smooth. Myxoid Lipoma was identified as the pathologic finding (Fig. 7).

3. Discussion

Lipoma is a benign tumor with no risk of malignant transformation. It is slow growing. Symptoms are usually from local compression effect

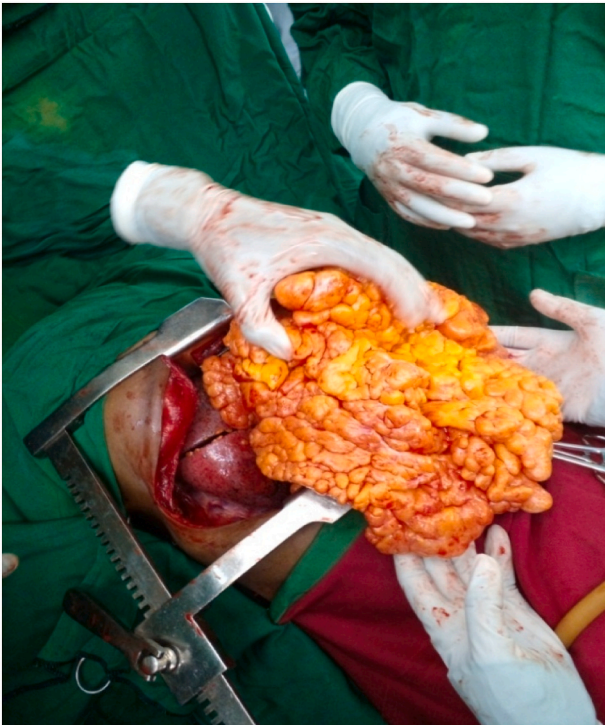

Fig. 5. Intraoperative picture shows the largest mass removed just by dividing the pedicle.

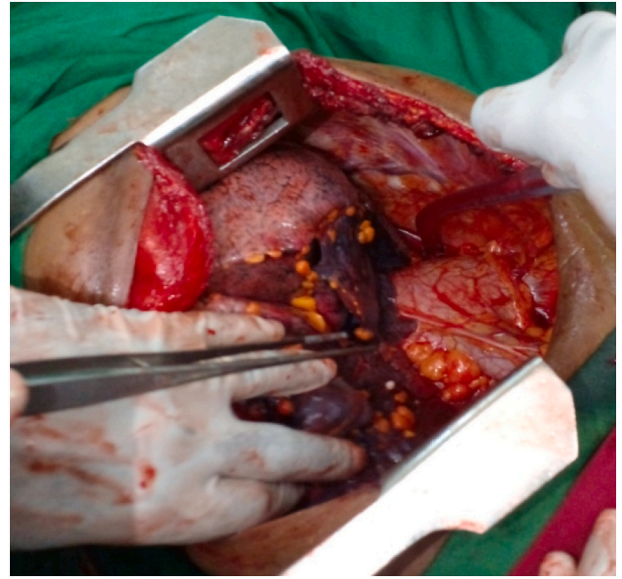

Fig. 6. Intraoperative picture showing small multiple lipomas deposited on the visceral and parietal pleura including the mediastinal pleura.

as it is not locally infiltrative. Most have a size of less than 5 cm in diameter [4]. In our patient, the largest lipoma was unusually very large; measuring around 25 * 17 * 15 cm. Excision is the mainstay of management.

Intrathoracic lipoma is quite rare that we don't really find much reported cases. The first description of intrathoracic lipoma was made by Fothergill in 1781 [5]. Since it is usually asymptomatic, it grows till it attains a very large size and cause compression effect. In our patient also, the mass was huge enough to displace all adjacent structures away. The latest case reported was by Mohammed Aldahmashi et al., in 2019. They reported a large intrathoracic lipoma measuring 25 * 20 * 10 cm compressing the right lung and diaphragm as well as the liver. The patient was symptomatic and the diagnosis was settled by a chest CT which should a fatty consistency of the mass. It was removed by a conventional posterolateral thoracotomy. The specimen was subjected to histopathology and it was confirmed to be a fibrolipoma. After the surgery, the patient was quite well [6].

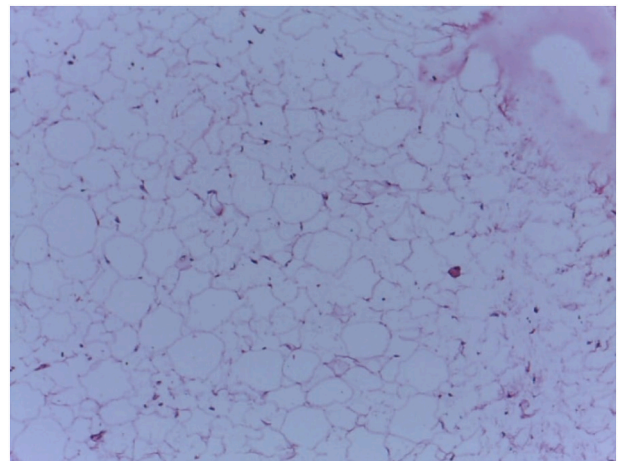


Fig. 7. Microsection reveals adipose tissue fragment comprised of sheets of mature adipocyte having bland appearing eccentric nuclei.

CT scan of the chest gives us detailed information about the site, size and consistency of the mass. Lipoma has attenuation coefficients of -50 to -150 Hounsfield units [5]. Nevertheless, lipoma has nonhomogeneous appearance which makes it difficult to differentiate it from well differentiated liposarcoma preoperatively [7]. For this reason, once the diagnosis is made by imaging, it is advised to make excision in all patients; given that they are fit for surgery. Histologically, lipoma is characterized by abundant mature adipose tissue with no mitotic activity and normal fibro-connective tissue in between [5].

Intraoperative finding is usually fatty mass that is well circumscribed and lobulated. It usually doesn't have adhesion with adjacent structures. This is exactly what we saw in our case. The mass was large and lobulated. It had a pedicle attached to the costal pleura close to the sternum around the 7th intercostal space. This is similar with the finding of Ming Chen et al. They reported that the mass was large occupying more than 75 % of the hemi chest having a pedicle at level of 7th rib [8].

The mainstay of management for intrathoracic lipoma is resection. The definitive diagnosis is with histopathologic study; therefore resected specimen must be subjected to analysis. Definitive diagnosis is difficult to make with imaging only so surgery must be done [9]. Resection is curative and the risk that the disease will come back again is very rare. Sometimes, if the diagnosis lipoma is settled preoperatively with biopsy, it might be acceptable to delay surgery and follow patients conservatively [10]. These are more appropriate if patients are very old, friable and not fit for surgery. If it is decided to follow patients conservatively, it is good to check development of any signs of mass effect and imaging must be done serially to follow its growth [11].

4. Conclusion

Generally, intrathoracic lipoma is a very rare condition. Mostly, the diagnosis is made incidentally. If symptoms occur, they are usually due to compression effect. Thoracotomy and resection of the mass is almost always advised as it is both diagnostic and therapeutic. This case report presents one very rare condition therefore it will give surgeons an insight about its existence. This way, they will keep it in the back of their head as a differential when they evaluate patients with intra-thoracic mass. This paper will also be an added data for the scientific literature in studying rare conditions.

Funding

This research did not receive any specific grant from funding agencies in the public, commercial, or not-for-profit sectors.

Ethical approval

For the publication of a case report at our institution, ethical approval is not necessary.

Consent

Written informed consent was obtained from the patient for publication of this case report and accompanying images. A copy of the written consent is available for review by the Editor-in-Chief of this journal on request.

Author contribution

Samuel Tesfaye (Principal Investigator): Conceptualization, Methodology, Writing - Original draft.

Bethlehem Abera: Conceptualization, Methodology, Writing - Original draft.

Abebe Bezabeh: Writing - Review & editing.

Yoseph Solomon: Writing - Review & editing

Workneh Tesfaye: Writing - Review & editing.

Research registration

Not applicable.

Guarantor

Yoseph Solomon Bezabih.

Provenance and peer review

Not commissioned, externally peer-reviewed.

Declaration of competing interest

None.

References

- [1] J. Tseung, Robbins and Cotran Pathologic Basis of Disease, LWW, 2005.
- [2] J. LoCicero, Shields' General Thoracic Surgery, Lippincott Williams & Wilkins, 2018.
- [3] R.A. Agha, et al., The SCARE 2020 guideline: updating consensus surgical CAse REport (SCARE) guidelines, *Int. J. Surg.* 84 (2020) 226–230.
- [4] F. Brunicaudi, et al., Schwartz's Principles of Surgery, 10e, McGraw-Hill, 2014.
- [5] P. Mathur, et al., Pleural lipoma, *Int. J. Respir. Pulm. Med.* 4 (2017) 069.
- [6] M. Aldahmashi, et al., The largest reported intrathoracic lipoma: a case report and current perspectives review, *J. Cardiothorac. Surg.* 14 (1) (2019) 1–5.
- [7] S. Jaovisidha, et al., MR imaging of fat-containing tumours: the distinction between lipoma and liposarcoma, *Singap. Med. J.* 51 (5) (2010) 418.
- [8] M. Chen, et al., Intrathoracic giant pleural lipoma: case report and review of the literature, *J. Cardiothorac. Surg.* 8 (1) (2013) 1–4.
- [9] E. Akar, M. Haberal, O. Dikis, Diagnostic and therapeutic treatment methods for intrathoracic extrapulmonary lipomas, *Niger. J. Clin. Pract.* 23 (5) (2020) 626–630.
- [10] A. Menon, C. Marchand, A. Medford, Intrapleural lipoma mimicking a lung cancer, *QJM* 108 (8) (2015) 649–650.
- [11] J. Hwang, et al., Deep-seated intramuscular lipoma penetrates the intercostal muscle, *J. Thorac. Dis.* 7 (10) (2015) E493.