

# A Novel Treatment of Denuded Areas in Newborns: A Report of 2 Successful Cases

Jennifer Gaona, MD\*†‡§  
 Felipe Milanés, MD¶  
 Teresa Vergara, MD¶  
 Laura Lara, MD§  
 Andres Duran, BsM, MSc||  
 Adriana Robayo, BsM||

**Summary:** Covering denuded areas in the extremes of life is challenging for the plastic surgeon. In newborns, this becomes a greater challenge because of the immaturity of all of their systems, making any injury a potential risk for death. We present in this case report a successful treatment of 2 cases covered with cultured autologous keratinocytes. In this procedure, a small skin biopsy is taken from the retroauricular area and the keratinocytes are cultured. After 5 days, a membrane with the cells cultured is applied covering the denuded area. We find the autologous keratinocyte method a suitable option for the treatment of denuded areas in newborns, without causing any additional morbidity and in a very short period of time. (*Plast Reconstr Surg Glob Open* 2015;3:e523; doi: 10.1097/GOX.0000000000000448; Published online 23 September 2015.)

Newborns are a special group of population characterized by their complex physiology, which allows either a rapid and satisfactory recovery or a fast deterioration. Their immature systems and recent change of environment at the moment of birth make the treatment of any pathology a significant challenge due to the fact that any type of injury can potentiate the risk of death. Skin lesions in neonates have several etiologies, including genetic diseases, trauma, or even iatrogenic. The appropriate and early management of such defects has a great importance given the cutaneous barrier protagonism in terms of corporal body surface of the newborn and includes supportive treatment and either conservative management or surgery of any given skin defect.

Skin dermis substitutes and acellular cultures are methods that provide an adequate epithelialization while maintaining normal characteristics of skin. There are very few reports in the medical literature that describe and evaluate the use of dermis substitutes for the coverage of skin lesions in neonates. Nevertheless, they are presented as a suitable reconstruction alternative for all types of tissues and an available option for the coverage of denuded areas.

Among the research of the literature regarding the use of skin substitutes in neonates, there is one report describing the use of Apligraf (Organogenesis, Canton, Mass.) for the management of epidermolysis bullosa.<sup>1</sup> In this article, they also describe 2 reports of the unsuccessful use of keratinocytes allograft for the management of skin defects.<sup>1</sup> In a different study, Knauth et al<sup>2</sup> report the use of a semipermeable polyurethane membrane as artificial skin in a preterm newborn. Another article describes the applicability of Hyalomatrix PA (Anika Therapeutics, Bedford, Mass.) in the treatment of denuded areas due to fluid extravasation in preterm babies.<sup>3</sup> Two reports were found in which Integra (Integra LifeSciences Corp., Plainsboro, N.J.) was used in the management of skull and scalp defects in neonates with Adams-Oliver syndrome<sup>4</sup> and another in which they report a pediatric series of cases including 3 newborns, one with congenitally absent cranium, an-

From the \*Escuela de Medicina, Juan N. Corpas, Bogotá, Colombia; †Pontificia Universidad Javeriana, Bogotá, Colombia; ‡Hospital Central de la Policía, Bogotá, Colombia; §Hospital Simón Bolívar, Bogotá, Colombia; ¶Universidad Nuestra Señora del Rosario, Bogotá, Colombia; and ||Department of Biomedical Engineering, Andes University, Bogotá, Colombia.

Received for publication December 5, 2014; accepted June 11, 2015.

Copyright © 2015 The Authors. Published by Wolters Kluwer Health, Inc. on behalf of The American Society of Plastic Surgeons. All rights reserved. This is an open-access article distributed under the terms of the Creative Commons Attribution-Non Commercial-No Derivatives License 4.0 (CCBY-NC-ND), where it is permissible to download and share the work provided it is properly cited. The work cannot be changed in any way or used commercially.

DOI: 10.1097/GOX.0000000000000448

**Disclosure:** The authors have no financial interest to declare in relation to the content of this article. The Article Processing Charge was paid for by the authors.

other with meningomyelocele, and a third with cutis aplasia.<sup>5</sup> One case report was found in which Integra was used for reconstruction posterior to thrombectomy for neonatal ischemia in the extremities.<sup>6</sup> Lastly, there are 3 successful cases reported using AlloDerm (LifeCell Corp., Bridgewater, N.J.) for the treatment of omphalocele.<sup>7-10</sup>

Keraderm (Keraderm, Bogotá, Colombia)<sup>11</sup> is a culture of autologous keratinocytes and fibroblasts in autologous plasma and serum, grown in a collagen membrane that allows easy placing over the denuded area. The purpose of this autologous keratinocyte graft is to achieve complete coverage of skin defects avoiding autologous skin grafts and the pain that a donor site produces.

The cultured autologous keratinocyte sheets should be applied to a wound bed that is ready for grafting, so an adequate recipient bed with satisfactory granulation tissue will optimize the process.

Being a cellular culture, a skin sample is required, and it can be performed in an uncomplicated process: a thin skin sample measuring 5 mm × 5 mm is collected from any anatomical area and a blood sample from the patient. Cells are cultured in autologous serum and incubated, and 5–7 days after the sample is collected, the keratinocyte sheets are ready for grafting. It is noticeable that the entire process is simple and practical and does not require a surgical intervention unless special circumstances are present.

In this report, we describe 2 cases in which Keraderm sheets were used to cover denuded areas in neonates: one with an extravasation injury and the second case with a burn by boiling liquid.

### CASE 1

Female preterm newborn, 36 weeks gestation, who required hospitalization in the pediatric intensive care unit for neonatal adaptation. During the hospital stay, she suffered focal ischemia related to intravenous fluid

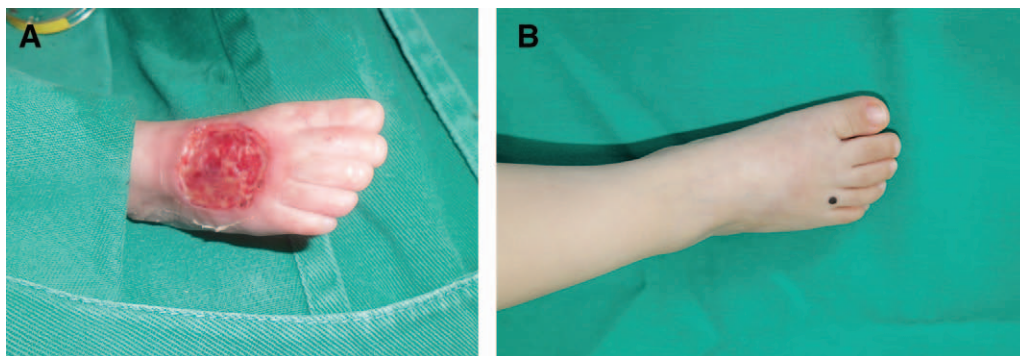
extravasation in the dorsum of the right foot, which led to skin necrosis. The skin sample was collected, and after 7 days (corresponding to the 22nd day after birth), surgical debridement was performed and the lesion was covered with the autologous keratinocyte sheet. After 5 days, the surgical area was evaluated, finding partial epithelialization. A complete epithelialization was obtained 15 days after the cultured keratinocyte sheet placement. During the process, the patient never demonstrated signs of infection, hypersensitivity reactions, or systemic deterioration. After 1-year follow-up, the resulting scar was considered favorable, given its flexibility, no retractions, and without movement limitations of the toes. The patient developed a mole on the fourth toe, but we believe that this finding is not related to the treatment and it is under follow-up (Fig. 1).

### CASE 2

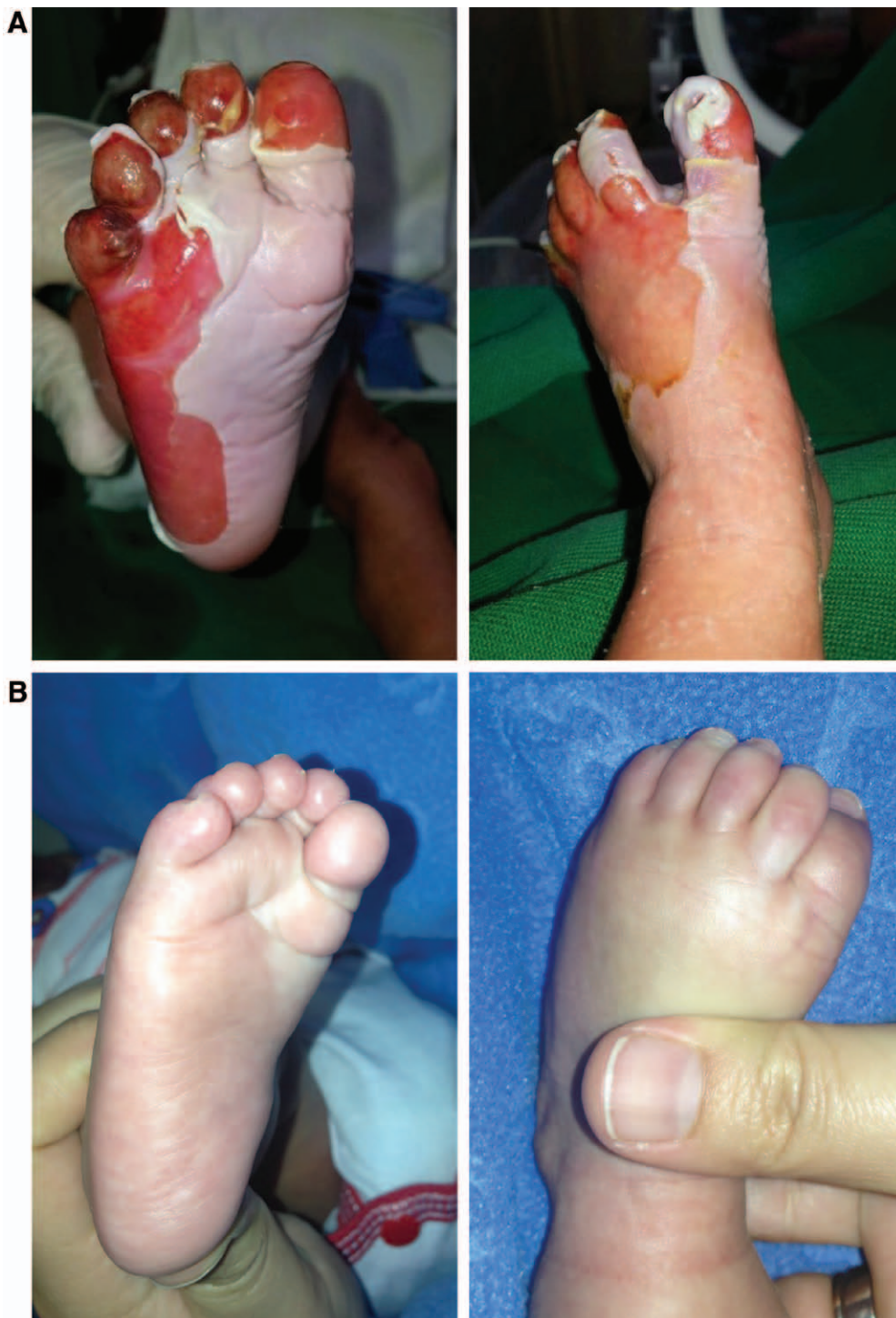One-day-old newborn who suffered a superficial and deep second-grade scalding burn in both feet, with compromise of fourth and fifth toes of the right foot. Initially, a conservative management was implemented, consisting of periodical dressing changes to favor debridement. The first surgical debridement was performed at 7 days when the skin and blood samples were collected and the autologous keratinocyte sheet was fabricated. After 7 days, coverage of skin defects with cultured keratinocytes was present. The first evaluation was made 5 days after the placement of the keratinocyte graft, in which partial epithelialization was encountered, accompanied by scarce serous secretion. Two days later (7 days after sheet placement), the surgical area was reevaluated, finding complete epithelialization. After 1-year follow-up, the scar was considered favorable, found to be compliant, and without hypertrophy or retractions (Fig. 2).

### DISCUSSION AND CONCLUSIONS

Human skin is a complex organ and has vital functions: it acts as a barrier, provides mechanical protection against potentially infectious agents, and also prevents dehydration produced by the loss of body water. In neonates, the permanence of these



**Fig. 1.** A, Aspect of the injury generated by intravenous fluid extravasation. Surgical debridement and keratinocyte sheet placement. Aspect 5 days after surgery. B, Aspect of the scar after 1 year, with evidence of an excellent scar.



**Fig. 2.** A, Seven-day-old patient with deep second-grade scalding burns in feet. Surgical debridement and keratinocyte sheet placement. B, One-year follow-up with adequate scar and with no evidence of functional limitation.

characteristics must be guaranteed, as they are more susceptible than adults to any injury due to the immaturity of all body systems. It is for this reason that the dermal substitutes become a favorable and effective option for covering denuded areas that may

arise due to various etiologies, allowing coverage of the lesions without generating new skin injuries or wounds, as in the case of autologous skin grafts.

With cultured autologous keratinocyte sheets, an early coverage is achieved, mechanical barrier

protection is reestablished, and at the same time, it resembles the biological properties of the organ. Additionally, the procedure to obtain the samples to elaborate the keratinocyte sheets is relatively simple, minimally invasive (which considerably diminishes trauma and pain), does not require extensive donor areas, reduces surgical time or even makes it nonexistent, and does not present hypersensitivity reactions or rejections because it is an autologous tissue.

We present the report of 2 neonatal cases with denuded areas in the lower limbs treated with cellular cultures, obtaining an epithelialization time of approximately 7 days, who did not require major surgical intervention. The subjective evaluations of the resulting scars demonstrate excellent outcomes, without scar contraction or functional limitation.

A detailed search of the published literature showed no successful cases reported of skin defects in neonates managed with cellular cultures. We argue that this report shows that this treatment is a feasible, viable, and effective option, allowing an early closure of the wound without any pain or additional scars. We also believe that this technique avoids the comorbidity that a secondary intention healing presents as well as the need of harvesting a split-thickness graft, properties that are extremely important, especially in this group of patients.

**Jennifer Gaona, MD**

Pontificia Universidad Javeriana

Juan N. Corpas, Bogotá

Colombia

E-mail: info@gaonazambrano.com

## REFERENCES

1. Falabella AF, Schachner LA, Valencia IC, et al. The use of tissue-engineered skin (Apligraf) to treat a newborn with epidermolysis bullosa. *Arch Dermatol.* 1999;135:1219–1222.
2. Knauth A, Gordin M, McNelis W, et al. Semipermeable polyurethane membrane as an artificial skin for the premature neonate. *Pediatrics* 1989;83:945–950.
3. Onesti MG, Carella S, Maruccia M, et al. The use of hyalomatrix PA in the treatment of extravasation affecting premature neonates. *Plast Reconstr Surg.* 2012;129:219e–221e.
4. Khashab ME, Rhee ST, Pierce SD, et al. Management of large scalp and skull defects in a severe case of Adams-Oliver syndrome. *J Neurosurg Pediatr.* 2009;4:523–527.
5. Ghazi B, Williams J. Use of Integra in complex pediatric wounds. *Ann Plast Surg.* 2011;66:493–496.
6. Orfaniotis G, Watson SB. Surgical management of neonatal limb ischaemia: a technique for open thrombectomy and the novel use of Integra. *J Plast Reconstr Aesthet Surg.* 2013;66:1142–1144.
7. Alaish SM, Strauch ED. The use of Alloderm in the closure of a giant omphalocele. *J Pediatr Surg.* 2006;41:e37–e39.
8. Almond SL, Goyal A, Jesudason EC, et al. Novel use of skin substitute as rescue therapy in complicated giant exomphalos. *J Pediatr Surg.* 2006;41:e1–e2.
9. Kapfer SA, Keshen TH. The use of human acellular dermis in the operative management of giant omphalocele. *J Pediatr Surg.* 2006;41:216–220.
10. Dyer JA. Newborn skin care. *Semin Perinatol.* 2013;37:3–7.
11. Gaona J, Zambrano JC, Nieto LE. Estandarizacion del metodo de cultivo de queratinocitos autologos en suero autologo para el cubrimiento de areas cruentas. *Revista de la Sociedad Colombiana de Cirugía Plástica.* 2009;15(2):43–47.