



RESEARCH

Open Access

The effect of low level laser on condylar growth during mandibular advancement in rabbits

Mostafa Abtahi¹, Maryam Poosti^{2*}, Nasrollah Saghravanian³, Kamran Sadeghi¹ and Hooman Shafae¹

Abstract

Introduction: It has been shown that Low Level Laser (LLL) has a positive effect on bone formation. The aim of this study was to evaluate the effect of low level laser on condylar growth during mandibular advancement in rabbits.

Materials and methods: Continuous forward mandibular advancement was performed in fourteen male Albino rabbits with the mean age of 8 weeks and the mean weight of 1.5 ± 0.5 kg, with acrylic inclined planes. The rabbits were randomly assigned into two groups after 4 weeks. LLL (KLO3: wave length 630 nm) was irradiated at 3 points around the TMJ, through the skin in the first group. The exposure was performed for 3 minutes at each point (a total of 9 minutes) once a day for 3 weeks. The control group was not exposed to any irradiation. The rabbits in both groups were sacrificed after two months and the histological evaluation of TMJ was performed to compare fibrous tissue, cartilage, and new bone formation in condylar region in both groups. Disc displacement was also detected in both groups. Student's t-test, Exact Fisher and Chi square tests were used for the statistical analysis.

Results: The formation of fibrous tissue was significantly lower, while bone formation was significantly greater in lased group as compared with control group. The thickness of cartilage did not differ significantly between two groups.

Conclusion: Irradiation of LLL (KLO3) during mandibular advancement in rabbits, increases bone formation in condylar region, while neither increase in the cartilage thickness nor fibrous tissues was observed.

Keywords: Low level laser, rabbit, bite jumping, condyle

Introduction

The Class II malocclusion has been called the most frequent skeletal problem in the orthodontic practice [1,2]. The solution can involve the use of functional or fixed orthodontic appliances, or both [3]. It has been claimed that the most frequent skeletal problem in Class II patients is mandibular retrognathia [4,5]. In the treatment of Class II malocclusion, capability to alter patients' facial growth is of particular interest, namely by means of functional appliances [6,7]. The findings from animal and human studies have been accepted as evidence that functional appliances can stimulate condylar [8-10] or mandibular growth, [11,12] and are able to make changes in the underlying skeletal pattern of the patient. Therefore the success of

Class II treatment with mandibular deficiency depends on the ability of functional appliances to encourage condylar growth.

Quantitative histological studies have clarified the time-dependent nature of the adaptive response, indicating that the initial large changes in cartilaginous proliferation are progressively diminished when restoration of functional equilibrium is obtained [13].

The development of technologies capable of accentuating the growth potential of mandibular cartilage could allow our profession to predictably accelerate the growth phenomena of this tissue. One stimulus capable of improving this process is the application of low-intensity pulsed ultrasound [14,15].

Recently, low-level laser was used to enhance bone healing after fracture [16,17], after mandibular distraction osteogenesis [18,19] and also for condylar growth

* Correspondence: poustimaryam@yahoo.com

²Orthodontic Dept, School of Dentistry, Islamic Azad University, Tehran, Iran
Full list of author information is available at the end of the article

stimulation [20]. The results suggest that Low level laser therapy (LLLTT) had a positive effect on the percentage of newly formed bone. Better-quality bone sites may allow early healing, thus shortening total treatment time.

Considering the positive effects of LLLTT on bone regeneration and the common tendency of shortening treatment period in orthodontics, the aim of the present study was to evaluate the effect of low level laser on condylar growth during mandibular advancement in rabbits. Our hypothesis was that LLLTT could increase bone formation during mandibular advancement.

Materials and methods

This study was approved by ethical committee of Mashhad University of Medical sciences. (Code: 88349). Fourteen male white Albino rabbits with the mean age of 8 weeks and the mean weight of 1.5 ± 0.5 kg were selected. All the animals had intact central incisors in the upper and lower arch. Under general anesthesia (intramuscular injection of 1 ml Xylazine and Ketamin with 1:2 ratio) primary impressions were obtained from maxilla and after constructing special trays secondary impressions were taken and plaster models were made. Identical acrylic inclined planes were constructed for the anterior teeth of rabbits, to serve as functional appliances and create continuous forward mandibular advancement. These appliances were bonded to upper central incisors by self cure composite. (Figure 1)

Following bonding the bite jumper appliance, rabbits were randomly assigned into two groups of seven. In the first group 630 nm low level laser with 10 mw power and a probe diameter of 0.8 mm (KLO3 Mustang2000, Russia) possessing a continuous mode, was irradiated at 3 points around the TMJ, through the skin from the end of the 3rd week after bite jumping [21]. Exposure was performed for 3 minutes [22] at each point (a total of 9 minutes) once a day for 3 weeks [23].

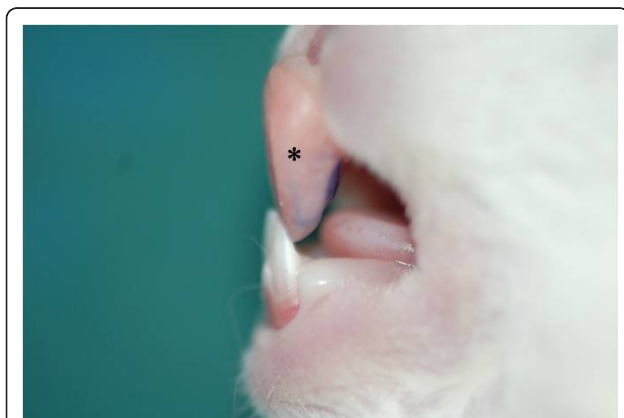


Figure 1 bite jumper appliance.

The control group was not exposed to any irradiation. After two months the rabbits in both groups were sacrificed by vital perfusion, the mandibles were dissected and fixed in formaldehyde 4%, decalcified in EDTA for 60 days and then embedded in paraffin. Serial sections from TMJ including condyle and glenoid fossa were cut sagittally with 4-5 μ m diameter, and stained with hematoxylin and eosin (H&E) to determine the following criteria:

- 1- Maximum thickness of condylar fibrous tissue. (The number of fibroblasts and collagen bundles were determined in tissue; extensive separation of fibroblasts by abundant collagen was considered as Fibrosis.) [24]
- 2- Minimum thickness of condylar fibrous tissue
- 3- Maximum thickness of condylar cartilage
- 4- Minimum thickness of condylar cartilage
- 5- Maximum thickness of condylar new bone
- 6- Minimum thickness of condylar new bone
- 7- Disc displacement

The sections were evaluated blindly under a light microscope (Leica BME) with $\times 100$ magnification. The photograph of each section was taken and saved as a digital file, and then analyzed by Adobe Photoshop CS2 software (Adobe System Incorporated, USA). (Figure 2). The bone interconnected to cartilage considered as new bone. The power calculation for different variables to confirm the reliability of the study was performed.

After the normal distribution of data was confirmed by Kolmogorov-Smirnov test the data were analyzed by Student t-test, Exact Fisher and Chi square tests.

Results

The power calculation for different variables included a follow: maximum condylar fibrous: 0.99, minimum condylar fibrous: 0.70, maximum condylar cartilage: 0.35, minimum condylar cartilage: 0.12, maximum new bone: 1, minimum new bone: 1. The power of our study for bone formation and condylar cartilage was above 80% which was completely acceptable.

The results show that maximum and minimum fibrous tissue thickness in condylar region are statistically greater in control group as compared to laser group ($p < 0.05$), while maximum and minimum thickness of new condylar bone is statistically greater which shows more bone formation in the laser group ($p < 0.01$). There was no statistically significant difference found in the maximum and minimum of new cartilage formed in the condylar area ($p > 0.05$). (Table 1)

Discussion

In this study we clearly demonstrated the stimulatory effects of 630 nm low level KLO3 laser irradiation on

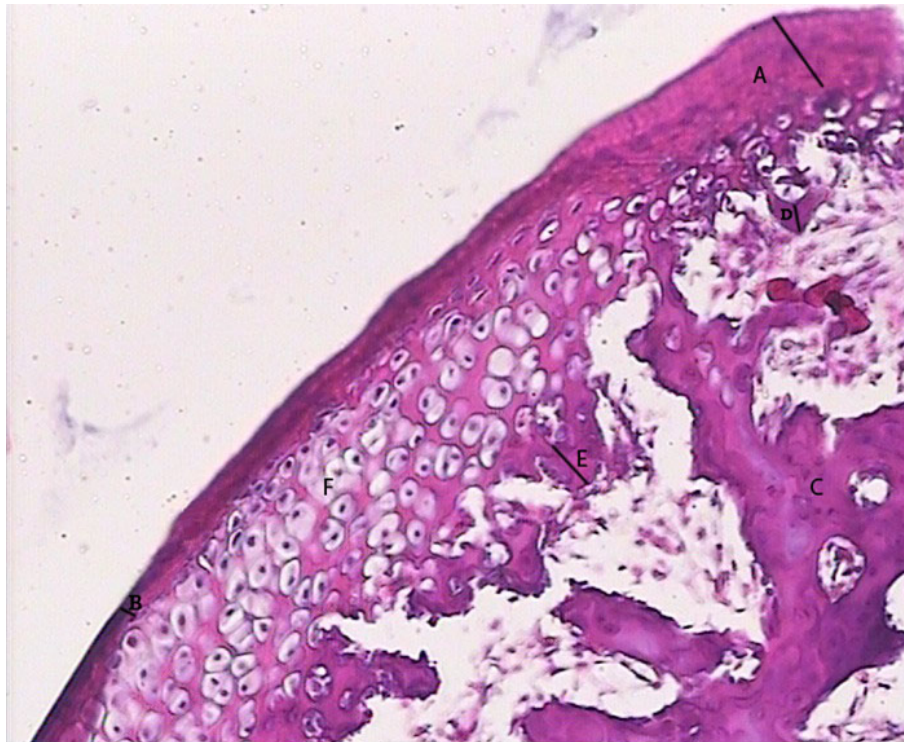


Figure 2 A: Maximum thickness of condylar fibrous tissue B: Minimum thickness of condylar fibrous tissue C: old bone D: Minimum thickness of condylar new bone E: Maximum thickness of condylar new bone F: hypertrophic chondrocytes.

bone formation in condylar region during mandibular advancement in rabbits. The data of this study suggests that newly formed bone was significantly increased by 3 weeks irradiation around TMJ during employing bite jumper appliance.

Rabie *et al* have shown that the best response of TMJ to mandibular advancement and the highest level of bone formation in the glenoid fossa was detected on day 21, so we started our laser irradiation on the third week [21].

Histological examination showed no pathological changes such as bone resorption in condylar area, and lower fibrous tissue formation in lased group indicates lower inflammation established in this group. Statistically significant greater amounts of bone were observed in the experimental group which strongly indicates that application of LLL accelerates the maturation of new bone tissue.

Miloro *et al* found that LLL accelerates the process of bone regeneration in the mandibles during the consolidation phase after distraction osteogenesis as compared with control animals [19].

Current theories suggest that transcription of certain nuclear proteins, such as a rhodopsin-kinase enzyme may be photosensitive at certain wavelengths and this may be responsible for the accelerated wound healing capabilities of the LLL [25].

The results of Stein's studies indicate that low-level laser therapy has a biostimulatory effect on human osteoblast-like cells [26] and it could promote

Table 1 Comparison of lased and control group condyles in different variables (mm)

Variable(mm)	Group	Mean	STD	Max	Min	P-value
Max thickness condylar fibrous tissue	L	1.40	0.46	0.90	2.10	0.00
	C	2.99	0.89	2.10	4.50	
Min thickness condylar fibrous tissue	L	0.59	0.25	0.25	1.10	0.014
	C	1.02	0.43	0.60	1.90	
Max thickness condylar cartilage	L	3.73	1.42	1.80	6.80	0.115
	C	4.83	1.41	2.80	7.10	
Min thickness condylar cartilage	L	1.41	0.91	0.75	4.10	0.413
	C	1.74	0.73	0.90	3.10	
Max thickness condylar new bone	L	19.29	1.63	16.20	21.60	0.00
	C	12.24	1.03	9.80	13.10	
Min thickness condylar new bone	L	5.04	0.97	3.50	6.50	0.00
	C	2.25	0.50	1.60	3.20	

proliferation and maturation of human osteoblasts in vitro [27]. Similar conclusions have been obtained by Dörtbudak about the effect of soft diode lasers on osteoblasts derived mesenchymal cells [28].

Liu believes that LLL may accelerate the process of fracture repair or increases the callus volume and bone mineral density, in the early stages of fracture healing [29].

Khadra et al claimed that the application of LLL with a GaAlAs diode laser device can promote bone healing and formation in skeletal defects [30].

Future studies are warranted with larger numbers of animals. Also, further research is needed to determine the precise cellular and biochemical effects of LLL treatment on both hard and soft tissues.

Conclusion

Regarding the findings of this study LLL may prove efficacious in allowing a shorter period of functional therapy. Irradiation of LLL (KLO3) during mandibular advancement in rabbits, increases bone formation in condylar region, while no increase in the cartilage thickness or fibrous tissues was observed. This would provide great benefit to patients, allowing them to avoid the burdens of a prolonged treatment

Acknowledgements

This research was financially supported by research vice chancellor of Mashhad University of Medical Sciences.(Code: 88349)

Author details

¹Orthodontic Dept, School of Dentistry and Dental Research Center, Mashhad University of Medical Sciences, Mashhad, 91735 Iran. ²Orthodontic Dept, School of Dentistry, Islamic Azad University, Tehran, Iran. ³Oral and maxillofacial Pathology Dept, School of Dentistry, Mashhad University of Medical Sciences, Mashhad, 91735 Iran.

Authors' contributions

MA guided the practical parts of animal study and participated in study design, MP participated in the design of the study and prepared the manuscript, NS performed the histological study, KS accomplished the animal study, HS helped with the statistical analysis. All authors read and approved the final manuscript.

Competing interests

The authors declare that they have no competing interests.

Received: 28 September 2011 Accepted: 23 February 2012

Published: 23 February 2012

References

- Sharma JN: Epidemiology of malocclusions and assessment of orthodontic treatment need for the population of eastern Nepal. *World J Orthod* 2009, **10**(4):311-6.
- Celikoglu M, Akpınar S, Yavuz I: The pattern of malocclusion in a sample of orthodontic patients from Turkey. *Med Oral Patol Oral Cir Bucal* 2010, **15**(5):e791-6.
- Remmer KR, Mamandras AH, Hunter WS, Way DC: Cephalometric changes associated with treatment using the activator, the Frankel appliance, and the fixed appliance. *Am J Orthod* 1985, **88**:363-372.
- McNamara JA Jr: Components of class II malocclusion in children 8-10 years of age. *Angle Orthod* 1981, **51**:177-202.
- Staley R: Etiology and prevalence of malocclusion. In *Textbook of Orthodontics*. Edited by: Bishara S. Philadelphia: WB Saunders; 2001:83-96.
- Singh GD, Clark WJ: Localization of mandibular changes in patients with class II division 1 malocclusions treated with twin-block appliances: finite element scaling analysis. *Am J Orthod Dentofacial Orthop* 2001, **119**(4):419-25.
- Clark W: Design and management of Twin Blocks: reflections after 30 years of clinical use. *J Orthod* 2010, **37**(3):209-16.
- Elgoyhen JC, Moyers RE, McNamara JA Jr, Riolo ML: Craniofacial adaptation of protrusive function in young rhesus monkeys. *Am J Orthod* 1972, **62**:469-480.
- Petrovic AG: Mechanisms and regulation of mandibular condylar growth. *Acta Morphol Neerl Scand* 1972, **10**:25-34.
- Ruf S, Baltromejus S, Panchez H: Effective condylar growth and chin position changes in activator treatment: a cephalometric roentgenographic study. *Angle Orthod* 2001, **71**:4-11.
- McNamara JA Jr, Hinton RJ, Hoffman DL: Histologic analysis of temporomandibular joint adaptation to protrusive function in young adult rhesus monkeys (*Macaca mulatta*). *Am J Orthod* 1982, **82**:288-298.
- Rodrigues de Almeida M, Castanha Henriques JF, Rodrigues de Almeida R, Ursi W: Treatment effects produced by Frankel appliance in patients with class II, division 1 malocclusion. *Angle Orthod* 2002, **72**:418-425.
- Kiliaridis S, Engstrom C, Thilander B: The relationship between masticatory function and craniofacial morphology. I. A cephalometric longitudinal analysis in the growing rat fed a soft diet. *Eur J Orthod* 1985, **7**:273-283.
- El-Bialy T, El-Shamy I, Graber TM: Growth modification of the rabbit mandible using therapeutic ultrasound: is it possible to enhance functional appliance results? *Angle Orthod* 2003, **73**:631-639.
- Oyonarte R, Zarate M, Rodriguez F: Low-intensity pulsed ultrasound stimulation of condylar growth in rats. *Angle Orthod* 2009, **79**:964-970.
- Bashardoust Tajali S, Macdermid JC, Houghton P, Grewal R: Effects of low power laser irradiation on bone healing in animals: a meta-analysis. *J Orthop Surg Res* 2010, **5**:1.
- Kazem Shakouri S, Soleimanpour J, Salekzamani Y, Oskuie MR: Effect of low-level laser therapy on the fracture healing process. *Lasers Med Sci* 2010, **25**:73-77.
- Kreisner PE, Blaya DS, Gaiao L, Maciel-Santos ME, Etges A, Santana-Filho M, de Oliveira MG: Histological evaluation of the effect of low-level laser on distraction osteogenesis in rabbit mandibles. *Med Oral Patol Oral Cir Bucal* 2010, **15**:e616-618.
- Miloro M, Miller JJ, Stoner JA: Low-level laser effect on mandibular distraction osteogenesis. *J Oral Maxillofac Surg* 2007, **65**:168-176.
- Seifi M, Maghzi A, Gutknecht N, Mir M, Asna-Ashari M: The effect of 904 nm low level laser on condylar growth in rats. *Lasers Med Sci* 2010, **25**:61-65.
- Rabie AB, Zhao Z, Shen G, Hagg EU, Dr O, Robinson W: Osteogenesis in the glenoid fossa in response to mandibular advancement. *Am J Orthod Dentofacial Orthop* 2001, **119**:390-400.
- Yamaguchi M, Hayashi M, Fujita S, Yoshida T, Utsunomiya T, Yamamoto H, Kasai K: Low-energy laser irradiation facilitates the velocity of tooth movement and the expressions of matrix metalloproteinase-9, cathepsin K, and alpha(v) beta(3) integrin in rats. *Eur J Orthod* 2010, **32**:131-139.
- Rabie AB, Xiong H, Hagg U: Forward mandibular positioning enhances condylar adaptation in adult rats. *Eur J Orthod* 2004, **26**:353-358.
- Scardino M, Swaim S, Sartin E, Hoffman C, Oglivie G, Hanson R, Coolman SL, Davenport E: The effects of omega-3 fatty acid diet enrichment on wound healing. *Veterinary Dermatology* 1999, **10**:283-90.
- Bliizotes M, Murtagh J, Wiren K: Beta-adrenergic receptor kinase-like activity and beta-arrestin are expressed in osteoblastic cells. *J Bone Miner Res* 1996, **11**:820-826.
- Stein E, Koehn J, Sutter W, Wendtlandt G, Wanschitz F, Thurnher D, Baghestanian M, Turhani D: Initial effects of low-level laser therapy on growth and differentiation of human osteoblast-like cells. *Wien Klin Wochenschr* 2008, **120**:112-117.
- Stein A, Benayahu D, Maltz L, Oron U: Low-level laser irradiation promotes proliferation and differentiation of human osteoblasts in vitro. *Photomed Laser Surg* 2005, **23**:161-166.
- Dortbudak O, Haas R, Mallath-Pokorny G: Biostimulation of bone marrow cells with a diode soft laser. *Clin Oral Implants Res* 2000, **11**:540-545.
- Liu X, Lyon R, Meier HT, Thometz J, Haworth ST: Effect of lower-level laser therapy on rabbit tibial fracture. *Photomed Laser Surg* 2007, **25**:487-494.

30. Khadra M, Kasem N, Haanaes HR, Ellingsen JE, Lyngstadaas SP: Enhancement of bone formation in rat calvarial bone defects using low-level laser therapy. *Oral Surg Oral Med Oral Pathol Oral Radiol Endod* 2004, **97**:693-700.

doi:10.1186/1746-160X-8-4

Cite this article as: Abtahi et al.: The effect of low level laser on condylar growth during mandibular advancement in rabbits. *Head & Face Medicine* 2012 **8**:4.

**Submit your next manuscript to BioMed Central
and take full advantage of:**

- Convenient online submission
- Thorough peer review
- No space constraints or color figure charges
- Immediate publication on acceptance
- Inclusion in PubMed, CAS, Scopus and Google Scholar
- Research which is freely available for redistribution

Submit your manuscript at
www.biomedcentral.com/submit

