

## Case report

# Sub-internal limiting membrane hemorrhage treated with intravitreal tissue plasminogen activator followed by octafluoropropane gas injection



Yu-Kang Chou <sup>a, b</sup>, Yi-Ming Huang <sup>b</sup>, Po-Kang Lin <sup>a, b, \*</sup>

<sup>a</sup> Medical Department, National Yang-Ming University, Taipei, Taiwan

<sup>b</sup> Department of Ophthalmology, Taipei Veterans General Hospital, Taipei, Taiwan

## ARTICLE INFO

## Article history:

Received 5 August 2014

Received in revised form

12 October 2014

Accepted 19 October 2014

Available online 4 December 2014

## Keywords:

octafluoropropane

sub-internal limiting membrane

hemorrhage

tissue plasminogen activator

## ABSTRACT

Sub-internal limiting membrane (sub-ILM) hemorrhage is a relatively rare disease which is associated with different etiologies and often leads to loss of visual acuity. We report two cases of sub-ILM hemorrhage, both confirmed by optical coherence tomography (OCT) and treated with an intravitreal injection of tissue plasminogen activator (tPA) followed by an octafluoropropane (C<sub>3</sub>F<sub>8</sub>) pneumopexy and a strict postoperative prone positioning. The hemorrhage was totally resolved and complete visual recovery was achieved in both cases. We found tPA hemolysis with C<sub>3</sub>F<sub>8</sub> pneumopexy to be a safe and effective method for treating sub-ILM hemorrhage.

Copyright © 2014, The Ophthalmologic Society of Taiwan. Published by Elsevier Taiwan LLC. All rights reserved.

## 1. Introduction

Sub-internal limiting membrane (sub-ILM) hemorrhage is an uncommon disease which often leads to severe visual loss. Various causes are reported including Valsalva retinopathy, blood dyscrasia, Terson syndrome, and ocular trauma.<sup>1</sup> Patients with sub-ILM hemorrhage can be observed only without intervention, but the hemorrhage may take months to clear and induces further damage.<sup>2</sup> Several treatments have been reported, such as vitrectomy and puncturing the ILM by green argon laser and neodymium-doped yttrium aluminum garnet (Nd:YAG) laser.<sup>1–3</sup> Outcomes vary with different specific approaches. In subretinal hemorrhage, intravitreal injection of tissue plasminogen activator (tPA) followed by pneumopexy has been reported to be effective in clearing the hemorrhage.<sup>4</sup> We applied this management to treat two cases of sub-ILM hemorrhage due to different causes and assessed the efficacy.

## 2. Case Reports

This study examined two eyes of two patients with sub-ILM hemorrhage due to different causes. Preoperative examinations included best-corrected visual acuity (BCVA), intraocular pressure (IOP), fundus photograph, fluorescein angiography (FA), and optical coherence tomography (OCT). After giving informed consent, both patients received a tPA injection followed by an octafluoropropane (C<sub>3</sub>F<sub>8</sub>) gas injection.

Under local anesthesia, 50 µg of tPA in 0.1 mL balanced salt solution was injected intravitreally through the pars plana. The patient was kept supine for 4 hours. Then, following an anterior chamber paracentesis, 0.4 mL pure C<sub>3</sub>F<sub>8</sub> was injected into the vitreous cavity through the pars plana. The patient then changed to a prone position. No complications were noted during the procedures and multiple follow-up examinations were scheduled in both cases.

### 2.1. Case 1

A 44-year-old woman was referred to our clinic for sudden visual loss of the right eye after severe coughing. No systemic disease or past ophthalmic history was reported. Her BCVA was 6/15 in the right eye and 6/6 in the left eye. No elevation of IOP was noted.

Conflicts of interest: The authors declare that there are no conflicts of interest related to the subject matter or materials discussed in this article.

\* Corresponding author. Department of Ophthalmology, Taipei Veterans General Hospital, Number 201, Section 2, Shipai Road, Beitou District, Taipei 11217, Taiwan.

E-mail address: [pklin123@hotmail.com](mailto:pklin123@hotmail.com) (P.-K. Lin).

Fundus photography and FA revealed a well-circumscribed pre-macular hemorrhage near the inferior arcade encroaching upon the fovea in the right eye (Figs. 1A and 1B). OCT revealed a dome-shaped hyporeflective area beneath a hyper-reflective band at the fovea (Fig. 1C), compatible with sub-ILM hemorrhage.

The patient received an intravitreal tPA injection followed by a C<sub>3</sub>F<sub>8</sub> pneumopexy. Multiple follow-up examinations were scheduled on the 3<sup>rd</sup> day, the 10<sup>th</sup> day, the 24<sup>th</sup> day, the 6<sup>th</sup> week, the 8<sup>th</sup> week, the 4<sup>th</sup> month, and the 6<sup>th</sup> month after the treatment. Postoperative BCVA of the right eye improved to 6/8.6 on the 3<sup>rd</sup> day, 6/7.5 on the 24<sup>th</sup> day, and was 6/6 consistently after the 8<sup>th</sup> week. No elevation of IOP was noted during the visits. Post-treatment fundus photography revealed significant absorption of the hemorrhage (Figs. 1D–F). Repeated FAs revealed no active lesion throughout the follow-up period (Figs. 1G and 1H). OCT demonstrated gradual absorption of the hemorrhage in the sub-ILM space (Figs. 1I–N).

## 2.2. Case 2

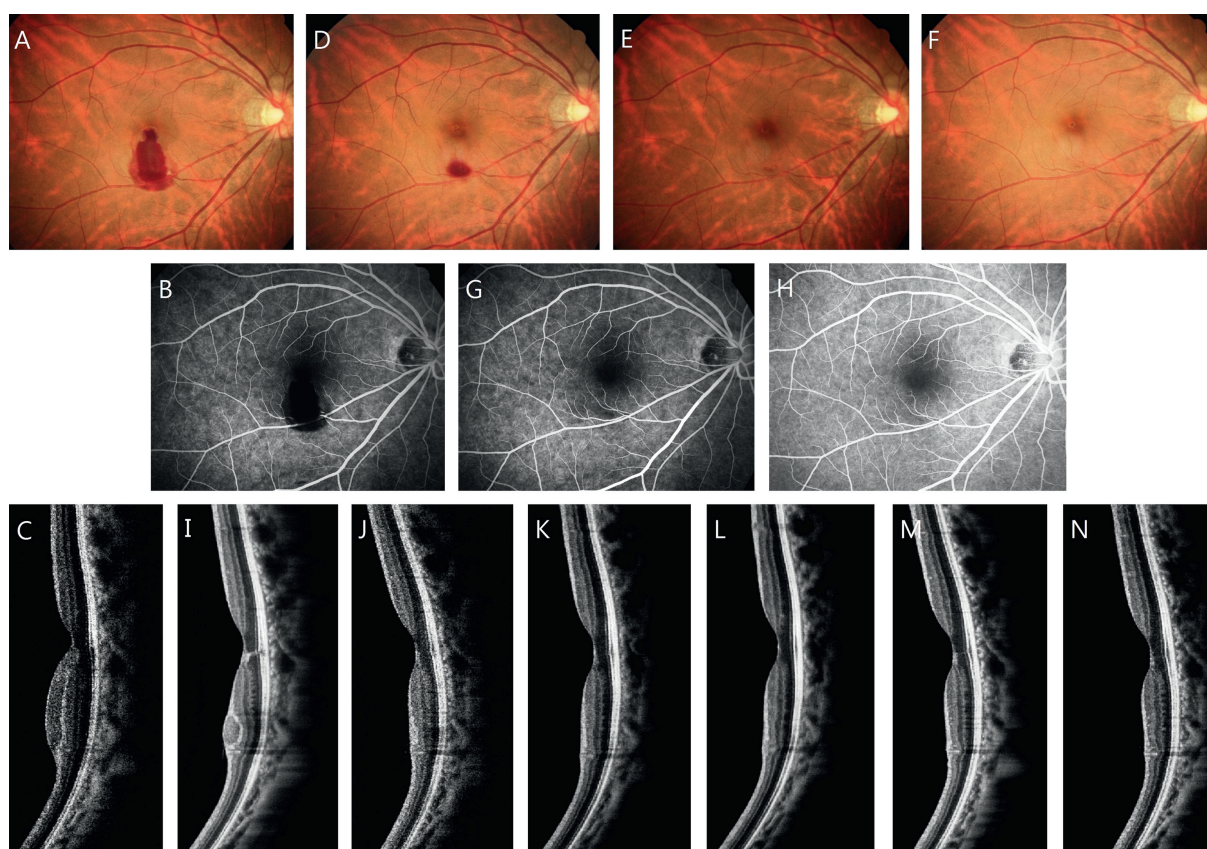
A 20-year-old woman, treated with chemotherapy for acute promyelocytic leukemia, with severe anemia and thrombocytopenia, was referred to our clinic due to acute vision loss and bilateral retinal hemorrhages. Her BCVA was 6/8.6 in the right eye and 3/60 in the left eye. No elevation of IOP was noted. Fundus photography disclosed several macular hemorrhages in the right eye and a large area of sub-ILM hemorrhage involving the fovea of

the left eye (Fig. 2A). FA demonstrated fluorescence blockage in the fovea (Fig. 2B) and OCT confirmed the sub-ILM location (Fig. 2C).

Initially the management for the hemorrhage was suspended due to leukopenia (White blood cell: 270/mm<sup>3</sup>). After 1 month, when the condition became stable, preoperative examinations were performed and fundus photograph, FA, and OCT showed a partially organized sub-ILM hemorrhage with residual blood in the fovea of the left eye (Figs. 2D–F). Her BCVA remained 3/60 in the left eye. The patient received an intravitreal tPA injection followed by a C<sub>3</sub>F<sub>8</sub> pneumopexy. Multiple follow-up examinations were carried out on the 3<sup>rd</sup> day, the 5<sup>th</sup> day, the 10<sup>th</sup> day, the 18<sup>th</sup> day, the 4<sup>th</sup> week, the 6<sup>th</sup> week, and the 2<sup>nd</sup> month after treatment. Post-operative BCVA of the left eye improved to 5/60 on the 3<sup>rd</sup> day, 6/60 on the 5<sup>th</sup> day, 6/6 on the 10<sup>th</sup> day, and was 6/6 consistently afterward. No elevation of IOP was noted during the visits. Post-treatment fundus photography showed significant absorption of the hemorrhage (Figs. 2G–I). No recurrent bleeding or neovascularization was noted in the FA on the visit of the 18<sup>th</sup> day (Fig. 2J). Gradual blood absorption in the sub-ILM space was demonstrated in OCT and a translucent prefoveal cavity with overriding stretched ILM was disclosed (Figs. 2K–Q).

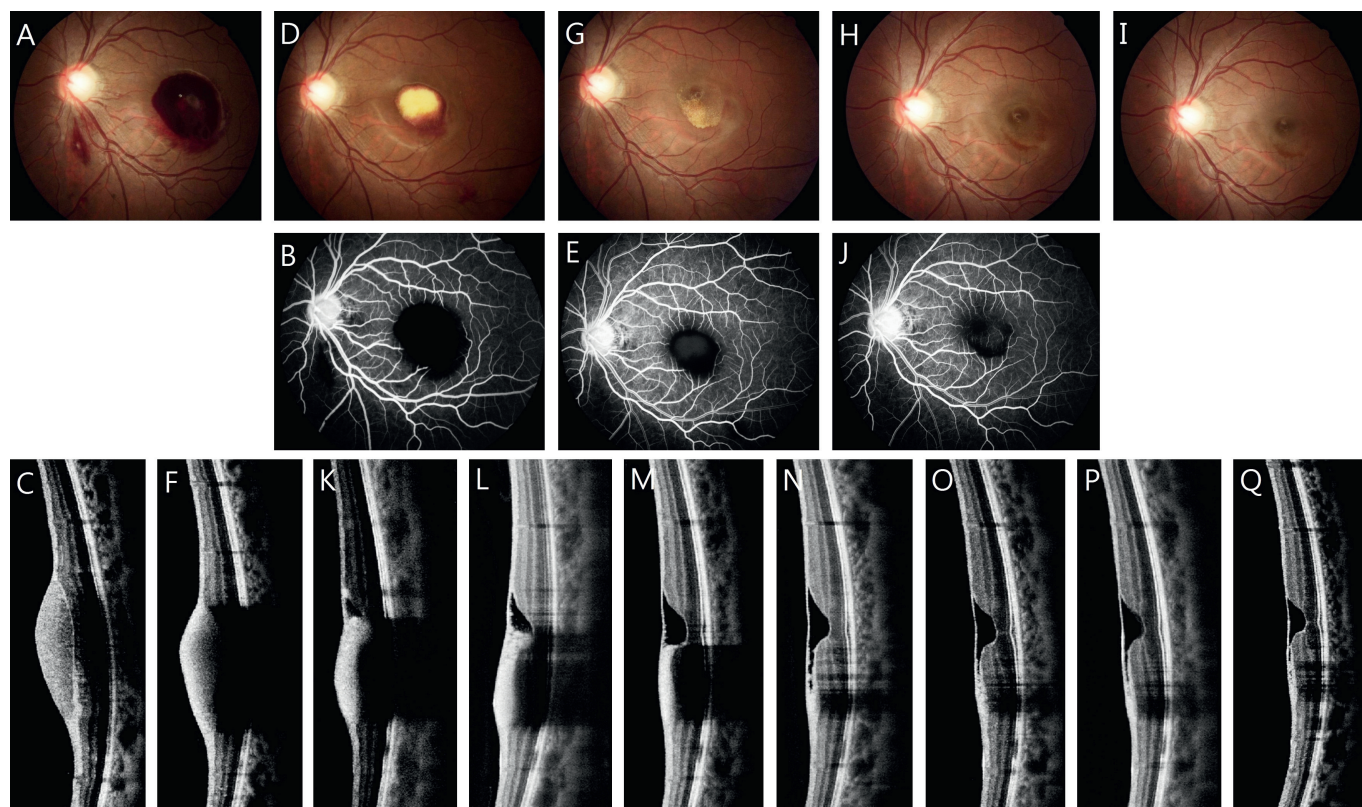
## 3. Discussion

Various causes of sub-ILM hemorrhage have been reported.<sup>1</sup> Valsalva retinopathy may be associated with a rupture of perifoveal retinal capillaries caused by a rapid increase in intraocular



**Fig. 1.** At the initial presentation of the right eye, (A) fundus photograph and (B) fluorescein angiography revealed a well-circumscribed hemorrhage near the inferior arcade encroaching upon the fovea and (C) the vertical scan of optical coherence tomography (OCT) demonstrated a dome-shaped, hyporeflective area under a hyper-reflective band at the inferior arcade, suggesting that the hemorrhage corresponded to the sub-internal limiting membrane space. Absorption of the hemorrhage was found under fundus photograph (D) 10 days, (E) 8 weeks, and (F) 4 months after injection. Postoperative fluorescein angiography showed blockage of the residual hemorrhage (G) 8 weeks after injection and (H) complete blood absorption with no neovascularization 6 months after injection. OCT demonstrated gradual blood absorption with no postoperative complications (I) 10 days, (J) 24 days, (K) 6 weeks, (L) 8 weeks, (M) 4 months, and (N) 6 months after injection.





**Fig. 2.** At the initial presentation of the left eye, (A) fundus photograph and (B) fluorescein angiography revealed a large area of sub-internal limiting membrane (ILM) hemorrhage involving the fovea and (C) the vertical scan of optical coherence tomography (OCT) demonstrated a dome-shaped blood clot under a hyper-reflective band, confirming the sub-ILM hemorrhage. Preoperative (D) fundus photograph, (E) fluorescein angiography, and (F) OCT showed the remaining hemorrhage and the partially organized blood clot in the fovea. Postoperative fundus photograph revealed blood absorption (G) 10 days, (H) 4 weeks, and (I) 2 months after injection. (J) Postoperative fluorescein angiography disclosed the blood absorption with no recurrent bleeding or neovascularization 18 days after injection. Postoperative OCT demonstrated the gradual absorption of the hemorrhage with the formation of the sub-ILM cavity with overriding stretched ILM (K) 3 days, (L) 5 days, (M) 10 days, (N) 18 days, (O) 4 weeks, (P) 6 weeks, and (Q) 2 months after injection.

venous pressure due to increased intrathoracic or intra-abdominal pressure, such as coughing, sneezing, or strenuous physical activity.<sup>5</sup> In most cases, the extravasated blood is sedimented under the ILM.<sup>6</sup> Blood dyscrasia, such as anemia and thrombocytopenia, may be an important risk factor for developing retinopathy.<sup>7</sup> It is believed that the reduction of coagulability and endothelial cell integrity of the retinal vasculature allows the blood cells to leak through the endothelial barrier of the retinal capillaries.<sup>1</sup>

Although the spontaneous absorption of hemorrhage less than one disk in diameter tends to resolve in a short period of time, a larger area of blood clot may take months to clear.<sup>2</sup> Due to the rareness of the disease, reported complications of long-term untreated sub-ILM hemorrhage are not found. However, it is well understood that prolonged retinal contact with hemoglobin and iron may cause toxic retinal damage and lead to irreversible visual impairment.<sup>8,9</sup> Different managements for sub-ILM hemorrhage have been reported.<sup>1,2</sup> Nd:YAG laser is effective in clearing the hemorrhage from Valsalva retinopathy by puncturing the ILM.<sup>3</sup> However, Garcia Fernandez et al<sup>2</sup> suggested that Nd:YAG laser should be used to treat premacular hemorrhage instead of sub-ILM hemorrhage due to complications such as retinal hole formation or retinal detachment. Pars plana vitrectomy has been used for immediate removal of the hemorrhage and for the confirmation of the bleeding location.<sup>1</sup> Complications may occur including bleeding, cataract, increased IOP, and retinal detachment.<sup>1</sup> Vitrectomy is suggested for dense hemorrhage or insufficient spontaneous absorption in Valsalva retinopathy.<sup>2</sup>

Intravitreal injection of tPA followed by pneumopexy has been reported effective in treating subretinal and subhyaloid

hemorrhage.<sup>4,10</sup> As an enzyme, tPA catalyzes the conversion of plasminogen to plasmin, which is responsible for fibrinolysis and blood clot breakdown. In Patient 2, we found intravitreal injection of tPA effective in dissolving the partially organized blood clot even when the treatment was delayed for 1 month. In this study, we injected 50  $\mu$ g of tPA intravitreally to treat the sub-ILM hemorrhage. This dosage is considered safe to avoid retinal toxicity and sufficient for blood clot lysis in subretinal hemorrhages.<sup>4</sup> We found that successful blood clot lysis was achieved without tPA-related retinal toxicity in our patients. In the treatment of subretinal hemorrhage, it is believed that tPA may diffuse into the subretinal space through the microlesions in the retina caused by stretching from the hemorrhage.<sup>11</sup> We believe that this hypothesis explains the passage of tPA into the sub-ILM space in our cases.

In submacular hemorrhage, intravitreal gas injection followed by prone positioning is effective in displacing the thick hemorrhage from the fovea.<sup>12</sup> We believe that an intravitreal gas injection after tPA hemolysis could be used as pneumopexy for ILM detachment caused by the hemorrhage. In the treatment of subretinal hemorrhage using a tPA injection with a pneumatic injection, a delay of 3–6 hours before the gas injection is sufficient to allow tPA to migrate across the retina.<sup>13</sup> Because of the proximity of the blood to the retinal surface in sub-ILM hemorrhages, a delay of 4 hours in our cases led to a successful outcome of tPA hemolysis and blood absorption.

A translucent cavity under a hyper-reflective membrane, presumably the ILM, was disclosed in the second case after treatment. It is believed that the growth factors contained in the blood may stimulate the cells along the outer ILM and retinal surface and cause

the cavity lined by these cells to exist even after the hemorrhage was resolved.<sup>14</sup> This occurs mainly in cases of sub-ILM hemorrhage and may not be resolved with observation alone.<sup>14</sup>

Unlike the natural course of recovery, the hemorrhage was effectively absorbed with faster visual recovery in both cases. We observed neither complications nor progression despite the lack of immediate hemorrhage removal by vitrectomy or laser puncturing. This result suggested that tPA hemolysis with intravitreal injection and pneumopexy was a safe and effective method to treat sub-ILM hemorrhage. Further large-scale and long-term studies may be suggested for further evaluation of the benefits and disadvantages of this therapy.

## References

1. De Maeyer K, Van Ginderdeuren R, Postelmans L, Stalmans P, Van Calster J. Sub-inner limiting membrane haemorrhage: causes and treatment with vitrectomy. *Br J Ophthalmol*. 2007;91:869–872.
2. Garcia Fernandez M, Navarro JC, Castano CG. Long-term evolution of valsalva retinopathy: a case series. *J Med Case Rep*. 2012;6:346.
3. Perez-Rico C, Montes-Mollon A, Castro-Rebollo M, Pareja-Esteban J, Benitez-Herreros J. Optical coherence tomography features of sub-internal limiting membrane hemorrhage and temporary premacular cavity following Nd:YAG laser membranotomy in valsalva retinopathy. *Jpn J Ophthalmol*. 2008;52:513–515.
4. Singh RP, Patel C, Sears JE. Management of subretinal macular haemorrhage by direct administration of tissue plasminogen activator. *Br J Ophthalmol*. 2006;90:429–431.
5. Mehdi Nili Ahmatabadi R, Karkhaneh A, Mirshahi A, et al. Premacular hemorrhage in valsalva retinopathy: a study of 21 cases. *Iran J Ophthalmol*. 2009;21:11–16.
6. Meyer CH, Mennel S, Rodrigues EB, Schmidt JC. Is the location of valsalva hemorrhages submembranous or subhyaloidal? *Am J Ophthalmol*. 2006;141:231. author reply 231–232.
7. Carraro MC, Rossetti L, Gerli GC. Prevalence of retinopathy in patients with anemia or thrombocytopenia. *Eur J Haematol*. 2001;67:238–244.
8. Sanders D, Peyman GA, Fishman G, Vlcek J, Korey M. The toxicity of intravitreal whole blood and hemoglobin. *Albrecht Von Graefes Arch Klin Exp Ophthalmol*. 1975;197:255–267.
9. O'Hanley GP, Canny CL. Diabetic dense premacular hemorrhage. A possible indication for prompt vitrectomy. *Ophthalmology*. 1985;92:507–511.
10. Koh HJ, Kim SH, Lee SC, Kwon OW. Treatment of subhyaloid haemorrhage with intravitreal tissue plasminogen activator and C3F8 gas injection. *Br J Ophthalmol*. 2000;84:1329–1330.
11. Hesse L. Treating subretinal hemorrhage with tissue plasminogen activator. *Arch Ophthalmol*. 2002;120:102–103. author reply 203.
12. Mizutani T, Yasukawa T, Ito Y, et al. Pneumatic displacement of submacular hemorrhage with or without tissue plasminogen activator. *Graefes Arch Clin Exp Ophthalmol*. 2011;249:1153–1157.
13. Hassan AS, Johnson MW, Schneiderman TE, et al. Management of submacular hemorrhage with intravitreal tissue plasminogen activator injection and pneumatic displacement. *Ophthalmology*. 1999;106:1900–1906. discussion 1906–1907.
14. Goel N, Kumar V, Seth A, Raina UK, Ghosh B. Spectral-domain optical coherence tomography following Nd:YAG laser membranotomy in valsalva retinopathy. *Ophthalmic Surg Lasers Imaging*. 2011;42:222–228.