



Contents lists available at ScienceDirect

International Journal of Surgery Case Reports

journal homepage: www.casereports.com

Diagnosis of a 09 cm pheochromocytoma mistaken to be an intramesenteric pancreatic tumor: Case report complying with the scare guidelines

Fatima Zahrarahou*, Achraf Miry, Houda Mirali, Leila Mahmoudi, Amal Bennani, Mohammed Bouziane

General Surgery Department, Mohamed VI University Hospital, Oujda, Morocco

ARTICLE INFO

Article history:

Received 27 September 2020
Received in revised form 19 October 2020
Accepted 20 October 2020
Available online 25 November 2020

Keywords:

Pheochromocytoma
Hypertension
Chromogranine A
PASS
Case report
Scare guidelines

ABSTRACT

INTRODUCTION: Pheochromocytoma is an adrenal medullary tumor of the chromaffin cells first described in 1886, remains an entity not fully discovered that case reports keep showing its diversity in clinical presentation, diagnosis methods treatment and follow up challenges.

CASE PRESENTATION: We report the case of a 47 year old woman with complaining from abdominal pain and major weightless with a 09 cm tumor of the body of the pancreas viewed in imaging with no hormonal secretion but high levels of chromogranine A open surgery conducted that revealed the tumor to be located between the adrenal medulla and the Aorta misleading the team between an adrenal tumor or a zuckerkind body tumor. The hemodynamic changes after manipulation of the tumor and the histopathology confirming the diagnosis of pheochromocytoma. Our main surprise was the aspect of the tumor bombing in the peritoneal cavity firstly thought to be mesenteric tumor; and the stability of the patient with no premedication until the tumor had been manipulated, enlarging the hypothesis about catecholamine secretion of these tumor.

DISCUSSION: The diagnosis is basically simple when the tumor expresses its catecholamines by biomarkers testing, an imaging. Functional imaging should be used to locate the tumor or its metastasis, the sequence of testing or imaging can vary either it's a symptomatic tumor or an incidentaloma. Preoperative measures should be taken so no major preoperative complications and the main treatment is the tumor complete resection

CONCLUSION: The malignancy of the pheochromocytoma is no near to be reliably identified which imposes a lifetime follow up of these patients as for metastasis were described even after 40 years after diagnosis.

© 2020 Published by Elsevier Ltd on behalf of IJS Publishing Group Ltd. This is an open access article under the CC BY-NC-ND license (<http://creativecommons.org/licenses/by-nc-nd/4.0/>).

1. Introduction

Pheochromocytoma is an adrenal medullary tumor of the chromaffin cells. It was always known for its catecholamine's secretion but the non-secreting entity is getting known nowadays. It can also rise in other organs and are called Ectopic pheochromocytomas.

Felix Fraenkel was the first to describe it in 1886 reporting a bilateral adrenal tumors after the autopsy of a female patient deceased after a heart attack, the denomination though was attributed by Ludwig Pick in 1926 after revealing the tumor's reaction to chromium salts exposure by turning its color to a dark brown. Pheochromocytomas are relatively rare with no gender

predisposition and a significant number of clinically silent or under-diagnosed ; this fact proven by the estimated number of tumors discovered during autopsy series which prevalence rates varies between 0,05 % and 0,3% [1]

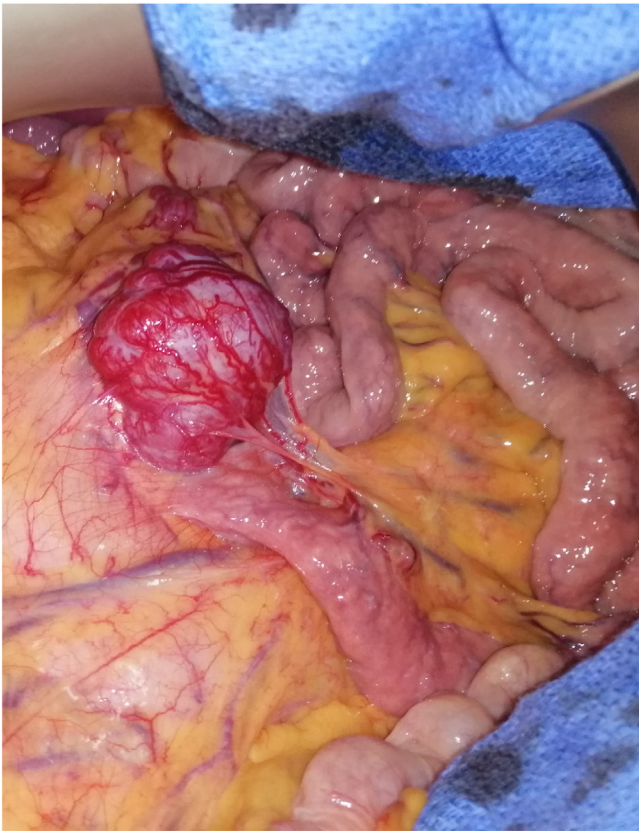We report a rare case of preoperative discovery of a mesenteric pheochromocytoma at the universal hospital of Oujda-Morocco, this work has been reported in line with the SCARE criteria [2]

2. Presentation of the case

A 47 year old female, mother to 5 children, with no relevant personal nor familial medical history, under no medication, presented to our institute for paroxysmic epigastric pain evolving for 5 years associated with vomiting, anorexia and significant weight Loss and a BMI 15.8, physical examination has found no abnormalities, laboratory investigations revealed no deficiencies no abnormalities and complete blood count, hepatic enzymes, renal function, lipase measurement were within the normal limits, an abdominal

* Corresponding author.

E-mail addresses: fatimazahrou@gmail.com (F. Zahrarahou), achrafmiry@outlook.com (A. Miry), mirali.houda@gmail.com (H. Mirali), lailamhd916@gmail.com (L. Mahmoudi), bouzianemohammed@hotmail.com (M. Bouziane).



A peroperative image showing a pheochromocytoma budding in the peritoneum, looking like a stromal intestinal tumor

Fig. 1. peroperative open abdomen first look at the pheochromocytoma: a gastrointestinal stromal tumor (GIST) Alike.

computerized tomography (CT) with contrast injections showed a 76 mm tumor probably originated from the body of the pancreas, a pancreatic magnetic resonance imaging (MRI) performed confirmed the tumor measuring 91*74*86 mm but denied the pancreatic origin and showed the topographical relation of the tumor with small bowel and suggested a gastrointestinal stromal tumor. Further biochemical testing were performed finding a highly elevated chromogranin A, negative urinary catecholamine, predicting an endocrine neoplasm.

A parenteral nutrition along with a hypercaloric diet was restored due to the non-availability of a proper immunonutrition. An exploratory laparotomy through a midline incision was performed, finding an amazing mesenteric tumor of the proximal jejunum at the first look (Fig. 1) the surprise though was the topographically relation of the tumor with the adrenal gland, the pancreas, the Aorta and the left renal hilum, which was hardly dissected from the aorta, the superior mesenteric artery and the left renal artery using energy devices (Enseal© Ethicon), during the manipulation of the tumor, a hypertensive crisis occurred for which a calcium antagonist had been used with no residual hypotension after the tumor resection, the blood pressure remained at the normal rates, no antihypertensive drugs were needed, the drainage system was removed by the second day after the surgery, and the length of stay was 3 days after the surgery.

The histopathology found a 173 g masse with a tumor proliferation arranged in nests and thick spans surrounded by a fibrous capsule on the edges (Fig. 2) and at a high enlargement it shows large tumor cells with a regular nucleus and a clear and eosinophilic cytoplasm. The stroma is endocrinoid in appearance and made of fine, regular vessels. Immunohistochemistry (IHC) analysis confirmed a positive expression of chromogranin A along with the

protein S 100 (PS100) confirming the histopathological diagnosis of a pheochromocytoma with a Pheochromocytoma of the Adrenal Gland Scaled Score (Pass) score of 2

The follow up at 6 months showed an enhancement of the physical examination with a significant weight gain of 6 pounds, no residual abdominal pain or vomiting, no cardiac nor hypertension symptoms, a CT scan was scheduled at 12 months with a chromogranin testing. The investigations for other endocrine neoplasms were negative

3. Discussion

The symptoms of the pheochromocytoma is generally related to its adrenal secretion, typically a hypertensive crisis with tachycardia and headaches, the hypertension can be paroxysmic or sustained, also it can be triggered by excessive physical activity, general anesthesia or some drugs especially monoamine oxidase inhibitors [3] but a significant amount of these tumors are diagnosed incidentally after an abdominal imaging or even discovered peroperative for other purposes surgeries or even autopsies. [4]

The hereditary pattern can be related to this tumor by mutations of several tumor suppression genes; especially the multiple endocrine neoplasia (MEN) type 2 that presents a mutation in the RET proto-oncogene with a rate of 50 % of pheochromocytoma along with 100 % thyroid carcinomas and the Von Hippel Lindau (VHL) syndrome type II along with neurofibromatosis (NF) type I, and it is likely to discover more hereditary mutations in the future that are yet to be fully elucidated [3]

Plasmatic or urinary Hormonal excess testing of catecholamines or their metabolites establishes the biochemical diagnosis of a pheochromocytoma, but in daily practice ; pheochromocytomas should be considered in case of resistant high blood pressure at a young age, or during anesthesia or during adrenergic episodic crisis [5]

The aim of imaging should be looking for tumors of the adrenal medulla that contains the majority of the chromaffin cells that may or may not have degenerated after birth, the

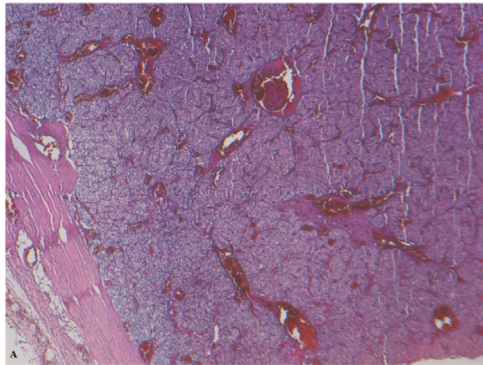
Zuckermandl organ, the retro-peritoneum and the urinary bladder that contains the sympathetic nerves, as well called ectopic tumors that may be secreting those catecholamines

CT and MRI are highly specific for studying the adrenal medulla tumors showing pheochromocytomas as masses with a high signal intensity on T2-weighted, especially fat-suppressed T2-weighted imaging [6]

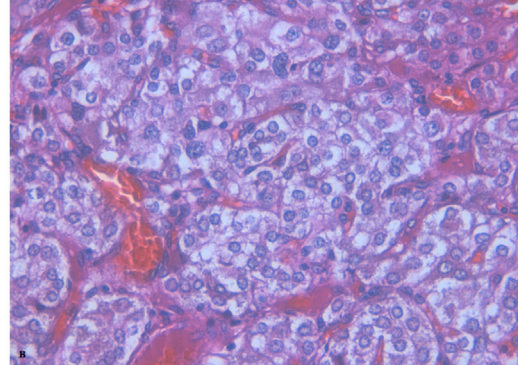
As has been confirmed the expression of somatostatin receptor within pheochromocytomas; functional imaging took a very big turn from the use of metaiodobenzylguanidine scintigraphy (MIBG) which is a metanephrine analogue tagged with radioisotope to positron emission tomography (PET) coupling the Gallium 68 to octreotate instead of the fludeoxyglucose (18F-FDG). The availability of such imaging may be very exclusive, it's reserved to the study of metastatic or ectopic pheochromocytomas or biochemically active tumors with negative CT/MRI imaging [7]

The gold standard treatment is surgical resection of the tumor, with very strict preoperative preparation to control blood pressure using adrenergic blockade [8], laparoscopy should be preferred to open abdomen unless the tumor size exceeds 8 cm, uncertain diagnosis or a contraindication to laparoscopy as well as the surgeon expertise and the lateral or anterior trans peritoneal approach is ideally considered unless the patient has a history of previous abdominal surgery or a bilateral adrenalectomy then the posterior approach is required so no position changing will be needed [7]

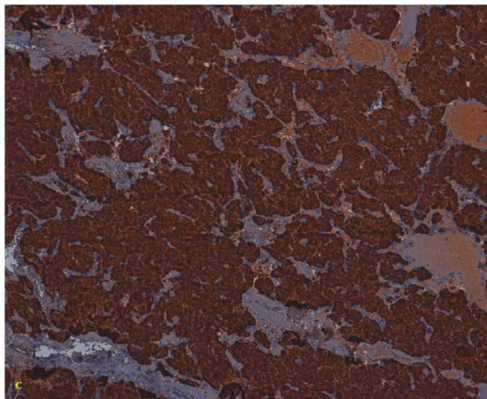
Malignant pheochromocytoma represents approximately 10 % of all pheochromocytomas and have been reported one case of malignant non secretant pheochromocytoma in history so far [9],



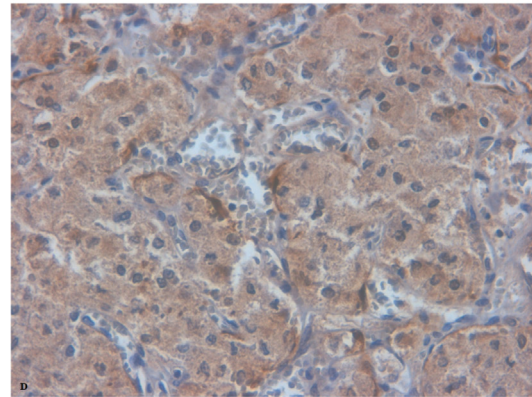
A: Microphotograph at low magnification showing a tumor proliferation arranged in nests and thick spans surrounded by a fibrous capsule on the periphery.



B: Highly magnified photomicrograph showing large tumor cells with a regular nucleus and a clear or eosinophilic cytoplasm. The stroma is endocrinoid in appearance and made of fine, regular vessels.



C: Immunohistochemical profile showing positive labeling of tumor cells by chromogranin A.



D: Immunohistochemical profile showing a positive labeling of the supra-tentacular cells by the PSt100.

Fig. 2. Histopathology images identifying the pheochromocytoma with an IHC testing to chromogranine A and S100.

they are locally invasive, metastatic or recurrent and no preoperative measure can reliably identify the malignant specimen, though Rao et al. had led an investigation about the plasmatic measurement of chromogranin A concluding that it is an effective test for diagnosis and significantly related to tumor size and it might point to a malignant pheochromocytoma [10].

In the other hand, the revised WHO classification no longer distinguishes benign or malignant tumors and that they all should be considered to contain some malignant potential which will only be revealed through metastasis [11] but the PASS predicted benign pheochromocytoma with a score < 4 and suggested a close follow up when PASS score's exceeds 4 [12]

4. Conclusion

allegedly With the lack of a clear protocol for the follow up of pheochromocytomas, nor a reliable criteria to identify the malignant potential moreover other endocrine tumors, should lead to more studies of both malignant and benign, adrenal and ectopic pheochromocytomas as well as screening for hereditary diseases.

Declaration of Competing Interest

No conflict of interest.

Funding

No sources of funding to our research has been needed.

Ethical approval

It's a one case report needing no ethnical approval.

Consent

Written informed consent was obtained from the patient for publication of this case report and accompanying images. A copy of the written consent is available for review by the Editor-in-Chief of this journal on request.

Author contribution

F.Rahou: fatima zaharahou: fatimazahou@gmail.com (corresponding author), general surgery resident

Have written the article, Have consulted the patient, prescribed all of the tests and prepared the patient for surgery and participated in the surgery

A.Miry,:Achraf Miry : achrafmiry@outlook.com (anatomopathology resident) : have helped writing the article, confirm the histological diagnosis

H.Mirali: Houda Mirali: mirali.houda@gmail.com (radiology resident) : have helped with the imaging analysis

L.Mahmoudi: Leila Mahmoudi: lailamhd916@gmail.com (radiology resident) : have helped with the imaging analysis

A.Bennani: Amalbennani: (anatomopathology professor): confirm the histological diagnosis

M.Bouziane: Mohammed bouziane :bouzianemohammed@hotmail.com (oncology surgery professor) : have

supervised the writing of the paper, and has been the leader surgeon of the case)

Registration of research studies

Not Applicable.

Guarantor

M.Bouziane: Mohammed bouziane : bouzianemohammed@hotmail.com (oncology surgery professor).

Provenance and peer review

Not commissioned, externally peer-reviewed.

References

- [1] M.G. Sutton, S.G. Sheps, J.T. Lie, Prevalence of clinically unsuspected pheochromocytoma. Review of a 50-year autopsy series, *Mayo Clin. Proc.* 56 (6) (1981), 354e360.
- [2] R.A. Agha, M.R. Borrelli, R. Farwana, K. Koshy, A. Fowler, D.P. Orgill, For the SCARE Group, The SCARE 2018 statement: updating consensus Surgical Case Report (SCARE) guidelines, *Int. J. Surg.* 60 (2018) 132–136.
- [3] V.L. Martucci, K. Pacak, Pheochromocytoma and paraganglioma: diagnosis, genetics, management, and treatment, *Curr. Probl. Cancer* 38 (1) (2014), 7e41.
- [4] A. Soltani, M. Pourian, B.M. Davani, Does this patient have pheochromocytoma? A systematic review of clinical signs and symptoms, *J. Diabetes Metab. Disord.* 15 (6) (2015).
- [5] A. Tsirlin, Y. Oo, R. Sharma, A. Kansara, A. Gliwa, M.A. Banerji, Pheochromocytoma: a review, *Maturitas* 77 (3) (2014) 229–238, <http://dx.doi.org/10.1016/j.maturitas.2013.12.009>.
- [6] H.S. Qiao, et al., *Eur. J. Radiol.* 62 (2007) 335–341.
- [7] Yufei Chen, Quan-Yang Duh, Update on Diagnosis and Management of Pheochromocytoma, *Advances in Treatment and Management in Surgical Endocrinology*, Chapter 14, Elsevier, 2020, pp. 139–149, <http://dx.doi.org/10.1016/B978-0-323-66195-9.00014-00015>.
- [8] A. Jain, R. Baracco, G. Kapur, Pheochromocytoma and paraganglioma—an update on diagnosis, evaluation, and management, *Pediatr. Nephrol.* (2019), <http://dx.doi.org/10.1007/s00467-018-4181-2>.
- [9] S. Borzouei, S.H. Mousavi-bahar, S.A. Salimbahrami, M. Sardari Masihi, Malignant pheochromocytoma with negative biochemical markers: is it time to reclassify pheochromocytomas? *Urol. Case Rep.* (2019) 100858, <http://dx.doi.org/10.1016/j.eucr.2019.100858>.
- [10] F. Rao, H.R. Keiser, D.T. O'Connor, Malignant pheochromocytoma: chromaffin granule transmitters and response to treatment, *Hypertension* 36 (2000) 1045–1052.
- [11] J. Guilmette, P.M. Sadow, A guide to pheochromocytomas and paragangliomas, *Surg. Pathol. Clin.* (2019), <http://dx.doi.org/10.1016/j.path.2019.08.009>.
- [12] A. Harari, W.B. Inabnet, *Malignant pheochromocytoma: a review*, *Am. J. Surg.* 201 (5) (2011) 700–708, <http://dx.doi.org/10.1016/j.amjsurg.2010.04.012>.

Open Access

This article is published Open Access at [sciencedirect.com](https://www.sciencedirect.com). It is distributed under the [IJSCR Supplemental terms and conditions](#), which permits unrestricted non commercial use, distribution, and reproduction in any medium, provided the original authors and source are credited.