



Contents lists available at ScienceDirect

International Journal of Surgery Case Reports

journal homepage: www.casereports.com

A case report of duplex gallbladder and review of the literature

Y.M. Goh^a, Y.L. Goh^a, L.C. Ewan^a, P.D. Turner^b, S. Lapsia^{c,*}, D.A. Subar^{a,*}^a Department of Hepato-Biliary Surgery, East Lancashire Teaching Hospitals NHS Trust, United Kingdom^b Department of Upper Gastro-Intestinal Surgery, Lancashire Teaching Hospitals NHS Foundation Trust, United Kingdom^c Department of Radiology, East Lancashire Teaching Hospitals, NHS Trust, United Kingdom

ARTICLE INFO

Article history:

Received 27 April 2015

Received in revised form 22 July 2015

Accepted 23 July 2015

Available online 30 July 2015

Keywords:

Biliary colic

Duplicate gallbladder

Double gallbladder

Laparoscopic cholecystectomy

ABSTRACT

Gallbladder duplication is a rare congenital abnormality first described by Boyden in 1926. Pre-operative diagnosis is essential in identifying anatomical abnormalities in order to avoid biliary injuries at the time of surgery or performance of an incomplete operation. We present a case of a duplex gallbladder and review of the literature.

© 2015 The Authors. Published by Elsevier Ltd. on behalf of Surgical Associates Ltd. This is an open access article under the CC BY-NC-ND license (<http://creativecommons.org/licenses/by-nc-nd/4.0/>).

1. Introduction

Duplex gallbladder pathology is rare with a reported incidence of 1 in 34,000 [1]. This congenital abnormality can be classified using Boyden's [1] or Harlaftis's [2] classification based on its anatomy. Patients with this pathology can be asymptomatic or symptomatic. If symptomatic, surgery to remove the gallbladders is indicated. Although rare, it is important to be aware of duplex gallbladders pre-operatively. This can avoid the second gallbladder being missed intra-operatively with these patients re-presenting with biliary symptoms at a later date.

2. Case report

A 28 year old male was referred to our tertiary hepato-biliary unit with a 12 month history of intermittent episodes of colicky right upper quadrant pain and nausea. He was otherwise fit and well with no past medical history. He had an appendectomy in childhood.

Pre-operative blood tests including full blood count, liver function test, C-reactive protein and amylase were normal. Abdominal ultrasound scan (USS) revealed a duplex gallbladder with no gallstones or biliary dilatation (Fig. 1). This was confirmed on magnetic resonance cholangiopancreatography (MRCP) which demonstrated a duplex gallbladder with a single cystic duct (Fig. 2). He underwent laparoscopic cholecystectomy and on-table cholangiogram (OTC)

which confirmed the above MRCP findings of a single cystic duct draining two separate gallbladders (Figs. 3, 4). Intra-operatively, clips were applied to the single cystic duct and artery, respectively and they were divided between the clips. The gallbladders were dissected off the gallbladder fossa and retrieved in a nylon bag via the epigastric port.

The patient made an uneventful recovery and was discharged three days later with no post-operative complications. A telephone follow-up at 6 weeks was unremarkable.

3. Discussion

Duplicated gallbladder (DG) is a rare congenital abnormality with a reported incidence of 1 in 34,000 [1]. DG occurs when either the cystic primordium splits during the 5th to 6th week of embryogenesis to give a duplicate gallbladder or when there is extra-budding of the biliary primordium to give rise to an accessory gallbladder [2]. Classification of DG is based on their relation to the cystic duct:

Group 1: Bilobed gallbladder with a single cystic duct as in this case. It has an incidence of 45.1% [3] and is described as 'split primordium group' and 'vesica fellea divisa' by Harlaftis [2] and Boyden [1] respectively.

Group 2: Two separate gallbladders and cystic ducts, described as 'accessory group' and 'vesica fellea duplex' by Harlaftis [2] and Boyden [1] respectively. This group has an incidence of 54.9% [3].

There is no published literature to our knowledge of any association between a duplicated gallbladder and other duplex structures.

Patients with duplex gallbladders can either be asymptomatic or symptomatic. If symptomatic, they can present with biliary colic, cholecystitis, cholangitis or pancreatitis. Differential

* Corresponding author at: Royal Blackburn Hospital, Haslingden Road BB2 3HH, United Kingdom.

E-mail address: daren.subar@elht.nhs.uk (D.A. Subar).

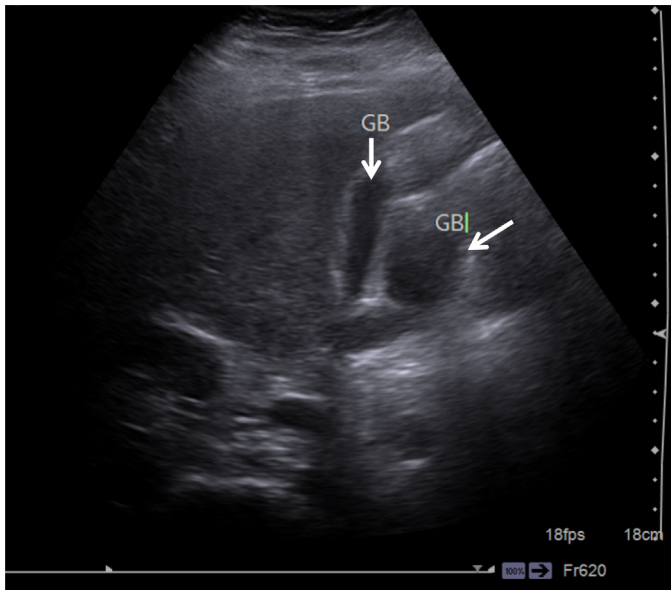


Fig. 1. USS showing two gallbladders (GB) (arrow).

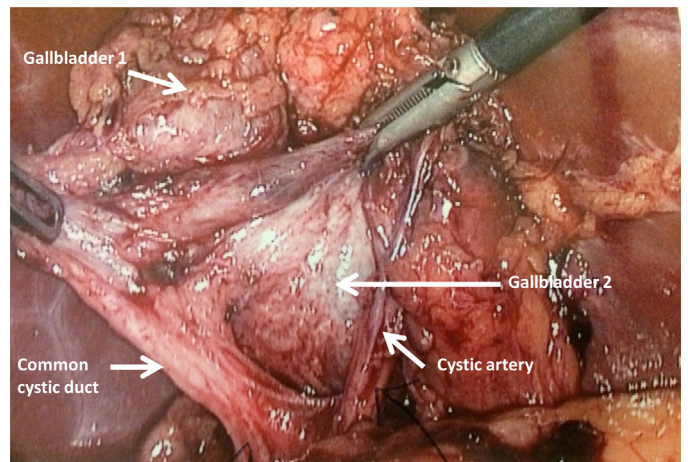


Fig. 3. Calot's triangle and two gallbladders seen intra-operatively.

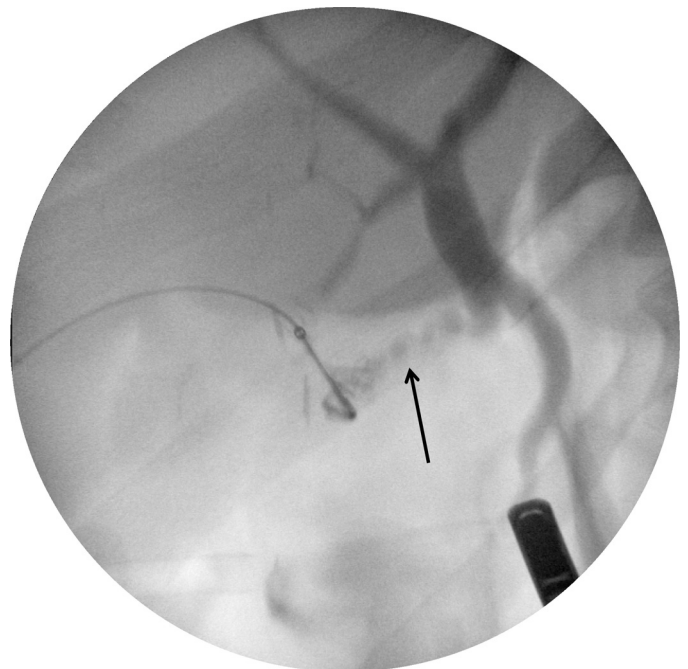


Fig. 4. On-table cholangiogram (OTC) demonstrating a single cystic duct (arrow) draining 2 separate gallbladders.

diagnoses include Phrygian cap, choledochal cyst, folded gallbladder, focal adenomatosis, gallbladder diverticulum and intraperitoneal fibrous bands [1].

USS is the first-line investigation and is highly sensitive in assessing gallstones, cholecystitis and gallbladder anatomical abnormalities [4]. Gocmen et al. [5] and Ozgen et al. [6] reports limitations of USS in failing to differentiate between the various pathologies of the gallbladder as described in the differential diagnoses above, therefore warranting further investigation such as MRCP, CT, oral cholecystography, percutaneous transhepatic cholangiogram or HIDA scan [1,4,7,9,11]. MRCP is superior to USS for anatomical evaluation of the biliary tree. In the absence of a definite diagnosis ERCP can help to demonstrate a DG with contrast-filling of the biliary tree. However, it is invasive and the operator may miss a second gallbladder demonstrated by the contrast [7,8]. Therefore MRCP is now the widely accepted choice of investigation for duplicate gallbladder pathology [7].

In addition to double gallbladders there have been 11 reported cases of triple gallbladders in the literature [9], all of which were diagnosed pre-operatively on ultrasound scan [10]. Roeder et al. published a case report on triple gallbladder with cholecystitis and cholelithiasis in one gallbladder, papillary adenocarcinoma in

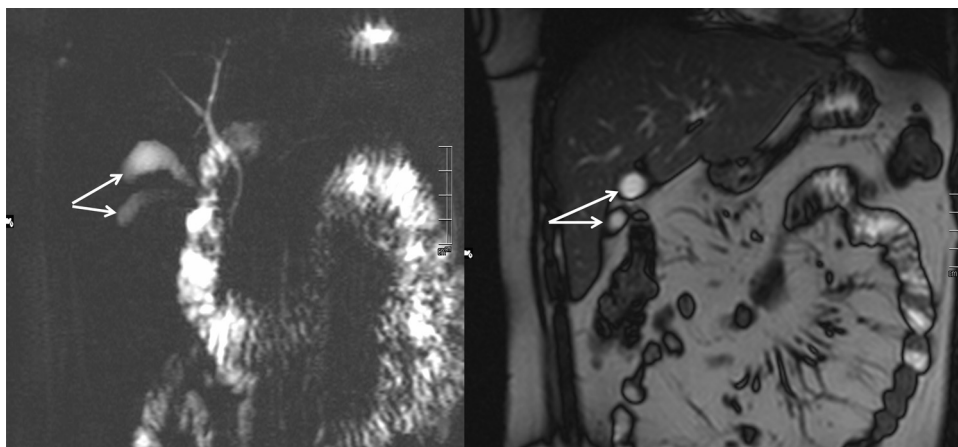


Fig. 2. MRCP showing duplex gallbladder (shown by arrows).

the second gallbladder and a disease-free intra-hepatically located third gallbladder [11]. However, there is no documented evidence of duplicated gallbladders associated with an increased incidence of gallbladder cancer.

Missed diagnosis can lead to patients representing with biliary symptoms or peri-operative injuries. Therefore, defining the anatomy of the biliary tree is crucial at the pre-operative stage as it enables the surgeon to be aware of the type of anatomical variation and reduce the risks of complications from biliary and vascular injury including damage to the common bile duct or other important nearby structures. Silvis et al. [12] and Borchi et al. [13] each report a case of a missed symptomatic DG on radiological imaging that required a second reoperation after a cholecystectomy.

Prophylactic surgery is not recommended for asymptomatic duplex gallbladders found incidentally since the risk of double gallbladders becoming pathological is not increased [3,14–16]. Hishinuma et al. suggest that if one of the DG is normal, the incidence of having a pathology in the other gallbladder is not increased [17]. Likewise, Goiney et al. reported that each of the gallbladders in a DG has the same incidence of developing a pathology as for a single gallbladder [18].

4. Conclusion

Duplex gallbladders are a rare congenital abnormality. Surgery is only indicated for symptomatic duplex gallbladders. Detailed pre-operative imaging is essential to avoid a missed diagnosis. MRCP is now the ideal choice of non-invasive imaging modality.

Conflict of interest

None.

Funding

None.

Ethical approval

None.

Consent

Written informed consent was obtained from the patient for publication of this case report and accompanying images.

Author contribution

Yan Mei Goh, Yan Li Goh, and Lorna Ewan were involved in conducting the literature search and review and writing of the

paper. Paul Turner was the primary surgeon responsible for the case before referring to HPB unit. Snehal Lapsia provided the radiological images and results. Daren Subar was the operating surgeon who was responsible for delivering patient care, edited the final version of the manuscript and provided the overall supervision.

Research registry

researchregistry156.

Guarantor

Yan Li Goh and Daren Subar.

References

- [1] E.A. Boyden, The accessory gallbladder: an embryological and comparative study of aberrant biliary vesicles occurring in man and the domestic mammals, *Am. J. Anat.* 1226 (38) (2015) 177–231.
- [2] N. Harlaftis, S.W. Gray, R.P. Olafson, et al., Three cases of unsuspected double gallbladder, *Am. Surg.* 42 (1976) 178–180.
- [3] G.K. Paraskevas, A. Raikos, O. Ioannidis, et al., Duplicated gallbladder: surgical application and review of the literature, *IJAE* 116 (2) (2011) 61–66.
- [4] K.L. McDonald, T. Lwin, Sonographic and scintigraphic evaluation of gallbladder duplication, *Clin. Nucl. Med.* 11 (1986) 692–693.
- [5] R. Gocman, Y. Yesilkaya, Imaging findings of gallbladder duplication due to two cases: case report and review of literature, *Med. Ultrason.* 14 (4) (2012) 358–360.
- [6] A. Ozgen, D. Akata, A. Arat, et al., Gallbladder duplication: imaging findings and differential considerations, *Abdom. Imaging* 24 (1999) 285–288.
- [7] P.K. Vasanthraj, R. Ramachandran, K. Athiyappan, et al., Imaging in double gallbladder with acute cholecystitis—a rare entity, *Surg. Sci.* 5 (2014) 273–279.
- [8] R.G. Khandelwal, T.V.S. Reddy, T.G. Balachandrar, et al., Symptomatic “H” type duplex gallbladder, *JLS* 14 (2010) 611–614.
- [9] B. Alicioglu, An incidental case of triple gallbladder, *World J. Gastroenterol.* 13 (2007) 2004–2006.
- [10] S. Barnes, H. Nagar, C. Levine, et al., Triple gallbladder: preoperative sonographic diagnosis, *J. Ultrasound Med.* 23 (2004) 1399–1402.
- [11] W.J. Roeder, W.L. Mersheimer, K.K. Kazarian, Triplication of the gallbladder with cholecystitis, cholelithiasis and papillary adenocarcinoma, *Am. J. Surg.* 121 (1971) 746–748.
- [12] R. Silvis, A.J. van Wieringen, C.H. van der Werken, Reoperation for symptomatic double gallbladder, *Surg. Endosc.* 10 (1996) 336–337.
- [13] F. Borghi, G. Giraudo, P. Geretto, et al., Perforation of missed double gallbladder after primary laparoscopic cholecystectomy: endoscopic and laparoscopic management, *J. Laparoendosc. Adv. Surg. Tech.* 18 (3) (2008) 429–431.
- [14] N. Harlaftis, S.W. Gray, J.E. Skandalakis, Multiple gallbladders, *Surg. Gynecol. Obstet.* 145 (1977) 928–934.
- [15] R. Udelsman, P.H. Sugarbaker, Congenital duplication of the gallbladder associated with an anomalous right hepatic artery, *Am. J. Surg.* 149 (1985) 812–815.
- [16] Y. Pillay, Gallbladder duplication, *Int. J. Surg. Case Rep.* 11 (2015) 18–20.
- [17] M. Hishinuma, Y. Isogai, Y. Matsuura, et al., Double gallbladder, *Gastroenterol. Hepatol.* 19 (2004) 233–235.
- [18] R.C. Goiney, S.A. Schoenecker, D.R. Cyr, et al., Sonography of gallbladder duplication and differential considerations, *AJR Am. J. Roentgenol.* 145 (2) (1985) 241–243.

Open Access

This article is published Open Access at [sciencedirect.com](https://www.sciencedirect.com). It is distributed under the [IJSCR Supplemental terms and conditions](#), which permits unrestricted non commercial use, distribution, and reproduction in any medium, provided the original authors and source are credited.