

[CASE REPORT]

Neuromyelitis Optica Spectrum Disorder Complicated by Posterior Reversible Encephalopathy Syndrome as an Initial Manifestation

Tomoaki Shima, Shuhei Tsujino, Kairi Yamashita, Takuro Hirayama, Kaori Fukushima, Tadashi Kanamoto, Rie Ohta, Atsushi Nagaoka, Shunsuke Yoshimura, Teiichiro Miyazaki, Yohei Tateishi, Hirokazu Shiraishi and Akira Tsujino

Abstract:

A 25-year-old woman was admitted to our hospital due to tonic convulsion with severe headache after having experienced symptoms of nausea and vomiting for a month. Brain magnetic resonance imaging showed extensive symmetrical lesions in the cortical and subcortical areas of parieto-occipital lobes and basal ganglia, consistent with typical characteristics of posterior reversible encephalopathy syndrome (PRES). Furthermore, some residual lesions in the left side of dorsal medulla oblongata and central area of the cervical spinal cord along with the presence of serum anti-aquaporin-4 antibody yielded the diagnosis of neuromyelitis optica spectrum disorder (NMOSD). We herein discuss the mechanism by which PRES may occur together with NMOSD.

Key words: neuromyelitis optica spectrum disorder, posterior reversible encephalopathy syndrome, anti-aquaporin-4 antibody, anti-SS-A antibody

(Intern Med 59: 1887-1890, 2020)

(DOI: 10.2169/internalmedicine.4226-19)

Introduction

Posterior reversible encephalopathy syndrome (PRES) is most commonly encountered in association with acute hypertension, exposure to immunosuppressants, and autoimmune diseases such as systemic lupus erythematosus. A small number of previous reports have shown that PRES may sometimes occur as a complication of neuromyelitis optica spectrum disorder (NMOSD); however, its mechanism remains unknown. We herein report a case of NMOSD complicated by PRES, and discuss the mechanism underlying this co-occurrence.

Case Report

A 25-year-old Japanese woman who underwent eyelid cosmetic surgery a month earlier was prescribed antibiotics

and analgetics for 3 days following surgery. A few days later, symptoms of nausea and vomiting occurred which thereafter gradually worsened. Two weeks before admission, she developed headache and fever and was admitted to another hospital when the headache aggravated. After admission, tonic convulsion occurred and brain magnetic resonance imaging (MRI) showed multiple brain lesions; the patient was then transferred to our hospital. She developed a disturbance of consciousness, and her blood pressure was 127/97 mmHg. Nuchal rigidity was present and patellar reflex was 2+, although Babinski reflex was negative. Laboratory studies showed elevated white blood cells (15,900/ μ L), C-reactive protein (2.79 mg/dL), antinuclear antibody (1:80) and anti-SS-A antibody (>1,200.0 U/mL). Anti-double-stranded DNA antibody, anti-Sm antibody, anti-cardiolipin antibody, lupus anticoagulant, anti-SS-B antibody, and anti-neutrophil cytoplasmic antibodies (p-ANCA and c-ANCA) were within the normal ranges. A cerebrospinal fluid (CSF)

Department of Neurology and Stroke, Nagasaki University Hospital, Japan

Received: November 20, 2019; Accepted: March 6, 2020; Advance Publication by J-STAGE: April 23, 2020

Correspondence to Dr. Tomoaki Shima, tomoakishima0915@nagasaki-u.ac.jp

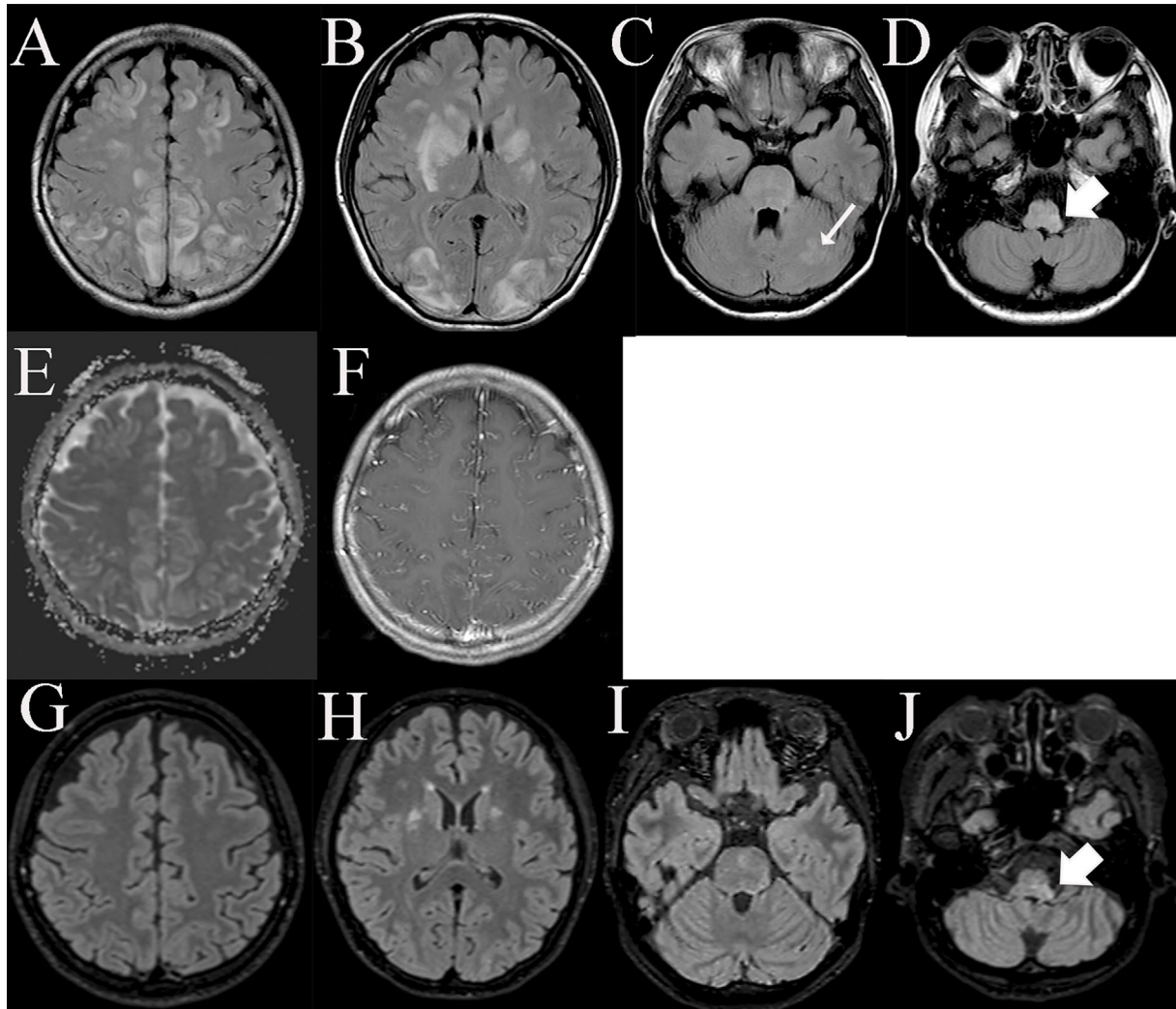


Figure 1. Brain MRI on admission (A-F) and after methylprednisolone pulse therapy (G-J). MRI shows symmetrical parieto-occipital, cortical, and subcortical lesions with a hyperintense signal on FLAIR (A) and on an apparent diffusion coefficient map (E), and these lesions are accompanied by leptomeningeal enhancement on postcontrast T1-weighted images (F). FLAIR images demonstrate hyperintense signal lesions in bilateral basal ganglia and occipital lobes (B), left cerebellar hemisphere (thin arrow, C), and left side of dorsal medulla oblongata (thick arrow, D). After methylprednisolone pulse therapy, the lesions in parieto-occipital lobes disappeared (G) and lesions in basal ganglia shrunk greatly (H). Left cerebellar hemisphere lesion also disappeared (I) but lesions in the dorsal medulla oblongata remained (thick arrow, J). MRI: magnetic resonance imaging, FLAIR: fluid attenuated inversion recovery

examination revealed mononuclear pleocytosis (27 cells/ μ L) with mildly elevated protein (53 mg/dL) and normal glucose levels (90 mg/dL). Further, a CSF analysis indicated an increase in myelin basic protein (905 pg/mL), although the IgG index was within the normal range and oligoclonal bands were negative. Brain MRI showed extensive symmetrical lesions in parieto-occipital, cortical and subcortical areas, and in basal ganglia, which appeared hyperintense on fluid attenuated inversion recovery (FLAIR) and an apparent diffusion coefficient (ADC) map (Fig. 1A, B and E). The lesions in left cerebellar hemisphere revealed the same signal intensities (Fig. 1C). We also found lesions on the left side of the dorsal medulla oblongata, which appeared hyperin-

tense on FLAIR (Fig. 1D). The parieto-occipital lesions were accompanied by leptomeningeal enhancement on post-contrast T1-weighted images (Fig. 1F). MRI of the spine showed lesions in the cervical spinal cord, especially in the central gray matter, which appeared to be hyperintense on T2-weighted sequences (Fig. 2). There was no lesion in the thoracic region or the lumbar spinal cords. Though the clinical course and brain MRI images suggested PRES, the patient did not have any associated factors of PRES such as hypertensive crisis and was not taking any immunosuppressive agents. As a result, we considered an autoimmune disease as the cause of PRES. Intravenous methylprednisolone (IVMP) was administered at 1,000 mg/day, and the follow-

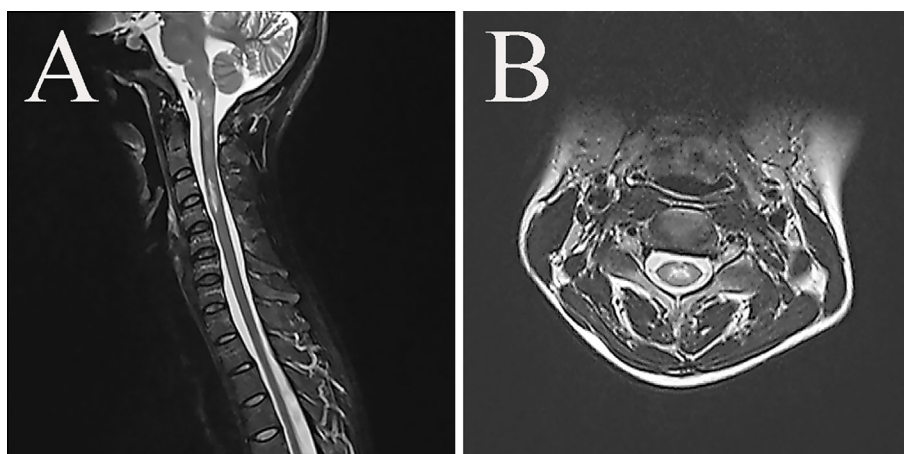


Figure 2. Spinal cord MRI in sagittal (A) and axial (B) T2-weighted images show lesions in cervical spinal cord with hyperintense signal, especially in the central gray matter. MRI: magnetic resonance imaging

ing day the patient recovered consciousness. Neurological examinations revealed nystagmus, dysarthria, and paresthesia in the left upper limb. A positive result was obtained for anti-aquaporin-4 antibody (AQP4-Ab) (17.6 U/mL), and the patient was treated with 3 courses of IVMP (1,000 mg/day for three days) that resulted in the disappearance of neurological symptoms. Brain MRI showed that lesions in the parieto-occipital lobes and left cerebellar hemisphere had disappeared and lesions in basal ganglia had shrunk greatly, but some lesions in the dorsal medulla oblongata and cervical spinal cord remained (Fig. 1G-J). She was then prescribed prednisolone at 10 mg/day and tacrolimus at 3 mg/day as recurrence prevention treatment and thus was discharged from the hospital.

Discussion

Neuromyelitis optica (NMO) is an inflammatory disease of the central nervous system (CNS) that is characterized by optic neuritis and myelitis. Since the discovery of AQP4-Ab with high disease specificity in NMO (1), AQP4-Ab positive cases have been found to have various clinical phenotypes. Even cases that do not meet the diagnostic criteria proposed by Wingerchuk et al. in 2006, are referred to as NMOSD if the AQP4-Ab is positive with acute inflammatory CNS lesions (optic nerve, spinal cord, area postrema, other brainstem, diencephalic, or cerebral) (2). In the present case, some residual lesions on the left side of dorsal medulla oblongata and central area of the cervical spinal cord, along with the presence of serum AQP4-Ab suggested NMOSD.

PRES is a pathological condition that exhibits symmetrical vasogenic edema in the cerebral hemisphere due to vascular endothelial dysfunction, and it is most commonly associated with hypertension, eclampsia, drugs, and autoimmune diseases. Treating the causative factors leads to an improvement in both clinical and imaging findings over the course of days to weeks. In our case, the patient's diastolic pressure at admission was slightly elevated, but the mean arterial

pressure was 107 mmHg and the blood pressure after admission remained completely normal without any treatment. Hypertension before admission was not pointed out. Antibiotics and analgetics for 3 days were only taken a month before admission due to tonic convulsion with severe headache. Therefore, we considered that hypertension and drugs were unlikely to have triggered PRES in our case.

According to the radiologic findings, vasogenic edema is consistently present in the parietal or occipital regions (98%), but other locations are also common including the frontal lobes (68%), inferior temporal lobes (40%), cerebellar hemispheres (30%), basal ganglia (14%), and brain stem (13%) (3). Cerebellar involvement is significantly more frequent in patients with autoimmune diseases (4). Recently, Karia et al. identified gadolinium-based contrast enhancement in 43.7% of the patients with PRES and the most common pattern (76%) was leptomeningeal enhancement, though a cortical or nodular pattern of enhancement has also been identified (5). In this case, lesions in both parieto-occipital lobes with leptomeningeal enhancement and basal ganglia, which disappeared immediately with treatment, indicated vasogenic edema is consistent with PRES lesions. Similarly, asymmetrical lesions in the left cerebellar hemisphere were also considered as PRES lesions. Conversely, residual lesions in the dorsal medulla oblongata and cervical spinal cord suggested NMOSD because not only are these common sites for NMOSD but the lesions have also tend to persist after steroid therapy.

To date, at least 12 cases of PRES in NMO/NMOSD (6-11) have been reported, excluding rituximab-associated PRES (12, 13). These cases were all females and 11 of 12 cases had preexisting NMO/NMOSD, while one case had lesions resembling PRES at the onset of NMOSD (11). Magaña et al. proposed that water flux impairment due to AQP-4 autoimmunity might predispose to PRES in NMOSD patients who either have labile blood pressure or treatments that affecting fluid balance such as intravenous immunoglobulin G and plasma exchange (6).

Recently, Takeshita et al. reported that AQP4-Ab induces interleukin 6 (IL-6) production by AQP4-positive astrocytes and that IL-6 signaling to endothelial cells decreases the barrier function (14). Furthermore, Shimizu et al. indicated that glucose-regulated protein 78 (GRP78) autoantibody present in the serum of NMOSD patients was associated with blood-brain barrier disruption (15). Such evidence supports the fact that antibody-related endothelial dysfunction directly contributes to the development of PRES, though neither IL-6 nor GRP78 antibody were measured in our case.

Anti-SS-A antibody, which was extremely high in our patient, may also be involved in the pathogenesis of PRES. NMOSD is known to accompany autoimmune diseases such as Sjögren's syndrome and systemic lupus erythematosus. Park et al. reported that anti-SS-A antibody seropositivity was 37.5% in patients positive for AQP4-Ab (16). Alexander et al. indicated that SS-A antigens are expressed in human endothelial cells and that anti-SS-A antibody may be associated with disruption of the blood-brain barrier (17). Interestingly, Jeong et al. reported PRES to be an initial neurological manifestation of primary Sjögren's syndrome, in which case AQP4-Ab was also weakly positive (18). Therefore, the anti-SS-A antibody in the present case may also be associated with disruption of the blood-brain barrier, along with AQP4-Ab. We should therefore consider asymptomatic Sjögren's syndrome due to its effects on the pathogenesis, although a salivary gland biopsy was not performed in the present case since no xerosis was observed.

Conclusion

The findings of this case suggested that in NMOSD, vascular endothelial cells may be damaged by autoantibodies which may thus lead to the onset of concomitant PRES.

The authors state that they have no Conflict of Interest (COI).

References

- Lennon VA, Kryzer TJ, Pittock SJ, Verkman AS, Hinson SR. IgG marker of optic-spinal multiple sclerosis binds to the aquaporin-4 water channel. *J Exp Med* **202**: 473-477, 2005.
- Wingerchuk DM, Banwell B, Bennett JL, et al. International panel for NMO diagnosis. International consensus diagnostic criteria for neuromyelitis optica spectrum disorders. *Neurology* **85**: 177-189, 2015.
- Bartynski WS, Boardman JF. Distinct imaging patterns and lesion distribution in posterior reversible encephalopathy syndrome. *AJNR Am J Neuroradiol* **28**: 1320-1327, 2007.
- Fugate JE, Claassen DO, Cloft HJ, Kallmes DF, Kozak OS, Rabinstein AA. Posterior reversible encephalopathy syndrome: associated clinical and radiologic findings. *Mayo Clin Proc* **85**: 427-432, 2010.
- Karia SJ, Rykken JB, McKinney ZJ, Zhang L, McKinney AM. Utility and significance of gadolinium-based contrast enhancement in posterior reversible encephalopathy syndrome. *AJNR Am J Neuroradiol* **37**: 415-422, 2016.
- Magaña SM, Matiello M, Pittock SJ, et al. Posterior reversible encephalopathy syndrome in neuromyelitis optica spectrum disorders. *Neurology* **72**: 712-717, 2009.
- Shimazaki H, Ando A, Nakamura Y, Kanbayashi T, Tanaka K, Nakano I. A case of neuromyelitis optica complicated by posterior reversible encephalopathy syndrome and a papillary thyroid cancer. *Nihon Naika Gakkai Zasshi (Journal of Japanese Society of Internal Medicine)* **99**: 1913-1915, 2010 (in Japanese).
- Igel C, Garretto D, Robbins MS, Swerdlow M, Judge N, Dayal A. Neuromyelitis optica in pregnancy complicated by posterior reversible encephalopathy syndrome, eclampsia and fetal death. *J Clin Med Res* **7**: 193-195, 2015.
- Benmoh Y, Hamid M, Arrami A, et al. Neuromyelitis optica spectrum disorders associated to posterior reversible encephalopathy syndrome: pathogenesis, diagnosis, treatment and evolution: a case report and literature review. *J Neurol Neurophysiol* **9**: 472, 2018.
- Kamo H, Ueno Y, Sugiyama M, et al. Pontine hemorrhage accompanied by neuromyelitis optica spectrum disorder. *J Neuroimmunol* **330**: 19-22, 2019.
- Kim SM, Kim JS, Heo YE, Yang HR, Park KS. Cortical oscillopsia without nystagmus, an isolated symptom of neuromyelitis optica spectrum disorder with anti-aquaporin 4 antibody. *Mult Scler* **18**: 244-247, 2012.
- Sánchez-Carteyron A, Alarcia R, Ara JR, Martín J. Posterior reversible encephalopathy syndrome after rituximab infusion in neuromyelitis optica. *Neurology* **74**: 1471-1473, 2010.
- Berger JR, Neltner J, Smith C, Cambi F. Posterior reversible encephalopathy syndrome masquerading as progressive multifocal leukoencephalopathy in rituximab treated neuromyelitis optica. *Mult Scler Relat Disord* **3**: 728-731, 2014.
- Takeshita Y, Obermeier B, Cotleur AC, et al. Effects of neuromyelitis optica-IgG at the blood-brain barrier in vitro. *Neurol Neuroimmunol Neuroinflamm* **4**: e311, 2016.
- Shimizu F, Schaller KL, Owens GP, et al. Glucose-regulated protein 78 autoantibody associates with blood-brain barrier disruption in neuromyelitis optica. *Sci Transl Med*. Forthcoming.
- Park JH, Hwang J, Min JH, Kim BJ, Kang ES, Lee KH. Presence of anti-Ro/SSA antibody may be associated with anti-aquaporin-4 antibody positivity in neuromyelitis optica spectrum disorder. *J Neurol Sci* **348**: 132-135, 2015.
- Alexander EL, Ranzanbach MR, Kumar AJ, et al. Anti-Ro(SS-A) autoantibodies in central nervous system disease associated with Sjögren's syndrome (CNS-SS): clinical, neuroimaging, and angiographic correlates. *Neurology* **44**: 899-908, 1994.
- Jeong HN, Suh BC, Kim YB, Chung PW, Moon HS, Yoon WT. Posterior reversible encephalopathy syndrome as an initial neurological manifestation of primary Sjögren's syndrome. *Clin Auton Res* **25**: 259-262, 2015.

The Internal Medicine is an Open Access journal distributed under the Creative Commons Attribution-NonCommercial-NoDerivatives 4.0 International License. To view the details of this license, please visit (<https://creativecommons.org/licenses/by-nc-nd/4.0/>).