

Case Report

Durable and Complete Response to Herceptin Monotherapy in Patients with Metastatic Gastroesophageal Cancer

Brenen P. Swofford^a Tomislav Dragovich^b

^aUniversity of Arizona College of Medicine – Phoenix, Phoenix, AZ, USA; ^bBanner MD Anderson Cancer Center, Gilbert, AZ, USA

Keywords

Gastroesophageal carcinoma · Adenocarcinoma · HER2 overexpression · Trastuzumab · Herceptin

Abstract

Gastroesophageal cancer is the sixth leading cause of cancer-related death worldwide. The 2 most common histologies are squamous cell carcinoma and adenocarcinoma, which has seen an increase in incidence correlating with an increase in obesity in developed countries. Gastroesophageal adenocarcinoma has a preponderance to metastasize early, making it a highly lethal cancer with a low 5-year survival rate of ~15–25%. Therefore, for the majority of patients, treatment focuses on palliation and prolongation of survival. Combination chemotherapy regimens, mostly platinum-based, have only modestly prolonged survival in patients with stage IV disease. Recently, it was discovered that the activation of the HER2 receptor plays an important role in a minority of adenocarcinomas of the distal esophagus and stomach. This introduced the treatment option of trastuzumab (Herceptin), a monoclonal antibody directed at the HER2 receptor, which has demonstrated improvement in overall and progression-free survival as noted in the ToGA trial. Currently, the role of Herceptin therapy beyond first-line therapy and outside of combination regimens is not well established. In this

KARGER

Brenen Swofford, DO
Banner – University Medical Center Phoenix
1111 E. McDowell Road
Phoenix, AZ 85006 (USA)
E-Mail Brenen.Swofford@bannerhealth.com

Tomislav Dragovich, MD, PhD
Banner MD Anderson Cancer Center
2940 E Banner Gateway Dr., Suite 450
Gilbert, AZ 85234 (USA)
E-Mail Tomislav.Dragovich@bannerhealth.com

case report we review 2 cases of patients with gastroesophageal cancer, with HER2 overexpression, who achieved a robust response to trastuzumab in combination with chemotherapy and were able to maintain a durable response with maintenance trastuzumab monotherapy.

© 2017 The Author(s)
Published by S. Karger AG, Basel

Introduction

Esophageal cancer can be separated into 2 main categories, squamous cell carcinoma or adenocarcinoma. It is estimated that ~17,000 cases of esophageal cancer will be diagnosed in the USA yearly [1, 2]. Additionally, ~15,000 annual deaths are expected from this malignancy [1, 2]. In the USA, there has been a decline in the incidence of squamous cell carcinoma of the esophagus, but an increase in adenocarcinoma has also been noted [1, 3]. This change is believed to be due to a decrease in tobacco usage but an increasing patient population with obesity [1, 3].

Previous studies have demonstrated that a history of smoking, alcohol consumption, or a diet lacking fruits and vegetables accounts for ~90% of esophageal squamous cell cancers in the USA [1, 2]. The majority of adenocarcinomas arise from Barrett metaplasia of the esophagus due to gastroesophageal reflux disease [1, 2]. Other important risk factors include smoking, alcohol consumption, and obesity [1, 2].

While the risk factors are similar, the pathology of these 2 types of esophageal cancer differs dramatically. Squamous cell carcinomas are often diagnosed in the midportion of the esophagus and arise from denuded epithelium or plaques [2, 4]. These early lesions become infiltrating or ulcerated masses and disseminate quickly to include the local lymph nodes and lymphatics [4]. Distant metastases occur to the liver, lung, and bone and are seen in ~30% of patients [5]. Adenocarcinoma most commonly occurs along the gastroesophageal junction, and results from Barrett metaplasia [4, 6]. Early lesions present as an ulcer or nodule, and lymph node metastases occur early in this disease process [4, 6]. Clinical manifestations include dysphagia from esophageal obstruction, weight loss due to dysphagia, and tumor-related anorexia and nausea/vomiting [4, 6].

Cancers of the gastroesophageal tract have a relatively high mortality, mostly because of their preponderance to metastasize quickly [4, 6]. Locally advanced, unresectable, and metastatic cancers of the gastrointestinal tract are not curable [2, 6]. The overall survival rate at 5 years is estimated to be 15–25% [7]. Goals of therapy include palliation of symptoms and prolongation of survival. Multidisciplinary management utilizing endoscopic procedures, surgical interventions, systemic chemotherapy, and radiotherapy are the primary therapeutic approaches in the management of this cancer. Overexpression and/or amplification of the HER2 receptor has been associated with an aggressive growth pattern of esophageal and gastric cancers [8]. It is estimated that between 10 and 30% of gastroesophageal adenocarcinomas overexpress HER2 [8]. The addition of the therapeutic monoclonal antibody targeting the HER2 receptor (trastuzumab, Herceptin) to chemotherapy was evaluated in a randomized trial and demonstrated improvement in progression-free and overall survival in the first-line therapy of metastatic gastroesophageal adenocarcinomas overexpressing HER2 [8]. There is limited data or experience in this population when utilizing trastuzumab after progression with first-line therapy or as maintenance monotherapy. The following 2 case reports demonstrate a complete and long-lasting response utilizing trastuzumab in combination with induction chemotherapy and as maintenance therapy in the management of metastatic esophageal adenocarcinoma.

Case Presentation

The first case involves a 66-year-old male who was diagnosed with gastroesophageal junction adenocarcinoma. He presented with symptoms consistent with GERD and epigastric discomfort. He underwent an upper endoscopy in February 2014, at which time a 4-cm mass was noted, and biopsy confirmed adenocarcinoma, staged as T3N1Mx (Fig. 1). The patient underwent concurrent chemoradiation with carboplatin/paclitaxel in March 2014 and completed treatment in April 2014. An esophagectomy was performed in June 2014. However, during a restaging scan 3 months later a posterior right lower lobe pulmonary nodule was noted. The nodule was biopsied and proved to be metastatic adenocarcinoma. His performance status was 1 as measured by the ECOG scale. The patient underwent 6 cycles of FOLFOX. The tissue specimen was noted to overexpress HER2; therefore trastuzumab was added to chemotherapy in January 2015. After achieving complete PET CT response in June 2015, the therapy was switched to maintenance trastuzumab (consisting of 6 mg/kg every 3 weeks). Restaging CT scans in November 2015 revealed stable disease without progression. Another PET CT in February 2016 demonstrated no evidence of recurrent disease or active residual disease. The patient was tolerating trastuzumab therapy, and multiple surveillance ECHO examinations did not demonstrate change in his cardiac ejection fraction. At the present time, more than 3 years since the original diagnosis of metastatic adenocarcinoma, repeat staging scans have failed to demonstrate any evidence of recurrence or disease progression (Fig. 1).

The second case is a 61-year-old male who presented with acid reflux symptoms in early May 2015. He underwent an EGD with a mass noted, and a biopsy was obtained confirming the diagnosis of gastroesophageal adenocarcinoma (Fig. 2). Staging scans revealed pulmonary nodules which were biopsied and demonstrated the presence of metastatic adenocarcinoma. The tumor tissue was amplified for HER2, with overexpression noted. His performance status was 0 as measured by the ECOG scale. The patient started combination chemotherapy with docetaxel, cisplatin, and capecitabine plus trastuzumab (Herceptin). Unfortunately, the patient became neutropenic and a dose adjustment was made. PET CT performed in August 2015 demonstrated an excellent response with the previously affected nodal areas now completely regressed. Capecitabine was discontinued after 3 cycles due to severe fatigue and hand-foot syndrome but docetaxel, cisplatin, and trastuzumab were continued for an additional 5 cycles. Given the continued response, cisplatin was discontinued and the patient continued on docetaxel and trastuzumab for another 2 cycles. In February 2016 repeat staging scans revealed no evidence of active disease; therefore docetaxel was discontinued and the patient was continued on trastuzumab maintenance (6 mg/kg every 3 weeks). The patient tolerated this therapy well, and ECHO examinations did not reveal a decrease in cardiac ejection fraction. However, after 3 months of trastuzumab maintenance therapy a PET CT scan demonstrated disease progression in the left supraclavicular lymph nodes. Paclitaxel was introduced while trastuzumab therapy continued. However, after 2 months on this therapy he demonstrated slight progression of disease and the therapy was then changed to FOLFIRI plus trastuzumab. He completed 6 cycles of this combination with evidence of complete remission on PET CT scan. At that time (January 2017) he received consolidative radiation therapy (50.4 Gy) to the primary tumor field and previously involved nodal areas including the supraclavicular lymph nodes. The patient completed radiation therapy (with capecitabine as radiation sensitizer) in March 2017 and was continued on maintenance therapy of trastuzumab. PET CT in June 2017 failed to demonstrate any evidence of disease recurrence or active metastatic disease process (Fig. 2). The patient has

continued on trastuzumab maintenance therapy with continued evidence of a complete response 30 months after the diagnosis of metastatic disease (last evaluation with PET CT was in September 2017).

Discussion

Since the 1970s the incidence of squamous cell carcinoma has been declining while the incidence of adenocarcinoma of the distal esophagus and gastroesophageal junction has been on the rise [1, 3]. The diagnosis of adenocarcinoma carries a poor prognosis as this malignancy metastasizes quickly and has a high recurrence rate [2, 6]. Therefore, therapy has largely focused on the palliation of symptoms, improvement of the quality of life, and prolongation of survival.

Between 10 and 30% of gastroesophageal adenocarcinomas have amplification and/or overexpression of HER2 [8]. HER2 is an epidermal growth factor receptor involved in the transmission of growth factor signaling that promotes cellular proliferation and inhibits apoptosis [8]. This was initially discovered in breast cancer models and led to the development of a therapeutic anti-HER2 monoclonal antibody (trastuzumab, Herceptin) [8]. Roughly 10 years later this concept was explored in patients with gastric and esophageal adenocarcinomas which were found to overexpress HER2 [8].

The benefit of adding trastuzumab to chemotherapy in patients with metastatic gastroesophageal adenocarcinomas with HER2 overexpression was demonstrated in the ToGA trial [9]. This trial compared standard chemotherapy (6 cycles of cisplatin + either fluorouracil or oral capecitabine) with and without trastuzumab (given as a loading dose of 8 mg/kg and then 6 mg/kg every 3 weeks as a maintenance dose) [9]. The objective response rate was higher in those subjects who received trastuzumab, and the median overall survival was significantly increased in this group [9]. Based on results from this trial, trastuzumab was approved in combination with cisplatin and fluoropyrimidines for the first-line therapy of patients with metastatic HER2-positive adenocarcinoma [9]. Future studies are aimed at optimizing dosing, schedule, sequence, and additive or synergistic benefits of combining trastuzumab with different chemotherapy regimens.

The dosing and schedule of trastuzumab was further studied in the HELOISE trial, which compared maintenance dosing of 10 mg/kg every 3 weeks to 6 mg/kg every 3 weeks [10]. The 10 mg/kg dosing did not demonstrate an associated increase in efficacy [10]. Many clinicians utilize the cardiac ineligibility criteria from the North American adjuvant Herceptin trials, which are utilized in breast cancer, as exclusion criteria [11]. Further studies are necessary to evaluate whether these criteria may be applied to gastroesophageal adenocarcinoma which tests positive for HER2. Additionally, the current literature is limited with regard to the length and sequence of trastuzumab therapy in patients with gastric or esophageal adenocarcinomas. For patients with HER2-positive breast cancer, the maintenance duration of trastuzumab therapy has been set to 52 weeks [11]. The concept of continuing HER2 receptor blockade beyond progression on chemotherapy has demonstrated benefit in patients with metastatic HER2-overexpressing breast cancer [11].

An additional factor which may affect the expression of HER2 and therapeutic options is the location of the tumor. In a study completed by Van Cutsem et al. [12], a correlation was noted in HER2 positivity and location of the tumor. Patients with specimens from the gastroesophageal junction had a higher HER2 positivity than those tumors found in the body of the stomach [12]. As noted in the case report above, both of the patients presented had tu-

mors located in the gastroesophageal junction. This is reminiscent of another study that demonstrated response to anti-EGFR targeting in patients with gastroesophageal cancer compared to more distal tumors in the stomach [13]. Based upon these studies, it appears that the location of gastroesophageal adenocarcinoma plays an important role in its responsiveness to targeted therapies [12, 13].

These case reports demonstrate rarely seen complete response to the combination of trastuzumab with a chemotherapy regimen, followed by long-lasting remissions on trastuzumab maintenance monotherapy. While these 2 cases are anecdotal, they raise important questions regarding optimization of trastuzumab therapy in HER2-overexpressing gastroesophageal adenocarcinomas, beyond first-line combination therapy. There is a clear precedence for continuing biologic therapy beyond progression in breast cancer (trastuzumab) and colon cancer (bevacizumab). Given the increasing efficacy, and also unfortunately the toxicity of combination chemotherapy regimens for gastric and esophageal cancers, the concept of maintenance therapy and/or a “STOP and GO” approach becomes increasingly appealing in this disease. Further studies are required to evaluate the duration of therapy, the prognosis status of HER2 positivity, and the overall survivability of metastatic gastroesophageal adenocarcinoma with HER2 expression.

Statement of Ethics

The authors certify that the material in this case report has been acquired according to modern ethical standards and has been presented in such a fashion as to protect the rights of the individuals involved.

Disclosure Statement

All authors certify and confirm that no conflicts of interest exist within this case report.

References

- 1 Salvon-Harman JC, Cady B, Nikulasson S, et al: Shifting proportions of gastric adenocarcinomas. *Arch Surg* 1994;129:381.
- 2 Hölscher AH, Bollschweiler E, Schneider PM, Siewert JR: Prognosis of early esophageal cancer. Comparison between adeno- and squamous cell carcinoma. *Cancer* 1995;76:178.
- 3 SEER Cancer Statistics. <http://www.seer.cancer.gov/statistics/> (accessed March 31, 2011).
- 4 Meltzer SJ: The molecular biology of esophageal carcinoma. *Recent Results Cancer Res* 1996;142:1.
- 5 Thorban S, Roder JD, Nekarda H, et al: Immunocytochemical detection of disseminated tumor cells in the bone marrow of patients with esophageal carcinoma. *J Natl Cancer Inst* 1996;88:1222.
- 6 Lieberman MD, Shriver CD, Bleckner S, Burt M: Carcinoma of the esophagus. Prognostic significance of histologic type. *J Thorac Cardiovasc Surg* 1995;109:130.
- 7 Custodio A, Carmona-Bayonas A, Jiménez-Fonseca P, et al: Nomogram-based prediction of survival in patients with advanced oesophagogastric adenocarcinoma receiving first-line chemotherapy: a multicenter prospective study in the era of trastuzumab. *Br J Cancer* 2017;116:1526.
- 8 Bartley AN, Washington MK, Ventura CB, et al: HER2 testing and clinical decision making in gastroesophageal adenocarcinoma: guideline from the College of American Pathologists, American Society for Clinical Pathology, and American Society of Clinical Oncology. *Arch Pathol Lab Med* 2016;140:1345.
- 9 Bang YJ, Van Cutsem E, Feyereislova A, et al: Trastuzumab in combination with chemotherapy versus chemotherapy alone for treatment of HER2-positive advanced gastric or gastro-oesophageal junction cancer (ToGA): a phase 3, open-label, randomised controlled trial. *Lancet* 2010;376:687.

- 10 Shah MA, Xu RH, Bang YJ, et al: HELOISE: phase IIIb randomized multicenter study comparing standard-of-care and higher-dose trastuzumab regimens combined with chemotherapy as first-line therapy in patients with human epidermal growth factor receptor 2-positive metastatic gastric or gastroesophageal junction adenocarcinoma. *J Clin Oncol* 2017;35:2558.
- 11 Perez EA, Romond EH, Suman VJ, et al: Trastuzumab plus adjuvant chemotherapy for human epidermal growth factor receptor 2-positive breast cancer: planned joint analysis of overall survival from NSABP B-31 and NCCTG N9831. *J Clin Oncol* 2014;32:3744.
- 12 Van Cutsem E, Bang YJ, et al: HER2 screening data from ToGA: targeting HER2 in gastric and gastroesophageal junction cancer. *Lancet* 2010;376:1302.
- 13 Dragovich T, McCoy S, et al: Phase II trial of erlotinib in gastroesophageal junction and gastric adenocarcinomas: SWOG 0127. *J Clin Oncol* 2007;25:2334.

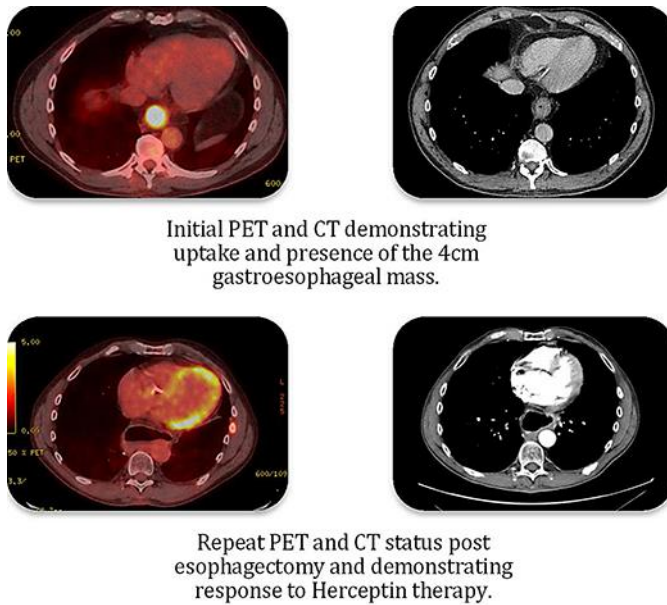
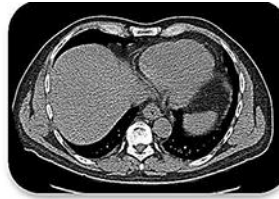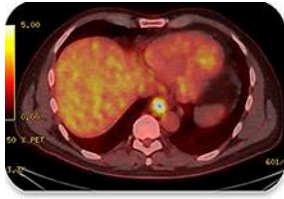

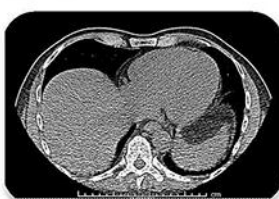
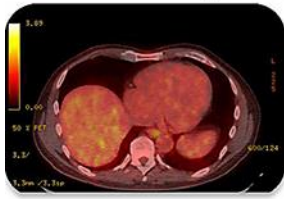Fig. 1. PET and CT images demonstrating the first patient's (66-year-old male) response with initial and final imaging.



Initial PET and CT
demonstrating
gastroesophageal mass.



Repeat PET and CT status
demonstrating response to
Herceptin therapy.

Fig. 2. PET and CT images demonstrating the second patient's (61-year-old male) response with initial and final imaging.