

Initial experience with phacoemulsification and goniotomy using the Kahook dual blade in advanced open-angle glaucoma: Six-month outcomes in Indian eyes

Rashmi Krishnamurthy, Sirisha Senthil, Nikhil Choudhari

Purpose: The aim of this study was to report our initial experience on the outcomes of phacoemulsification in combination with goniotomy using the Kahook Dual Blade (KDB) in eyes with advanced open-angle glaucoma (OAG). **Methods:** The outcomes of phaco-goniotomy with KDB in advanced OAG in Indian eyes were retrospectively analyzed. Based on the Hodapp-Anderson-Parrish criteria of visual field defects, severe glaucoma (mean deviation on standard automated perimetry worse than 12 dB) was considered as advanced glaucoma. Preoperative, intraoperative, and postoperative data were collected through 6 months of follow-up. Outcome measures included antiglaucoma medications (AGM), the proportion of eyes achieving >1AGM reduction, intraocular pressure (IOP), and visual acuity. **Results:** Median (interquartile range) number of AGM in eyes that underwent phaco-KDB goniotomy reduced from 2 (2,3) at baseline to 1 (0,1) at 6 months ($P = 0.002$). Median IOP reduced from 20 (20,26) mmHg at baseline to 14 (12,15) mmHg at 6 months ($P = 0.02$). The proportion of eyes achieving >1 medication reduction was 88% eyes (8/9). Adverse events noted were IOP spike (22 mmHg) in 2 eyes and intra-op hyphema in 1 eye on postoperative day-1, both resolved in a week with conservative management. Except one eye with central corneal scar due to prior pterygium surgery, 8 eyes had 20/20 vision at 1 week which was maintained till last follow-up. **Conclusion:** Phacoemulsification with KDB Goniotomy significantly lowered the need for AGM with moderate IOP reduction in advanced OAG eyes. There were no serious complications and the visual recovery was good and early.

Key words: Goniotomy, Indian eyes, intraocular pressure, Kahook Dual blade, open-angle glaucoma

Combined cataract surgery with trabeculectomy is the conventional surgery in eyes with coexistent cataract and advanced open-angle glaucoma (OAG).^[1] Recently, combining micro-invasive glaucoma surgery (MIGS) with cataract surgery has gained popularity in many parts of the world due to its better safety profile.^[2-4] Although the intraocular pressure (IOP) lowering is modest, a significant reduction in number of antiglaucoma medications (AGM) is reported.^[5] However, our experience with MIGS is limited due to their non-availability in India. In developing countries, delayed presentation, advanced glaucoma, issues with compliance to medications, and lack of affordability demand combined surgery in these eyes.^[6,7]

Kahook Dual Blade (KDB) (New World Medical, Rancho Cucamonga, CA, USA) is a single-use ophthalmic surgical blade designed to perform ab-interno goniotomy and excision of trabecular meshwork (TM) strip to help restore the conventional aqueous outflow pathway.^[5]

The current series is a pilot study to report the efficacy and safety of KDB goniotomy combined with cataract surgery in eyes with advanced OAG in Indian eyes.

Methods

Three surgeons (RKM, SIR, NKL) were trained to perform KDB goniotomy under the guidance of an experienced surgeon in performing KDB goniotomy (DS). The study was approved

VST Glaucoma Centre, L V Prasad Eye Institute, Hyderabad, Telangana, India

Correspondence to: Dr. Sirisha Senthil, L.V. Prasad Eye Institute, Kallam Anji Reddy campus, L.V. Prasad Marg, Road No: 2, Banjara Hills, Hyderabad - 500 034, Telangana, India. E-mail: sirishasenthil@lvpei.org

Received: 25-Sep-2020

Revision: 26-Jan-2021

Accepted: 12-Apr-2021

Published: 25-Aug-2021

Video Available on:
www.ijo.in

Access this article online

Website:
www.ijo.in

DOI:
10.4103/ijo.IJO_2999_20

Quick Response Code:



by our institutional review board and adhered to the tenets of declaration of Helsinki. Consenting patients aged >50 years, advanced stage of OAG (both primary and Pseudoexfoliation glaucoma), with visually significant cataract, glaucomatous disc damage, visual field mean deviation worse than -12dB on standard automated perimetry, and IOP <30 mmHg on >1 topical AGM needing cataract surgery or combined surgery between June 2019 to December 2019 were included. They underwent combined cataract surgery with in-the-bag posterior chamber intra-ocular lens (PCIOL) implantation and simultaneous KDB goniotomy. Advanced glaucoma was defined based on the modified visual field severity criteria, based on Standard Automated Perimetry (SAP) mean deviation (MD) defined by Hodapp, Anderson, and Parrish.^[8] MD worse than 12.0 dB was classified as severe glaucoma based on the above criteria.^[8] Patients with prior glaucoma surgery, angle-closure glaucoma, and <6 months of follow-up were excluded. Rationale for doing KDB goniotomy was to achieve a reduction in the number of AGM and IOP reduction in these eyes with advanced glaucoma.

Surgical technique [Video Clip 1]

A 2.8 mm clear corneal entry was made superiorly or temporally based on the surgeon's discretion. Standard

This is an open access journal, and articles are distributed under the terms of the Creative Commons Attribution-NonCommercial-ShareAlike 4.0 License, which allows others to remix, tweak, and build upon the work non-commercially, as long as appropriate credit is given and the new creations are licensed under the identical terms.

For reprints contact: WKHLRPMedknow_reprints@wolterskluwer.com

Cite this article as: Krishnamurthy R, Senthil S, Choudhari N. Initial experience with phacoemulsification and goniotomy using the Kahook dual blade in advanced open-angle glaucoma: Six-month outcomes in Indian eyes. Indian J Ophthalmol 2021;69:2484-7.

phacoemulsification with in-the-bag PCIOL implantation was first performed. Microscope eyepiece was tilted 45° toward the surgeon. Cohesive viscoelastic (sodium hyaluronate 1.4%) was used to fill the anterior chamber (AC) and under-surface of the Swan-Jacob direct goniolens. Lens was placed on the cornea to visualize the inferior or nasal (opposite) angle structures. Through the clear corneal entry, KDB was inserted into the AC, and the TM was first pierced with the tip and lifted along the ramp (KDB design shown in Fig. 1). KDB was advanced along the Schlemm’s canal either in clockwise or counter-clockwise direction to excise about 90°–110° of TM tissue. The floating TM strip was removed with the micro-forceps. Blood reflux seen was washed along with the residual viscoelastic at the end of surgery (steps of surgery described in Fig. 2).




Figure 1: Kahook Dual Blade design: sharp tip - blue circle, ramp - yellow star, and dual blades - yellow dotted double arrow

Data included demographic details, logMAR visual acuity, IOP, and number of AGM at (pre and post-surgery) visits. Outcome measures were number of AGM, IOP, vision, and complications.

Statistical analysis

Statistical analysis was performed using software STATA ver. 14 (StataCorp, College Station, TX, USA). Due to the small sample size, data is presented using median and interquartile range.

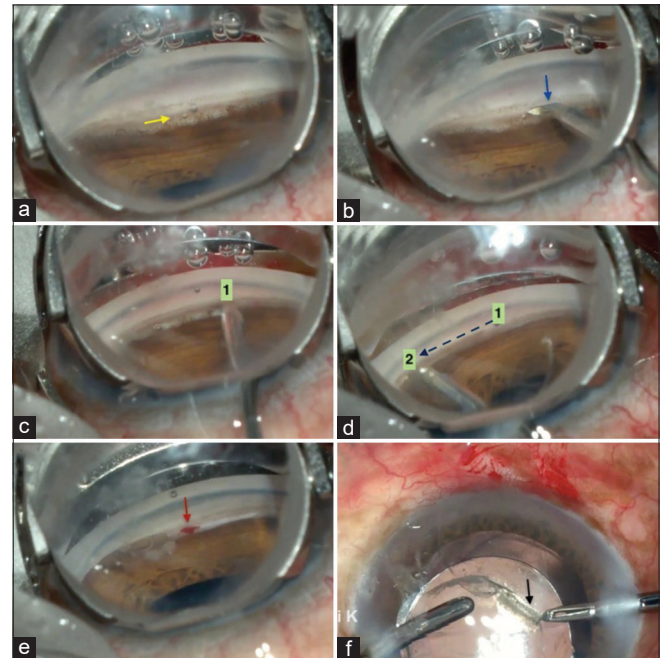


Figure 2: Steps of KDB goniotomy (a) Visualization of trabecular meshwork (yellow arrow) and angle with the help of goniotomy lens; (b) introduction of KDB blade (blue arrow) up to the opposite angle through the 2.8 mm clear corneal incision; (c) starting point of goniotomy (point 1); (d) end point of goniotomy (point 2); (e) blood reflux (red arrow) from Schlemm’s canal; (f) removal of residual TM strip (black arrow) with Utrata’s forceps]

Table 1: Baseline demographic data of 9 patients

	<i>n</i> (%)	Median (interquartile range)	Range
Age in years	-	66 (61, 70)	55-72
Gender <i>n</i> (%)		-	-
Male	7 (78%)		
Female	2 (22%)		
Eye <i>n</i> (%)		-	-
RE	1 (11%)		
LE	8 (89%)		
Glaucoma type <i>n</i> (%)		-	-
POAG	3 (33%)		
PXFG	6 (67%)		
LogMAR visual acuity	-	0.4 (0.2, 1.5)	0.1-2
Baseline IOP (mm Hg)	-	20 (20,26)	16-42
Pre-op number of AGM	-	2 (2, 3)	1-3
Preop IOP with AGM (mmHg)	-	16 (16,17)	14-26
Cup-disc ratio	-	0.9 (0.9,0.9)	0.7-0.9
Mean deviation on SAP in mean±standard deviation	-	-23.04±6.29	-15.21 to -31.78

n=number, RE=Right eye, LE=Left eye, POAG=Primary open angle glaucoma, PXFG=Pseudo-exfoliation glaucoma, LogMAR=Logarithm of the Minimum Angle of Resolution, IOP=intraocular pressure, AGM=antiglaucoma medication

Table 2: AGM used and IOP at each time point

	Number of AGM Median (interquartile range)	P (change from baseline)	IOP (mmHg)	IOP Range (mmHg)	P (change from baseline)
Baseline	2 (2,3)	-	20 (20,26)	16-42	-
Day 1	1 (1,1)	0.007	13 (12,15)	8-22	0.01
Week 1	1 (0,1)	0.0007	15 (14,17)	10-19	0.008
Month 1	1 (0,1)	0.0002	13 (12,17)	8-18	0.001
Month 3	1 (0,1)	0.0005	15 (13,15)	10-16	0.02
Month 6	1 (0,1)	0.002	14 (12,15)	10-17	0.02

AGM=antiglaucoma medication, IOP=intraocular pressure

Table 3: Incidence of adverse events

Adverse event	Number of eyes (%)	Resolution time
Corneal edema	4	1 week
Intraocular pressure spikes (>=22 mm Hg)	2	1 week
Intra-op hyphema	1	1 day

Results

Thirteen patients underwent KDB goniotomy between June 2019 and December 2019. Three patients underwent stand-alone KDB goniotomy and hence were excluded. One patient with prior trabeculectomy underwent phaco-KDB goniotomy and was also excluded from the study. Thus, 9 patients met the inclusion criteria and the baseline demographic data is given in Table 1.

The median (interquartile range) number of AGM reduced from 2 (2,3) at baseline to 1 (0,1) ($P = 0.002$) at 6 months [Table 2]. At the last follow-up, 3 eyes (33%) did not require any AGM and 6 (67%) eyes were on 1 AGM (despite IOP being less than 20 mmHg). The decision to continue one AGM from day 1 postoperatively was in view of advance stage of glaucoma.

The median IOP reduced from 20 (20,26) mmHg at baseline to 14 (12,15) mmHg at 6 months ($P = 0.02$) [Table 3]. At baseline, 7 (78%) patients had IOP <18mmHg on 1-3 AGM and 2 (22%) had IOP of 26 mmHg on 3AGM. At last follow-up, percentage of eyes with IOP <18 and <14 mmHg was 100% and 55%, respectively.

The median baseline Logarithm of the Minimum Angle of Resolution (LogMAR) visual acuity was 0.4 (0.2,1.5). At last follow-up, LogMAR visual acuity was 0.0 in 8 (of 9) eyes. One eye had a nebular corneal scar due to previous pterygium surgery and was thus attributed to LogMAR vision of 0.8 at last follow-up.

Adverse event of intra-op hyphema was noticed in one patient ($n = 1$) on day-1 postoperatively. Two eyes developed IOP spike of 22 mmHg on day 1 postoperatively. However, they resolved in a week with conservative management.

Discussion

In eyes with co-existent cataract and advance glaucoma, combined surgery is preferred to reduce IOP or number of AGM or to prevent postoperative IOP spikes.^[1,9,10] Traditional filtration surgery (trabeculectomy) has the risk of complications such as hypotony, bleb leak, shallow AC, choroidal detachment, rarely sight-threatening complications like wipe-out, hypotony maculopathy, blebitis, and endophthalmitis.^[1,9] Risk of

wipeout is associated with increased intra-orbital pressure by the peribulbar anesthesia, digital ocular massage causing mechanical optic nerve compression, and possibly by the intraoperative and postoperative IOP fluctuations.^[11]

Studies on micro-invasive glaucoma surgeries (MIGS) combined with cataract surgery under topical anesthesia have reported them to be a safe and effective treatment option in open-angle glaucoma.^[5,12-14] Most of the resistance to aqueous outflow in OAG is offered by the trabecular meshwork. Various MIGS procedures are described to overcome this TM resistance.^[2,13,15] The techniques are designed to achieve this by one of the following mechanisms: destroy the TM (using trabectome), excise the TM (using KDB goniotomy) or bypass the TM (using istent, Hydrus), or ab-interno GATT (gonioscopy assisted transluminal trabeculotomy).^[2-4] Goniotomy (angle surgery) as a treatment modality for childhood glaucoma is performed since a long time;^[16] hence, the learning curve of KDB goniotomy was not very steep as the surgeons were competent in performing goniotomy with a needle or MVR (micro-vitreoretinal) blade.

In our series, we retrospectively analyzed the intermediate results of combined phaco-KDB Goniotomy in Indian eyes. Median baseline untreated IOP was 20 (20,26) mmHg. This dropped to 16 (16,17) mmHg after starting the AGM preoperatively. Due to the presence of cataract, advance disc damage, and borderline IOP, we preferred cataract surgery combined with KDB goniotomy. We did not include eyes with IOP >30 mmHg. The mean IOP drop after KDB goniotomy in the previously published studies by Greenwood *et al.*^[5] and Dorairaj *et al.*^[12] was around 4 mmHg. We too observed 4 mmHg IOP drop similar to the above studies in severe glaucoma [Table 4].

The advantages of decreasing the number of topical AGM would be an improvement in compliance, reduction in medical treatment cost, and decrease in the ocular surface toxicity from long-term use of AGM.^[7] We noted a significant reduction in the number of AGM by 1.7 meds ($P = 0.002$) in our study which was similar to the study done by Greenwood *et al.*^[5] where the AGM decreased from 1.6 ± 1.3 to 0.9 ± 1.0 ($P < 0.005$). Apart from self-resolving hyphema, none of the sight-threatening complications like cystoid macular edema, corneal edema, epi-retinal membrane, cyclodialysis cleft, and iridodialysis as reported in few studies (<3%, $n = 1-3$),^[10,17,18] were seen in our series.

This preliminary data marks the beginning of MIGS in India. KDB-goniotomy in our series was safe and effective in reducing the number of AGM and IOP and also helped faster visual recovery in eyes with advanced glaucoma that underwent combined cataract surgery and KDB-goniotomy. In view of no bleb related problems and fewer transient postoperative complications, this procedure would help with decreasing the number of postoperative follow-up visits compared to

Table 4: Comparison with other studies that included *severe glaucoma and had 6 months of follow-up

Study design (n)	Mean reduction of AGM (n)	Mean reduction of IOP (mmHg) (%)	Complication apart from self-limiting hyphema persisting >1 month	Resurgery % (n)
Hirabayashi <i>et al.</i> ^[18] Retrospective (n=42)	1.2	2.1±1.8	7.1% (CME n=2; ERM n=1)	7.1% (3) (-one case of MicroPulse laser trabeculoplasty -one case of Xen® gel stent, and -one case of Ahmed valve implantation)
Salinas <i>et al.</i> ^[10] Retrospective (n=53)	1.2	4.5±2.6 (23.9%)	2 Corneal edema 7 IOP spike >10 mmHg from baseline 1 Vitreous Hmg	1.88% (1) (One case of glaucoma drainage device)
Greenwood <i>et al.</i> ^[5] Prospective interventional case series (n=71)	0.7	4.6±2.6 26%	2 IOP spike (2.8%) 1 Corneal edema 1 CME 1 Iridodialysis (1.4% each)	Not mentioned
Our study Pilot study (n=9)	1.6	3.8±2.5	4 Corneal edema 2 IOP spike (seen on day 1 and All resolved in 1 week)	Nil

IOP=intraocular pressure, n=number, AGM=antiglaucoma medication, CME=cystoid macular edema, ERM=epiretinal membrane, Hmg=hemorrhage

trabeculectomy. Cost of KDB would be a limitation; however, increased usage and possible Indian manufacturing may make it more affordable. The biggest limitation is a small series in this pilot study. However, the prospective long-term comparative studies with phaco-trabeculectomy would give us better insights into this new technique in our population.

Conclusion

Phaco-KDB goniotomy definitely has a role to play in the management of advanced open angle glaucomas with its safety and efficacy as was seen in our pilot study.

Acknowledgements

Syril K Dorairaj (DS), MS, Department of Ophthalmology, Mayo Clinic, 4500 San Pablo Road, Jacksonville, FL4776, USA, for helping in learning the technique.

Funding

Hyderabad Eye Research Foundation (HERF)

Financial support and sponsorship

Nil.

Conflicts of interest

There are no conflicts of interest.

References

- Carlson DW, Alward WL, Barad JP, Zimmerman MB, Carney BL. A randomized study of mitomycin augmentation in combined phacoemulsification and trabeculectomy. *Ophthalmology* 1997;104:719-24.
- Dhingra D, Bhartiya S. Evaluating glaucoma surgeries in the MIGS context. *Rom J Ophthalmol* 2020;64:85-95.
- Lavia C, Dallorto L, Maule M, Ceccarelli M, Fea AM. Minimally-invasive glaucoma surgeries (MIGS) for open angle glaucoma: A systematic review and meta-analysis. *PLoS One* 2017;12:e0183142.
- Richter GM, Coleman AL. Minimally invasive glaucoma surgery: Current status and future prospects. *Clin Ophthalmol* 2016;10:189-206.
- Greenwood MD, Seibold LK, Radcliffe NM, Dorairaj SK, Aref AA, Roman JJ, *et al.* Goniotomy with a single-use dual blade: Short-term results. *J Cataract Refract Surg* 2017;43:1197-201.
- Ramakrishnan R, Khurana M. Surgical management of glaucoma: An Indian perspective. *Indian J ophthalmol* 2011;59(Suppl 1):S118-22.
- Rajurkar K, Dubey S, Gupta PP, John D, Chauhan L. Compliance to topical anti-glaucoma medications among patients at a tertiary hospital in North India. *J Curr Ophthalmol* 2018;30:125-9.
- Hodapp E, Parrish RKII, Anderson DR. *Clinical Decisions in Glaucoma*. St Louis: Mosby. 1993. p. 52-61.
- Gedde SJ, Schiffman JC, Feuer WJ, Herndon LW, Brandt JD, Budenz DL, *et al.* Three-year follow-up of the tube versus trabeculectomy study. *Am J Ophthalmol* 2009;148:670-84.
- Salinas L, Chaudhary A, Berdahl JP, Lazcano-Gomez GS, Williamson BK, Dorairaj SK, *et al.* Goniotomy using the kahook dual blade in severe and refractory glaucoma: 6-month outcomes. *J Glaucoma* 2018;27:849-55.
- Aggarwal SP, Hendeles S. Risk of sudden visual loss following trabeculectomy in advanced primary open-angle glaucoma. *Br J Ophthalmol* 1986;70:97-9.
- Dorairaj SK, Seibold LK, Radcliffe NM, Aref AA, Jimenez-Roman J, Lazcano-Gomez GS, *et al.* 12-Month outcomes of goniotomy performed using the kahook dual blade combined with cataract surgery in eyes with medically treated glaucoma. *Adv Ther* 2018;35:1460-9.
- Dorairaj SK, Kahook MY, Williamson BK, Seibold LK, ElMallah MK, Singh IP. A multicenter retrospective comparison of goniotomy versus trabecular bypass device implantation in glaucoma patients undergoing cataract extraction. *Clin Ophthalmol* 2018;12:791-7.
- Berdahl JP, Gallardo MJ, ElMallah MK, Williamson BK, Kahook MY, Mahootchi A, *et al.* Six-month outcomes of goniotomy performed with the kahook dual blade as a stand-alone glaucoma procedure. *Adv Ther* 2018;35:2093-102.
- Wakil SM, Birnbaum F, Vu DM, McBurney-Lin S, ElMallah MK, Tseng H. Efficacy and safety of kahook dual blade goniotomy: 18-month results. *J Cataract Refract Surg* 2020;46:1408-15.
- Barkan O. Micro-surgery in chronic simple glaucoma. *Cal West Med* 1938;48:10-2.
- Le C, Kazaryan S, Hubbell M, Zurakowski D, Ayyala RS. Surgical outcomes of phacoemulsification followed by istent implantation versus goniotomy with the kahook dual blade in patients with mild primary open-angle glaucoma with a minimum of 12-month follow-up. *J Glaucoma* 2019;28:411-4.
- Hirabayashi MT, King JT, Lee D, An JA. Outcome of phacoemulsification combined with excisional goniotomy using the Kahook Dual Blade in severe glaucoma patients at 6 months. *Clin Ophthalmol* 2019;13:715-21.