



Colposcopy at a turning point

Kyehyun Nam

Department of Obstetrics and Gynecology, Soonchunhyang University Bucheon Hospital, Bucheon, Korea

For women who have abnormal Pap test results, the biopsy under colposcopic evaluation is the gold standard for determining the treatment modality. To increase the effectiveness of colposcopic communication, the International Federation for Cervical Pathology and Colposcopy (IFCPC) recently published fourth new nomenclature, aiming to create an evidence-based terminology. To increase the diagnostic accuracy of colposcopy, multiple biopsies of two or more sites are recommended. Recently, with the introduction of human papillomavirus (HPV) vaccine for cervical cancer prevention, pre-cancerous diseases caused by virus types 16 and 18 have been reduced, which is expected to reduce the number of colposcopic examinations and make colposcopic diagnosis more difficult.

Keywords: Colposcopy; Papillomaviridae; Uterine cervical neoplasms

Introduction

In 2012, 527,600 individuals were diagnosed with and 265,700 died from cervical cancer worldwide, making it the fourth most frequently diagnosed cancer and the fourth leading cause of cancer death among women. In developing countries, it is the second most common cancer and is the third highest cause of death after breast and lung cancers [1]. However, the occurrence of cervical cancer has decreased by >80% over the past 40 years in high income countries that have good cervical cancer screening systems in place [2]. Such a decrease can be attributed to effective treatment of pre-malignant cervical lesions through Pap cytology and colposcopy performed nationwide on all women. In Republic of Korea, cervical cancer was the seventh most common cancer among women in 2014, with 3,500 women being diagnosed with cervical cancer, which represented an annual percent change (APC) of -3.7% in cervical cancer occurrence since 1999 [3]. When abnormal Pap test results are found, cervical conization was performed unquestionably in the past, but this has changed in recent times to determining the appropriate treatment modality based on the biopsy results via colposcopy. This has reduced indiscriminate cervical conization.

Colposcopy is used to determine the biopsy site in women who have abnormal Pap test results and, in an effort to increase the accuracy of colposcopic diagnosis and facilitate communication, the International Federation for Cervical Pathology and Colposcopy (IFCPC) recently announced fourth

new nomenclatures based on revised colposcopic terminology. Since human papillomavirus (HPV) infection was identified as a key factor in the occurrence of cervical cancer, testing for HPV has been used for cervical cancer screening. In addition, an HPV vaccine was developed and has been used for cervical cancer prevention since 2006. Meanwhile, the accuracy of colposcopy has since been questioned due to issues associated with random biopsies and biopsy numbers. Accordingly, this article will discuss colposcopic terminology, accuracy of colposcopy, and the impacts of HPV testing and vaccination on colposcopy.

2011 colposcopic terminology

Colposcopy was developed in 1925 by Hans Hinselmann and

Received: 2017.06.08. Revised: 2017.07.10. Accepted: 2017.07.10.

Corresponding author: Kyehyun Nam

Department of Obstetrics and Gynecology, Soonchunhyang University Bucheon Hospital, 170 Jomaru-ro, Wonmi-gu, Bucheon 14584, Korea

E-mail: khnam@schmc.ac.kr

<http://orcid.org/0000-0003-3893-3968>

Articles published in *Obstet Gynecol Sci* are open-access, distributed under the terms of the Creative Commons Attribution Non-Commercial License (<http://creativecommons.org/licenses/by-nc/3.0/>) which permits unrestricted non-commercial use, distribution, and reproduction in any medium, provided the original work is properly cited.

Copyright © 2018 Korean Society of Obstetrics and Gynecology

has been used since. Initially, it was used for clinical cervical cancer screening before the introduction of Pap cytology. In recent years, it has predominately been used for identifying the biopsy site for secondary histological diagnosis when abnormal Pap results are found. Direct biopsies via colposcopy have an important role in determining the treatment modality. The IFCPC has revised and published three editions of colposcopic terminology; in 1975, 1990, and 2002. The current fourth edition was announced at the World Congress held in Rio de Janeiro, Brazil, on July 5, 2011 (Table 1). Notable revisions included that the terms “satisfactory” and “unsatisfactory” were replaced by “adequate” and “inadequate,” respectively. In the current edition, colposcopy must test for the following three variables: 1) adequate or inadequate, with the reason given; 2) squamocolumnar junction visibility; and 3) transformation zone type. Moreover, the current edition also calls for additional descriptions on the size and location of cervical lesions, as well as descriptions on whether such lesions are located inside or outside of the transformation zone. For high grade lesions, 2 new major signs were also added;

“inner border sign” (Fig. 1) and “ridge sign” (Fig. 2) [4]. A study that investigated the diagnostic value of these two newly added terms found their positive predictive value for cervical intraepithelial neoplasia (CIN) grade 2 or worse (CIN 2+) to be 98.3% and 94.7%, respectively [5]. Furthermore, the fourth edition unified and announced colposcopic terminology for the vagina for the first time (Table 2).

Accuracy of colposcopy

Although colposcopy has made an undeniable contribution to the treatment of cervical cancer, the diagnostic accuracy of colposcopy is still controversial. Accuracy issues arise from inconsistencies between visible changes in cervical epithelium and the severity of premalignant lesions [6]. The diagnostic sensitivity of high-grade CIN 2 or worse is reported to be 30%–70% [7-9]. It has been claimed that, to increase the diagnostic accuracy, the number of biopsies must be increased and random biopsies should be performed on areas with no

Table 1. 2011 International Federation of Cervical Pathology and Colposcopy (IFCPC) colposcopic terminology of the cervix

Section	Pattern
General assessment	Adequate or inadequate for the reason (i.e., cervix obscured by inflammation, bleeding, scar). Squamocolumnar junction visibility: completely visible, partially visible, not visible. Transformation zone types 1, 2, 3.
Normal colposcopic finding	Original squamous epithelium: mature, atrophic. Columnar epithelium; ectopy/ectropion. Metaplastic squamous epithelium; nabothian cysts; crypt (gland) openings. Deciduosis in pregnancy.
Abnormal colposcopic finding	
General principles	Location of the lesion: inside or outside the transformation zone; location of the lesion by clock position. Size of the lesion: number of cervical quadrants the lesion covers. Size of the lesion as percentage of cervix.
Grade 1 (minor)	Fine mosaic; fine punctation; thin acetowhite epithelium; irregular, geographic border.
Grade 2 (major)	Sharp border; inner border sign; ridge sign; dense acetowhite epithelium; coarse mosaic; coarse punctuation; rapid appearance of acetowhitening; cuffed crypt (gland) openings.
Nonspecific	Leukoplakia (keratosis, hyperkeratosis), erosion Lugol's staining (Schiller's test): stained or non-stained.
Suspicious for invasion	Atypical vessels. Additional signs: fragile vessels, irregular surface, exophytic lesion, necrosis, ulceration (necrotic), tumor or gross neoplasm.
Miscellaneous findings	Congenital transformation zone, condyloma, polyp (ectocervical or endocervical), inflammation, stenosis, congenital anomaly, posttreatment consequence, endometriosis.

Modified from “2011 IFCPC Nomenclature”, by the International Federation of Cervical Pathology and Colposcopy, 2011, available from: <http://www.ifcpc.org/en/healthcare-professionals/resource-material/2011-ifcpc-nomenclature> (copyright 2011 by the International Federation of Cervical Pathology and Colposcopy).

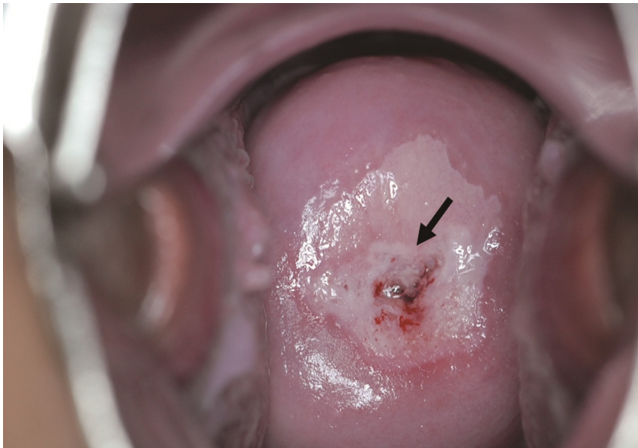


Fig. 1. Inner border sign. The arrow points to the sharp demarcation between outer thin and inner dense acetowhite area that exists within the same lesion.

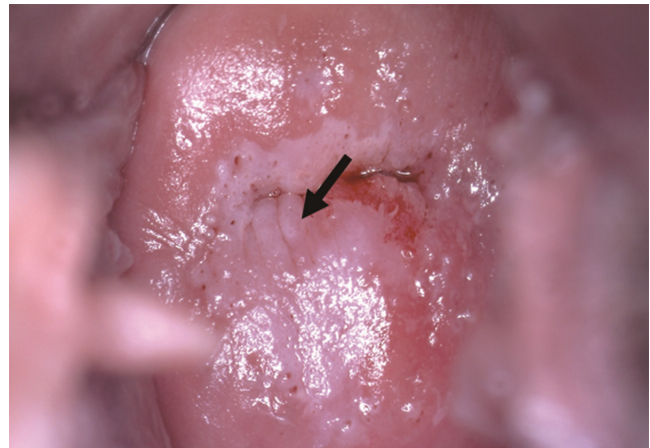

Fig. 2. Ridge sign. The arrow points to the opaque protuberance of an acetowhite lesion after application of 5% acetic acid within the transformation zone.

Table 2. 2011 International Federation of Cervical Pathology and Colposcopy (IFCPC) clinical and colposcopic terminology of the vagina

Section	Pattern
General assessment	Adequate or inadequate for the reason (i.e., inflammation, bleeding, scar) transformation zone.
Normal colposcopic findings	
General principles	Upper third or lower two-thirds. Anterior, posterior, or lateral (right or left).
Grade 1 (minor)	Thin acetowhite epithelium, fine punctuation fine mosaic.
Grade 2 (major)	Dense acetowhite epithelium, coarse punctuation coarse mosaic.
Suspicious for invasion	Atypical vessels. Additional signs: fragile vessels, irregular surface, exophytic lesion, necrosis ulceration (necrotic), tumor or gross neoplasm.
Nonspecific	Columnar epithelium (adenosis). Lesion staining by Lugol's solution (Schiller's test): stained or non-stained, leukoplakia.
Miscellaneous findings	Erosion (traumatic), condyloma, polyp, cyst, endometriosis, inflammation, vaginal stenosis, congenital transformation zone.

Modified from "2011 IFCPC Nomenclature", by the International Federation of Cervical Pathology and Colposcopy, 2011, available from: <http://www.ifcpc.org/en/healthcare-professionals/resource-material/2011-ifcpc-nomenclature> (copyright 2011 by the International Federation of Cervical Pathology and Colposcopy).

signs of disease [9]. Colposcopic accuracy is associated with high sensitivity in high-grade lesions (Fig. 3), but it is much lower in low-grade lesions (Fig. 4). Accuracy of colposcopy began to be questioned due to issues associated with biopsy numbers and random biopsies. Originally, diagnosis was made by performing a single biopsy on the most severe area found on colposcopy. However, performing a single biopsy on the worst appearing lesion can result in missing a third of precancerous findings [10-12]. Moreover, a study reported that increasing the number of biopsies can increase the diagnostic accuracy [10]. By increasing the number of biopsies from 1

to 2, and then from two to three, the precancerous lesion increased substantially. Therefore, biopsies are recommended for acetowhite areas, metaplastic regions, and areas with higher abnormalities; from at least 2 and up to 4 targeted sites from distinct acetowhite lesions.

Random biopsy on areas that appeared to be disease-free in colposcopy found high-grade lesions in 13%–37% of the cases [9,13,14]. Some doctors have claimed that random biopsies should be chosen when performing histological examination via colposcopy, but current official colposcopy guidelines do not recommend random biopsy. Researchers have

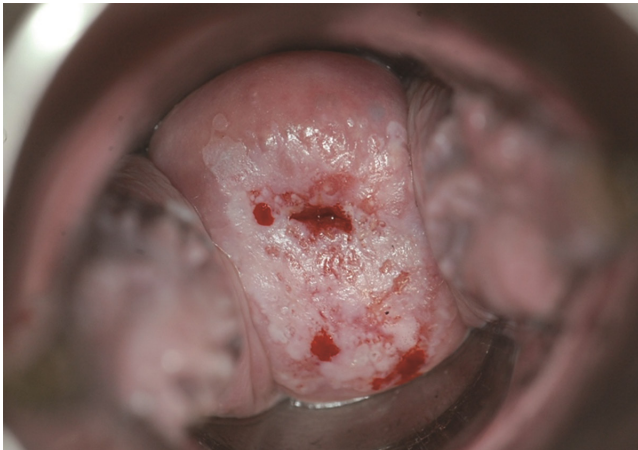


Fig. 3. Dense acetowhite epithelium lesion without abnormal vessels comparable with high-grade lesion.

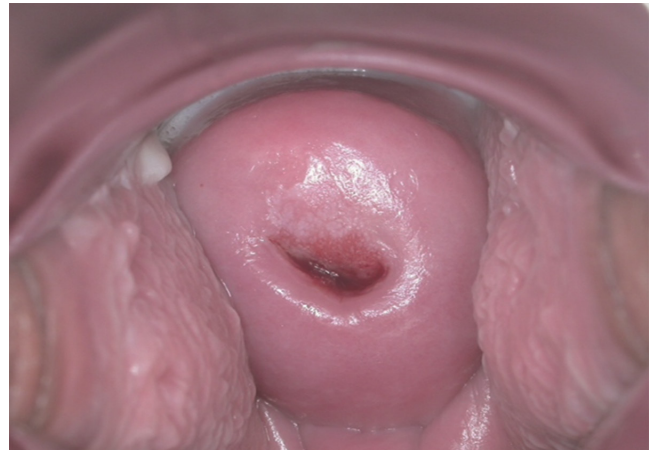

Fig. 4. Thin acetowhite epithelium lesion with fine mosaic vessels comparable with low-grade lesion.

recently published that random biopsies can detect significant diseases in cases with type 16 and 18 infections, even if the disease does not appear on colposcopy [14]. The lesion size of CIN 2 or 3 diagnosed by random biopsy are significantly smaller than lesions diagnosed by colposcopic directed biopsy and involve fewer quadrants of the cervix, associated with old age, low-grade cytology and other than HPV type 16 [9,15]. Similarly, in an Atypical Squamous Cells of Undetermined Significance/Low-Grade Squamous Intraepithelial Lesion Triage Study by Sherman et al. [16], CIN 3 that were missed on initial colposcopy involved very small lesions.

Colposcopy and HPV

The factor that had the greatest impacts on colposcopy is HPV. The hypothesis that HPV has an important role in the carcinogenesis of cervical cancer was presented in the 1970s by Herald Zur Hauxen, and involvement of HPV in the carcinogenesis of cervical cancer became an accepted fact in the 1990s through the distribution of molecular and biological proof. Based on this discovery, HPV testing is being used along with Pap cytology for cancer screening. In 2003, the US Food and Drug Administration (FDA) approved co-testing with traditional Pap cytology and HPV testing for cervical cancer screening [17]. Screening by cytology alone would require such screening to be performed every year but, by adding HPV tests for co-testing, the interval between screenings can be extended to up to 5 years. Moreover, HPV vaccination for the prevention of cervical cancer has been used in clinical set-

tings since 2006. Dr. Hauxen received the 2008 Nobel Prize in Medicine as the discovery of import role of HPV in the carcinogenesis of cervical cancer. HPV testing has higher sensitivity than cytology, which offers the advantage of being able to detect early and smaller preneoplastic lesions.

The impact that the introduction of HPV testing has had on colposcopy can be summarized into 3 major points. First, in the past, when abnormal pap results were found, colposcopy was performed right away. However, guidelines have recently been established that recommend that the presence of lesions should be determined in advance through HPV testing and colposcopy should only be performed when lesions will be detected likely. Moreover, conservative treatment is recommended for pregnant women or low-grade cytology cases. Through co-testing, the interval between screenings has been extended from the traditional interval of 1 year to 2–5 years. These changes have led to a decreasing trend in the number of patients seeking colposcopy [18]. Second, with the introduction of cervical cancer vaccination, premalignant cervical lesions associated with types 16 and 18 have also decreased. In Australia, since the introduction of HPV vaccination, women aged 12–26 years have shown a decrease of 34% in low-grade lesions and 47% in high-grade lesions at 5 years post-vaccination [19]; similar results were also reported from Canada [20]. Third, recent studies have stated that colposcopic findings may vary according to HPV types. In particular, lesions related to type 16 are more definitive and larger than other types [21,22]. Premalignant lesions of other types exhibit colposcopy findings that are less definitive and make diagnosis more difficult. It is believed that the introduc-

tion of the vaccine would further reduce premalignant lesions related to type 16, making colposcopy even more difficult and reducing its usage.

Conclusion

With improved public health and hygiene and the introduction of HPV vaccination, cervical cancer and premalignant lesions have begun to decrease. A decreased number of patients requiring colposcopy has been shown to have an impact on colposcopy education, and thus, novel approaches for colposcopy education are deemed necessary. Moreover, biopsies on 2 or more sites are recommended to increase the accuracy of colposcopy. This year marks 10 years since the introduction of HPV vaccination. Since last year, girls turning 12 years of age have received free cervical cancer vaccination in Republic of Korea. In the future, premalignant lesions associated with HPV types 16 and 18 are expected to decrease even further due to cervical cancer vaccination. Lesions associated with HPV type 16 appear clearly on colposcopy, but as these lesions gradually decrease, the procedures of colposcopy are expected to become even more difficult.

Acknowledgments

I thank Eun-Ae Jung (Librarian, Medical Library, Soonchunhyang University Bucheon Hospital) for carefully proofreading the manuscript. I also thank support from National Testing Lab (NTL) Co., LTD. for the photos of tele-cervicography.

Conflict of interest

No potential conflict of interest relevant to this article was reported.

References

1. Ferlay J, Soerjomataram I, Ervik M, Dikshit R, Eser S, Mathers C, et al. GLOBOCAN 2012 v1.0, cancer incidence and mortality worldwide: IARC cancer base no. 11 [Internet]. Lyon (FR): International Agency for Research on Cancer; 2014 [cited 2017 May 10]. Available from: <http://globocan.iarc.fr>.
2. Sankaranarayanan R. Screening for cancer in low- and middle-income countries. *Ann Glob Health* 2014;80:412-7.
3. National Cancer Center (KR). Annual report of cancer statistics in Korea in 2014 [Internet]. Goyang (KR): National Cancer Center; 2017 [cited 2017 May 10]. Available from: <http://www.ncc.re.kr/cancerStatsView.ncc?bbsnum=397&searchKey=total&searchValue=&pageNum=1>.
4. Bornstein J, Bentley J, Bösze P, Girardi F, Haefner H, Menton M, et al. 2011 colposcopic terminology of the International Federation for Cervical Pathology and Colposcopy. *Obstet Gynecol* 2012;120:166-72.
5. Vercellino GF, Erdemoglu E, Chiantera V, Vasiljeva K, Malak AH, Schneider A, et al. Clinical relevance of objectifying colposcopy. *Arch Gynecol Obstet* 2015;291:907-15.
6. Reid R, Scalzi P. Genital warts and cervical cancer. VII. An improved colposcopic index for differentiating benign papillomaviral infections from high-grade cervical intraepithelial neoplasia. *Am J Obstet Gynecol* 1985;153:611-8.
7. Massad LS, Collins YC. Strength of correlations between colposcopic impression and biopsy histology. *Gynecol Oncol* 2003;89:424-8.
8. Massad LS, Jeronimo J, Katki HA, Schiffman M; National Institutes of Health/American Society for Colposcopy and Cervical Pathology Research Group. The accuracy of colposcopic grading for detection of high-grade cervical intraepithelial neoplasia. *J Low Genit Tract Dis* 2009;13:137-44.
9. Pretorius RG, Zhang WH, Belinson JL, Huang MN, Wu LY, Zhang X, et al. Colposcopically directed biopsy, random cervical biopsy, and endocervical curettage in the diagnosis of cervical intraepithelial neoplasia II or worse. *Am J Obstet Gynecol* 2004;191:430-4.
10. Gage JC, Hanson VW, Abbey K, Dippery S, Gardner S, Kubota J, et al. Number of cervical biopsies and sensitivity of colposcopy. *Obstet Gynecol* 2006;108:264-72.
11. Wentzensen N, Walker JL, Gold MA, Smith KM, Zuna RE, Mathews C, et al. Multiple biopsies and detection of cervical cancer precursors at colposcopy. *J Clin Oncol* 2015;33:83-9.

12. Pretorius RG, Belinson JL, Burchette RJ, Hu S, Zhang X, Qiao YL. Regardless of skill, performing more biopsies increases the sensitivity of colposcopy. *J Low Genit Tract Dis* 2011;15:180-8.
13. Nam K, Chung S, Kwak J, Cha S, Kim J, Jeon S, et al. Random biopsy after colposcopy-directed biopsy improves the diagnosis of cervical intraepithelial neoplasia grade 2 or worse. *J Low Genit Tract Dis* 2010;14:346-51.
14. Huh WK, Sideri M, Stoler M, Zhang G, Feldman R, Behrens CM. Relevance of random biopsy at the transformation zone when colposcopy is negative. *Obstet Gynecol* 2014;124:670-8.
15. Chen Q, Du H, Pretorius RG, Wang C, Yang B, Wang G, et al. High-grade cervical intraepithelial neoplasia detected by colposcopy-directed or random biopsy relative to age, cytology, human papillomavirus 16, and lesion size. *J Low Genit Tract Dis* 2016;20:207-12.
16. Sherman ME, Wang SS, Tarone R, Rich L, Schiffman M. Histopathologic extent of cervical intraepithelial neoplasia 3 lesions in the atypical squamous cells of undetermined significance low-grade squamous intraepithelial lesion triage study: implications for subject safety and lead-time bias. *Cancer Epidemiol Biomarkers Prev* 2003;12:372-9.
17. Wright TC Jr, Schiffman M, Solomon D, Cox JT, Garcia F, Goldie S, et al. Interim guidance for the use of human papillomavirus DNA testing as an adjunct to cervical cytology for screening. *Obstet Gynecol* 2004;103:304-9.
18. Landers EE, Erickson BK, Bae S, Huh WK. Trends in colposcopy volume: where do we go from here? *J Low Genit Tract Dis* 2016;20:292-5.
19. Brotherton JM, Malloy M, Budd AC, Saville M, Drennan KT, Gertig DM. Effectiveness of less than three doses of quadrivalent human papillomavirus vaccine against cervical intraepithelial neoplasia when administered using a standard dose spacing schedule: observational cohort of young women in Australia. *Papillomavirus Res* 2015;1:59-73.
20. Smith LM, Strumpf EC, Kaufman JS, Lofters A, Schwandt M, Lévesque LE. The early benefits of human papillomavirus vaccination on cervical dysplasia and anogenital warts. *Pediatrics* 2015;135:e1131-40.
21. Jeronimo J, Massad LS, Schiffman M; National Institutes of Health/American Society for Colposcopy and Cervical Pathology (NIH/ASCCP) Research Group. Visual appearance of the uterine cervix: correlation with human papillomavirus detection and type. *Am J Obstet Gynecol* 2007;197:47.e1-8.
22. Nam K, Kwak J, Kim J, Jeon S. Human papillomavirus type 16 causes larger colposcopic lesions than other HPV types in patients with grade 3 cervical intraepithelial neoplasia. *J Low Genit Tract Dis* 2013;17:1-5.