

# Partial reimplantation of Tenckhoff catheter for channel perforation and aneurysm: A case series

Shrawan K. Singh, Dig Vijay Singh, Vivekanand Jha<sup>1</sup>, Vinay Sakhuja<sup>1</sup>

Departments of Urology and <sup>1</sup>Nephrology, PGIMER, Chandigarh, India

## ABSTRACT

Tenckhoff catheter placement is a well established procedure to facilitate continuous ambulatory peritoneal dialysis (CAPD) in end-stage renal disease (ESRD) management. The removal and replacement of the catheter following complications adds morbidity in an already immunocompromised patient of ESRD. A salvage procedure with partial replacement was undertaken in four patients on CAPD. By catheter repositioning, the complications of catheter removal (like wound hematoma, abscess, need of break-in period hemodialysis) and of reinsertion (like leak, obstruction, migration, infection and failure) are avoided. It also reduced the economic burden of insertion in a new catheter.

**Key words:** Channel aneurysm, channel perforation, continuous ambulatory peritoneal dialysis, end-stage renal disease, partial replantation, Tenckhoff catheter

## INTRODUCTION

Tenckhoff catheter placement is well established to facilitate continuous ambulatory peritoneal dialysis (CAPD) in the treatment of end-stage renal disease (ESRD). Complications of these catheters, while *in situ*, are well documented.<sup>[1]</sup> The removal and replacement of Tenckhoff catheter for these complications adds morbidity in an already immunocompromised patient of ESRD. We present details of the catheter problems encountered in 4 patients on CAPD over a span of 13 years and describe the salvage procedure of partial re-implantation undertaken in them. Four patients.

## CASE REPORTS

### Case 1

A 60-year-old female, who was on CAPD for 7 years,

For correspondence: Dr. Shrawan Kumar Singh,  
Department of Urology, Post Graduate Institute of Medical  
Education and Research, Chandigarh, India.  
E-mail: shrawansingh2002@yahoo.com

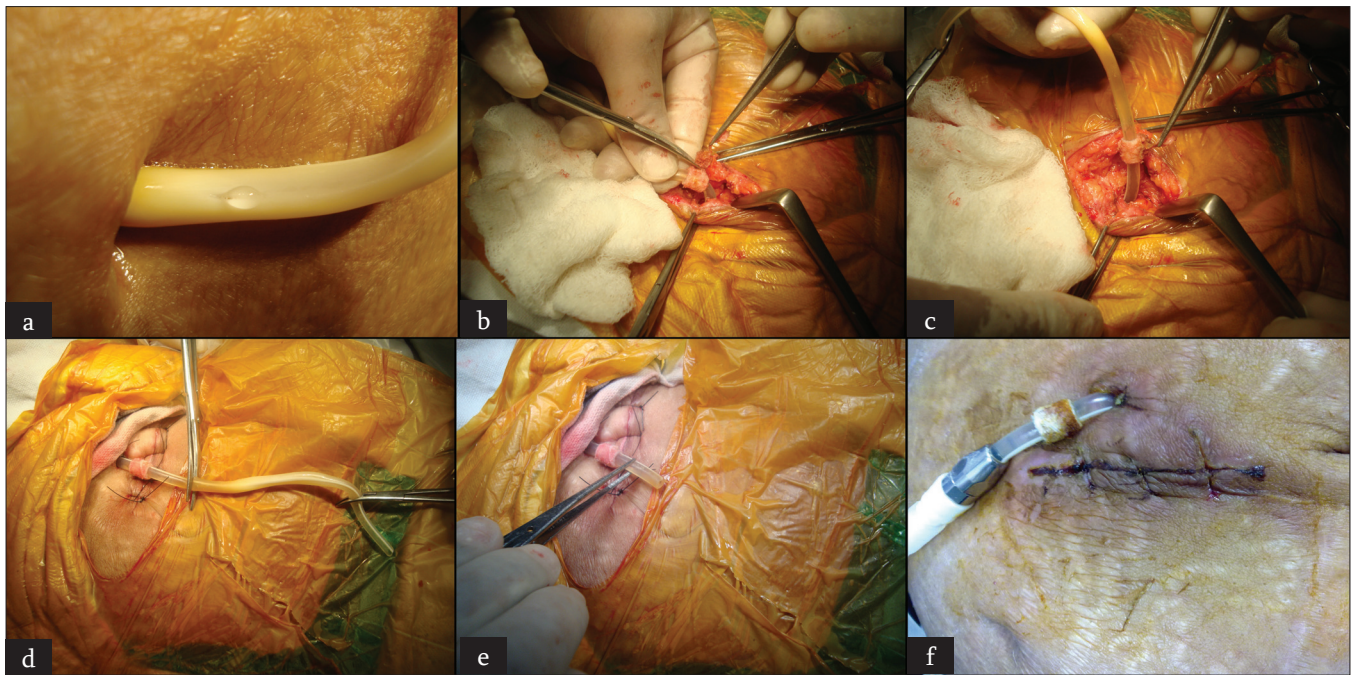
### Access this article online

<b>Quick Response Code:</b> 	<b>Website:</b> <a href="http://www.indianjurol.com">www.indianjurol.com</a>
	<b>DOI:</b> 10.4103/0970-1591.114036

presented with channel perforation of the Tenckhoff catheter. She had no mechanical or infective complication earlier. At presentation, she complained of leak from a perforation of Tenckhoff catheter. She was afebrile with stable vitals. On examination, there was a 2 mm longitudinal crack, 2 cm distal to the skin exit site of the catheter with stenosed distal channel. Peritoneal fluid leak was easily discernible at the site of the crack. There was no pericatheter leakage, edema, or induration at the exit site. Leukocyte count of catheter fluid was within normal limits and culture was sterile. Based on the clinical diagnosis of Tenckhoff catheter's crack, we planned for partial reimplantation. The surgical procedure was performed under local anesthetic 1% lignocaine. We placed the skin incision over the previous scar of catheter insertion. Dissection was carried out along the proximal normal portion of catheter so as to gain adequate length from the looped internal part, which was then exteriorized along with outer Teflon cuff superior to the incision line. This partial replantation was accomplished by excision of catheter proximal to the crack site and fitting the tungsten adapter at the cut end [Figure 1]. Immediately following the procedure, CAPD was re-started and she is undergoing regular dialysis for last 6 months without any complications.

### Case 2

The second case was a 41-year-old male patient who was on CAPD for 2 years. He presented with perforation in the catheter due to accidental injury by a surgical blade while removing the dressing. This was managed in a similar manner to that mentioned earlier. He was on regular dialysis for next 3 years without any catheter-related complication.



**Figure 1:** Sequential images of patient's presentation, operative steps, and postoperative condition of case 1, (a) Leak from crack in catheter (b) Dissection of distal cuff (c) dissection proximal to distal cuff (d) Excising exteriorized catheter proximal to crack (e) adequate length of catheter post excision (f) Two week post procedure

### Case 3

The third case was a 45-year-old male, who presented after 15 months of CAPD catheter insertion, with perforation in the Tenckhoff catheter. The cause of the perforation was frequent cleaning of catheter with spirit. Partial reimplantation was performed. He was advised to avoid any alcoholic antiseptic for catheter care and he continued dialysis from the same catheter for the next 4 years.

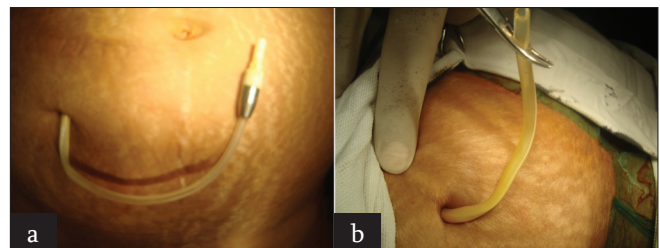
### Case 4

The fourth case was a 50-year-old female patient who reported with aneurysmal dilatation and kinking of the Tenckhoff catheter at the exit site after 3 years of CAPD insertion [Figure 2]. The cause of the problem was not known. Due to very short length of the normal proximal part of the catheter, it required not only partial reimplantation but also attachment of the extension channel to the catheter *in situ*. In the follow-up at 6 months, she was not suffering from any CAPD-related problems.

The clinical summary of the cases is given in Table 1.

## DISCUSSION

Tenckhoff catheter insertion for CAPD is a procedure associated with significant surgical morbidity. It is associated with both early and late complications like catheter migration, catheter obstruction, exit-site/tunnel infection (ESTI), leak from the main incision, wound infection, post-insertion peritonitis, and hemoperitoneum.<sup>[1,2]</sup>



**Figure 2:** Aneurysmal dilatation and distal narrowing of Tenckhoff catheter of case 4 (a) aneurysmal dilatation at exit site (b) distal narrow lumen

Removing a catheter because of intractable ESTI seems to be justified by the fact that presence of foreign bodies, such as the catheter, usually makes complete eradication of infective pathogens difficult. The cuff and the catheter, once invaded by infective pathogens, are apt to provide a milieu of persistent colonization. In such situation, removal of the whole catheter may be mandatory if the tunnel infection has extended to the inner cuff area (usually diagnosed by the presence of tender swelling in the proximal tunnel region or by sonographic finding of fluid accumulation in that region); otherwise, removal of a part of the catheter is sufficient to treat ESTI. Total replantation and even partial replantation have been the established treatment modalities for ESTI.<sup>[3,4]</sup>

However, partial replantation of Tenckhoff catheters is indicated for patients who meet the criteria like positive culture of exit-site discharge with negative culture of ascites, erythema, or tenderness localized over the exit site or the distal part of the tunnel, relapse or no response after

**Table 1: Clinical summary of four cases**

Cases	Age/sex	Duration b/w catheter insertion and damage	Cause of catheter damage	Condition	Management	Follow-up
1	60/F	7 years	Stenosis	Perforation	Partial reimplantation	2 years
2	41/M	2 years	Surgical blade	Perforation	Partial reimplantation	3 years
3	45/M	15 months	Catheter damage by spirit	Perforation	Partial reimplantation	4 years
4	50/F	3 years	Not known	Aneurysm dilatation	Partial reimplantation and extension channel attachment	6 months

antibiotic therapy for 3 weeks, and no sign of infection over the internal cuff area but near-cuff perforation of the catheter which is a troublesome problem. High risk of ascending infection, irritation of exit site, and painful sensation are noted after repairing the perforation with glue.<sup>[4]</sup> Wu *et al.* performed partial reimplantation in 26 cases out of which 24 cases had ESTI and 2 cases were due to channel perforation. They used extension channel as a new double-cuffed catheter connected to the native one by a segment of siliconized tube and always removed the native cuffed channel.<sup>[4]</sup> On the other hand, in our series of four cases, the cause of intervention was perforation and channel aneurysm instead of ESTI. We preserved the proximal normal portion of catheter, exteriorizing it with the outer cuff, and there was no need of extension channel except for the fourth case where there was an inadequate length of proximal normal catheter. Hence, the added economic burden of using extension channel for every replantation is unwarranted.

By repositioning the catheter, we avoided not only the complications of catheter removal like wound hematoma and abscess, but also the need of break-in period hemodialysis and its complications.<sup>[5]</sup> Besides psychological benefits, it also reduced the economic burden of reinsertion without

compromising the outcome. Partial reimplantation of a Tenckhoff catheter is a simple and effective procedure for patients with near-cuff perforation of the catheter.

## REFERENCES

1. Stuart S, Booth TC, Cash CJ, Hameeduddin A, Goode JA, Harvey C, *et al.* Complications of continuous ambulatory peritoneal dialysis. *Radiographics* 2009;29:441-60.
2. Tiong HY, Poh J, Sunderaraj K, Wu YJ, Consigliere DT. Surgical complications of Tenckhoff catheters used in continuous ambulatory peritoneal dialysis. *Singapore Med J* 2006;47:707-11.
3. Chao SH, Tsai TJ. Partial replantation of Tenckhoff catheters to treat intractable exit-site/tunnel infection. *J Am Soc Nephrol* 1996;7:1085-7.
4. Wu YM, Tsai MK, Chao SH, Tsai TJ, Chang KJ, Lee PH. Surgical management of refractory exit-site/tunnel infection of Tenckhoff catheter: Technical innovations of partial replantation. *Perit Dial Int* 1999;19:451-4.
5. Cheng YL, Chau KF, Choi KS, Wong FK, Cheng HM, Li CS. Peritoneal catheter-related complications: A comparison between hemodialysis and intermittent peritoneal dialysis in the break-in period. *Adv Perit Dial* 1996;12:231-4.

**How to cite this article:** Singh SK, Singh DV, Jha V, Sakhuja V. Partial reimplantation of Tenckhoff catheter for channel perforation and aneurysm: A case series. *Indian J Urol* 2013;29:133-5.

**Source of Support:** Nil, **Conflict of Interest:** None declared.

## Dispatch and return notification by E-mail

The journal now sends email notification to its members on dispatch of a print issue. The notification is sent to those members who have provided their email address to the association/journal office. The email alerts you about an outdated address and return of issue due to incomplete/incorrect address.

If you wish to receive such email notification, please send your email along with the membership number and full mailing address to the editorial office by email.