

Evaluation of Tracheobronchial Diseases: Comparison of Different Imaging Techniques

Qihang Chen, MD^{1,2}
Jin Mo Goo, MD¹
Joon Beom Seo, MD³
Myung Jin Chung, MD¹
Yu-Jin Lee, MD¹
Jung-Gi Im, MD¹

Index words :

Bronchi, CT
Computed tomography (CT),
three-dimensional
Computed tomography (CT),
volume rendering

Korean J Radiol 2000 ; 1 : 135-141

Received July 7, 2000; accepted
after revision August 25, 2000.

Department of ¹Radiology, Seoul National University College of Medicine and the Institute of Radiation Medicine, SNUMRC; Department of ²Radiology, Beijing Hospital; Department of ³Radiology, Gil Medical Center, Gachon Medical School

Supported in part by a research grant from BK21

Address reprint requests to :

Jung-Gi Im, MD, Department of Radiology, Seoul National University Hospital, 28 Yongon-dong, Chongno-gu, Seoul 110-744, Korea.
Telephone: (822) 760-3338
Fax: (822) 743-6385
e-mail: imjg@radcom.snu.ac.kr

Objective: To compare the clinical utility of the different imaging techniques used for the evaluation of tracheobronchial diseases.

Materials and Methods: Forty-one patients with tracheobronchial diseases [tuberculosis (n = 18), bronchogenic carcinoma (n = 10), congenital abnormality (n = 3), post-operative stenosis (n = 2), and others (n = 8)] underwent chest radiography and spiral CT. Two sets of scan data were obtained: one from routine thick-section axial images and the other from thin-section axial images. Multiplanar reconstruction (MPR) and shaded surface display (SSD) images were obtained from thin-section data. Applying a 5-point scale, two observers compared chest radiography, routine CT, thin-section spiral CT, MPR and SSD imaging with regard to the detection, localization, extent, and characterization of a lesion, information on its relationship with adjacent structures, and overall information.

Results: SSD images were the most informative with regard to the detection (3.95 ± 0.31), localization (3.95 ± 0.22) and extent of a lesion (3.85 ± 0.42), and overall information (3.83 ± 0.44), while thin-section spiral CT scans provided most information regarding its relationship with adjacent structures (3.56 ± 0.50) and characterization of the lesion (3.51 ± 0.61).

Conclusion: SSD images and thin-section spiral CT scans can provide valuable information for the evaluation of tracheobronchial disease.

A spiral CT scanner can obtain a volumetric data set, and by means of various retrospective reconstruction techniques such as multiplanar reconstruction (MPR) imaging, multiplanar volume reconstruction imaging, three-dimensional (3-D) shaded-surface display (SSD) and virtual bronchoscopy, this can be displayed in a number of ways. The use of these techniques can lead to more accurate evaluation of tracheobronchial diseases. Two- and three-dimensional (2-D and 3-D) images are advantageous for the detection of mild stenoses and horizontal webs, evaluating the dimensions of an airway narrowing, and displaying congenital airway abnormalities (1–5). Conventional CT remains the “gold standard” in the imaging of airway disease, though endobronchial lesions in the central airway can be missed on routine thick-section CT (6–7). The purpose of our study was to evaluate the clinical utility of 2-D and 3-D spiral CT in tracheobronchial diseases by comparing it with chest radiography and routine thick-section CT and thin-section spiral CT.

MATERIALS AND METHODS

Between January 1994 and March 1999, 126 patients with known or suspected ab-

normality of central airways underwent spiral thin-section CT scanning with 3-D SSD imaging. In 41 of the 126, all chest radiographs and routine thick-section CT, thin-section spiral CT, MPR and 3-D SSD images were available. This retrospective study was based on these 41 cases.

Fifteen of the patients were men and 26 were women, and they were aged between 21 and 71 (mean, 45) years. The final diagnoses were endobronchial tuberculosis (n = 18), bronchogenic carcinoma (n = 10), congenital abnormality (n = 3), post-operative stenosis (n = 2), and others (n = 8), conditions which were confirmed either histopathologically or clinically.

In 33 cases, chest radiographs were obtained using a film-screen system and the high-voltage technique, and in eight, by means of computed radiography. For all spiral CT examinations, a Somatom Plus-S or Plus 4 scanner (Siemens Medical Systems, Erlangen, Germany) was used, while for routine CT (RCT) scans, the spiral technique (8-10-mm collimation, pitch of 1) was employed. Scan parameters for thin-section spiral CT (TCT) scans were 2–3-mm collimation, 4-mm table feed, and 1–2-mm reconstruction interval. Intravenous contrast medium was used in all cases involving RCT scanning, and in 25 involving TCT. For this modality, the length of the z-axis was 9–20 cm, and all such scans were obtained during a single breath hold. Axial images were obtained at both mediastinal window setting (window width 300–400 HU, window level 0–40 HU) and lung window setting (window width 1300–

1500 HU, window level -650 to -750HU).

The TCT data were used to create both MPR and SSD images on the CT workstation. In all cases, coronal and sagittal MPR images were obtained along the long axis of the trachea (Fig. 1A), and in selected cases, oblique or curved reformatted images (Fig. 1B) were added. In all cases, MPR images were obtained at mediastinal window setting (window width 300–400 HU, window level 0–60 HU), and in selected cases at lung window setting (window width 1400–1800 HU, window level -470 to -600 HU).

SSD images were obtained using double threshold voxel selection (5); the lower threshold was -700 HU, and the upper was between -200 and -250 HU. In 25 cases, SSD images were edited to remove unnecessary lung parenchymal structures, using the cutting facility of the 3-D package (Fig. 2). In the remaining 16 cases (including all five of left upper lobar lesions), images were preprocessed with slice by slice editing to remove unwanted volumetric image data (Fig. 3). Three-dimensional images were obtained at a window width of 300 HU and window level of 900–1100 HU.

In each patient, chest radiographs RCT, TCT, 2-D MPR, and SSD images were retrospectively evaluated by two chest radiologists (Q.C., J-G.I), who reached a consensus. Images obtained by means of various techniques were analyzed for detectability, localization, extent, and characterization of the lesion, information on its relationship with adjacent structures, and overall information. Each feature

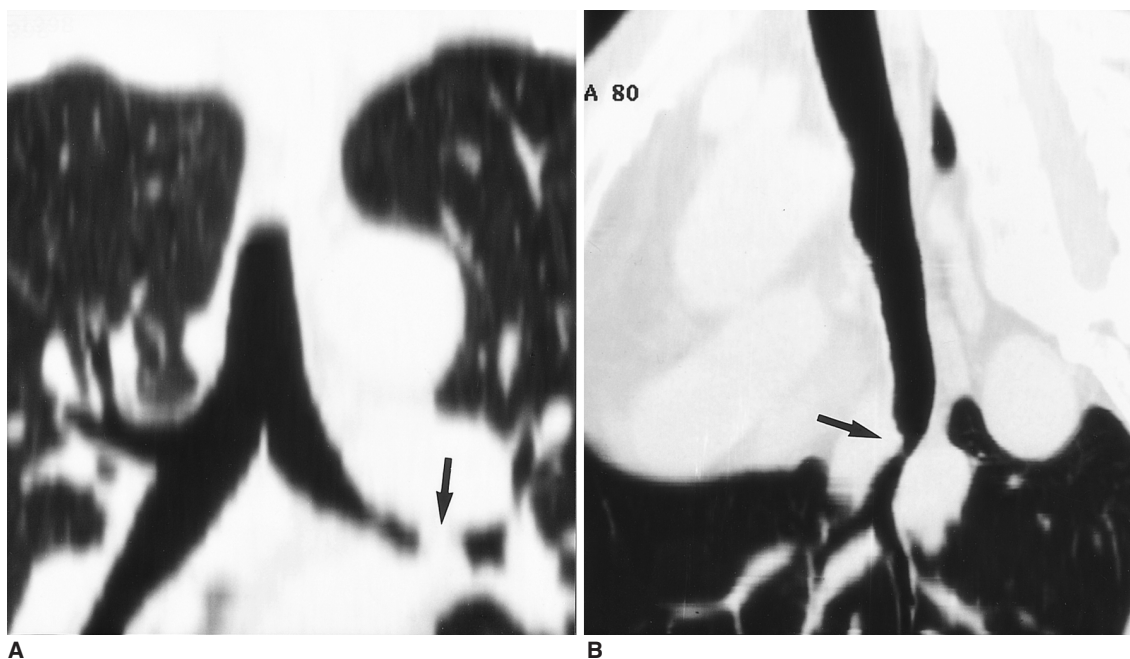


Fig. 1. Bronchogenic carcinoma in a 66-year-old man.

A. Coronal MPR image shows apparent total obstruction of the left main bronchus by a polypoid soft tissue lesion (arrow).

B. Curved reformatted image along the axis of the left upper lobe shows focal wall thickening of the left main bronchus (arrow).

Clinical Utility of CT Imaging Techniques for Tracheobronchial Diseases

was graded on a five-point scale: score 0, no information; 1, poor; 2, fair; 3, good; and 4, excellent.

For statistical analysis, Wilcoxon's matched-pairs signed-ranks test was used. A p value of less than 0.05 was considered statistically significant.

(n=2), left main bronchus (n=8), bronchus intermedius (n=7), right main bronchus and bronchus intermedius (n=2), trachea and right main bronchus (n=2), trachea and left main bronchus (n=5), left upper lobar bronchus (n=5), and trachea and both main bronchi (n=2). All but three

RESULTS

Lesions involved the trachea (n=8), right main bronchus

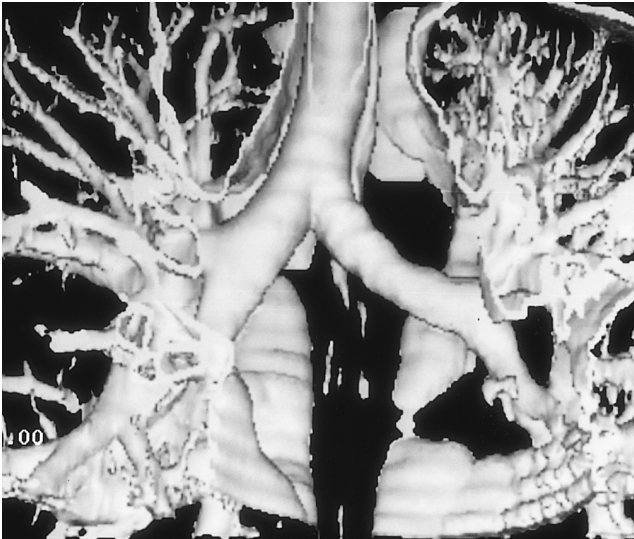


Fig. 2. SSD image from which unnecessary lung was removed shows the trachea and bilateral main bronchi.

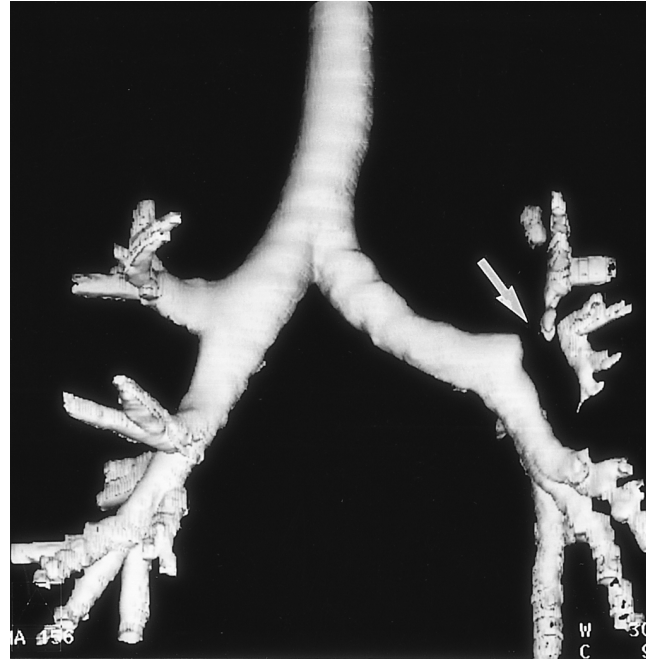


Fig. 3. SSD image preprocessed with slice by slice editing to remove unwanted structures shows complete focal obstruction of the left upper lobar bronchus (arrow).

Table 1. Mean Score of Chest Radiography (CXR), Routine CT (RCT), Thin-section Spiral CT (TCT), Multiplanar Reconstruction (MPR) and Shaded Surface Display (SSD) Imaging

	CXR	RCT	TCT	MPR	SSD
Detection	1.24 ± 0.97	2.98 ± 0.65	3.46 ± 0.50	3.80 ± 0.51	3.95 ± 0.31
Localization	1.10 ± 0.89	2.85 ± 0.61	3.37 ± 0.49	3.78 ± 0.42	3.95 ± 0.22
Extent	0.93 ± 0.79	2.27 ± 0.63	3.00 ± 0.45	3.56 ± 0.55	3.85 ± 0.42
Relationship	0.78 ± 0.47	3.29 ± 0.27	3.56 ± 0.50	3.12 ± 0.40	2.12 ± 0.60
Characterization	1.07 ± 0.82	3.05 ± 0.86	3.51 ± 0.60	3.29 ± 0.56	3.20 ± 0.60
Overall	1.07 ± 0.79	2.73 ± 0.55	3.20 ± 0.46	3.56 ± 0.55	3.83 ± 0.44

Note.—Data are mean ±SD

Table 2. p-Values for Difference between Various Techniques (Wilcoxon's Matched-Pairs Signed-Ranks Test)

	Detection			Localization			Extent			Relationship			Characterization			Overall		
	TCT	MPR	SSD	TCT	MPR	SSD	TCT	MPR	SSD	TCT	MPR	SSD	TCT	MPR	SSD	TCT	MPR	SSD
RCT	<.01	<.01	<.01	<.01	<.01	<.01	<.01	<.01	<.01	<.05	NS	<.01	<.01	NS	NS	<.01	<.01	<.01
TCT	—	<.01	<.01	—	<.01	<.01	—	<.01	<.01	—	<.01	<.01	—	NS	<.05	—	<.01	<.01
MPR	—	—	<.05	—	—	<.05	—	—	<.01	—	—	<.01	—	—	NS	—	—	<.05

Note.—NS = not significant, RCT = routine CT, TCT = thin-section spiral CT, MPR = multiplanar reconstruction imaging, SSD = shaded surface display imaging

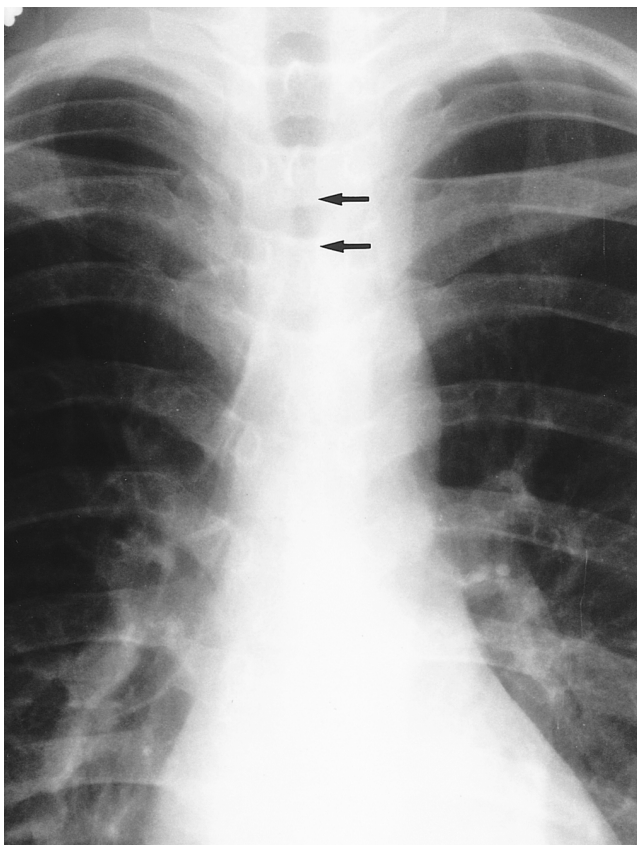


Fig. 4. Endotracheal tuberculosis in a 26-year-old woman. Posteroanterior chest radiograph shows segmental narrowing of the trachea (arrows).

cases of congenital abnormality showed narrowing of airways. Lesions of the tracheobronchial tree varied from mild narrowing to complete obstruction, and from focal stenosis to diffuse narrowing.

The mean scores of various techniques are summarized in Table 1, and the statistical differences between various pairs of techniques (permutations of RCT, TCT, MPR, and SSD) are summarized in Table 2.

In general, in evaluating tracheobronchial disease, chest radiographs showed low values. In cases of pneumonectomy or lesions at the level of the thoracic inlet, a score of 3 for localization and for detection was obtained in only two and four cases, respectively (Fig. 4). In terms of detection, localization, extent, relationship, characterization, and overall information, chest radiographs were significantly inferior to RCT, TCT, MPR, and SSD ($p < 0.0001$).

For detection and localization of the lesion, SSD had the highest score, and was significantly superior to other CT techniques. It was inferior to TCT in only one case, in which the lesion was seen as a mild irregularity of the right main bronchus (Fig. 5). For MPR, the score was between that of TCT and SSD, and in 34 cases (83%), the score for RCT was 3 or 4. Due to the small size of the endotracheal lesion, one case of RCT had a score of 1.

With regard to extent, in 39 cases (95%), the score for RCT was 2 or 3. For TCT, a score of 3 or 4 was achieved in 37 cases (90%), and for both MPR and SSD, one of these

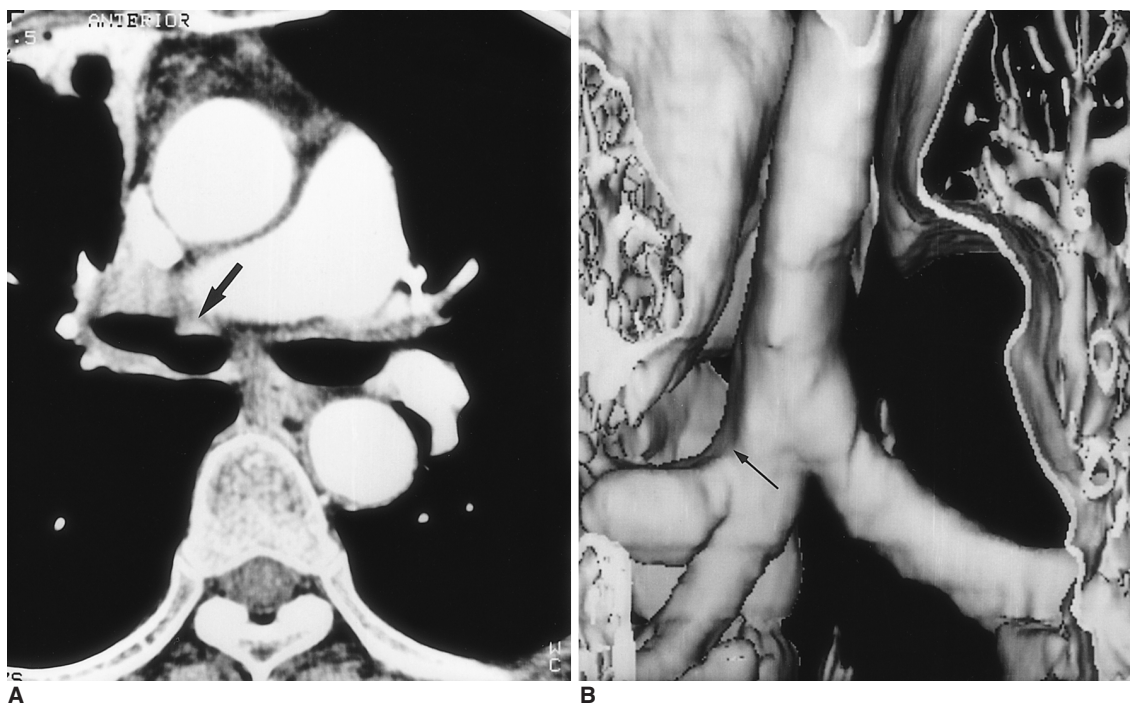

Fig. 5. Endobronchial tuberculosis in a 67-year-old woman.
A. Thin-section spiral CT shows mild irregular wall thickening (arrow) of the right main bronchus (score for detection = 4).
B. SSD image shows subtle irregularity (arrow) in the right main bronchus (score for detection = 2).

scores was obtained in 40 cases (98%) (Fig. 6). Thus, SSD was significantly superior to other techniques (Fig. 7).

SSD provided information about airways, but none with which to evaluate the relationship between abnormalities and adjacent structures (Fig. 8A). For this modality, a score of 2 was assigned in 37 cases (90%), while for RCT and MPR, a score of 3 or 4 was deemed appropriate in 40 cases (98%) (Fig. 8). For TCT, the score in all 41 cases was 3 or 4, and in assessing relationship of a lesion with adjacent structures, this technique was thus significantly superior to the others. There was no significant difference between RCT and MPR.

As regards characterization of a lesion, TCT and MPR were assigned a score of 3 or 4 in 39 cases (95%). TCT had the highest mean score, and was significantly superior to RCT and SSD.

In terms of overall information, SSD was regarded as sig-

nificantly more informative than other modalities. In 40 cases (98%), the score for TCT, MPR and SSD was 3 or 4.

DISCUSSION

High voltage chest radiography is cheap but still not sensitive enough to accurately evaluate airway stenoses (8). Although chest radiography remains in use for initial imaging of diseases of the chest, our study showed that the results obtained provided poor information with which to evaluate the tracheobronchial tree. When a lesion is located in the extrathoracic or proximal trachea, the modality may, however, provide certain valuable information, and it is also useful in excluding pulmonary disease or providing additional important lung-related data with which to evaluate tracheobronchial diseases.

As previously emphasized in the literature, an endobronchial tumor located in the central airway can be missed on conventional CT, particularly on 10-mm thick-section CT scans (6, 7). A spiral CT scanner can acquire a set of volumetric data during a single breath hold, and effectively obviates misregistration caused by varying depths of respiration between scans. In our study, all RCT involved the use of spiral CT, but even so, a small endotracheal lesion was missed. This was, however, clearly demonstrated by TCT, MPR, and SSD, the last of which was found to be most informative with regard to lesion detection. Lee et al. emphasized that the acquisition of SSD images led to no significant improvement in lesion detection (9). Transverse imaging, however, has an inherent limitation, and mild airway changes, especially those without

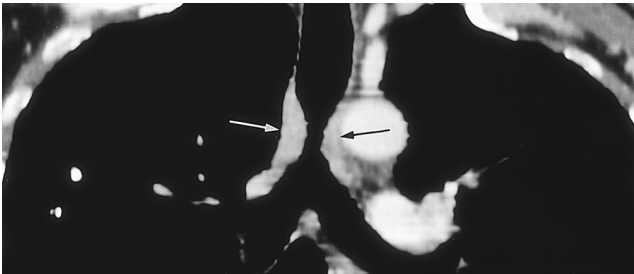


Fig. 6. Tracheal tumor in a 54-year-old man. The histology of this tumor was not confirmed because its hypervascularity, as revealed by bronchoscopy, precluded biopsy. Coronal MPR image demonstrates the extent of concentric wall thickening of the trachea (arrows).

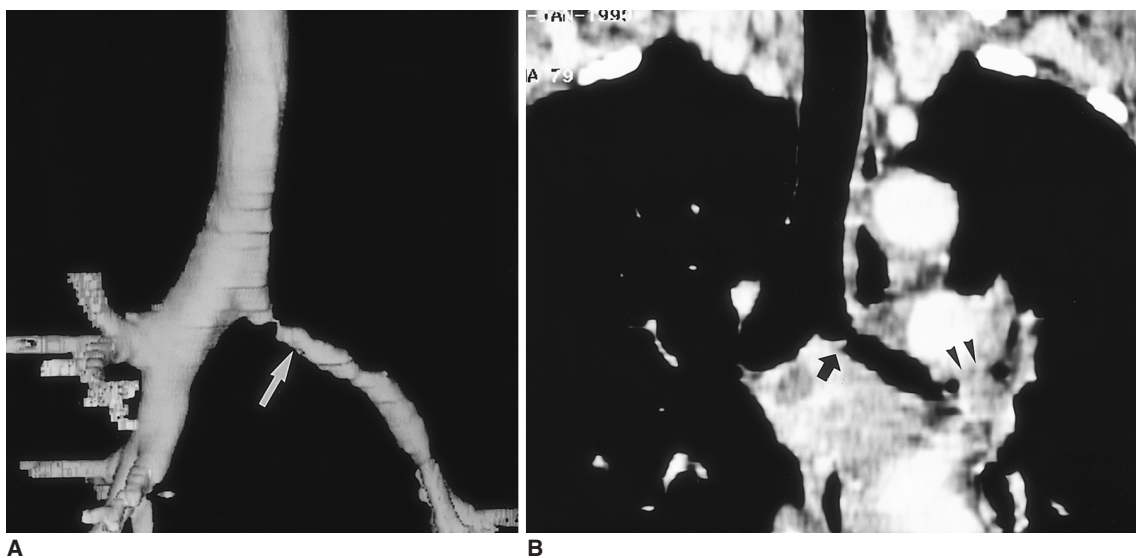


Fig. 7. Endobronchial tuberculosis in a 55-year-old woman. SSD image (A) (score for extent = 4) and coronal MPR image (B) (score for extent = 2) show irregular narrowing of the left main bronchus (arrow) and complete obstruction of the left upper lobar bronchus (arrowheads).

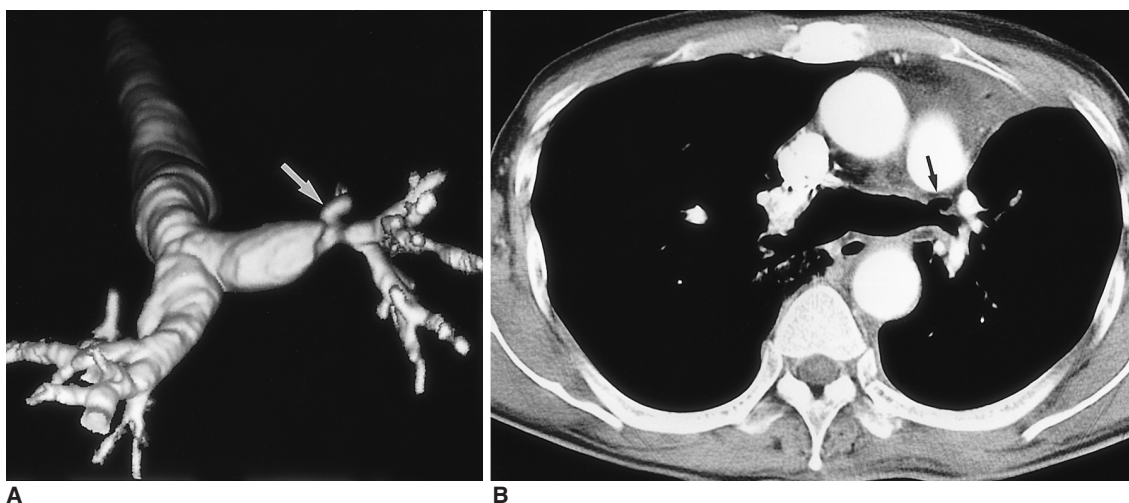
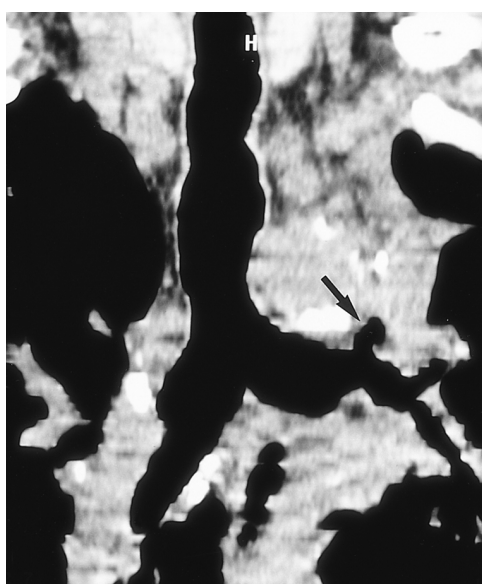


Fig. 8. An outpouching lesion at the anastomotic site after sleeve left upper lobectomy in a 67-year-old man. SSD (A), routine enhanced CT (B), and coronal MPR image (C) show an outpouching lesion at the anastomotic site (arrow). For these three techniques, the respective score for relationship was 0, 4, and 3, respectively.



wall thickness, may be missed. MPR was relatively less informative than SSD in detecting airway lesions. As Kauczor et al. emphasized, SSD images are less reliable in detecting peripheral (segmental) airway stenosis than those obtained by MPR (4). In a study by LoCicero et al., the longitudinal extent of abnormalities was best demonstrated by MPR and SSD images, whereas the transverse extent of disease and relationships to adjacent structures were most clearly revealed by axial CT (3).

In this study, SSD proved to be the best technique for localizing tracheobronchial lesions. In this respect, RCT was less informative than TCT, MPR and SSD images, especially in the localization of a lesion close to the bilateral second carina. The partial volume effect of RCT may account for this difference.

It has been widely accepted that MPR and SSD images provide more accurate assessment of the extent of tracheo-

bronchial narrowing than axial images (6, 9), particularly in the case of a lesion located in the left main bronchus, and in our study, SSD was the most informative modality for evaluating the extent of an airway lesion. MPR has been shown to be more precise than axial imaging in demonstrating the length of a stricture, especially when the lesion gradually narrows or, is located obliquely (1, 3, 9). Because the structure of the tracheobronchial tree is geometrically complex, SSD imaging is particularly useful in this respect. Accurate assessment on the basis of single plane images such as those obtained by TCT or MPR is difficult; curved reformation, though, is able to render complex 3-D structures in a single flat plane and may be of value in identifying the course of an extremely tortuous airway (10). Such reformation to some extent distorts the true anatomical relationship, however, and may even generate an artificial lesion. SSD provides the most reliable information on the extension of airway lesions, and using a state-of-the-art CT scanner, takes only slightly longer to process than MPR, especially in cases involving irregular or asymmetric airway narrowing.

When a single or double threshold is used, only a few voxels are visible, and for this reason, a limitation of SSD imaging is that the technique fails to provide information with which to evaluate the relationship between an abnormality and adjacent structures. Our experience has shown, however, that when the volume-rendering technique is used, 3-D imaging can display airway narrowing and adja-

cent major vessels or soft tissue mass, as well as providing a lymph node map. Using special software, Boisell et al. produced high-quality volume-rendering 3-D images of airways and lymph nodes against a background of spiral CT data (11). A study by Higgins et al. also included modified SSD images showing the complex geometry of the major airways, aorta, and a tumor (12). TCT preserves CT attenuation and has high spatial resolution, and in our study it therefore provided the best information for the evaluation of the relationship between abnormalities and adjacent structures. MPR may occasionally provide additional information in some regions such as the aortopulmonary window, and because it can render all image data, is superior in displaying both adjacent structures of the airway and peripheral structures. In this study it was, however, less informative than TCT and RCT, and was also relatively poor in evaluating the relationship between bilateral main bronchial lesions and adjacent structures. The main reason for this may be its lower longitudinal resolution.

MPR, and particularly SSD, images can help provide a global understanding of tracheobronchial status, and we speculated that this is why both imaging techniques showed good grades for overall information. Such images are very useful in the diagnosis of congenital airway abnormalities. SSD images usually depict the inner border of an airway instead of the true wall of the tracheobronchial tree, and their characterization of tracheobronchial lesions is therefore relatively poor; they merely demonstrate patterns of airway narrowing. Because it has better spatial resolution than RCT, TCT was the most informative modality, and its characterization of bilateral main bronchial lesions, was superior to MPR.

In conclusion, SSD and MPR were superior for the detection, localization, and evaluation of the extent of airway disease, such images were especially useful in the preparation of endobronchial procedures and in surgical planning. RCT alone cannot adequately evaluate tracheobronchial disease, and in the detection, localization, and determination of the extent of lesions, the evaluation of their rela-

tionship with adjacent structures, and characterization of airway disease, was less accurate than TCT. For the evaluation of suspected or known endobronchial abnormality, 3-D CT based on TCT is therefore the method of choice.

References

1. Quint LE, Whyte RI, Kazerooni EA, et al. Stenosis of the central airways: evaluation by using helical CT with multiplanar reconstruction. *Radiology* 1995;194:871-877
2. Sagy M, Poustchi-Amin M, Nimkoff L, Silver P, Shikowitz M, Leonidas JC. Spiral computed tomographic scanning of the chest with three dimensional imaging in the diagnosis and management of paediatric intrathoracic airway obstruction. *Thorax* 1996;51:1005-1009
3. LoCicero J, Costello P, Campos CT, et al. Spiral CT with multiplanar and three-dimensional reconstructions accurately predicts tracheobronchial pathology. *Ann Thorac Surg* 1996;62:811-817
4. Kauczor HU, Wolcke B, Fischer B, Mildenerger P, Lorenz J, Thelen M. Three-dimensional helical CT of the tracheobronchial tree: evaluation of imaging protocols and assessment of suspected stenoses with bronchoscopic correlation. *AJR* 1996;167:419-424
5. Lacrosse M, Trigaux JP, Van Beers BE, Weynants P. 3D spiral CT of the tracheobronchial tree. *J Comput Assist Tomogr* 1995; 19:341-347
6. Gurney JW. Missed lung cancer at CT: imaging findings in nine patients. *Radiology* 1996;199:117-122
7. Whyte RI, Quint LE, Kazerooni EA, Cascade PN, Iannettoni MD, Orringer MB. Helical computed tomography for the evaluation of tracheal stenosis. *Ann Thorac Surg* 1995;60:27-31
8. Hernandez RJ, Tucker GF. Congenital tracheal stenoses: role of CT and high kV films. *Pediatr Radiol* 1987;17:192-196
9. Lee KS, Yoon JH, Kim TK, Kim JS, Chung MP, Kwon OJ. Evaluation of tracheobronchial disease with helical CT with multiplanar and three-dimensional reconstruction: correlation with bronchoscopy. *RadioGraphics* 1997;17:555-567
10. Naidich DP, Gruden JF, McGuinness G, McCauley DI, Bhalla M. Volumetric (helical/spiral) CT (VCT) of the airways. *J Thorac Imag* 1998;12:11-28
11. Boiselle PM, Patz EF Jr, Vining DJ, Weissleder R, Shepard JA, McLoud TC. Imaging of mediastinal lymph nodes: CT, MR, and FDG PET. *RadioGraphics* 1998;18:1061-1069
12. Higgins WE, Ramaswamy K, Swift RD, McLennan G, Hoffman EA. Virtual bronchoscopy for three-dimensional pulmonary image assessment: state of the art and future needs. *RadioGraphics* 1998;18:761-778