

Transphyseal anterior cruciate ligament reconstruction in adolescents with substantial remaining growth causes temporary growth arrest resulting in subclinical leg-length discrepancy

Ji Young Jeon, MD^a, Jaehyung Lee, MD^b, Michael Seungcheol Kang, MD^{b,*}

Abstract

The purpose of the present study was to investigate the characteristics of growth disturbances in patients with remaining growth after transphyseal anterior cruciate ligament (ACL) reconstruction who were confirmed to have no definite postoperative physeal abnormalities on magnetic resonance imaging (MRI).

Forty adolescents (mean age 15.6 ± 1.0 years [range 12.2–16.8], mean follow-up 2.7 ± 0.7 years [range 2.0–5.5 years]), who underwent transphyseal ACL reconstruction and were confirmed to have no focal physeal disruptions on follow-up MRIs 6 to 12 months after the operation, were retrospectively evaluated. The patients were grouped according to the leg-length growth of the uninjured side, measured on scanograms, obtained before surgery, and at the final follow-up.

Leg-length discrepancies (LLD) at the last follow-up were greater in patients with leg growth ≥ 4 cm than in those with leg growth < 4 cm (5.3 ± 9.0 mm vs -0.3 ± 4.2 mm, $P = .033$); however, no significant difference was observed between subgroup patients with leg growth of 4 to 6 cm or ≥ 6 cm (5.6 ± 10.4 mm vs 4.8 ± 7.0 mm, $P = .958$). On multivariate analysis, leg growth was a significant predictive factor for the final LLD ($P = .030$).

Adolescents with additional leg-length growth after transphyseal ACL reconstructions presented with greater LLDs (as shown in the < 4 cm vs ≥ 4 cm groups), but they also presented a ceiling effect (as shown in the 4–6 cm vs ≥ 6 cm subgroups). Transphyseal ACL reconstructions appeared to cause temporary growth arrest/disturbances in patients with substantial remaining growth which then resumed resulting in clinically insignificant LLDs.

Abbreviations: ACL = anterior cruciate ligament, LLD = leg-length discrepancies.

Keywords: anterior cruciate ligament reconstruction, growth, leg-length discrepancy, transphyseal

1. Introduction

Anterior cruciate ligament (ACL) injuries occur in 3% to 7% of adolescents,^[1,2] but the incidence in adolescents who have not reached skeletal maturity is gradually increasing owing to the steady increase in sports activity participation in this population.^[1,3,4] While conservative treatments may be performed in skeletally immature patients with ACL ruptures, they have been

reported to be inadequate.^[4,5] Surgical treatments include methods in which the reconstructed graft is passed through the physis (the transphyseal technique) and methods in which it is not (the physeal-sparing technique). Physeal-sparing ACL reconstructions are often performed in children or adolescents with substantial remaining growth to prevent growth disturbances^[3]; however, remaining instability has been reported^[6] and long-term follow-up results are rarely reported.^[7–9] The transphyseal technique can be used to reduce instability by reconstructing an anatomically similar ligament in the same manner as in adult patients, but it has the disadvantage of inducing physeal lesions because of the reconstructed graft passing through it.^[10] Some studies have reported that the transphyseal technique has little effect on residual growth in adolescents with remaining growth,^[11–13] whereas others have suggested that growth disturbance after surgery is underestimated.^[14] However, these studies were not based on the actual increase in leg length.

Magnetic resonance imaging (MRI) is the most sensitive modality for detecting physeal changes or injuries.^[15] In a study using MRIs,^[16] some physeal changes were reported after transphyseal ACL reconstructions, although no significant clinical deterioration was observed. Some of these changes might have originated from surgical procedures or trauma. Although their clinical significance is yet undetermined, the presence of focal physeal disruptions could theoretically affect the remaining growth. The patients with such focal physeal lesions would be more prone to growth disturbances which may manifest differently depending on their location. However, little is known

Editor: Sebastian Farr.

This study was supported by a grant (2017–0207) from Asan Medical Center Children's Hospital, Seoul, Korea.

The authors report no conflicts of interest.

^a Department of Radiology, Gil Medical Center, Gachon University College of Medicine, Namdong-gu, Incheon, ^b Department of Orthopedic Surgery, Asan Medical Center Children's Hospital, Songpa-gu, Seoul, Republic of Korea.

* Correspondence: Michael Seungcheol Kang, Department of Orthopedic Surgery, Asan Medical Center Children's Hospital, University of Ulsan College of Medicine, 88, Olympic-ro, 43-gil, Songpa-gu, Seoul 05505, Republic of Korea (e-mail: kang@amc.seoul.kr).

Copyright © 2019 the Author(s). Published by Wolters Kluwer Health, Inc. This is an open access article distributed under the terms of the Creative Commons Attribution-Non Commercial License 4.0 (CCBY-NC), where it is permissible to download, share, remix, transform, and buildup the work provided it is properly cited. The work cannot be used commercially without permission from the journal.

Medicine (2019) 98:26(e16081)

Received: 26 February 2019 / Received in final form: 22 May 2019 / Accepted: 24 May 2019

<http://dx.doi.org/10.1097/MD.00000000000016081>

about the occurrence of growth disturbances in patients without these physal lesions.

To test our hypothesis that there would be growth disturbances in patients with remaining growth after transphyseal ACL reconstructions, even if there was no definite postoperative focal physal disruptions, the presence and characteristics of growth disturbances in those patients were assessed. To determine the impact of actual growth, we investigated the growth disturbances according to the leg-length growth of the uninjured side and confirmed the absence of focal physal disruptions on postoperative follow-up MRIs.

2. Materials and methods

2.1. Patients

Ninety patients who underwent transphyseal ACL reconstructions at our institute between 2008 and 2016 at the age of <17 years were retrospectively evaluated. Of them, 57 patients whose ACLs were reconstructed using the single-bundle technique were included. Patients who underwent revision surgery within 2 years after their operation ($n=2$) and those without available postoperative follow-up data of >2 years ($n=5$) were excluded. Among these patients, those without available follow-up MRI scans taken between postoperative month 6 and 1 year ($n=7$), and those with evidence of abnormal physal lesions on follow-up MRIs ($n=3$; 2 with physal tenting and 1 with asymmetrical early physal closure) were also excluded. Finally, 40 patients were included in the analysis.

The patients were grouped according to the leg-length growth of their uninjured side measured on scanograms taken before surgery and at the final follow-up. Patients who presented a leg-length growth of ≥ 4 cm were categorized as the G (≥ 4 cm) group, and the others as the G (<4 cm) group. A cutoff value of 4 cm was established because it produced the largest statistical significance among the various cutoff values.

Various types of grafts were used for reconstruction with the autologous hamstring graft being the most common (72.5%). Combined surgeries such as meniscal repair and/or meniscectomy were performed in 24 cases.

The present study protocol was reviewed and approved by our institutional review board.

2.2. Investigated variables

The patients' sex, laterality (right or left leg), age at surgery, time from trauma to surgery, follow-up duration, graft used for reconstruction, and difference in anterior translation measured using a KT-2000 knee arthrometer (MEDMetric, San Diego, CA) at 30 lbs, were investigated. Full-length standing anteroposterior radiographs of both lower extremities with the patella facing forward (telerradiographs) and scanograms centered at the hip, knee, and ankle with a radiopaque ruler were taken preoperatively and at every postoperative follow-up visit. The leg-length discrepancy (LLD), mechanical lateral distal femoral angle (mLDFA), and the medial proximal tibial angle (MPTA) were measured on the telerradiographs and scanograms taken at the last follow-up for both the injured and uninjured legs (Fig. 1). MRI scans taken preoperatively and during the follow-ups, were used to measure the meniscal width, length, and extrusion for the medial and lateral menisci (Fig. 2).¹⁷ Meniscal tears that were detected preoperatively and during the follow-ups were also investigated. The femoral and tibial

diameters and graft thicknesses were measured on the follow-up MRI scans.

2.3. Statistical analyses

For the comparisons between the G (≥ 4 cm) and G (<4 cm) groups, the chi-squared test was used to analyze differences in frequency, and the Fisher exact test was used when the frequency was <5. The independent sample *t* test was used to analyze mean differences.

Associations between LLDs and the other variables were analyzed using linear regression analysis. To eliminate confounders among the variables, we included variables with the possibility of being confounders in the multivariate analysis. For that reason, variables with *P* values of $\leq .15$ in the univariate analysis were included in the multivariate analysis. Likewise, for the MRI measurements, only the variables measured on preoperative MRI scans were included in the analysis if the measurements were performed both preoperatively and at follow-up.

The G (≥ 4 cm) group was additionally subdivided into patients with a leg growth of 4 to 6 cm (sub-G [4–6 cm]) and those with a leg growth of ≥ 6 cm (sub-G [≥ 6 cm]). The Wilcoxon ranked-sum (Mann–Whitney *U* test) test was used for the subgroup analyses.

A *P* value of <.05 was considered statistically significant. All statistical analyses were performed using SPSS version 21 software (IBM Co., Armonk, NY).

3. Results

The Lysholm scores of the G (≥ 4 cm) and G (<4 cm) groups were 59.1 ± 22.9 and 66.9 ± 17.3 before the operation ($P = .223$) and 91.0 ± 11.2 and 93.3 ± 6.1 at the last follow-up, respectively ($P = .407$).

3.1. Comparisons between the patients with leg growths of ≥ 4 cm and <4 cm during the period from surgery to the last follow-up

Comparisons between the G (≥ 4 cm) and G (<4 cm) groups are shown in Tables 1 and 2. The mean growth of the uninjured leg was 59.5 mm in the G (≥ 4 cm) group and 9.8 mm in the G (<4 cm) group. The total LLD at the last follow-up was larger in the G (≥ 4 cm) group than in the G (<4 cm) group (5.3 mm vs -0.3 mm, $P = .033$). This difference mainly originated from the tibial-length discrepancy (4.4 mm vs 0 mm).

No significant differences in angular deformities such as mLDFA and MPTA were found between the 2 groups.

3.2. Variables related to LLD at the last follow-up

The variables related to LLD at the last follow-up are shown in Table 3. The growth of the uninjured leg between the surgery and the last follow-up, the preoperative lateral meniscal width, and the difference in anterior translation measured using the KT-2000 knee arthrometer were significantly associated with the LLD at the last follow-up.

3.3. Subgroup analysis of the G (≥ 4 cm) group

In the G (≥ 4 cm) group, the LLDs between the patients with a leg growth of 4 to 6 cm and those with a leg growth ≥ 6 cm were compared; however, no significant differences were found between them (Table 4).

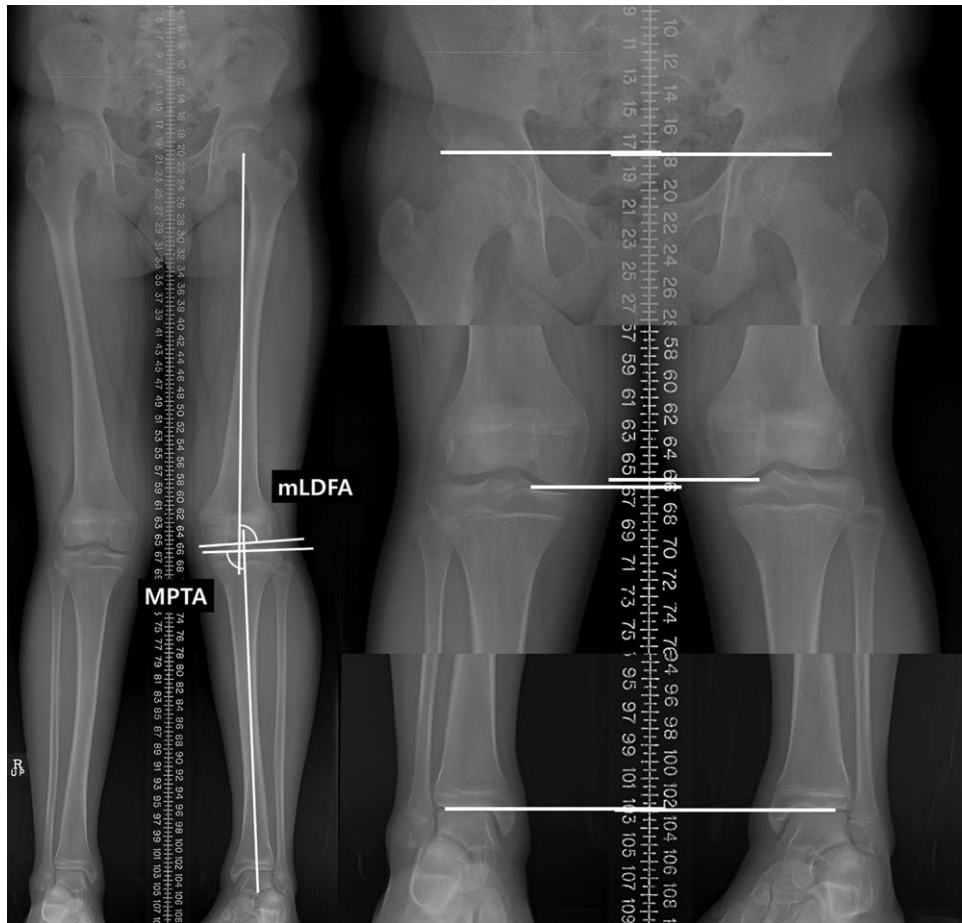


Figure 1. Teleradiograms including the full-length standing view of both legs with the patella in the facing-forward position (left) and scanograms centered at the hip, knee, and ankle with a radiopaque ruler (right). Leg-length discrepancy was measured on the scanograms. Femoral lengths were measured from the upper margin of the femoral head to the distal margin of the medial femoral condyle. Tibial lengths were measured from the distal margin of the medial femoral condyle to the distal tibial plafond. Total leg lengths were measured from the upper margin of the femoral head to the distal tibial plafond. mLDFA=mechanical lateral distal femoral angle, MPTA=medial proximal tibial angle.

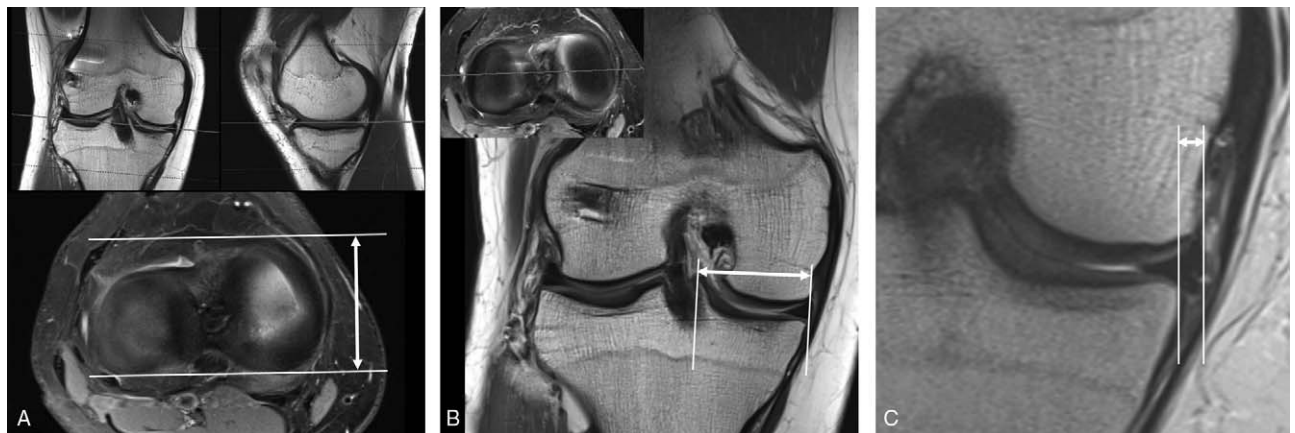


Figure 2. (A) Meniscal lengths were measured as the distance from the anterior to the posterior margins of the meniscus on the transverse image (double-headed arrow). (B) Meniscal widths were measured as the distance from the outer border of the meniscus to the medial edge of the intercondylar eminence on the coronal image that crossed the center of the meniscal body (double-headed arrow). (C) Meniscal extrusions were measured as the distance from the outer edge of the tibial plateau to the outer border of the meniscus on the coronal image (double-headed arrow). The gray lines in each composite figure indicate the level of the chosen images in other sections.

4. Discussion

We investigated the growth disturbances in patients with remaining growth after transphyseal ACL reconstructions. To assess the effect according to actual growth, we included only patients without definite physeal lesions seen on MRIs performed 6 to 12 months postoperatively and compared the LLDs and angular deformities according to growth in the length of the uninjured legs. The patients with more leg-length growth (≥ 4 cm) showed greater LLDs than the others (< 4 cm). Among the patients with substantial remaining growth (≥ 4 cm), no significant difference in the final LLDs were found between the patients with a growth of 4 to 6 cm and those with a growth of ≥ 6 cm.

There was no additional growth inhibition in the subgroup patients with a growth of ≥ 6 cm compared with those with a growth of 4 to 6 cm. Therefore, we suggest that transphyseal ACL reconstruction seemed to cause temporary growth arrest/disturbances in the patients with substantial remaining growth, after which the growth resumed. This temporary growth arrest/disturbance mainly occurred in the tibias (Table 1). Given that approximately 20% to 30% of leg-length growth occurs in the

proximal tibia,^[18,19] the proximal tibia should grow > 10 to 15 mm arithmetically when the leg grows ≥ 4 cm. However, the mean final tibial-length discrepancy was less than that value (4.4 mm in G [≥ 4 cm] group). This might indicate that the growth disturbance was temporary.

On the other hand, the clinical implications of the present results should also be considered. Although there was a significant difference in LLDs according to residual growth after transphyseal ACL reconstructions, the degree of LLDs was relatively small (5.9 mm) even in the G (≥ 4 cm) group. Given that most patients with LLDs < 2 cm have no subjective discomfort and require no treatment,^[20] this does not seem to be clinically meaningful. However, while patients in this study presented with substantial residual growth, they were adolescents with an average age of 15.6 years and one should not assume that LLDs will also be subclinical in younger children who have substantial growth much more.

As many researchers have suggested, we believe that the reason the procedure does not induce significant LLDs is because the tunnel is made as vertical and as central as possible to minimize

Table 1
Comparison between the patients with a leg-length growth of ≥ 4 cm and those with a leg-length growth of < 4 cm.

	All patients (N=40)	G (≥ 4 cm) (n=16)	G (< 4 cm) (n=24)	P value
Demographics				
Sex				1.000
Male	31 (77.5%)	12 (75.0%)	19 (79.2%)	
Female	9 (22.5%)	4 (25.0%)	5 (20.8%)	
Laterality				.519
Right	20 (50.0%)	7 (43.8%)	13 (54.2%)	
Left	20 (50.0%)	9 (56.3%)	11 (45.8%)	
Age (years)	15.6 \pm 1.0	15.8 \pm 1.1	15.5 \pm .9	.411
Time from trauma to surgery (days)	61.6 \pm 77.8	74.2 \pm 109.9	53.1 \pm 46.9	.478
Follow-up duration (years)	2.7 \pm .7	2.7 \pm .5	2.7 \pm .9	.940
Graft used for reconstruction				1.000
Autologous hamstring	29 (72.5%)	12 (75.0%)	17 (70.8%)	
Others	11 (27.5%)	4 (25.0%)	7 (29.2%)	
KT-2000, mm*				
Preoperative	5.2 \pm 4.1	5.9 \pm 4.9	4.7 \pm 3.4	.393
Last follow-up	2.1 \pm 2.2	1.7 \pm 2.4	2.4 \pm 2.0	.333
Difference	-3.0 \pm 3.5	-4.1 \pm 3.3	-2.3 \pm 3.6	.112
Teleradiogram and scanogram				
Leg length (uninjured side), mm				
Preoperative	850.6 \pm 52.5	849.0 \pm 41.8	851.6 \pm 59.4	.880
Last follow-up	880.2 \pm 60.6	908.5 \pm 44.7	861.4 \pm 63.3	.014
Growth [†]	29.7 \pm 27.7	59.5 \pm 15.4	9.8 \pm 10.8	<.001
LLD at the last follow-up, mm [‡]				
LLD, total (femur + tibia)	2.0 \pm 7.0	5.3 \pm 9.0	-.3 \pm 4.2	.033
Femoral-length discrepancy	.2 \pm 4.3	.9 \pm 4.8	-.2 \pm 4.0	.410
Tibial-length discrepancy	1.7 \pm 5.9	4.4 \pm 6.9	.0 \pm 4.4	.033
mLDFA at the last follow-up, °				
Injured side	90.1 \pm 7.8	90.2 \pm 7.9	90.0 \pm 7.9	.945
Contralateral uninjured side	90.2 \pm 8.0	90.1 \pm 7.7	90.3 \pm 8.4	.924
Difference	-.1 \pm 1.5	.2 \pm 1.4	-.3 \pm 1.5	.367
MPTA at the last follow-up, °				
Injured side	89.6 \pm 3.3	89.7 \pm 3.6	89.4 \pm 3.2	.778
Contralateral uninjured side	89.4 \pm 3.4	89.9 \pm 3.7	89.0 \pm 3.1	.444
Difference	.2 \pm 1.1	-.2 \pm 1.0	.4 \pm 1.1	.124

LLD=leg-length discrepancy, mLDFA=mechanical lateral distal femoral angle, MPTA=medial proximal tibial angle.

*KT-2000: compared with the contralateral uninjured knee.

[†]Growth: leg-length difference between preoperatively and at the last follow-up.

[‡]A positive value means that the injured leg was short.

P values indicating statistical significance (P value < 0.05) are in bold.

Table 2
Magnetic resonance imaging measurements performed preoperatively and at follow-up.

	All patients (N=40)	G (≥ 4 cm) (n=16)	G (<4 cm) (n=24)	P value
Medial MW, mm				
Preoperative	31.4 \pm 2.3	31.2 \pm 2.6	31.6 \pm 2.2	.563
At follow-up	32.4 \pm 2.2	32.2 \pm 2.4	32.6 \pm 2.1	.547
Difference	1.0 \pm .9	1.0 \pm 1.0	1.0 \pm .8	.996
Medial ME, mm				
Preoperative	1.2 \pm 1.2	.8 \pm .8	1.4 \pm 1.3	.077
At follow-up	.9 \pm 1.1	.4 \pm .8	1.3 \pm 1.2	.017
Difference	-.3 \pm 1.4	-.4 \pm .9	-.2 \pm 1.6	.680
Medial ML, mm				
Preoperative	47.4 \pm 3.3	47.0 \pm 3.3	47.7 \pm 3.4	.494
At follow-up	48.0 \pm 3.2	47.7 \pm 3.4	48.2 \pm 3.1	.687
Difference	.6 \pm 1.8	.7 \pm 1.8	.4 \pm 1.9	.590
Lateral MW, mm				
Preoperative	32.4 \pm 2.8	31.9 \pm 3.2	32.7 \pm 2.5	.381
At follow-up	33.4 \pm 2.6	32.7 \pm 2.8	33.8 \pm 2.3	.165
Difference	1.0 \pm 1.0	.8 \pm 1.3	1.1 \pm .7	.285
Lateral ME, mm				
Preoperative	.5 \pm .9	.7 \pm 1.1	.4 \pm .7	.470
At follow-up	.5 \pm .9	.7 \pm 1.1	.4 \pm .7	.292
Difference	.0 \pm .8	.0 \pm 1.1	-.1 \pm .6	.685
Lateral ML, mm				
Preoperative	35.0 \pm 3.3	35.0 \pm 3.3	35.1 \pm 3.4	.931
At follow-up	35.0 \pm 6.3	36.1 \pm 2.7	34.2 \pm 7.9	.370
Difference	.0 \pm 7.5	1.1 \pm 2.4	-.8 \pm 9.4	.428
Medial meniscal tear				
Preoperative	11 (27.5%)	3 (18.8%)	8 (33.3%)	.473
Newly appeared at follow-up	8 (20.0%)	2 (13.3%)	6 (25.0%)	.450
Lateral meniscal tear				
Preoperative	15 (37.5%)	8 (50.0%)	7 (30.4%)	.217
Newly appeared at follow-up	3 (7.5%)	2 (13.3%)	1 (4.2%)	.326
Graft thickness in femur				
Coronal view	10.0 \pm 3.3	10.3 \pm 2.9	9.7 \pm 3.6	.554
Sagittal view	8.6 \pm 2.7	9.4 \pm 1.6	8.1 \pm 3.1	.157
Graft thickness in tibia				
Coronal view	8.8 \pm 1.9	9.0 \pm 2.0	8.7 \pm 1.9	.709
Sagittal view	11.2 \pm 3.2	10.8 \pm 3.2	11.4 \pm 3.2	.555
Graft angle in tibia				
Coronal view	12.1 \pm 5.2	11.9 \pm 6.5	12.2 \pm 4.4	.880
Sagittal view	35.2 \pm 6.5	37.4 \pm 6.2	33.8 \pm 6.4	.089
Femoral diameter				
Coronal view	53.3 \pm 21.6	57.9 \pm 19.9	50.2 \pm 22.5	.273
Sagittal view	49.3 \pm 6.9	49.3 \pm 5.0	49.3 \pm 8.0	.999
Tibial diameter				
Coronal view	59.1 \pm 6.9	57.8 \pm 4.3	59.9 \pm 8.1	.314
Sagittal view	46.9 \pm 4.0	46.3 \pm 4.7	47.2 \pm 3.5	.460

ME=meniscal extrusion, ML=meniscal length, MW=meniscal width.

the sectional area of damaged physes^[21] and that the graft filling the damaged physes prevents the formation of a bone bridge by acting as a fat graft.^[22] However, using the same rationale, the possibility of an angular deformity in the sagittal plane may theoretically be higher than that in the coronal plane because the graft angle in the tibia is close to the vertical axis in the coronal view (approximately 12° from the vertical axis), but not in the sagittal view (approximately 35° from the vertical axis). Unfortunately, the angular deformity was evaluated only in the coronal view by using the mL DFA and the MPTA. Even if the angular deformity was evaluated in the sagittal plane, it is doubtful whether there would be any clinical differences, because this hypothesis does not explain the minimal growth disturbance in the femur which usually has a more acute graft angle than the tibia.

On MRI, physal tenting, the presence of a focal bone bridge, an asymmetric Harris growth arrest line, an asymmetric early physal closure, and a metaphyseal extension of the physal cartilage were considered focal physal disruptions.^[16] We excluded patients with such physal lesions on the follow-up MRI scans taken postoperatively at 6 to 12 months. Two patients had physal tenting, and 1 had an asymmetrical early physal closure. The physal abnormalities found in these patients may have been affected by the surgery or may have been caused by the damage at the time of injury, and occasionally seem to cause significant growth disturbances, although the frequencies are low.^[14] Our study excluded these patients to evaluate the effects of the surgery on growth disturbance according to the residual growth. Assessment of growth disturbances based on focal

Table 3**Variables related to leg-length discrepancy at the last follow-up in the linear regression analysis.**

	Univariate analysis		Multivariate analysis (backward)	
	Standardized beta	P value	Standardized beta	P value
Leg growth	0.350	.027	0.316	.030
Medial MW, preoperative	-0.279	.081		
Medial ME, preoperative	-0.259	.107		
Lateral MW, preoperative	-0.304	.057	-0.348	.019
Medial ML, preoperative	-0.361	.022		
Lateral ML, preoperative	-0.293	.067		
KT-2000, at the last follow-up	-0.270	.093	-.304	.039

ME = meniscal extrusion, ML = meniscal length, MW = meniscal width.

physeal lesions was beyond the scope of this study; thus, the present results should not be applied to cases with those types of lesions. Additional studies regarding this issue are certainly needed.

In the multivariate analysis, the preoperative lateral meniscal width and the anterior translation measurements using KT-2000 at the last follow-up were also significantly associated with the LLD at the last follow-up. We suggest that it was biased by the children's growth, which might have affected the ligament laxity by making it tenser. However, more systematic research with a larger sample size is needed to elucidate this issue.

This study has limitations, and some considerations are required when interpreting the results of this study. First, the present results cannot be applied to younger children without additional research. Although transphyseal ACL reconstructions cause only temporary growth arrests, it is unknown whether it could be applied to young children who would continue to exhibit significant growth. There are many possible reasons why younger children were minimally represented in the present study. A much lower risk of ACL rupture in younger children might be 1 reason because ACL avulsion fractures (tibial spine fractures) are more likely to occur than ACL ruptures during trauma in those younger age groups. Bias might also exist since it is possible that the transphyseal technique might not be performed due to surgeons' concerns regarding growth in such young children. Secondly, we only included patients who presented no structural abnormalities on MRIs and no significant complications that required revisional surgery. A potential selection bias based on these criteria should also be considered. Furthermore, although MRI is currently believed to be the most sensitive modality for detecting physeal changes, no demonstrable lesions on MRI might not guarantee that the physeal function was completely intact. Thirdly, although preoperative teleradiograms/scanograms were collected, only

the leg length of the uninjured side was evaluated because the trauma could have altered the position of the injured knee which could also bias the measurements. Comparisons of growth disturbance using LLDs at the last follow-up assume no preoperative LLDs. However, some people normally present with a few degrees of LLD.^[2,3] This could also serve as a source of bias.

5. Conclusion

In summary, we evaluated the occurrence of deformities according to the growth in length of the uninjured leg. As such, transphyseal ACL reconstructions appeared to cause temporary growth arrest/disturbances in patients with substantial remaining growth, which then resumed, resulting in clinically insignificant LLDs.

Author contributions

Conceptualization: Ji Young Jeon, Jaehyung Lee, Michael Seungcheol Kang.

Data curation: Ji Young Jeon.

Formal analysis: Ji Young Jeon, Jaehyung Lee, Michael Seungcheol Kang.

Funding acquisition: Michael Seungcheol Kang.

Investigation: Ji Young Jeon, Jaehyung Lee.

Methodology: Michael Seungcheol Kang.

Supervision: Michael Seungcheol Kang.

Visualization: Michael Seungcheol Kang.

Writing – original draft: Ji Young Jeon, Jaehyung Lee.

Writing – review & editing: Ji Young Jeon, Michael Seungcheol Kang.

Michael Seungcheol Kang orcid: 0000-0002-0172-2721.

Ji Young Jeon orcid: 0000-0002-9864-4765.

References

- [1] McCarroll JR, Rettig AC, Shelbourne KD. Anterior cruciate ligament injuries in the young athlete with open physes. *Am J Sports Med* 1988;16:44–7.
- [2] Shea KG, Pfeiffer R, Wang JH, et al. Anterior cruciate ligament injury in pediatric and adolescent soccer players: an analysis of insurance data. *J Pediatr Orthop* 2004;24:623–8.
- [3] Bales CP, Guettler JH, Moorman CT3rd. Anterior cruciate ligament injuries in children with open physes: evolving strategies of treatment. *Am J Sports Med* 2004;32:1978–85.
- [4] Kannus P, Jarvinen M. Knee ligament injuries in adolescents. Eight year follow-up of conservative management. *J Bone Joint Surg Br* 1988; 70:772–6.

Table 4

Subgroup analysis for leg-length discrepancy at the last follow-up between patients with leg growth 4–6 cm (sub-G [4–6 cm]) and those with leg growth ≥6 cm (sub-G [≥6 cm]) during the period from surgery and last follow-up.

	Sub-G (4–6 cm) (n = 10)	Sub-G (≥6 cm) (n = 6)	P value
LLD, total (femur + tibia), cm	5.6 ± 10.4	4.8 ± 7.0	.958
Femoral-length discrepancy, cm	0.0 ± 4.9	2.5 ± 4.8	.220
Tibial-length discrepancy, cm	5.6 ± 7.7	2.3 ± 5.1	.492

LLD = leg-length discrepancy.

- [5] Graf BK, Lange RH, Fujisaki CK, et al. Anterior cruciate ligament tears in skeletally immature patients: meniscal pathology at presentation and after attempted conservative treatment. *Arthroscopy* 1992;8:229–33.
- [6] Amis AA, Scammell BE. Biomechanics of intra-articular and extra-articular reconstruction of the anterior cruciate ligament. *J Bone Joint Surg Br* 1993;75:812–7.
- [7] Behr CT, Potter HG, Paletta GA Jr. The relationship of the femoral origin of the anterior cruciate ligament and the distal femoral physal plate in the skeletally immature knee. An anatomic study. *Am J Sports Med* 2001;29:781–7.
- [8] DeLee JC, Curtis R. Anterior cruciate ligament insufficiency in children. *Clin Orthop Relat Res* 1983;112–8.
- [9] Kocher MS, Heyworth BE, Fabricant PD, et al. Outcomes of physal-sparing ACL reconstruction with iliotibial band autograft in skeletally immature prepubescent children. *J Bone Joint Surg Am* 2018;100:1087–94.
- [10] Kocher MS, Saxon HS, Hovis WD, et al. Management and complications of anterior cruciate ligament injuries in skeletally immature patients: survey of the Herodicus Society and The ACL Study Group. *J Pediatr Orthop* 2002;22:452–7.
- [11] Gaulrapp HM, Haus J. Intraarticular stabilization after anterior cruciate ligament tear in children and adolescents: results 6 years after surgery. *Knee Surg Sports Traumatol Arthrosc* 2006;14:417–24.
- [12] Higuchi T, Hara K, Tsuji Y, et al. Transepiphyseal reconstruction of the anterior cruciate ligament in skeletally immature athletes: an MRI evaluation for epiphyseal narrowing. *J Pediatr Orthop B* 2009;18:330–4.
- [13] Liddle AD, Imbuldeniya AM, Hunt DM. Transphyseal reconstruction of the anterior cruciate ligament in prepubescent children. *J Bone Joint Surg Br* 2008;90:1317–22.
- [14] Collins MJ, Arns TA, Leroux T, et al. Growth abnormalities following anterior cruciate ligament reconstruction in the skeletally immature patient: a systematic review. *Arthroscopy* 2016;32:1714–23.
- [15] Nakase M, Kim WC, Oka Y, et al. Detection of early changes after growth plate injury using MRI. *J Magn Reson Imaging* 2015;42:1698–704.
- [16] Yoo WJ, Kocher MS, Micheli LJ. Growth plate disturbance after transphyseal reconstruction of the anterior cruciate ligament in skeletally immature adolescent patients: an MR imaging study. *J Pediatr Orthop* 2011;31:691–6.
- [17] Matsuo T, Kinugasa K, Sakata K, et al. Post-operative deformation and extrusion of the discoid lateral meniscus following a partial meniscectomy with repair. *Knee Surg Sports Traumatol Arthrosc* 2017;25:390–6.
- [18] Anderson M, Messner MB, Green WT. Distribution of lengths of the normal femur and tibia in children from One to Eighteen years of age. *J Bone Joint Surg Am* 1964;46:1197–202.
- [19] Aguilar JA, Paley D, Paley J, et al. Clinical validation of the multiplier method for predicting limb length at maturity, part I. *J Pediatr Orthop* 2005;25:186–91.
- [20] Lee KM, Chung CY, Gwon DK, et al. Parental perspectives on leg length discrepancy. *J Pediatr Orthop B* 2012;21:146–9.
- [21] Makela EA, Vainionpaa S, Vihtonen K, et al. The effect of trauma to the lower femoral epiphyseal plate. An experimental study in rabbits. *J Bone Joint Surg Br* 1988;70:187–91.
- [22] Stadelmaier DM, Arnoczky SP, Dodds J, et al. The effect of drilling and soft tissue grafting across open growth plates. A histologic study. *Am J Sports Med* 1995;23:431–5.
- [23] Gurney B. Leg length discrepancy. *Gait Posture* 2002;15:195–206.