

Anatomic Repair vs Closed Reduction of the Syndesmosis

Foot & Ankle International®
 2021, Vol. 42(7) 877–885
 © The Author(s) 2021



Article reuse guidelines:
sagepub.com/journals-permissions
 DOI: 10.1177/1071100721990008
journals.sagepub.com/home/fai

Christopher Del Balso, MBBS, MSc, FRCSC¹ ,
 Al-Walid Hamam, MD, FRCSC^{1,2},
 Moaz Bin Yunus Chohan, MBBS, MSc¹ ,
 Christina Tieszer, MSc¹, Abdel-Rahman Lawandy, MD, PhD, FRCSC¹,
 and David William Sanders, MD, MSc, FRCSC¹

Abstract

Background: The goal of the study was to compare radiographic and functional outcomes between conventional closed syndesmotic reduction and screw fixation with open reduction, direct repair of the anterior inferior tibiofibular ligament (AiTFL) and screw fixation. We hypothesized that open reduction with restoration of the AiTFL would provide an improved reduction with better radiographic and functional outcomes.

Methods: Fifty consecutive patients with OTA 44-C ankle fractures were enrolled. Treatment was nonrandomized and based on surgeon preference. Patients were treated with either open reduction, suture-anchor AiTFL repair, and screw fixation (ART group), or conventional closed reduction of the syndesmosis followed by screw fixation (CR group). The primary outcome measure was anteroposterior (AP) displacement of the fibula on CT scan at 3 months postoperatively. Secondary outcome measures included the Maryland Foot Score, the American Orthopaedic Foot & Ankle Society (AOFAS) Ankle Hindfoot Score, and the Foot and Ankle Outcome Score (FAOS).

Results: Mean AP difference between injured and noninjured ankles was decreased in the ART group compared with the CR group (0.7 ± 0.3 mm vs 1.5 ± 0.3 mm, $P = .008$). No differences were observed between groups in overall scores for secondary outcome measures. The ART group displayed a significant difference in Maryland Foot Shoe subscore at 12 months (ART = 9.5 vs CR = 8.3, $P = .03$) and FAOS Quality of Life subscore at 12 months (64.1 compared to 38.3, $P = .04$).

Conclusion: Open anatomic syndesmotic repair resulted in improved radiographic outcomes compared with closed reduction. Cosmesis was worse at 6 weeks compared to the CR group; however, quality of life and footwear were improved in the ART group at 1 year postoperatively.

Level of Evidence: Level II, prospective comparative study.

Keywords: trauma, outcome studies, syndesmosis, arthritis

Introduction

The ankle syndesmosis is a complex joint between the distal tibia and fibula. It is stabilized by the anterior inferior tibiofibular ligament (AiTFL), the posterior inferior tibiofibular ligament (PiTFL), the inferior transverse ligament (ITL), and the interosseous membrane (IOM). Injury to these structures is common in OTA 44-C ankle fractures in which the fibular fracture is above the level of the ankle joint. Functional recovery following syndesmotic disruption is dependent on the quality of reduction of the syndesmosis.^{9,12,17,22,25} The adverse effects of syndesmosis malreduction of as little as 2 mm on clinical outcomes is becoming increasingly recognized.²⁵ The most common approach to repairing the

tibiofibular syndesmosis involves closed reduction, and screw fixation. This method relies on radiographic confirmation of reduction. The sensitivity and specificity of radiographic examination of the syndesmosis has been reported

¹Department of Orthopaedic Surgery, London Health Sciences Centre, Western University, London, Ontario, Canada

²Department of Orthopaedics, Winnipeg Regional Health Authority, Winnipeg, Manitoba, Canada

Corresponding Author:

David William Sanders, MD, MSc, FRCSC, Department of Orthopaedic Surgery, London Health Sciences Centre, 800 Commissioners Rd East, Western University, London, ON N6A5W9, Canada.

Email: david.sanders@lhsc.on.ca

Table 1. Study Inclusion and Exclusion Criteria.**Inclusion criteria**

- The subject is 18 years old or greater with a preoperative diagnosis of a Weber C (OTA 44-C) ankle fracture or isolated syndesmotom injury.
- The subject demonstrates lateral subluxation of the talus on radiographic or stress views.
- The lateral malleolus fracture if present begins at least 1.0 cm proximal to the syndesmosis.
- The subject has no history of previous severe ankle injury.
- The subject does not have an ipsilateral lower extremity injury that would impede results.
- The subject has no neuromuscular or neurosensory deficiency that would limit the ability to assess the operative procedure.
- The subject had operative repair by either closed (CR) or open fixation (ART).

Exclusion criteria

- The subject has a lateral malleolus fracture that begins less than 1.0 cm proximal to the syndesmosis.
- The subject has an open ankle fracture.
- The subject has a pathologic fracture.

Abbreviations: ART, anatomic repair technique; CR, closed reduction.

to be 31% and 83%, respectively.⁵ This explains the reported malreduction rates of 25% to 52% with this technique.²² Direct visualization has been shown to improve the quality of radiographic reduction, but no clinical correlation has been shown.¹²

This prospective study aimed to evaluate anatomic reduction, fracture healing, and return to function in patients who underwent operative repair of an unstable fracture of the ankle. Here, we compare the outcomes of patients who received treatment of an unstable syndesmotom injury by open reduction, anterior inferior tibiofibular ligament (AiTFL) suture-anchor repair, and syndesmotom screws (ART) to those who received a closed reduction with syndesmotom screw placement (CR). We hypothesized that improved outcomes would be obtained when the anatomic alignment of the ankle was restored, and the function of the syndesmosis maintained. Open reduction, with AiTFL suture anchor repair offers a novel strategy for management of syndesmotom injuries. We anticipate improved radiographic and functional outcome scores in patients undergoing open reduction of the syndesmosis with AiTFL repair, and screw fixation when compared with those receiving closed reduction and screw fixation of the syndesmosis.

Methods

Consecutive adult patients with OTA 44-C ankle fractures presenting for treatment at a level 1 trauma center from June 2013 to June 2014 were screened for inclusion in the study. The study protocol was approved by the Western University Health Sciences Research Ethics Board. A total of 50 patients were enrolled. Inclusion and exclusion criteria are listed in Table 1. Twenty-one patients underwent the anatomic repair technique (ART group) and 29 underwent standard closed reduction and screw fixation (CR group).

Operative technique was dependent upon the attending orthopedic surgeon. Two surgeons performed the ligament repair technique, whereas 4 surgeons performed standard closed reduction and screw fixation on the 50 consecutive

patients. Four of the 6 surgeons, including the 2 performing the ligament repair technique, were trauma fellowship trained. Functional outcomes were assessed using the validated Maryland Foot Score, the American Orthopaedic Foot & Ankle Society (AOFAS) Hindfoot Score, and the Foot and Ankle Outcome Score (FAOS) at 6 weeks, 3 months, 6 months, and 12 months postoperatively.^{16,18} Patient age, gender, time to surgery, mechanism of injury, and fracture pattern are shown in Table 2.

Operative Technique

Proximal fibular fractures (OTA 44-C3) did not undergo fixation. OTA 44-C fractures involving the distal third diaphyseal fibula (OTA 44-C1, OTA 44-C2) underwent standard plate and screw fixation. An external rotation stress examination verifying syndesmotom injury was then performed with the ankle in maximal dorsiflexion. Widening of the tibiofibular clear space (TCS) and medial clear space (MCS) of ≥ 2 mm was confirmatory.²⁶ Only those fractures demonstrating increased TCS and MCS ≥ 2 mm underwent syndesmotom fixation with either an open anatomic repair or closed reduction.

The ART involved direct visualization and reduction of the syndesmosis. The syndesmosis was distracted to allow interposed tissue and/or debris to be removed. Reduction was performed and verified by direct visualization alone with the ankle in maximal dorsiflexion. The reduction was maintained with manual compression until such time that the AiTFL repair was complete. AiTFL repair was performed using a suture anchor placed at the fibular footprint of the ligament, and was followed by placement of 2 syndesmotom screws (Figure 1). The closed reduction technique (CR) included reduction of the syndesmosis with reduction forceps positioned 1 cm above the joint line, with the medial tine placed in the anterior 50% of the tibia, and the ankle in maximal dorsiflexion. Fluoroscopic assessment of reduction was performed using medial clear space and tibiofibular overlap as indicators of appropriate reduction. This was

Table 2. Patient Demographics, Mechanism of Injury, and Fracture Classification.

	ART	CR	P value
Age, y, mean \pm SD	40.4 \pm 5.2	37.4 \pm 3.9	.37
Sex, %			.85
Male	71.4	70	
Female	28.6	30	
Time to treatment, d, mean \pm SD	5 \pm 2.1	3 \pm 1.2	.09
Mechanism of injury, %			.72
Low energy fall	66.7	65.5	
Sports	28.6	24.1	
MVC	4.8	10.3	
Fracture classification, %			<.01
44-C1	19	48.3	
44-C2	19	41.4	
44-C3	61.9	10.3	

Abbreviations: ART, anatomic repair technique; CR, closed reduction; MVC, motor vehicle crash.

followed by placement of 2 syndesmotom screws. All syndesmotom screws (ART and CR) were placed engaging 3 cortices. There were no differences in postoperative care between the 2 groups of patients.

Radiographic Evaluation

Standard postoperative radiographic evaluation was performed on all patients including anteroposterior (AP), lateral, and mortise views intraoperatively and then at 6 weeks and 3, 6, and 12 months post fracture. Radiographic images obtained at follow-up were used only to evaluate maintenance of the intraoperatively obtained reduction. Bilateral computed tomography (CT) scans were done 3 months postoperatively to assess the syndesmosis. A total of 41 patients underwent CT scans, with 38 having had bilateral CT imaging. Syndesmosis translation or diastasis was measured as previously described.⁵ Briefly, an axial cut 1 cm proximal to the ankle joint was used to determine the distance between the anterior and posterior facets of the tibial incisura and the fibula along a line perpendicular to the joint (AP difference) (Figure 2). Two investigators independently assessed AP difference with an intraclass correlation coefficient (ICC) of 0.84. A discrepancy between the injured and uninjured sides of more than 1 mm was considered significant. The AP difference of both groups was compared using a 2-sided *t* test ($\alpha=0.05$).

Clinical Evaluation

Functional outcomes were assessed through administration of the Maryland Foot Score, AOFAS Hindfoot Score, and the Foot and Ankle Outcome Score (FAOS) at 6 weeks and

at 3, 6, and 12 months postoperatively. Results were averaged for each time point and a 2-way analysis of variance with post hoc testing (Bonferroni) performed to determine differences in the 2 groups ($\alpha = 0.05$). Data analysis was performed using IBM SPSS Statistics for Windows, version 24 (IBM Corp, Armonk, NY).

Results

A total of 50 patients were enrolled in the investigation. Thirty-eight underwent bilateral ankle CT scanning at 3 months postoperatively (16 ART, 22 CR). Forty patients (17 ART, 23 CR) completed 12-month follow-up (Maryland Foot Score). The proportion of female patients was 28.6% in the ART group and 30% in the CR group ($P = .85$). One patient in the ART group was excluded, as their operative treatment did not follow protocol. No patient underwent routine syndesmotom screw removal. All 40 patients assessed at 12-month follow-up had plain radiographs that demonstrated lucency around syndesmotom screws indicative of loosening. Nine patients (2 ART, 7 CR) had isolated inferior syndesmotom screw breakage at final follow-up. An incomplete ossification of the syndesmosis was observed in 1 patient in the CR group. This patient was asymptomatic at final follow-up.

Radiographic Evaluation

An experienced orthopedic trauma surgeon reviewed intraoperative and postoperative x-rays. No patient had evidence of mal-reduction (>4 mm diastasis of syndesmosis) on plain films. On review of bilateral ankle CT scans, the mean difference in translation (AP difference) between injured and uninjured ankles was 0.7 ± 0.3 mm in the ART group (mean \pm SD), compared with 1.5 ± 0.3 mm in the CR group ($P = .008$) (Figure 3). Overall, 23.8% of the ART group and 55.2% of the CR group had ≥ 1 mm side-to-side difference. In addition, 4.8% of the ART group, and 17.2% of CR group had ≥ 2 mm incongruity.

Clinical Evaluation

All clinical assessments were administered at 6 weeks and 3, 6, and 12 months postoperatively. The distribution of data collected is as follows: 30 patients have 6-week data, 42 patients have 3-month data, 35 patients have 6-month data, and 40 patients have 12-month data.

Maryland Foot Score. The Cosmesis subscore was significantly greater at 6 weeks postoperatively in the CR group (10.0 ± 0.0) compared with the ART group (8.6 ± 1.7 , $P = .05$). A difference between the ART (9.5 ± 0.5) and CR (8.3 ± 0.9) group was observed for the Shoe subscore at 12 months ($P = .03$). No differences in subscores were

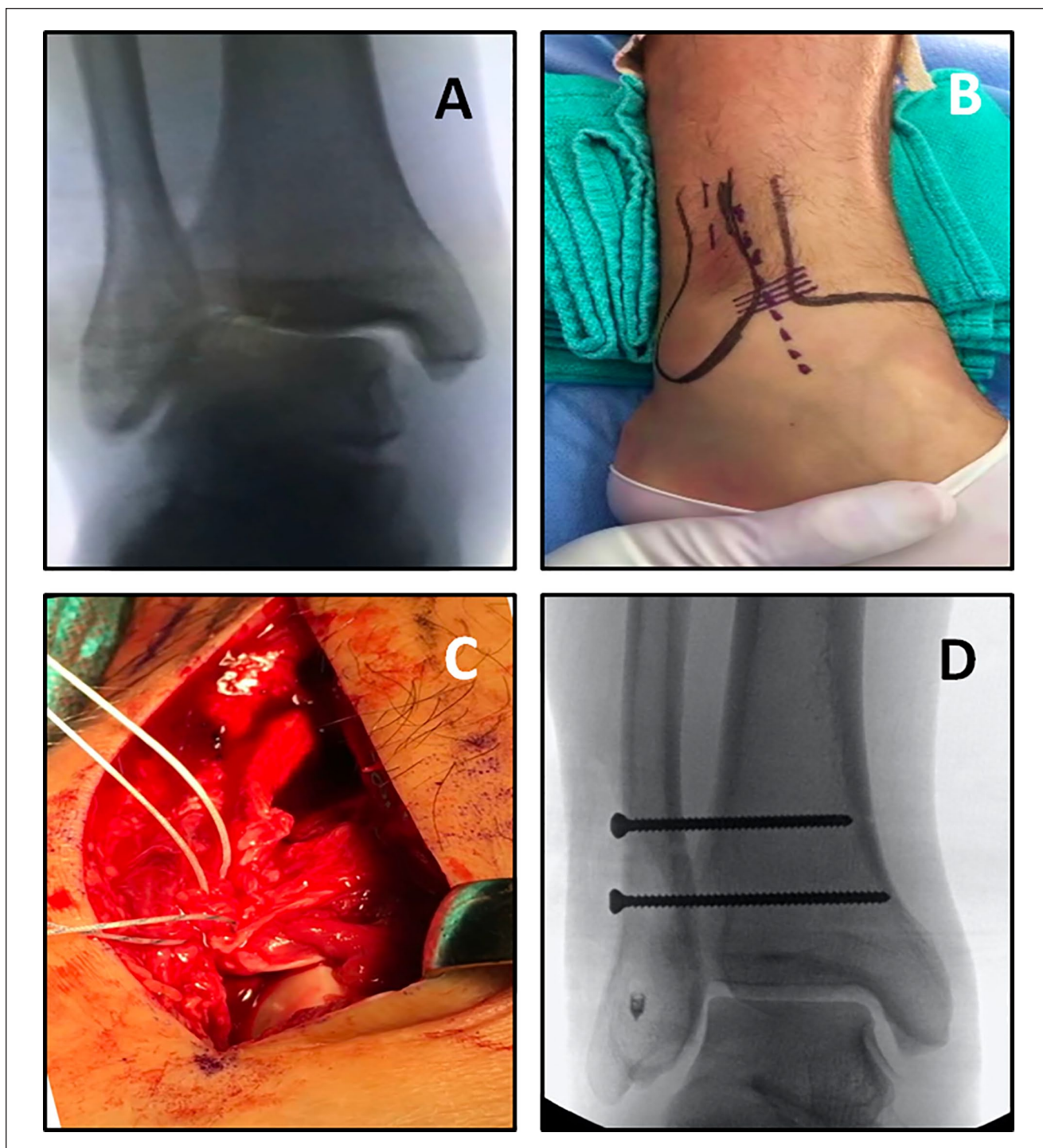


Figure 1. Anatomic repair technique (ART). (A) Intraoperative stress fluoroscopy demonstrating decreased tibiofibular overlap, and increased medial clear space. (B) Clinical photograph depicting the incision for open reduction of the syndesmosis, location of the anterior inferior tibiofibular ligament (AiTFL), and planned sites of syndesmotic screw fixation. (C) Intraoperative photograph showing suture anchor AiTFL repair. (D) Final intraoperative stress fluoroscopy following the ART demonstrates a congruent ankle mortise with a reestablished tibiofibular overlap, and appropriate medial clear space.

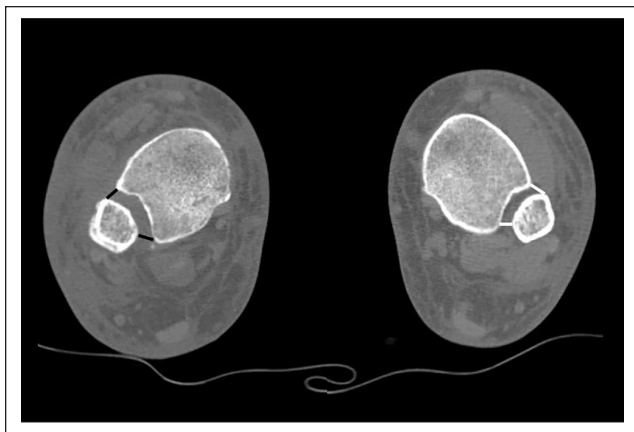


Figure 2. Anteroposterior difference was calculated as the distance between the anterior and posterior facets of the tibial incisura and the fibula. This patient (from Figure 1) underwent the anatomic repair technique (ART). The operative side (black) is compared to the uninjured side (white) on computed tomography (CT) at 3 months postoperatively.

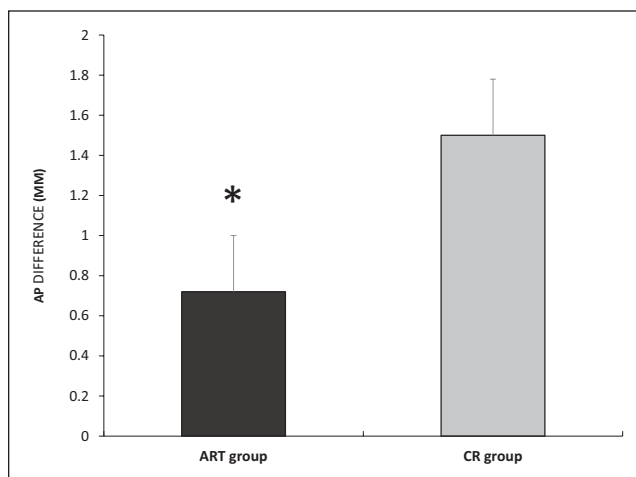


Figure 3. Anteroposterior (AP) difference comparison. The mean difference in translation (AP difference) between injured and uninjured ankles was significantly decreased in the ART group (0.7 ± 0.3 mm) when compared to the CR group (1.5 ± 0.3 mm) ($P = .008$). ART, anatomic repair technique; CR, closed reduction.

noted between groups at any other time point. No differences between groups were observed for the Maryland Foot Score (Figure 4).

AOFAS Hindfoot Score. No differences between ART and CR groups were detected with the AOFAS Hindfoot Score (Figure 5). No subscore category demonstrated differences between the groups.

Foot and Ankle Outcome Score. The Foot and Ankle Outcome Score (FAOS) revealed no difference in Total

Symptoms Score between the ART and CR groups. The Quality of Life (QoL) subscore revealed a statistically significant 25.8-point difference between the ART (64.1) and CR groups (38.2) at 12-month follow-up ($P = .04$). The Pain subscore, for which a lower score is indicative of increased pain, showed a trend toward improved scores for ART compared to CR at 12-month follow-up ($P = .07$). The Pain subscore for the ART and CR groups at 6 weeks was 70.4 ± 28.1 vs 63.9 ± 21.8 ; at 3 months was 67.9 ± 20.3 vs 57.9 ± 14.8 ; at 6 months was 73.3 ± 24.4 vs 58.0 ± 27.7 ; at 12 months was 52.8 ± 27.6 vs 43.3 ± 17.0 . There were no differences between groups with respect to any other FAOS subscores (Figure 6).

Discussion

This study endeavored to examine the radiographic and clinical benefit of open reduction of the syndesmosis with suture-anchor AiTFL repair, and screw fixation (ART) over conventional closed reduction, and screw fixation (CR) of the syndesmosis. An improved radiographic outcome was observed with the ART technique (0.7 ± 0.3 mm), as the CR group (1.5 ± 0.3 mm) demonstrated a 2-fold increased mean AP difference at 3 months as evaluated by CT. In addition, >17% of the CR group was noted to have ≥ 2 mm incongruity compared with <5% in the ART group. Clinically, the ART group demonstrated improved footwear (Maryland Foot Score, Shoe subscore) and improved quality of life (FAOS, Quality of Life subscore) at 12 months. These represent encouraging results with respect to the superiority of open reduction of the syndesmosis with suture-anchor AiTFL repair, and screw fixation (ART) over conventional closed reduction with percutaneous screw fixation (CR).

The syndesmosis is a complex joint between the distal tibia and fibula. The syndesmosis must accommodate forces of 500 N during walking, 1250 N during running, and approximately 7.5 Nm of torque resistance.^{2,10,21} It must allow for 1 to 2 mm of mortise widening, 3 to 5 degrees of external rotation, and 2 to 3 mm of proximal and distal migration during gait.¹⁹ It is estimated that 6445 syndesmotom injuries occur annually in the United States, with an incidence of 2.09 per 100 000 person-years.²³ Although not as common as other injuries about the ankle, ankle fractures with syndesmotom injury requiring fixation have been reported to result in the development of end-stage ankle arthrosis in 11% of cases.¹⁴ Malreduction has been shown to be the only modifiable risk factor for the development of end-stage arthrosis of the ankle in fractures that require syndesmotom fixation.¹⁴ The precise degree of malreduction that is clinically significant so as to produce end-stage ankle arthrosis is unknown. It is speculated to be in excess of 2 mm utilizing the AP difference technique employed in this study.²⁴

Conventional closed reduction with percutaneous screw fixation (CR) relies on radiographic confirmation of

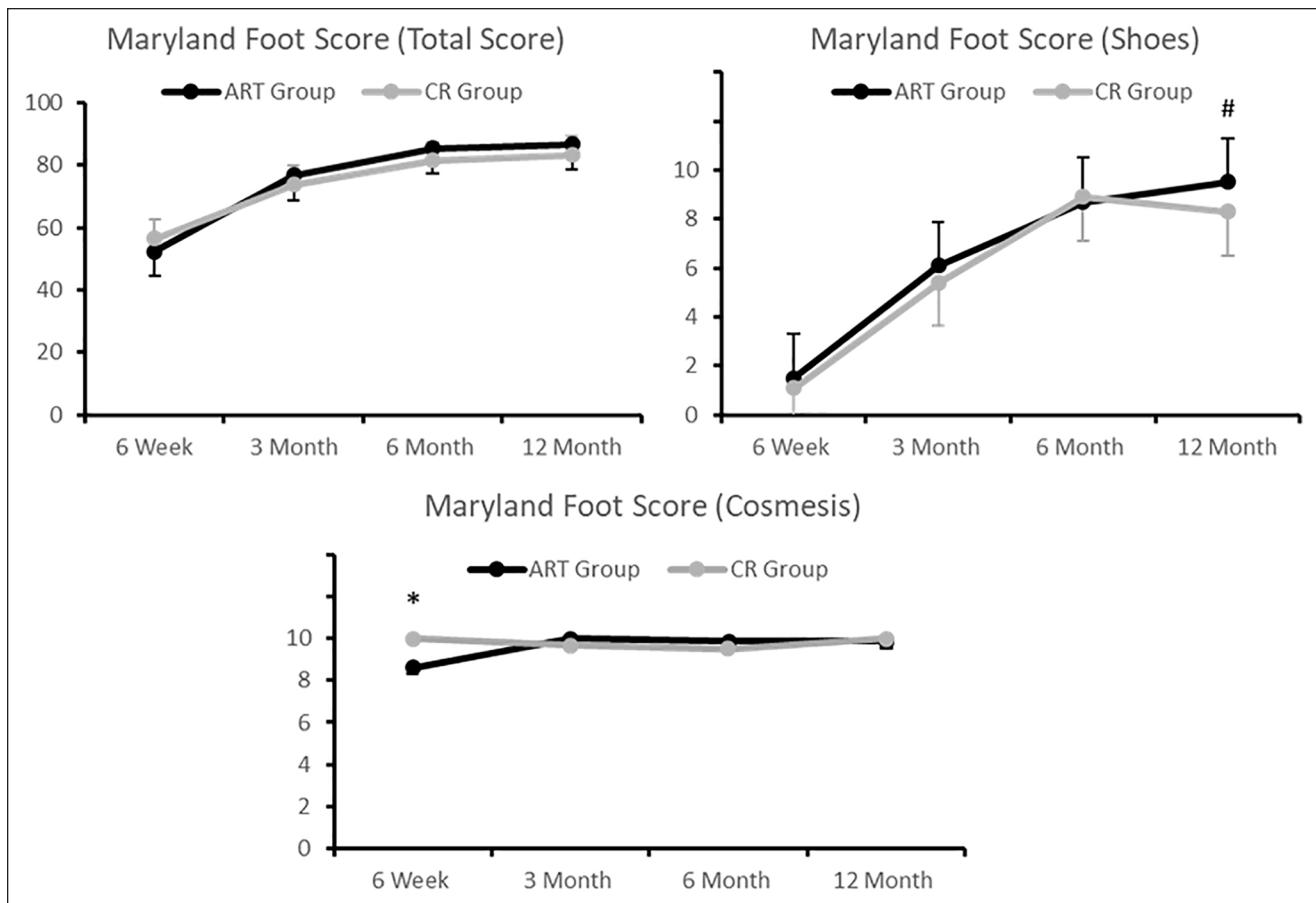


Figure 4. Maryland Foot Score. The Cosmesis subscore was significantly greater at 6 weeks postoperatively in the CR group (10.0 ± 0.0) compared with the ART group (8.6 ± 1.7) ($*P = .05$). A difference between the ART (9.5 ± 0.5) and CR (8.3 ± 0.9) group was observed for the Shoe subscore at 12 months ($\#P = .03$). ART, anatomic repair technique; CR, closed reduction.

reduction, and malreduction rates of 25%-52% have been reported in the literature with this technique.²² Previous trials have used plain radiographs for assessment of syndesmotic reduction, but this can underestimate further the rate of malreduction compared to CT imaging techniques.^{1,4-6,8,13,15,17} For this reason, CT scans at 3 months following operative intervention were used for assessment of reduction in the present study. Overall, malreduction rates in this study with closed reduction were decreased compared to that previously published. Surgeons' ability to judge reductions on the lateral view has improved over time. Nonetheless, the results observed here favor open reduction as 17.2% of patients who underwent conventional closed reduction with percutaneous screw fixation exhibited ≥ 2 mm of malreduction, compared with just 4.8% in the ART group.

Direct visualization has been shown to improve the quality of radiographic reduction.¹² In this investigation, open reduction combined with suture-anchor AiTFL repair and syndesmotic screws provided both improved radiographic and clinical outcomes. The relative contributions of the

open reduction and suture-anchor AiTFL repair are unknown. It stands to reason that direct visualization of the syndesmosis, stabilized by AiTFL repair prior to screw placement, would provide improved radiographic outcomes. Open anatomic reduction that consists of manual reduction and repair of the AiTFL prior to inserting syndesmotic screws may help to avoid rotational and translational malreduction of the syndesmosis. This assumption is supported by studies that show a high malreduction rate with closed reduction of the syndesmosis and a persistent (albeit low) malreduction with open reduction when the ligament is not repaired.^{11,17} The improved clinical outcomes in the ART group are likely a product of both improved reduction and AiTFL repair. Repair of the ligament may lead to improved healing of the AiTFL and restoration of ankle dynamics. Biomechanical investigation has demonstrated the importance of the AiTFL in syndesmotic stability, with a significant (24%) reduction in resistance to external rotation force with isolated sectioning of the AiTFL.³ Arthroscopic techniques exist for assistance in syndesmotic reduction and can be combined with use of a flexible

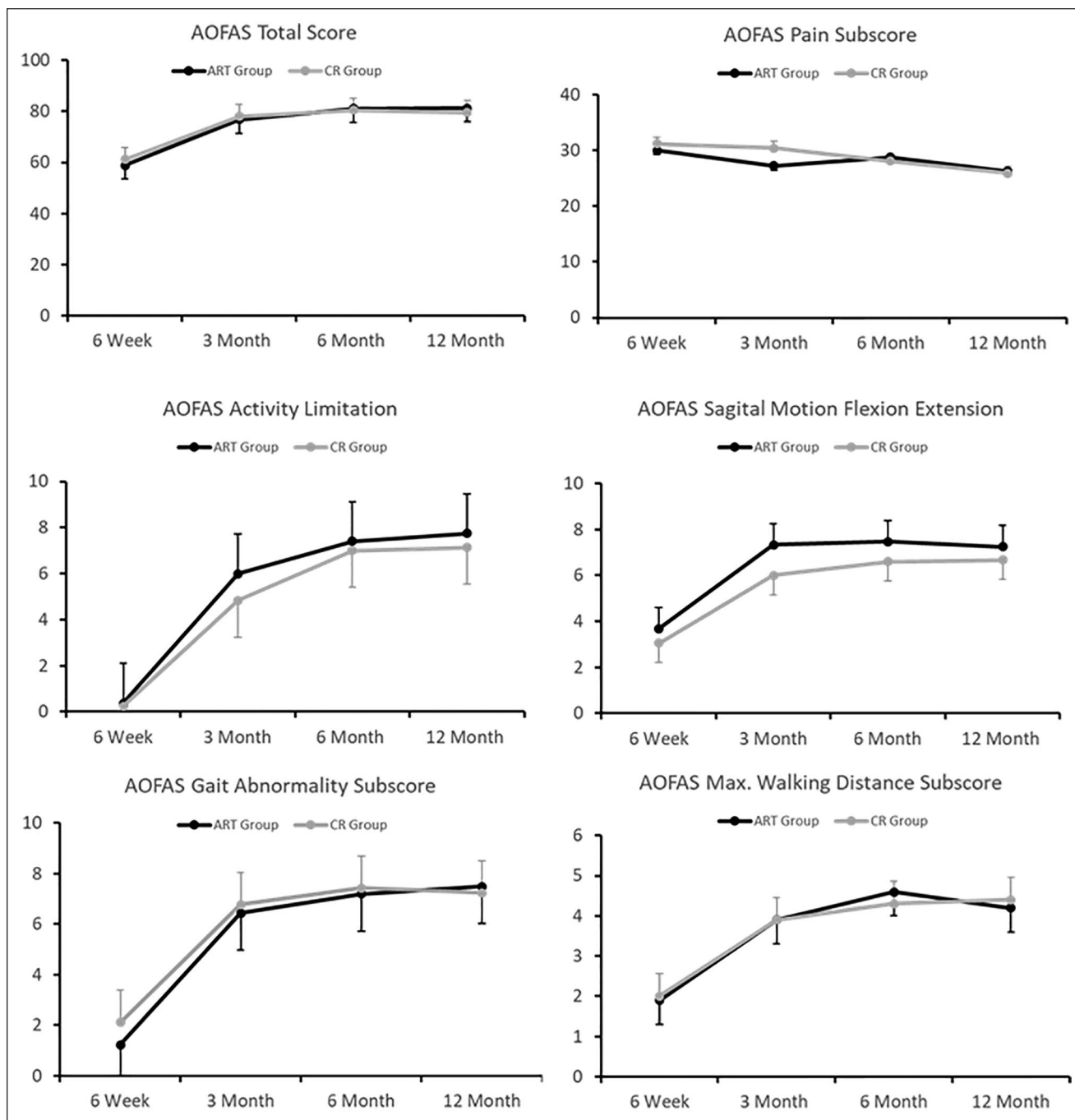


Figure 5. AOFAS Hindfoot Score. No differences between groups (ART vs CR) were observed for AOFAS total score, or any subscore. AOFAS, American Orthopaedic Foot & Ankle Society; ART, anatomic repair technique; CR, closed reduction.

stabilization construct. There exists a lack of clarity with respect to outcomes afforded by flexible vs static constructs, and there is the notion of excessive translation in the sagittal plane.^{7,20} Improved radiographic outcomes as observed in the ART group in the current investigation have corresponded to improved clinical outcomes in other studies.^{9,12,17,22,25} Clinical outcomes are considered to be a product of the quality of reduction. In our study, the

improvement in reduction quality with an open technique, and AiTFL repair was associated with improved footwear (Maryland Foot Score, Shoe subscore) and improved quality of life (FAOS, Quality of Life subscore) at 12 months when compared to conventional closed reduction with screw fixation. We speculate that this may be due to the increased rate (55.2%) of slight malreduction (between 1 and 2 mm) in the CR group, compared to just 23.8% in the

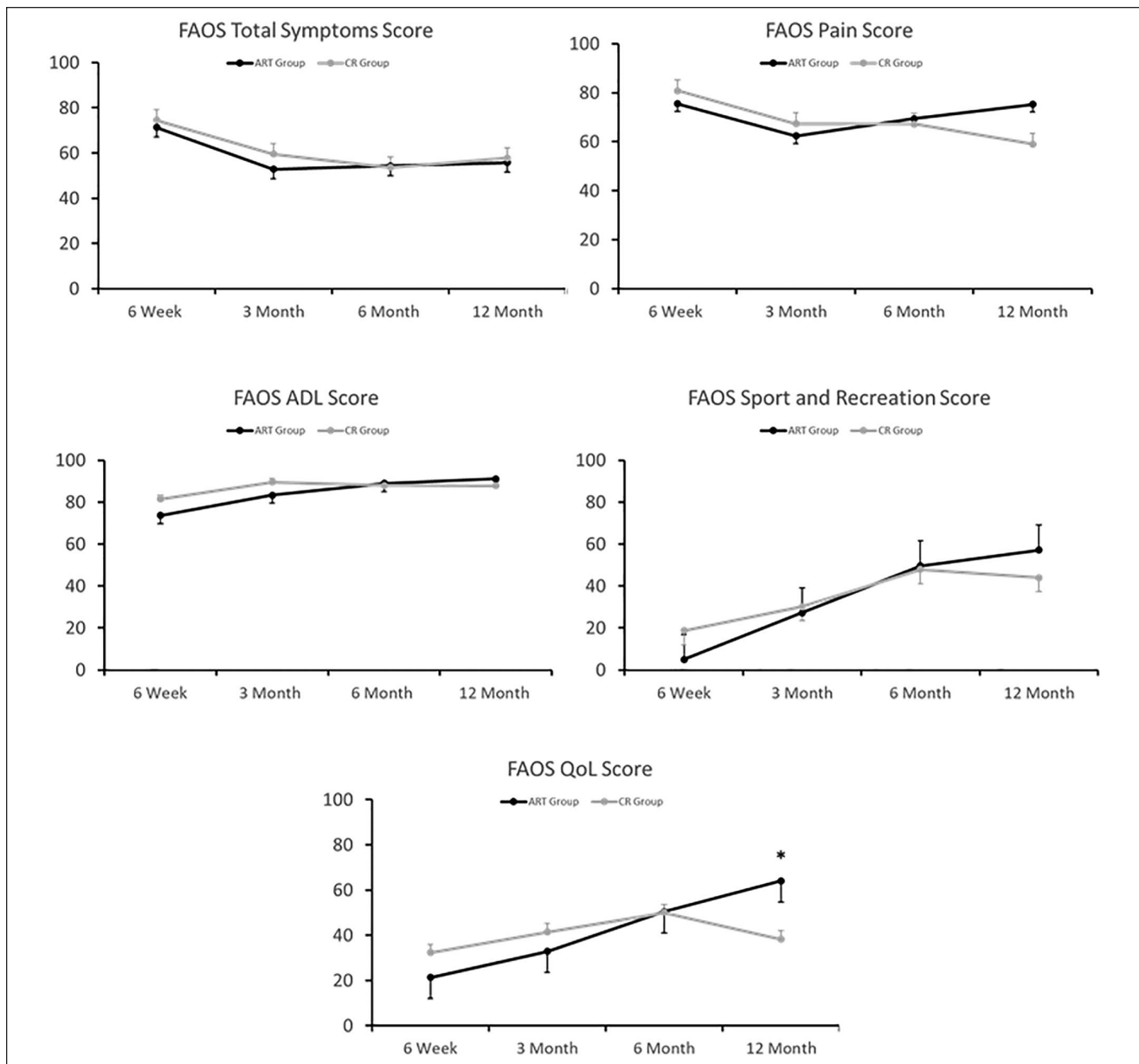


Figure 6. Foot and Ankle Outcome Score (FAOS). A significantly greater QoL subscore was observed at 12 months ($*P = .04$) in the ART group (64.1 ± 9.3) compared with the CR group (38.3 ± 8.1). ADL, activities of daily living; ART, anatomic repair technique; CR, closed reduction; QoL, Quality of Life.

ART group. It is generally agreed that more than 2 mm of malreduction is clinically significant.⁵ The results of this study would suggest that even as little as 1 mm of malreduction of the syndesmosis compared to the uninjured side can have a significant effect on clinical outcomes. The authors' enthusiasm for drawing this conclusion is tempered by the current investigation's relatively short-term outcomes.

Limitations of this study include those inherent to the lack of randomization of treatment, and a relatively small sample size with loss of patients to follow-up. The use of CT provides increased sensitivity for detection of malreduction when compared to plain radiography. However, the

inability to obtain weight-bearing CT imaging represents a limitation as syndesmoses may reduce under physiologic loads.

In conclusion, open reduction of the syndesmosis with suture-anchor AiTFL repair and screw fixation in OTA 44-C ankle fractures produced improved short-term radiographic and clinical outcomes when compared to conventional closed reduction and screw fixation, in the present investigation. The inability to elucidate relative contributions of open reduction and AiTFL repair in the improved radiographic and clinical outcomes represents an opportunity for further research. Future investigation of open reduction and

AiTFL repair vs closed reduction of syndesmotic injuries will be facilitated by the use of weight-bearing computed tomography, and benefit from longer follow-up.

Declaration of Conflicting Interests

The author(s) declared the following potential conflicts of interest with respect to the research, authorship, and/or publication of this article: Christopher Del Balso MBBS, MSc, FRCSC, Moaz Bin Yunus Chohan MBBS, MSc, and Christina Tieszer, MSc, report grants from Smith & Nephew, during the conduct of the study. ICMJE forms for all authors are available online.

Funding

The author(s) disclosed receipt of the following financial support for the research, authorship, and/or publication of this article: Smith & Nephew Orthopaedics.

ORCID iDs

Christopher Del Balso, MBBS, MSc, FRCSC,  <https://orcid.org/0000-0003-4074-6424>

Moaz Bin Yunus Chohan, MBBS, MSc,  <https://orcid.org/0000-0002-6588-5618>

References

- Anand A, Wei R, Patel A, Vedi V, Allardice G, Anand BS. Tightrope fixation of syndesmotic injuries in Weber C ankle fractures: a multicentre case series. *Eur J Orthop Surg Traumatol*. 2017;27(4):461-467.
- Burdett RG. Forces predicted at the ankle during running. *Med Sci Sports Exerc*. 1982;14(4):308-316.
- Clanton TO, Williams BT, Backus JD, et al. Biomechanical analysis of the individual ligament contributions to syndesmotic stability. *Foot Ankle Int*. 2017;38(1):66-75.
- Cottom JM, Hyer CF, Philbin TM, Berlet GC. Transosseous fixation of the distal tibiofibular syndesmosis: comparison of an interosseous suture and endobutton to traditional screw fixation in 50 cases. *J Foot Ankle Surg*. 2009;48(6):620-630.
- Gardner MJ, Demetrakopoulos D, Briggs SM, Helfet DL, Lorch DG. Malreduction of the tibiofibular syndesmosis in ankle fractures. *Foot Ankle Int*. 2006;27(10):788-792.
- Kocadal O, Yucel M, Pepe M, Aksahin E, Aktekin CN. Evaluation of reduction accuracy of suture-button and screw fixation techniques for syndesmotic injuries. *Foot Ankle Int*. 2016;37(12):1317-1325.
- Kromka JJ, Chambers MC, Popchak A, Irrgang J, Hogan MV. In a small retrospective cohort of patients with syndesmotic injury, only athletes benefited from placement of a suture button device: a pilot study. *J ISAKOS*. 2019;4(1):21-25.
- Laflamme M, Belzile EL, Bedard L, van den Bekerom MP, Glazebrook M, Pelet S. A prospective randomized multicenter trial comparing clinical outcomes of patients treated surgically with a static or dynamic implant for acute ankle syndesmosis rupture. *J Orthop Trauma*. 2015;29(5):216-223.
- Manjoo A, Sanders DW, Tieszer C, MacLeod MD. Functional and radiographic results of patients with syndesmotic screw fixation: implications for screw removal. *J Orthop Trauma*. 2010;24(1):2-6.
- Markolf KL, Schmalzried TP, Ferkel RD. Torsional strength of the ankle in vitro. The supination-external-rotation injury. *Clin Orthop Relat Res*. 1989;246:266-272.
- Miller AN, Barei DP, Iaquinio JM, Ledoux WR, Beingsner DM. Iatrogenic syndesmosis malreduction via clamp and screw placement. *J Orthop Trauma*. 2013;27(2):100-106.
- Miller AN, Carroll EA, Parker RJ, Boraiah S, Helfet DL, Lorch DG. Direct visualization for syndesmotic stabilization of ankle fractures. *Foot Ankle Int*. 2009;30(5):419-426.
- Naqvi GA, Shafiqat A, Awan N. Tightrope fixation of ankle syndesmosis injuries: clinical outcome, complications and technique modification. *Injury*. 2012;43(6):838-842.
- Ray R, Koohnejad N, Clement ND, Keenan GF. Ankle fractures with syndesmotic stabilisation are associated with a high rate of secondary osteoarthritis. *Foot Ankle Surg*. 2019;25(2):180-185.
- Rigby RB, Cottom JM. Does the Arthrex TightRope R provide maintenance of the distal tibiofibular syndesmosis? A 2-year follow-up of 64 TightRopes R in 37 patients. *J Foot Ankle Surg*. 2013;52(5):563-567.
- Roos EM, Brandsson S, Karlsson J. Validation of the foot and ankle outcome score for ankle ligament reconstruction. *Foot Ankle Int*. 2001;22(10):788-794.
- Sagi HC, Shah AR, Sanders RW. The functional consequence of syndesmotic joint malreduction at a minimum 2-year follow-up. *J Orthop Trauma*. 2012;26(7):439-443.
- Schepers T, Heetveld MJ, Mulder PG, Patka P. Clinical outcome scoring of intra-articular calcaneal fractures. *J Foot Ankle Surg*. 2008;47(3):213-218.
- Scranton PE Jr, McMaster JG, Kelly E. Dynamic fibular function: a new concept. *Clin Orthop Relat Res*. 1976;118:76-81.
- Seyhan M, Donmez F, Mahirogullari M, Cakmak S, Mutlu S, Guler O. Comparison of screw fixation with elastic fixation methods in the treatment of syndesmosis injuries in ankle fractures. *Injury*. 2015;46(suppl 2):S19-S23.
- Stauffer RN, Chao EY, Brewster RC. Force and motion analysis of the normal, diseased, and prosthetic ankle joint. *Clin Orthop Relat Res*. 1977;127:189-196.
- Van Heest TJ, Lafferty PM. Injuries to the ankle syndesmosis. *J Bone Joint Surg Am*. 2014;96(7):603-613.
- Vosseller JT, Karl JW, Greisberg JK. Incidence of syndesmotic injury. *Orthopedics*. 2014;37(3):e226-e229.
- Warner SJ, Fabricant PD, Garner MR, Schottel PC, Helfet DL, Lorch DG. The measurement and clinical importance of syndesmotic reduction after operative fixation of rotational ankle fractures. *J Bone Joint Surg Am*. 2015;97(23):1935-1944.
- Weening B, Bhandari M. Predictors of functional outcome following transsyndesmotic screw fixation of ankle fractures. *J Orthop Trauma*. 2005;19(2):102-108.
- Xenos JS, Hopkinson WJ, Mulligan ME, Olson EJ, Popovic NA. The tibiofibular syndesmosis. Evaluation of the ligamentous structures, methods of fixation, and radiographic assessment. *J Bone Joint Surg Am*. 1995;77(6):847-856.