

A case of Bietti crystalline dystrophy with clinical, electrophysiological, and imaging findings

 Murat Garli,  Sevda Aydin Kurna

Department of Ophthalmology, Health Sciences University, Fatih Sultan Mehmet Training and Research Hospital, Istanbul, Turkey

ABSTRACT

In this study, ophthalmologic examination findings, fundus fluorescein angiography, optic coherence tomography (OCT), visual field testing, electrophysiological, and systemic laboratory findings of a 43-year-old female patient who presented with blurry vision and who had retinal and corneal deposits were examined. Our patients' best-corrected visual acuity was 0.9 bilaterally. Her anterior segments and intraocular pressures were bilaterally normal. Fundus examination revealed bilateral glistening yellowish intraretinal crystalline deposits in the posterior pole and midperipheral retina. The electroretinographic examination revealed a decrease in scotopic and photopic a and b wave amplitudes. Corneal and intraretinal glistening crystalloid deposits were observed in the OCT. Our patient and her husband were relatives. Her sister's, brother's, and children's OCT also revealed bilateral corneal and intraretinal crystalloid deposits. We diagnosed this case as Bietti's crystalline dystrophy which is a rare disease with genetic inheritance that must be considered in the differential diagnosis in countries in which consanguineous marriage is often.

Keywords: Bietti's crystalline dystrophy; crystal deposit; electroretinography.

Cite this article as: Garli M, Aydin Kurna S. A case of Bietti crystalline dystrophy with clinical, electrophysiological, and imaging findings. *North Clin Istanbul* 2021;8(5):521–524.

Bietti's crystalline dystrophy (BCD) was described by Bietti in 1937 as a tapetoretinal degeneration with marginal corneal dystrophy [1]. Fundus examination reveals bright yellow-white crystals in the posterior pole, atrophy of the retinal pigment epithelium (RPE), and choroidal sclerosis [2]. Histopathological studies show significant damage to the RPE and choriocapillaris, choroid atrophy, focal hypertrophy, hyperplasia, and migration of RPE cells to the retina [3]. It is usually asymptomatic until 20–30 years of age. Patients may experience difficulty in night vision, color vision defect, or decreased visual acuity. Our aim in presenting this case is to evaluate the clinical, laboratory and electrophysiological findings, and imaging results together with the differential diagnosis.

CASE REPORT

A 43-year-old woman presented to our clinic with blurry vision. Her best-corrected visual acuity was 0.9 bilaterally. Her anterior segments and intraocular pressures were bilaterally natural. Fundus examination revealed bilateral glistening yellowish intraretinal crystalline deposits in the posterior pole and midperipheral retina (Fig. 1).

Fundus fluorescein angiography (FFA) revealed prominent choroidal vessels within the areas of choroidal atrophy and patchy hypofluorescence due to choroidal sclerosis bilaterally (Fig. 2). Hyperreflective dots in the intraretinal layers and RPE, thickening of the RPE-choriocapillaris complex were observed in the optical coherence tomography (OCT) (Fig. 3a). Visual field testing

Received: April 23, 2019 *Accepted:* November 13, 2019 *Online:* October 06, 2021



Correspondence: Murat GARLI, MD. Saglik Bilimleri Universitesi, Fatih Sultan Mehmet Egitim ve Arastirma Hastanesi, Goz Hastaliklari Klinigi, Istanbul, Turkey.

Tel: +90 216 578 30 00 e-mail: muratgarli@hotmail.com

© Copyright 2021 by Istanbul Provincial Directorate of Health - Available online at www.northclinist.com

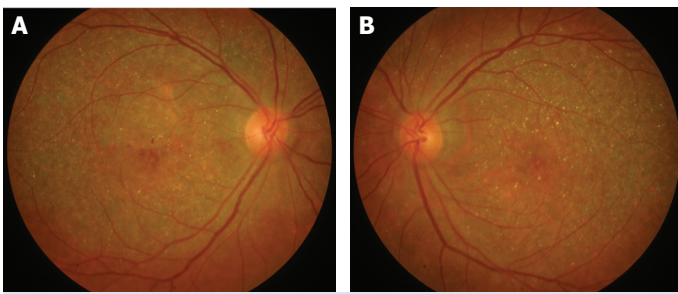


FIGURE 1. (A) Intraretinal crystalloid deposits are observed in the right fundus image. (B) Intraretinal crystalloid deposits are observed in the left fundus image.

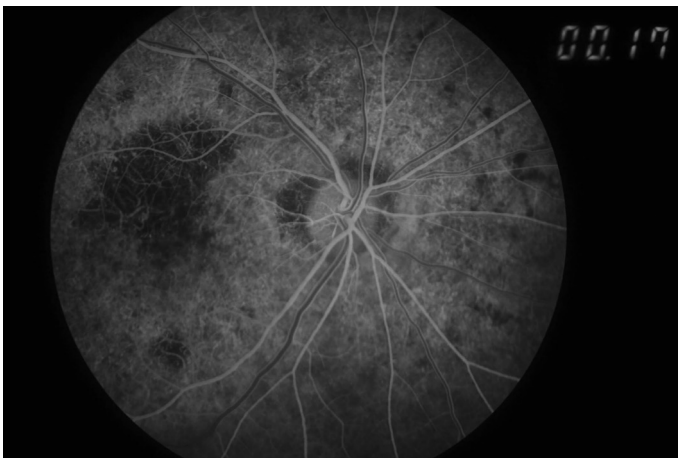


FIGURE 2. Fundus fluorescein angiography of the right eye shows hypofluorescent patchy areas due to choroidal sclerosis.

showed central scotomas bilaterally. Bilateral corneal subepithelial hyperreflective crystalloid deposits were observed in the anterior segment OCT (Fig. 3b).

The electroretinographic examination revealed a decrease in scotopic and photopic a and b wave amplitudes bilaterally. The electrooculographic values were normal. Total cholesterol, low-density lipoprotein (LDL), and triglyceride levels were high. Renal function tests were also normal in her blood testing. Lipid electrophoresis showed low levels of alpha lipoproteins and normal levels of pre-beta and beta-lipoproteins. Cystine and oxalate were not detected in the complete urinalysis.

Our patient had no history of anesthesia or drug use. She and her husband were relative (brother's grandchildren). Her sister's, brother's, and children's OCTs also revealed bilateral corneal subepithelial deposits or hyperreflective dots in the intraretinal layers or in the RPE layer.

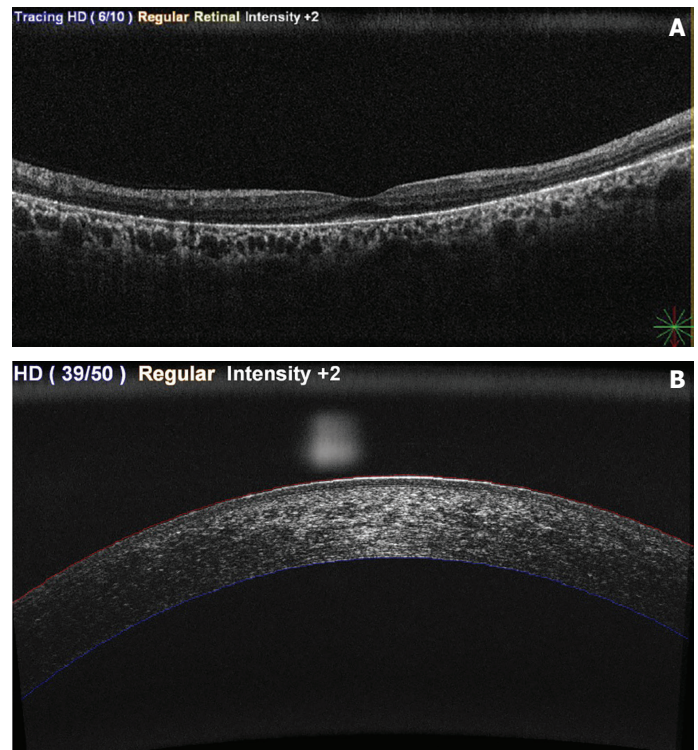

FIGURE 3. (A) Hyperreflective dots in the intraretinal layers and in the retinal pigment epithelium layer are observed in the optic coherence tomography of the left eye. (B) Corneal subepithelial hyperreflective deposits are observed in the anterior segment optic coherence tomography of the right eye.

Consent form was obtained from the patient for publication of personal information and photographs in a scientific journal.

DISCUSSION

BCD is a rare disease with the incidence of 1/67,000. We diagnosed our case as BCD with her clinical findings. Other diseases that should be considered in the differential diagnosis are fundus albipunctatus, retinitis punctata albescens, retinitis pigmentosa, Stargardt's disease, fundus flavimaculatus, cystinosis, and primary hyperoxaluria. We excluded the fundus albipunctatus or retinitis punctata albescens as we did not observe a patchy hyperfluorescence in the midperipheral fundus or white, round, opaque deposits in the posterior pole, instead our case had bilateral glistening yellowish intraretinal crystalline deposits in the posterior pole and midperipheral retina. Visual fields were also normal. We excluded the diagnosis of retinitis pigmentosa and

fundus flavimaculatus since the retinal vessels and optic discs were normal, bone spicules were not observed and dark choroid was not seen in the FFA. Peripheral vision and dark adaptation were also normal. Patients with cystinosis have cystine crystal accumulation in the cornea, conjunctiva, ciliary body, optic nerve, and sclera. Deposits in the fundus are at the level of RPE and choroid, but are not seen on all layers of the retina differing from BCD. In primary hyperoxaluria, excretion of oxalate and glycolate in urine increases. In our patient, these diagnoses were excluded with the results of the urinalysis and ocular examination. The differential diagnosis of crystals in the retina includes tamoxifen, canthaxanthine, talc, and nitrofurantoin poisoning [4]. Drug toxicity was also excluded since there was no history of drug use or anesthesia in our patient.

In our patient's macular OCT, we observed thickening of the RPE-choriocapillaris complex, hyperreflective dots in the intraretinal layers and in the RPE layer. Bright crystalloid corneal subepithelial deposits were observed in anterior segment OCT examination. Meyer et al. [5] reported similar OCT findings as hyperreflective crystalline deposits in the sensorial retina and RPE and thickening of the RPE-choriocapillaris complex. Querques et al. [6] indicated that hyperreflective deposits can be demonstrated in all layers of retina with OCT. Karaçorlu et al. [7] reported that RPE-choriocapillaris complex was thickened and reflectivity was increased only in the layer of RPE-choriocapillaris complex in their BCD case.

Crystal formation in BCD may possibly be due to lipid-binding protein anomaly or due to defective enzymes which are responsible for elongation and desaturation of fatty acids [8]. Cholesterol, cholesterol esters, and complex lipid inclusions in these patients are shown in corneal and conjunctival fibroblasts and circulating lymphocytes [3, 9]. In one case, while serum cholesterol and triglyceride levels were high, alpha, pre-beta, and beta-lipoproteins were found to be normal [10]. In our case, serum total cholesterol, LDL cholesterol, and triglyceride levels were high. Furthermore, serum alpha lipoproteins were high in lipid electrophoresis while pre-beta and beta-lipoproteins were normal in our case.

The heredity pattern of BCD is not clear. X-linked inheritance [3], autosomal recessive inheritance [11], and autosomal dominant inheritance [2] have been reported. An autosomal recessive mutation in the CYP4V2 gene which is located in the short arm of the fourth chromosome is considered to be responsible for the development

of BCD [11]. It is thought that due to the lack of enzyme involved in lipid metabolism crystalline material accumulates in the retina, cornea, and conjunctiva.

The electrophysiological findings of the cases in the literature are quite different. The ERG responses can be normal in some cases or small changes can be observed in scotopic response [1, 3]. In our case, mean scotopic and photopic a and b wave amplitudes were decreased bilaterally in ERG. The Arden ratios were normal in both eyes in EOG.

BCD is a rare disease with genetic inheritance. It must be considered in differential diagnosis in countries in which consanguineous marriage is often. Because of the slow progressive course of the disease, electrophysiological tests, anterior and posterior segment OCT, FFA, visual field examination, and laboratory tests may be useful in the early diagnosis and follow-up of patients.

Informed Consent: Written informed consent was obtained from the patient for the publication of the case report and the accompanying images.

Conflict of Interest: No conflict of interest was declared by the authors.

Financial Disclosure: The authors declared that this study has received no financial support.

Authorship Contributions: Concept – MG, SAK; Design – MG, SAK; Supervision – MG, SAK; Fundings – MG; Materials – SAK; Data collection and/or processing – MG; Analysis and/or interpretation – SAK; Literature review – MG; Writing – MG, SAK; Critical review – MG, SAK.

REFERENCES

- Harrison RJ, Acheson RR, Dean-Hart JC. Bietti's tapetoretinal degeneration with marginal corneal dystrophy (crystalline retinopathy): case report. *Br J Ophthalmol* 1987;71:220–3.
- Richards BW, Brodstein DE, Nussbaum JJ, Ferencz JR, Maeda K, Weiss L. Autosomal dominant crystalline dystrophy. *Ophthalmology* 1991;98:658–65.
- Wilson DJ, Weleber RG, Klein ML, Welch RB, Green WR. Bietti's crystalline dystrophy. A clinicopathologic correlative study. *Arch Ophthalmol* 1989;107:213–21.
- Nadim F, Walid H, Adib J. The differential diagnosis of crystals in the retina. *Int Ophthalmol* 2001;24:113–21.
- Meyer CH, Rodrigues EB, Mennel S, Schmidt JC. Optical coherence tomography in a case of Bietti's crystalline dystrophy. *Acta Ophthalmol Scand* 2004;82:609–12.
- Querques G, Quijano C, Bouzitou-Mfoumou R, Soubrane G, Souied EH. In-vivo visualization of retinal crystals in Bietti's crystalline dystrophy by spectral domain optical coherence tomography. *Ophthalmic Surg Lasers Imaging* 2010;1–3.
- Karaçorlu SA, Özdemir H, Şentürk F. Bietti'nin kristalin retinopatisinde optik koherens tomografi. *MN Oftalmol* 2006;13:148–50.

8. Lee J, Jiao X, Hejtmancik JF, Kaiser-Kupfer M, Gahl WA, Markello TC, et al. The metabolism of fatty acids in human Bietti crystalline dystrophy. *Invest Ophthalmol Vis Sci* 2001;42:1707–14.
9. Kaiser-Kupfer MI, Chan CC, Markello TC, Crawford MA, Caruso RC, Csaky KG, et al. Clinical biochemical and pathologic correlations in Bietti's crystalline dystrophy. *Am J Ophthalmol* 1994;118:569–82.
10. Özkırış A, Öner A, Everekliođlu C, Erkılıç K, Mirza E, Dođan H. A comparison of electroretinographic values of patients with Bietti's crystalline dystrophy with normal individuals. *Erciyes Med J* 2004;26:113–8.
11. Li A, Jiao X, Munier FL, Schorderet DF, Yao W, Iwata F, et al. Bietti crystalline corneoretinal dystrophy is caused by mutations in the novel gene CYP4V2. *Am J Hum Genet* 2004;74:817–26.
12. Harrison RJ, Acheson RR, Dean-Hart JC. Bietti's tapetoretinal degeneration with marginal corneal dystrophy (crystalline retinopathy): case report. *Br J Ophthalmol* 1987;71:220–3.