

Available online at [www.sciencedirect.com](http://www.sciencedirect.com)

ScienceDirect

journal homepage: <http://Elsevier.com/locate/radcr>

## Gastrointestinal

# The presence of an asymptomatic aberrant right subclavian artery: A potential risk factor in esophageal surgery?

Seung-Hun Chon MD<sup>a,\*</sup>, Felix Berlth MD<sup>a</sup>, De-Hua Chang MD<sup>b</sup>, Stefan P. Mönig MD<sup>c</sup>

<sup>a</sup> Department of General, Visceral and Cancer Surgery, University of Cologne, Kerpener Strasse 62, 50937 Cologne, Germany

<sup>b</sup> Department of Diagnostic and Interventional Radiology, University of Cologne, Cologne, Germany

<sup>c</sup> Surgery Department, Geneva University Hospitals, Geneva, Switzerland

### ARTICLE INFO

#### Article history:

Received 24 August 2017

Received in revised form 30

September 2017

Accepted 1 October 2017

Available online 21 November 2017

#### Keywords:

Right subclavian artery

Arteria lusoria

Arterial-esophageal fistula

Esophagectomy

### ABSTRACT

Bleeding of an aberrant right subclavian artery following transthoracic en bloc esophagectomy and intrathoracic gastric reconstruction is a rare but severe complication in esophageal surgery. Preoperative diagnosis can be achieved by computed tomography or magnetic resonance angiography (MRA). Various treatment options are available; thus, the treatment can be challenging and should be adjusted to the severity of the symptoms. Bleeding of an aberrant right subclavian artery can result from perioperative vascular injury or various postoperative complications. We report about a case of a patient with esophageal cancer and an asymptomatic, simultaneously existing aberrant right subclavian artery. The patient underwent a successful conventional Ivor-Lewis esophageal resection without any life-threatening bleeding. Early detection and intraoperative identification was of major importance for successful surgery.

© 2017 the Authors. Published by Elsevier Inc. under copyright license from the University of Washington. This is an open access article under the CC BY-NC-ND license (<http://creativecommons.org/licenses/by-nc-nd/4.0/>).

## Introduction

Anomalies of the aortic arch occur in 0.5%–2.5% of the population according to the literature [1,2]. The precise incidence is unknown and can only be derived from clinically symptomatic cases or incidental findings during surgery. However, because of the introduction of improved diagnostic tools such as high-resolution computed tomography (CT) or magnetic resonance angiography (MRA), asymptomatic courses of the aberrant right subclavian artery (arteria lusoria) are increasingly

being discovered as an incidental finding. The clinical staging procedures of the simultaneous occurrence of esophageal cancer can uncover the appearance of an aberrant right subclavian artery. In this context, it presents a potentially life-threatening risk when oncological resection is performed, for example, blunt dissection or thoracoscopic mobilization of the thoracic esophagus [3]. We report about a patient with cancer of the esophagus and an asymptomatic aberrant right subclavian artery. Because of the preoperative identification and careful intraoperative dissection, the resection was successfully performed without any life-threatening bleeding.

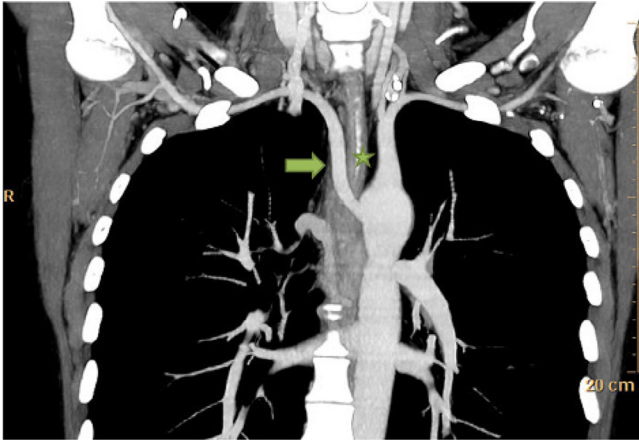
Competing Interests: The authors have declared that no competing interests exist.

\* Corresponding author.

E-mail address: [Seung-Hun.Chon@uk-koeln.de](mailto:Seung-Hun.Chon@uk-koeln.de) (S.-H. Chon).

<https://doi.org/10.1016/j.radcr.2017.10.004>

1930-0433/© 2017 the Authors. Published by Elsevier Inc. under copyright license from the University of Washington. This is an open access article under the CC BY-NC-ND license (<http://creativecommons.org/licenses/by-nc-nd/4.0/>).



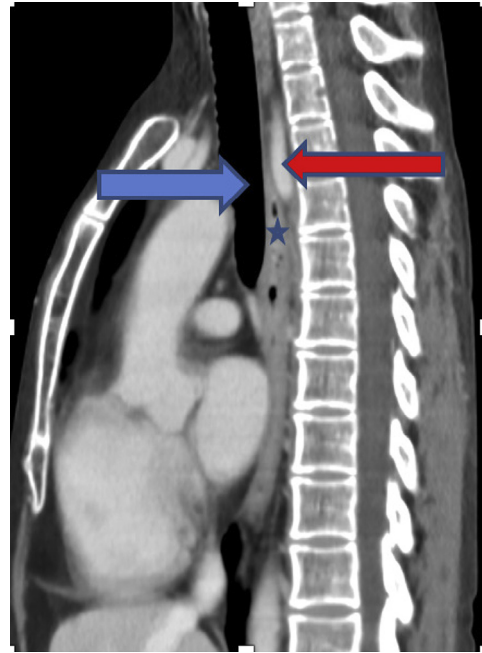
**Fig. 1** – Computed tomography (coronal reformation, maximum intensity projection) shows an aberrant right subclavian artery (arrow) that originates from the proximal portion of the descending aorta and crosses the central line behind the esophagus (star) to provide the right upper limb.

## Case report

Poorly differentiated squamous cell cancer of the thoracic esophagus was diagnosed in a 38-year-old female Caucasian patient. The preoperative staging showed an advanced tumor stage without distant metastases (cT3, cN+, and cM0) and a rare vascular anomaly of the right subclavian artery: the presence of an aberrant right subclavian artery (Fig. 1). A neoadjuvant radiochemotherapy (CROSS protocol: Carboplatin and paclitaxel for 5 weeks and concurrent radiotherapy; 41.4 Gy in 23 fractions) was performed because of the advanced clinical tumor stage. This treatment was followed by conventional Ivor-Lewis esophagectomy with extended 2-field lymphadenectomy and gastric pull-up with high intrathoracic anastomosis. The aberrant right subclavian artery was displayed intraoperatively (Fig. 2) and could be obtained. The pathologic staging revealed a ypT3, ypN0 (0/25), V0, L0, R0, G3 cancer. We discharged the patient on the 14th postoperative day without the occurrence of complication.

## Discussion

The aberrant right subclavian artery is one of the more common vascular anomalies affecting approximately 0.5%-2.5% of the population [1]. It is assumed that the aberrant right subclavian artery is formed as a result of complex transformations from vascular segments in the embryonic phase out of original 6 paired pharyngeal arch arteries [4]. In addition, when an aberrant right subclavian artery is present, there is a higher incidence of other anomalies (eg, bicarotid trunk, anomalies of the heart) [2]. Clinical symptoms (eg, chronic cough and dyspnea) tend to be rare. Regarding detection, a conventional biplanar x-ray of the thorax would not be specific or sensitive enough. However, as all patients with esophageal cancer

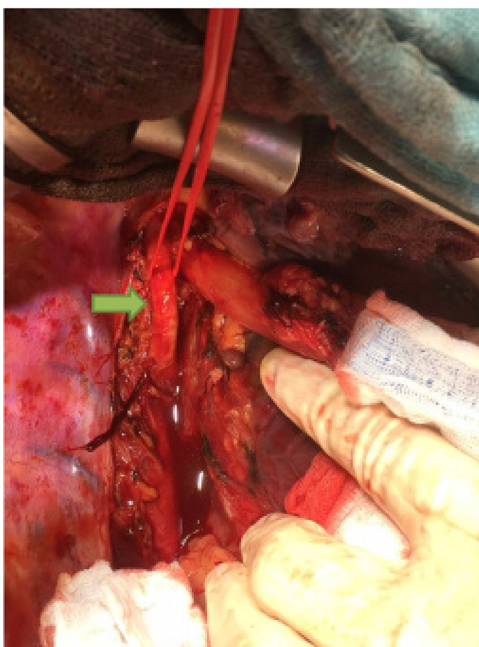


**Fig. 2** – CT (sagittal reformation) shows an aberrant right subclavian artery (red arrow) running behind the esophagus (star) and the trachea (blue arrow).

undergo a CT scan as staging, the radiologist should pay attention to rare vascular anomalies. Sectional images by means of an additional MRA might give a more precise information on the vascular anatomy and the topographic relationship with surrounding structures. However, no study has investigated the sensitivity and the specificity of these different technologies (CT and magnetic resonance imaging) so far [5]. Although only a few published cases are known, in which an aberrant right subclavian artery occurred simultaneously with a tumor in the esophagus, this vascular anomaly should be given special attention in esophageal surgery. If the anatomic structures are not taken into account properly, the arterial wall may accidentally be damaged during blunt transhiatal dissection, leading to uncontrolled bleeding. Therefore, a blunt dissection should rather be dispensed with when an aberrant right subclavian artery is detected. If, despite careful dissection, a lesion of the aberrant right subclavian artery occurs, conversion into open thoracotomy should be considered and further preparation should take place under visual monitoring. The subsequent formation of an arterial-esophageal fistula is another complication that may occur as a result of damage to the aberrant right subclavian artery and is reported in 2 cases in the literature [6]. In these 2 cases, the patient died as a consequence of this complication. If any complication arises regarding this anatomic variation, the survival of the patient depends on prompt diagnosis and therapy (Fig. 3).

## Conclusion

The aberrant right subclavian artery presents a potential risk factor in esophageal surgery when there is a simultaneous



**Fig. 3 – The aberrant right subclavian artery (arrow) intraoperatively.**

esophageal cancer, as a life-threatening complication may occur if the artery is injured. Transhiatal, blunt esophagectomy or thoracoscopic esophagectomy in patients with esophageal cancer and a simultaneous vascular anomaly should only be

performed at centers with corresponding experience. In this case, preoperative identification by a CT scan or an MRA is imperative, and precise representation and preparation of the aberrant right subclavian artery are needed intraoperatively.

#### REFERENCES

- [1] Edwards JE. Anomalies of the aortic arch system. *Birth Defects Orig Artic Ser.* 1977;13(3D):47–63.
- [2] Zapata H, Edwards JE, Titus JL. Aberrant right subclavian artery with left aortic arch: associated cardiac anomalies. *Pediatr Cardiol* 1993;14(3):159–61.
- [3] Pop D, Venissac N, Nadeemy AS, Schneck AS, Aze O, Mouroux J. Lesson to be learned: beware of lusoria artery during transhiatal esophagectomy. *Ann Thorac Surg* 2012;94(3):1010–1.
- [4] Congdon ED. Transformation of the aortic arch system during the development of the human embryo. *Contrib Embryol.* 1922;14(68):47–110.
- [5] Gomes AS, Lois JF, George B, Alpan G, Williams RG. Congenital abnormalities of the aortic arch: MR imaging. *Radiology* 1987;165(3):691–5.
- [6] Pantvaidya GH, Mistry RC, Ghanekar VR, Upasani VV, Pramesh CS. Injury of an aberrant subclavian artery: a rare complication of video assisted thoracoscopic esophagectomy. *Ann Thorac Cardiovasc Surg* 2005;11(1):35–7.