



Received: 2014.08.28
Accepted: 2014.11.27
Published: 2015.03.13

Authors' Contribution:

- A** Study Design
- B** Data Collection
- C** Statistical Analysis
- D** Data Interpretation
- E** Manuscript Preparation
- F** Literature Search
- G** Funds Collection

High-Intensity Focused Ultrasound (HIFU) in Localized Prostate Cancer Treatment

Mohammed Alkhorayef^{1ABCDEF}, Mustafa Z. Mahmoud^{2,3ABCDEF},
Khalid S. Alzimami^{1ABCDEF}, Abdelmoneim Sulieman^{2ABCDEF}, Maram A. Fagiri^{3ABCDEF}

¹ Department of Radiological Sciences, College of Applied Medical Sciences, King Saud University, Riyadh, Saudi Arabia

² Department of Radiology and Medical Imaging, College of Applied Medical Sciences, Salman bin Abdulaziz University, Al-Kharj, Saudi Arabia

³ Department of Basic Sciences, College of Medical Radiological Sciences, Sudan University of Science and Technology, Khartoum, Sudan

Author's address: Mustafa Z. Mahmoud, Radiology and Medical Imaging Department, Salman bin Abdulaziz University, PO Box 422, Al-Kharj 11942, Saudi Arabia, e-mail: m.alhassen@sau.edu.sa

Source of support: College of Applied Medical Sciences Research Center and the Deanship of Scientific Research at King Saud University

Summary

Background:

High-intensity focused ultrasound (HIFU) applies high-intensity focused ultrasound energy to locally heat and destroy diseased or damaged tissue through ablation. This study intended to review HIFU to explain the fundamentals of HIFU, evaluate the evidence concerning the role of HIFU in the treatment of prostate cancer (PC), review the technologies used to perform HIFU and the published clinical literature regarding the procedure as a primary treatment for PC.

Material/Methods:

Studies addressing HIFU in localized PC were identified in a search of internet scientific databases. The analysis of outcomes was limited to journal articles written in English and published between 2000 and 2013.

Results:

HIFU is a non-invasive approach that uses a precisely delivered ultrasound energy to achieve tumor cell necrosis without radiation or surgical excision. In current urological oncology, HIFU is used clinically in the treatment of PC. Clinical research on HIFU therapy for localized PC began in the 1990s, and the majority of PC patients were treated with the Ablatherm device.

Conclusions:

HIFU treatment for localized PC can be considered as an alternative minimally invasive therapeutic modality for patients who are not candidates for radical prostatectomy. Patients with lower pre-HIFU PSA level and favourable pathologic Gleason score seem to present better oncologic outcomes. Future advances in technology and safety will undoubtedly expand the HIFU role in this indication as more of patient series are published, with a longer follow-up period.

MeSH Keywords:

High-Intensity Focused Ultrasound Ablation • Magnetic Resonance Imaging • Interventional • Prostatic Neoplasms

PDF file:

<http://www.polradiol.com/abstract/index/idArt/892341>

Background

Prostate cancer (PC) is one of the most frequently diagnosed cancers in the male population in the world [1]. According to the American Cancer Society (ACS), PC represents 25% of newly diagnosed cancers every year [1]. In Europe, the mortality rate for PC was 21.1% in 2008 [2].

High-intensity focused ultrasound (HIFU) is a non-invasive therapy that was used for localized PC or salvage therapy in the 1990s. It is a technique that uses focused ultrasound waves to thermally ablate a portion of tissue situated at the focal point. High-power ultrasound can be focused on a targeted point to cause a rise in temperature between 70 and 80°C. This can result in thermal tissue

coagulation, necrosis, cavitation, and heat shock. Each sonication heats only a small focal target, so multiple sonications, raster scanner, volumetric focus steering or some other beam translation method must be utilized to ablate the entire target area [3]. The transrectal HIFU ablation is a minimally invasive treatment for PC that has been evaluated since the early 1990s [4–6]. It can be proposed either for patients with clinically localized PC who are not candidates for surgery or as salvage treatment of local recurrences of PC after external beam radiation therapy (EBRT) [7–10]. Five-year disease-free survival rates after HIFU ablation of clinically localized PC fall within the 66–78% range, which challenges the results of radiation therapy [7,11,12]. Although the knowledge that tissue destruction could be achieved with HIFU has been present since the 1930s. Efforts to clinically implement this technology were delayed due to the absence of imaging technology to monitor the procedure [13]. Some medical associations recommend HIFU for treatment of PC, but its accuracy is still not clear [14].

Basic research in the urological application of HIFU began in the 1980s, primarily in France and the USA, when computer technology became sufficient to facilitate the control and management of this fascinating energy source. The first clinical prototypes for use in urology emerged at that time. Early clinical trials of HIFU therapy for PC during the mid-late 1990s found a relationship between the coagulated prostate volume with HIFU and obstruction. Moreover, the analysis of prospective studies found a high rate of urinary tract infections in that necrotic tissue. As a result of the association between HIFU and obstruction, and consistent with the whole concept of therapy, HIFU has been routinely combined with adjuvant transurethral resection of the prostate (TURP) since 2000 to debulk tumor mass and to radically resect the middle lobes, calcifications, abscesses, and bladder neck [15–17].

Due to increased patients' interest and the current use of HIFU technology worldwide, this article reviewed HIFU to explain the fundamentals of HIFU and to evaluate the evidence concerning the role of HIFU in the treatment of PC as well as to review the technologies used to perform HIFU and the published clinical literature regarding the procedure as a primary treatment for PC.

Material and Methods

An inclusive literature review was carried out in order to review the scientific foundation of HIFU and it was discussed in terms of how it resulted in the development of two distinct devices. The merits and limitations of each of them are addressed. The PubMed, SAGE, MEDLINE and ScienceDirect databases were searched in January 2014 for publications containing any combination of HIFU and PC terms in the title of the report. Abstracts resulting from that search were reviewed for relevance to the clinical outcomes of the procedure.

Full manuscripts were retrieved and reviewed in search for information regarding evaluation of the evidence on the role of HIFU in the treatment of PC as well as the technologies used to perform HIFU and the published clinical

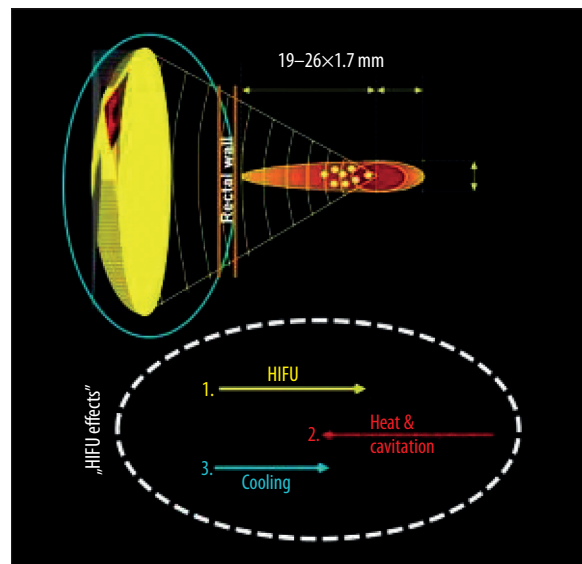


Figure 1. Physical principle of focused energy application [26].

literature on the procedure as a primary treatment for PC. Only the papers published between 2000 and 2013 were included in the outcome analysis.

There were no restrictions on the country of origin of the publications, which helped to provide a range of opinions and experiences. Articles identified in the refined search were further reviewed on an individual basis for content.

Results and Discussion

HIFU fundamentals

Around the beginning of the last century, the piezoelectricity phenomenon, the potential of piezoelectric materials as sources of ultrasound, and the biological effects of high-intensity ultrasound were all reported on [18–20]. A detailed chronicle of the early work and medical applications of therapeutic ultrasound was presented by Kremkau [21]. The specific properties of focused ultrasound conduction and modes of destruction in normal tissues were investigated further during the 1970s and 1980s, and studies using HIFU to irradiate experimental tumors followed [22–25]. The premise behind HIFU is the destruction of tissue by depositing large amounts of energy into it. This is accomplished by increasing the intensity of the waves and focusing the waves on a single point (Figure 1). If done in the right conditions, it will raise the temperature of tissue to a level sufficient to induce irreversible damage in a discrete volume of tissue [26,27].

The deposit of energy during HIFU can result in two mechanisms of tissue damage [28]. Elevation of tissue temperature leads to melting of lipid membranes and protein denaturation. This is the desired effect of HIFU. If large deposits of energy occur, mechanical damage may result in gas bubble formation and/or cavitation [29]. Gas can form inside tissue during HIFU as a result of several mechanisms [30].

The first mechanism is simply boiling that will occur if the temperature of the tissue is increased beyond the boiling

point of the liquids it contains. This will create air pockets that have the potential of reflecting the ultrasound signal and modify, in an uncontrollable way, the HIFU lesion [30]. The second mechanism is cavitation and can be either inertial or stable. During inertial cavitation, gas micro-bubbles form within tissue due to the negative pressure caused by HIFU. Upon the subsequent collapse due to the high pressure of the surrounding medium, the temperature and pressure inside the micro-bubble will increase rapidly. This can lead to the dissipation of the gas into the surrounding medium in the form of a shock wave [30].

Inertial cavitation is relatively unpredictable in terms of formation and dissipation of energy and is avoided during HIFU. Stable cavitation is the oscillation of existing micro-bubbles in the tissue and it is not associated with a violent collapse or dispersion of energy. Micro-bubble oscillations can result in sheering forces and viscous-damping heating. Although stable cavitation is currently avoided during the procedure, there is some experimental evidence that stable cavitation may be able to enhance tissue ablation during HIFU and is being further investigated [30].

A reproducible, but small volume of ablation is created for each pulse of energy during HIFU. The geometry of each ablation volume is an ellipsoid, and the size of the ellipsoid is a function of crystal geometry. Treatment of cancer of the prostate is accomplished by systematically pulsing energy throughout the target volume at different locations until the entire volume has been ablated [31].

HIFU experimental identification and essential clinical parameters

Computer simulation, *in vitro* and *in vivo* studies were conducted to identify and refine the ultrasound parameters required for the clinical treatment of prostatic disease. The destruction of PC with HIFU in these studies provided the evidence that prostate cancerous tissues can be destroyed by HIFU without inducing metastases, and that prostatic tissue can effectively be targeted through transrectal delivery of HIFU [4,32,33].

Essential clinical parameters for the medical use of HIFU include ultrasound frequency (MHz), acoustic intensity (Watts), duration of application (short time), intervals of the pulses (delay time), lateral distance between elementary lesions, longitudinal displacement of the energy source when applying multiple lesions, and penetration depth (focal point) dependent on the applicator design [13].

These multiple technical parameters are essential in the assembly of a HIFU system with a dedicated application for specific tissue. Complex technical decisions are involved in HIFU operation, and include the selection and design of the piezoelectric energy applicator, parameters of ultrasound treatment (MHz, Watts), application algorithm (impulse delay relation), imaging system, intraoperative target and safety features, target localization during treatment with transrectal ultrasound (TRUS) and controls [13].

Current standard urological applications use HIFU transducers with a fixed but adjustable focal point to be moved mechanically to treat a larger tissue volume [34,35].

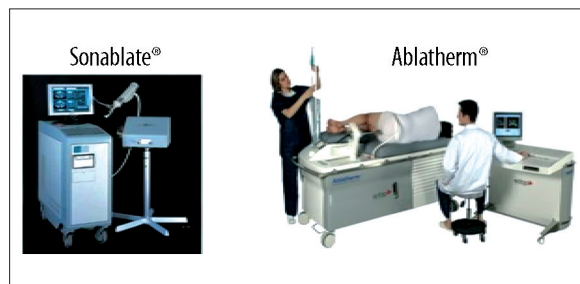


Figure 2. Commercially available transrectal HIFU devices: Ablatherm and Sonablate 500 [26].

Commercially available HIFU devices and treatment technologies

As of 2011, two transrectal HIFU devices were commercially available for the treatment of PC, the Ablatherm [Edap Technomed, Lyon, France] and the Sonablate 500 [Indianapolis, IN, USA] (Figure 2). Although neither of the devices has received Food and Drugs Administration (FDA) approval for marketing in the US, regulatory clearance is likely for the Ablatherm device when the results of a prospective trial become available [13,26].

Nevertheless, the foundation science and technology of both systems is identical, but there are several technological differences between the two devices. These differences, for the most part, arise from different schools of thought with regards to how best to design the optimal HIFU treatment system. Specifically, the differences arise in how the manufacturers went about choosing operating frequencies and intensities. This is an optimization based on the effects that modifying these parameters will have influence on image quality and ablation ability [13].

The Ablatherm machine consists of a treatment module that includes the patient's bed, probe positioning system, ultrasound power generator, cooling system for preservation of the rectal wall, and ultrasound scanner used during the treatment localization phase. There is also a treatment and imaging endorectal probe that incorporates both a biplanar imaging probe working at 7.5 MHz (Figure 3) and a treatment transducer focused at a maximum of 45 mm working at 3 MHz [26,36].

Numerous safety features have been incorporated, including a safety ring that stabilizes the rectal wall during transducer movements, a permanent control of the distance between the therapy transducer and the rectal wall, and a patient motion detector that stops treatment if the patient moves during the firing sequence [37]. HIFU is delivered as a single session therapy under spinal anesthesia for the duration of 2 to 3 hours. The treatment is conducted with the patient in the lateral position [37].

Unlike the Ablatherm machine, the Sonablate system has no dedicated bed. Several treatment probes are available, and are selected by the operator according to the size of the elementary lesion required, 10 mm in length and 2 mm in diameter for a single beam performing with 25-mm or 45-mm focal length probes, and 10 mm in length and 3 mm in diameter for a split beam performing with 30-mm, 35-mm, or 40-mm focal length probes [38].

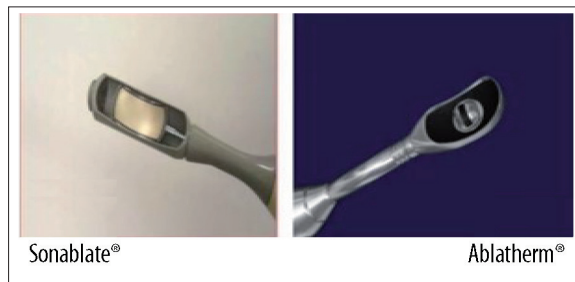


Figure 3. Different transrectal HIFU transducers for Sonablate 500 and Ablatherm [26].

Treatment parameters may also vary depending on the operator choice. Treatment is performed with patients in a dorsal position under general anesthesia. The probe (Figure 3) is chosen depending on prostate size, with larger glands requiring longer focal lengths. The treatment is usually conducted in three consecutive coronal layers, starting from the anterior part of the prostate and progressively moving to the posterior part, with at least one probe switch during the procedure [26,38].

Measurement of HIFU effects on PC tissues

Most patients treated with HIFU presented with localized cancer [36]. Usually HIFU is used as a standalone procedure with a 5-year disease-free survival rate (biochemical) by 77% for Ablatherm and 45–84% for Sonablate [39]. Best results after HIFU in terms of negative biopsies and low (prostatic specific antigen) PSA levels were achieved in patients with low-grade PC [39]. Based on The French Association of Urology (AFU) review, HIFU is the best short-term cancer control modality in terms of the rate of negative biopsies and decrease in PSA serum levels [40].

However, cautious optimism is recommended, as long-term results have not been provided yet. HIFU was delivered to regions of the prostate where biopsies had revealed cancer, and histological examination found a sharp demarcation between HIFU-treated and untreated areas, with complete necrosis in all specimens [41]. The treated areas appear as a non-enhancing hypointense zone surrounded by a peripheral rim of enhancement, 3 mm to 8 mm thick. These abnormalities correspond to a nucleus of coagulation necrosis surrounded by a peripheral zone of inflammation. Treatment-induced abnormalities visible with MRI usually disappear in 3 to 5 months in a centripetal manner, and HIFU-induced tissue contraction follows after about 6 months in small prostates of approximately 5cc [42].

Indications for HIFU therapy of PC

The most widespread use of HIFU, and initially the only indication for its use, has been in patients with localized PC who are not candidates for surgery because of age, general health status, a prohibiting comorbidity or a preference not to undergo radical prostatectomy [13]. However, with the accumulation of clinical experience and expansion of research protocols, these indications have broadened [10,43].

However, the indications have been expanded based on clinical experience to include partial and focal therapy

in unilateral low volume, low-Gleason tumors, incidental prostate cancer after trans-urethral resection (TUR), salvage therapy in recurrent prostate cancer after radical prostatectomy, radiotherapy, or hormone ablation, for locally advanced prostate cancer as adjuvant local tumor-debulking therapy, non-metastatic as well as metastatic stages, and hormone-resistant prostate cancer (HRPCa). It is well accepted that the gland can also be downsized by 30% within 3 months of androgen deprivation therapy (ADT), besides TURP. Still remaining contraindications for the HIFU device are a missing or a small rectum and a damaged rectal wall, caused by previous prostatic/rectal therapies [44].

Efficacy of HIFU for PC therapy

There is no universal consensus on the definition of biochemical failure in patients treated with HIFU [13]. The lowest negative biopsy rate was reported for patients treated with prototype devices [45]. Another series of negative biopsy rate of less than 80% included patients with a high risk PC [46,47]. In a more recent series, negative biopsy rates have ranged from 93%-96% [42,47]. Stricter criteria for treatment failure were applied when failure was defined as any positive biopsy or three successive elevations in PSA with a velocity ≥ 0.75 ng/mL/year [48].

Retreatment rates have also been reported in the literature, but their interpretation is confounded by the former practice of using two treatment sessions with only one prostatic lobe treated in each session. This approach was common in the studies of Poissonnier et al., and Gelet et al., but the only series that did not use that approach was a study involving high-risk patients reported by Ficarra et al. [7,45,49].

Ablatherm HIFU for PC primary therapy

The authors identified 11 case series assessing Ablatherm HIFU as a primary therapy option in prostate cancer (Table 1), which were conducted by four study groups in Germany, France, and the Republic of Korea [50–56]. Between 58 and 402 patients with localized prostate cancer (T1–T2, N0–Nx, M0) with a mean age of 66–72 years were treated with HIFU. In 4 of 11 case series, patients were recruited consecutively [7,11,45,55]. The mean preoperative PSA level was 7–12 ng/mL, Gleason score was ≤ 7 in most patients, and the mean preoperative prostate volume was 21–37 mL. Between 0% and 43% of men received neoadjuvant ADT, and 65–100% of patients underwent TURP before or in combination with HIFU. Patients received between one and three HIFU treatments; most patients, i.e. 57–96%, underwent one treatment. The mean follow-up period varied between 6 and 77 months. The biochemical disease-free survival rate was 66% and 77% after 5 years [7,50], and 69% after 7 years [50]. The negative biopsy rate was assessed in all but one study and varied between 65% and 94% [7,45,50–56]; the time of biopsy was not specified. In one case series the negative biopsy rate was 86% at 3 months [56].

The evidence concerning the patient-relevant outcomes, overall survival, and prostate cancer-specific survival

Table 1. Eleven case series assessing Ablatherm HIFU as a primary therapy option in prostate cancer.

Ablatherm HIFU for PC primary therapy in 11 case series conducted by four study groups in Germany, France, and the Republic of Korea [50–56]	
Number of treated cases	Between 58 and 402 patients [7,11,45,55]
Prostate cancer stage	T1–T2, N0–Nx, M0 [7,11,45,55]
Mean age (years)	66–72 years [7,11,45,55]
Mean preoperative PSA level (ng/mL)	7–12 ng/mL [7,11,45,55]
Gleason score	≤7 [7,11,45,55]
Mean preoperative prostate volume (ml)	Between 21 and 37 mL [7,11,45,55]
Patients who received neo-adjuvant ADT (%)	Between 0% and 43% [7,11,45,55]
TURP before or in combination with HIFU (%)	Between 65% and 100% [7,11,45,55]
Mean follow-up period (months)	Between 6 and 77 months [7,11,45,55]
Biochemical disease-free survival rate (years)	66% and 77% after 5 years [7,50] 69% after 7 years [50]
Negative biopsy rate (%)	Between 65% and 94% [7,11,15,45,50–52,54–56] About 86% at 3 months [56]
Adverse events (urinary tract)	Bladder neck/urethral stenosis/stricture (2–17%) [7,11,15,45,51,55] Prolonged urinary retention (3–14%) [7,11,15,45,51,55] Urinary tract infection (2–58%) [7,11,15,45,51,55] Urinary incontinence (2–34%) [7,11,15,45,51,55]
Adverse events (rectum)	Rectal burns (0–15%) [7,11,15,45,51,55] Recto urethral fistula (0–3%) [7,11,15,45,51,55]

is scarce because these factors were only assessed in one case series [50]. Adverse events of the urinary tract included bladder neck/urethral stenosis/stricture (2–17%), prolonged urinary retention (3–14%), urinary tract infection (2–58%), and urinary incontinence (2–34%). Adverse events of the rectum included rectal burn (0–15%) as well as recto-urethral fistula (0–3%). In six case series, outcomes in terms of quality of life were assessed using self-administered questionnaires that yielded either little differences from pre- to post-HIFU treatment, or controversial results [7,11,15,45,51,55].

Ablatherm HIFU for PC salvage therapy

Ablatherm HIFU as a salvage therapy option in recurrent prostate cancer after EBRT failure was assessed in three case series (Table 2), all of which were published from one study center in France [56–58]. Between 71 and 82 patients were treated with HIFU following recurrence of prostate cancer after EBRT [57,58]. In one case series patients were recruited consecutively [57]. The mean patient age was 67–71 years; mean preoperative PSA level was 8 ng/mL, Gleason score was ≤8 in most patients, and preoperative prostate volume was between 21 and 35 mL. Neoadjuvant ADT was administered to between 9% and 30% of men. Patients were treated with HIFU, one (41%) to five (1%) times and were followed up for a mean of 15–18 months. The negative biopsy rate was 80% at 15 months in one trial

[56] and between 78% and 80% in the remaining studies; the time of biopsy was not shown [57,58].

Evidence concerning patient-relevant outcomes is limited to adverse events concerning the urinary tract, such as bladder neck/urethral stricture/stenosis (17%), prolonged urinary retention (6%), urinary tract infection (1–6%), urinary incontinence (7–35%), as well as potency, adverse events within the rectum, and pain. One case series assessed the quality of life by self-administered questionnaires, but data were not presented [57].

Sonablate HIFU for PC primary therapy

Authors retrieved seven case series assessing Sonablate HIFU as a primary therapy option in prostate cancer (Table 3) that were carried out by three study groups in the United Kingdom, Italy, and Japan [59–64]. Between 63 and 517 patients were treated with Sonablate HIFU who were recruited consecutively in four case series [60,62–64]. Both localized (T1–T2, N0, M0) as well as locally advanced (T3, N0, M0) prostate cancers were treated using the Sonablate device. Median patient age, reported in all but one study, was between 68 and 72 years [60–64].

The remaining study reported a mean age of 64 years [59]. The median PSA level was 5–10 ng/mL in six studies [60–64]; mean PSA was given in one study and amounted

Table 2. Three case series assessing Ablatherm HIFU as a salvage therapy option in recurrent prostate cancer.

Ablatherm HIFU as a salvage therapy option in recurrent prostate cancer in 3 case series conducted in one study center in France [56–58]	
Number of treated cases	Between 71 and 82 patients [57,58]
Mean age (years)	67–71 years [57,58]
Mean preoperative PSA level (ng/mL)	8 ng/mL [57,58]
Gleason score	≤8 [57,58]
Mean preoperative prostate volume (mL)	Between 21 and 35 mL [57,58]
Patients who received neo-adjuvant ADT (%)	Between 9% and 30% [57,58]
HIFU following recurrence of prostate cancer after EBRT	Between 71 and 82 patients [57,58]
Mean follow-up period (months)	Between 15 and 18 months [57,58]
Negative biopsy rate (%)	80% at 15 months [56] Between 78% and 80% at 15 months [57,58]
Adverse events (urinary tract)	Bladder neck/urethral stricture/stenosis (17%) [57]
	Prolonged urinary retention (6%) [57]
	Urinary tract infection (1–6%) [57]
Adverse events (potency)	Urinary incontinence (7–35%) [57]
	Impotence/erectile dysfunction in only one trial [57]
Adverse events (rectum)	Rectourethral fistula [57]

to 8 ng/mL [59]. Gleason score was ≤7 in most patients, and median preoperative prostate volume was 22–33 mL; between 29% and 66% of men received neoadjuvant ADT. TURP was either not carried out or no information was provided. Patients received one to four HIFU treatments, but most (79–86%) were treated once. A median follow-up was between 14 and 34 months [60–64]; mean follow-up of 12 months was reported in one study [59]. The biochemical disease-free survival rate was given in six case series and varied between 78% and 84% at 1 year, 0–91% at 2 years, 20–86% at 3 years, and 45–84% at 5 years [60–64]. The negative biopsy rate was assessed in five studies [60–64], but the time of biopsy was only presented in three of them [60–62]. The negative biopsy rate was 19–89% at 6 months and 77%–84% at 12 months [60–62].

There is a lack of evidence concerning overall survival and prostate cancer-specific survival. The reported adverse events included urinary tract with bladder neck/urethral stricture/stenosis (4–30%), prolonged urinary retention (1–13%), urinary tract infection (4–24%), and urinary incontinence (1–2%). Impotence/erectile dysfunction and retrograde ejaculation occurred in 20–39% and 1–20% of men, respectively. All case series assessed the quality of life by self-administered questionnaires. However, the results were only presented in four of the seven trials [59–62].

Sonablate HIFU for PC salvage therapy

Until the advent of HIFU, when a patient had persistent or recurrent prostate cancer after radical radiation treatment,

the only other treatment options were salvage prostatectomy or hormone therapy. It appears that HIFU may provide a noninvasive, safe, and effective salvage treatment in this very-difficult-to-treat population [65].

After searching databases mentioned in the material and methods part of this study, the authors found only one review of 31 cases treated with the Sonablate 500 HIFU device (Table 4). That review was carried out in the United Kingdom between 1 February 2005 and 15 May 2007. All men had a presumed organ-confined, histologically confirmed, recurrent prostate adenocarcinoma following EBRT. The mean (range) age was 65 (57–80) years with a mean preoperative PSA level of 7.73 ng/mL. The patients were followed up for a mean (range) of 7.4 (3–24) months. Side-effects included stricture or intervention for necrotic tissue in 11 of the 31 patients (36%), urinary tract infection or dysuria syndrome in eight (26%), and urinary incontinence in two (7%). Recto-urethral fistula occurred in two men, although one was due to patient movement due to inadequate anaesthesia, so the 'true' rate was 3%. Half of the patients had PSA levels of <0.2 ng/mL at the last follow-up. Three patients had metastatic disease whilst another two had only local, histologically confirmed, failure. Another four patients had evidence of biochemical failure only. Overall, 71% had no evidence of a disease following salvage HIFU. Salvage HIFU is a minimally invasive daycase procedure that can achieve low PSA nadirs and better cancer control in the short term, with comparable morbidity to other forms of salvage treatment. The issue of accurate staging at the time of recurrence is still problematic, as a

Table 3. Seven case series assessing Sonablate HIFU as a primary therapy option in prostate cancer.

Sonablate HIFU for PC primary therapy in 7 case series carried out by three study groups in the United Kingdom, Italy, and Japan [59–64]	
Number of treated cases	Between 63 and 517 patients [60,62–64]
Prostate cancer stage	T1–T2, N0, M0 [60–64]
	Locally advanced T3, N0, M0 [60–64]
Mean age (years)	Between 68 and 72 years [60–64]
	64 years [59]
Mean preoperative PSA level (ng/mL)	5–10 ng/mL [60–64]
	8 ng/mL [59]
Gleason score	≤7 [59–64]
Mean preoperative prostate volume (mL)	22–33 mL [59–64]
Patients who received neo-adjuvant ADT (%)	Between 29% and 66% [59–64]
TURP (%)	Not carried out/No information [59–64]
HIFU sessions (%)	79–86% were treated once [59–64]
Mean follow-up period (months)	Between 14 and 34 months [60–64]
	12 months [59]
Biochemical disease-free survival rate (years)	Between 78% and 84% at 1 year, 0–91% at 2 years, 20–86% at 3 years, and 45–84% at 5 years [60–64]
Negative biopsy rate (%)	19–89% at 6 months and 77–84% at 12 months [60–62]
Adverse events (urinary tract)	Bladder neck/urethral stricture/stenosis (4–30%) [59–62]
	Prolonged urinary retention (1–13%) [59–62]
	Urinary tract infection (4–24%) [59–62]
Adverse events (potency)	Urinary incontinence (1–2%) [59–62]
	Impotence/erectile dysfunction (20–39%) [59–62]
	Retrograde ejaculation (1–20%) [59–62]

proportion of these men will harbour microscopic metastases undetected by conventional staging investigations [66].

HIFU in focal treatment of PC

The overtreatment of prostate cancer is recognized and the need for less-aggressive minimally sufficient treatment options is paramount [67,68]. Focal therapy for prostate cancer is in the same vein as the progress that has been made for the treatment of breast cancer, where lumpectomy is suggested as a first-line treatment of patients with lesions of limited size. The primary idea of carrying out focal therapy goes back to Onik et al., who were the first to use cryoablation for prostate lumpectomy [69]. That concept paper was followed by the first outcomes of focal cryoablation in 2007 [70–72] and a report on focal ablation with HIFU [73]. Bahn et al. followed up 31 men treated with hemispherical cryoablation using the stage as the primary selection criterion (26.6% of men had a Gleason

score of 7 and 9.7% had a PSA >10 ng/mL) [70]. With a median follow-up of 70 months, 92.8% of men had a stable PSA – according to the American Society for Therapeutic Radiology and Oncology (ASTRO) definition – and 96% had negative biopsies [70]. In the Ellis et al. series, 60 patients were selected (Table 5) for hemispherical cryoablation via a 12-core biopsy [72]. The average follow-up was 15 months and the biological progression-free survival rate was 80.4%, the incontinence rate was 3.6%, and erectile function was preserved in 70.6% of patients. It should be noted that 33% of patients included in that series were at intermediate risk or higher [72]. In the Onik et al. series (55 patients with a follow-up of more than 1 year), a stable PSA level was obtained in 95% of the patients and sexual function (Table 5) was preserved in 86% of the patients [71]. Not all patients in those two series were reevaluated with biopsy after focal treatment; the rate of negative biopsies is therefore subject to caution as compared to 100% in the Onik et al. series, and 77% in the Ellis et al. series [71,72].

Table 4. Thirty-one case series using the Sonablate 500 HIFU device as a salvage therapy option in recurrent prostate cancer.

Sonablate 500 HIFU device as a salvage therapy option in recurrent prostate cancer in 31 case series conducted in two centers in the United Kingdom [66]	
Number of treated cases	31 patients [66]
Prostate cancer stage	≤T3B, N0, M0 [66]
Mean age (years)	57–80 years [66]
Mean preoperative PSA level (ng/mL)	7.73 ng/mL [66]
Gleason score	≤6 in 16.1% of patients [66]
	7 in 54.9% of patients [66]
	≥8 in 16.1% of patients [66]
	Unknown in 12.9% of patients [66]
Mean preoperative prostate volume (mL)	No information [66]
Patients who received hormone therapy (%)	58% [66]
HIFU following recurrence of prostate cancer after EBRT	31 patients [66]
Mean follow-up period (months)	3–24 months [66]
Negative biopsy rate (%)	71% at 24 months [66]
Adverse events (urinary tract)	Stricture or intervention for necrotic tissue (36%) [66]
	Urinary tract infection or dysuria syndrome (26%) [66]
	Urinary incontinence (7%) [66]
Adverse events (potency)	Epididymitis (3%) [66]
Adverse events (rectum)	Rectourethral fistula (3%) [66]
	Prostrectal fistula (7%) [66]

Table 5. HIFU in focal treatment of PC.

Study	Number of patients	Median follow-up (months)	Negative biopsy rate (%)	Adverse effects in urinary tract (%)	Adverse effects concerning potency (%)
Bahn et al. [70]	31	70	96%	Urinary incontinence (0%)	11.1%
Onik et al. [71]	55	>12	100%	Urinary incontinence (0%)	14%
Ellis et al. [72]	60	15	77%	Urinary incontinence (3.6%)	29.4%
Muto et al. [73]	29	12	76.5%	Urethral stricture (8.6%)	0%
				Urinary tract infection (11.4%)	
Poissonnier et al. [7]	227	3	86%	Urinary incontinence (13%)	Data were incomplete (only 30% of subjects completed questionnaires)
				Urethral stricture (12%)	
Uchida et al. [67]	63	36	82%	Urethral strictures (24%)	13%

In the Muto et al. article, 29 patients underwent focal HIFU (Table 5) with a biochemical progression-free survival rate at 2 years of 83.3% for patients at low risk (TA–T2A, and Gleason score of 6, and PSA <10 ng/mL) and of 53.6% for patients at intermediate risk (T2B or Gleason

score of 7 or PSA >10 ng/mL). The rate of negative biopsies was 76.5% at 12 months in 17 patients who were rebiopsied [73]. It should be noted that the focal treatment in that series included the entire peripheral zone of the two prostate lobes and the transitional area of the diseased lobe (in

the end, only the transitional area of the lobe presumed to be healthy was saved) [73].

Early results with HIFU in focal treatment of PC appear encouraging in the context of study limitations for properly selected patients with clinically organ-confined disease. Since the overall experience is limited and follow-up is immature, long-term cancer control rates and more comprehensive analyses of treatment morbidity are necessary before advocating for the more widespread use of HIFU. Because HIFU has been used predominantly as a whole-gland therapy, additional experience will determine whether it can be successfully applied to focal lesions [74]. HIFU in focal treatment of PC capitalizes on the coagulation necrosis that occurs at temperatures higher than 60°C. Ultrasound energy is tightly focused, absorbed and converted to heat, resulting in a sharp delineation between the ablated and undamaged tissue. Accordingly, hundreds of cycles are often required for complete treatment. The size and location of the ablated area are modifiable based on the focusing system, ultrasound frequency, and the duration and absorption coefficient of the tissue. One of two systems is typically used, the Ablatherm or Sonablate [74].

Poissonnier et al. used Ablatherm to treat the prostate (Table 5) in 227 patients with clinical stages T1–T2 of prostate cancer, from 1994 to 2003 [80]. Because of their early experience with post-treatment voiding symptoms, more recent patients have undergone TURP and HIFU concomitantly. A mean number of cycles per session was 419 and mean follow-up was 27 months. While 86% of patients had a negative sextant biopsy at 3 months following treatment, 31% of men received neoadjuvant hormonal deprivation. Disease persistence requiring retreatment occurred in 43% of patients, incontinence in 13%, and urethral stricture in 12%. Erectile function data were incomplete as only 30% of subjects completed questionnaires [7]. Similarly, Uchida et al., treated the whole prostate in 63 patients (Table 5) with clinical stage T1–T2 of prostate cancer, using the Sonablate device [67]. Median operative time was 149 minutes, biopsies were taken 6 months after the procedure, and biochemical recurrence was defined as 3 consecutive PSA increases. A 3-year biochemical-free survival rate for men with pretreatment PSA of less than 10 ng/mL was 82%. Urethral strictures occurred in 24% of patients [67].

Future perspectives of HIFU for cancer treatment

HIFU is a non-invasive method of destroying a target tissue without skin incision whilst sparing adjacent tissues and organs, using real-time imaging guidance and control. The HIFU treatment involves relatively little pain and can be carried out with conscious sedation and on an outpatient basis. Such a technology provides a personalized treatment, adjusted to the individual patient anatomy, pathology and treatment response. The combination of Magnetic Resonance Imaging (MRI) and Focused Ultrasound (FUS), known as “MRgFUS”, provides an ability to plan and monitor treatment in near real time, with MRgFUS further increasing the safety profile of FUS due to real-time

temperature mapping [75]. Combined strategies have been recently addressed, in order to match the advantages of both imaging modalities [76]. Moreover, MRgFUS allows for achieving a higher degree of accuracy in ablation of the affected tissue [77–79]. In particular, MRI has the unique ability to monitor temperature and cavitation level in real time [80–82].

Another exciting opportunity for HIFU application in cancer therapy is its combination with pharmacological agents, particularly with modulators of apoptosis such as bortezomib. Bortezomib is boronic acid inhibitor for selective suppression of chymotryptic threonine protease activity. When administered alone or in combination with chemotherapy or radiation, bortezomib demonstrated anti-tumor activity (sensitizing the cancer cells to apoptosis) [5]. Poff et al. showed that pulsed HIFU could be exploited for tumor growth inhibition and induction of apoptosis in combination with anti-cancer drugs (bortezomib) [83].

Opposite to thermal induction, the mechanical impact from HIFU might be considered as an alternative for eliciting apoptosis. In a recent study, researchers exploited MR-guided HIFU for inducing apoptosis, where moderate acoustic power was applied (5 Watt acoustic power, 5 Hz frequency; 0.1 duty cycle) [84].

The data of a microscopic examination revealed an absence of thermal damage or destruction of tissues, while the apoptotic index achieved its peak (after 24 hours) compared to the control group. Finally, HIFU-induced apoptosis or HIFU-enhanced apoptosis induction will open more avenues for a novel non-invasive therapeutic approach of cancer treatment [84].

Conclusions

HIFU treatment for localized PC can be considered as an alternative minimally-invasive therapeutic modality for patients who are not candidates for radical prostatectomy, especially in the cases at low or moderate risk. Patients with lower pre-HIFU PSA level and favourable pathologic Gleason score seem to present better oncological outcomes. Salvage HIFU is a curative treatment option for a local relapse after EBRT with acceptable morbidity, but careful patient selection is imperative depending upon the prognostic factors. In addition, the efficacy and safety of HIFU as primary therapy should be further evaluated in randomized controlled trials comparing it with other minimally-invasive therapies and watchful waiting. Future advances in technology and safety will undoubtedly expand the HIFU role in this indication as more patient series are published with longer-term follow-up.

Acknowledgements

The authors extend their appreciation to the College of Applied Medical Science Research Center and the Deanship of Scientific Research at King Saud University for funding this research.

References:

- American Cancer Society: Prostate cancer facts. In: Cancer facts and figures 2009. Atlanta, GA: American Cancer Society, 2009; 19–20
- European Cancer Observatory. Cancer Fact Sheets. Available at: <http://eu-cancer.iarc.fr/2-cancer-factsheets.html,en>. Accessed December 21, 2013
- Jolesz FA: MRI guided focused ultrasound surgery. *Annu Rev Med*, 2009; 60: 417–30
- Gelet A, Chapelon JY, Margonari J et al: Prostatic tissue destruction by high intensity focused ultrasound: experimentation on canine prostate. *J Endourol*, 1993; 7: 249–53
- Gelet A, Chapelon JY, Margonari J et al: High intensity focused ultrasound experimentation on human benign prostatic hypertrophy. *Eur Urol*, 1993; 23: 44–47
- Chapelon JY, Margonari J, Vernier F et al: *In vivo* effects of high intensity ultrasound on prostatic adenocarcinoma dunning R3327. *Cancer Res*, 1992; 52: 6353–57
- Poissonnier L, Chapelon JY, Rouviere O et al: Control of prostate cancer by transrectal HIFU in 227 patients. *Eur Urol*, 2007; 51: 381–87
- Chaussy C, Thuroff S, Rebillard X et al: Technology insight: high intensity focused ultrasound for urologic cancers. *Nat Clin Pract Urol*, 2005; 2: 191–98
- Murat FJ, Poissonnier L, Rabilloud M et al: Midterm results demonstrate salvage high intensity focused ultrasound (HIFU) as an effective and acceptably morbid salvage treatment option for locally radio recurrent prostate cancer. *Eur Urol*, 2009; 55: 640–57
- Gelet A, Chapelon JY, Poissonnier L et al: Local recurrence of prostate cancer after external beam radiotherapy: early experience of salvage therapy using high intensity focused ultrasonography. *Urology*, 2004; 63: 625–29
- Blana A, Walter B, Rogenhofer S et al: High-intensity focused ultrasound for the treatment of localized prostate cancer: 5-year experience. *Urology*, 2004; 63: 297–300
- Uchida T, Ohkusa H, Yamashita H et al: Five years experience of transrectal high-intensity focused ultrasound using the sonablate device in the treatment of localized prostate cancer. *Int J Urol*, 2006; 13: 228–33
- Chaussy CG: Ultrasonidos de alta intensidad focalizados (HIFU) para el tratamiento local del cáncer de próstata: papel actual. *Archivos Españoles de Urología*, 2011; 64: 493–96 [in Spanish]
- Heidenreich A, Bolla M, Joniau S et al: Guidelines on prostate cancer. Available at: <http://www.uroweb.org/guidelines/online-guidelines/>. Accessed January 18, 2013
- Chaussy CH, Thuroff S: The status of high intensity focused ultrasound in the treatment of localized prostate cancer and the impact of a combined resection. *Curr Urol Rep*, 2003; 4: 248–52
- Chaussy C, Thuroff S: Results and side effects of high intensity focused ultrasound in localized prostate cancer. *J Endourol*, 2001; 15: 437–48
- Chaussy CH, Thuroff S: The use of high intensity focused ultrasound in prostate cancer. In: Ukimura O, Gill IS (ed.), *Contemporary interventional ultrasonography in urology*. Springer. London. 2009; 63–74
- Curie PJ, Curie P: Crystal physics: Development by pressure of polar electricity in hemihedral crystals with inclined faces. *Comptes Rendus Hebdomadaires des Séances de l'Académie des Sciences*. Paris 1880; 91: 294. Reprinted in Lindsay RB (ed.), *Acoustics: Historical and philosophical development*. Stroudsburg: Dowden, Hutchinson, & Ross, 1973; 373
- Biquard P: Paul Langevin. *Ultrasonics*, 1972; 10: 213–14
- Mahmoud MZ, Alkhorayef M, Alzimami KS et al: High-Intensity Focused Ultrasound (HIFU) in Uterine Fibroid Treatment: Review Study. *Pol J Radiol*, 2015; 80: 384–90
- Kremkau FW: Cancer therapy with ultrasound: a historical review. *J Clin Ultrasound*, 1979; 7: 287–300
- Bamber JC, Hill CR: Ultrasonic attenuation and propagation speed in mammalian tissues as a function of temperature. *Ultrasound Med Biol*, 1979; 5: 149–57
- Linke CA, Carstensen EL, Frizzell LA et al: Localized tissue destruction by high-intensity focused ultrasound. *Arch Surg*, 1973; 107: 887–91
- Frizzell LA: Threshold dosages for damage to mammalian liver by high-intensity focused ultrasound. *IEEE Trans Ultrason Ferroelect Freq Control*, 1988; 35: 578–81
- Goss SA, Fry FJ: The effects of high-intensity ultrasonic irradiation on tumour growth. *IEEE Trans Sonics Ultrasonics*, 1984; SU-31: 491–96
- Chaussy C, Tilki D, Thuroff S: Transrectal high-intensity focused ultrasound for the treatment of localized prostate cancer: current role. *J Cancer Ther*, 2013; 4: 59–73
- Linke CA, Carstensen EL, Frizzell LA et al: Localized tissue destruction by high intensity focused ultrasound. *Arch Surg*, 1973; 107: 887–91
- Hill CR, ter Haar GR: Review article: high intensity focused ultrasound – potential for cancer treatment. *Br J Radiol*, 1995; 68: 1296–303
- Barnett SB, ter Haar GR, Ziskin MC et al: Current status of research on biophysical effects of ultrasound. *Ultrasound Med Biol*, 1994; 20: 205–18
- Curiel L, Chavrier F, Gignoux B et al: Experimental evaluation of lesion prediction modelling in the presence of cavitation bubbles: intended for high intensity focused ultrasound prostate treatment. *Med Biol Eng Comput*, 2004; 42: 44–54
- Foster RS, Bihrlé R, Sanghvi NT et al: High intensity focused ultrasound in the treatment of prostatic disease. *Eur Urol*, 1993; 23: 29–33
- Oosterhof GO, Cornel EB, Smits GA et al: Influence of high intensity focused ultrasound on the development of metastases. *Eur Urol*, 1997; 32: 91–95
- Foster RS, Bihrlé R, Sanghvi N et al: Production of prostatic lesions in canines using transrectally administered high intensity focused ultrasound. *Eur Urol*, 1993; 23: 330–36
- Curiel L, Chavrier F, Souchon R et al: 1.5-D high intensity focused ultrasound array for non-invasive prostate cancer surgery. *IEEE Trans Ultrason Ferroelect Freq Control*, 2002; 49(2): 231–42
- Tan JS, Frizzell LA, Sanghvi NT et al: Design of focused ultrasound phased arrays for prostate treatment. *IEEE Ultrasonics Symposium*, 2000; 2: 1247–51
- Lukka H, Waldron T, Chin J et al: High intensity focused ultrasound for prostate cancer: a systematic review. *Clin Oncol (R Coll Radiol)*, 2011; 23: 117–27
- Chaussy CG, Thuroff S: Robot assisted high intensity focused ultrasound in focal therapy of prostate cancer. *J Endourol*, 2010; 24: 843–47
- SonaCare Medical. Misonix/US HIFU, “HIFU with the Sonablate 500. Available at: <http://www.ushifu.com/>. Accessed November 17, 2013
- Warmuth M, Johansson T, Mad P: Systematic review of the efficacy and safety of high intensity focused ultrasound for the primary and salvage treatment of prostate cancer. *Eur Urol*, 2010; 58: 803–15
- Blana A, Rogenhofer S, Ganzer R et al: Eight years’ experience with high intensity focused ultrasonography for treatment of localized prostate cancer. *Urology*, 2008; 72: 1329–33
- Beerlage HP, van Leenders GJ, Oosterhof GO et al: High Intensity focused ultrasound (HIFU) followed after one to two weeks by radical retro pubic prostatectomy: results of a prospective study. *Prostate*, 1999; 39: 41–46
- Rouviere O, Lyonnet D, Raudrant A et al: MRI appearance of prostate following transrectal HIFU ablation of localized cancer. *Eur Urol*, 2001; 40: 265–74
- Chaussy C, Thuroff S: Complete remission in metastatic prostate cancer after combined local and systemic therapy. *Urology*, 2006; 68: 197–98
- Vyacheslav S, Leonid S, Mikhail V, Ravil K: High-Intensity Focused Ultrasound (HIFU) For the Prostate Cancer: 5-year Experience. *International Journal of Tumor Therapy*, 2012; 1: 20–25
- Gelet A, Chapelon JY, Bouvier R et al: Transrectal high intensity focused ultrasound for the treatment of localized prostate cancer: factors influencing the outcome. *Eur Urol*, 2001; 40: 124–29
- Poissonnier L, Gelet A, Chapelon JY et al: Results of transrectal focused ultrasound for the treatment of localized prostate cancer (120 Patients with PSA < or +10 ng/ml). *Prog Urol*, 2003; 13: 60–72

47. Blana A, Murat FJ, Walter B et al: First analysis of the long term results with transrectal HIFU in patients with localised prostate cancer. *Eur Urol*, 2008; 53: 1194–201
48. Gelet A, Chapelon JY, Bouvier R et al: Transrectal high intensity focused ultrasound: minimally invasive therapy of localized prostate cancer. *J Endourol*, 2000; 14: 519–28
49. Ficarra V, Antonioli SZ, Novara G et al: Short term outcome after high intensity focused ultrasound in the treatment of patients with high risk prostate cancer. *BJU Int*, 2006; 98: 1193–98
50. Blana A, Murat FJ, Walter B et al: First analysis of the long-term results with transrectal HIFU in patients with localised prostate cancer. *Eur Urol*, 2008; 53: 1194–203
51. Chaussy C, Thuüroff S, Chaussy C, Thuüroff S: Results and side effects of high-intensity focused ultrasound in localized prostate cancer. *J Endourol*, 2001; 15: 437–40
52. Chaussy CG, Thuüroff S, Chaussy CG, Thuüroff S: High-intensive focused ultrasound in localized prostate cancer. *J Endourol*, 2000; 14: 293–99
53. Lee HM, Hong JH, Choi HY et al: High intensity focused ultrasound therapy for clinically localized prostate cancer. *Prostate Cancer Prostatic Dis*, 2006; 9: 439–43
54. Thuüroff S, Chaussy C, Vallancien G et al: High-intensity focused ultrasound and localized prostate cancer: efficacy results from the European multicentric study. *J Endourol*, 2003; 17: 673–77
55. Walter B, Rogenhofer S, Wieland WF, Blana A: Combination from TUR-P and high-intensity focused ultrasound (HIFU) for the treatment of localized prostate cancer – experience with 70 patients. *J Urologie Urogynakologie*, 2004; 11: 5–10
56. Colombel M, Poissonnier L, Martin X, Gelet A: Clinical results of the prostate HIFU project. *Eur Urol Suppl*, 2006; 5: 491–94
57. Gelet A, Chapelon JY, Bouvier R et al: Transrectal high-intensity focused ultrasound: minimally invasive therapy of localized prostate cancer. *J Endourol*, 2000; 14: 519–28
58. Gelet A, Chapelon JY, Poissonnier L et al: Local recurrence of prostate cancer after external beam radiotherapy: early experience of salvage therapy using high-intensity focused ultrasonography. *Urology*, 2004; 63: 625–29
59. Ahmed HU, Zacharakis E, Dudderidge T et al: High-intensity focused ultrasound in the treatment of primary prostate cancer: the first UK series. *Br J Cancer*, 2009; 101: 19–26
60. Mearini L, D'Urso L, Collura D et al: Visually directed transrectal high intensity focused ultrasound for the treatment of prostate cancer: a preliminary report on the Italian experience. *J Urol*, 2009; 181: 105–11
61. Muto S, Yoshii T, Saito K et al: Focal therapy with high-intensity focused ultrasound in the treatment of localized prostate cancer. *Jpn J Clin Oncol*, 2008; 38: 192–99
62. Uchida T, Baba S, Irie A et al: Transrectal high-intensity focused ultrasound in the treatment of localized prostate cancer: a multicenter study. *Hinyokika Kyo*, 2005; 51: 651–58
63. Uchida T, Ohkusa H, Nagata Y et al: Treatment of localized prostate cancer using high-intensity focused ultrasound. *BJU Int*, 2006; 97: 56–61
64. Uchida T, Shoji S, Nakano M et al: Transrectal high-intensity focused ultrasound for the treatment of localized prostate cancer: eight-year experience. *Int J Urol*, 2009; 16: 881–86
65. Barkin J: High intensity focused Ultrasound (HIFU). *Can J Urol*, 2011; 18: 5634–43
66. Zacharakis E, Ahmed HU, Ishag A et al: The feasibility and safety of high intensity focused ultrasound as salvage therapy for recurrent prostate cancer following external beam radiotherapy. *BJU Int*, 2008; 102: 786–92
67. Klotz L: Active surveillance for prostate cancer: patient selection and management. *Curr Oncol*, 2010; 17: 11–17
68. Soloway MS, Soloway CT, Eldefrawy A et al: Careful selection and close monitoring of low-risk prostate cancer patients on active surveillance minimizes the need for treatment. *Eur Urol*, 2010; 58: 831–35
69. Onik G, Narayan P, Vaughan D et al: Focal nerve sparing cryoablation for the treatment of primary prostate cancer: a new approach to preserving potency. *Urology*, 2002; 60: 109–14
70. Bahn DK, Silverman P, Lee Sr F et al: Focal prostate cryoablation: initial results show cancer control and potency preservation. *J Endourol*, 2006; 20: 688–92
71. Onik G, Vaughan D, Lotenföe R et al: Male lumpectomy: focal therapy for prostate cancer using cryoablation. *Urology*, 2007; 70: 18–21
72. Ellis D, Manny TB, Rewcastle JC: Focal cryosurgery followed by penile rehabilitation as primary treatment for localized prostate cancer: initial results. *Urology*, 2007; 70: 9–15
73. Muto S, Takashi Y, Saito K et al: Focal therapy with high intensity – focused-ultrasound in the treatment of localised prostate cancer. *Jpn J Clin Oncol*, 2008; 38: 192–99
74. Eggenger S, Scardino P, Carroll P et al: Focal Therapy for Localized Prostate Cancer: A Critical Appraisal of Rationale and Modalities. *J Urol*, 2007; 178: 2260–67
75. Jolesz FA, Hynynen K: Magnetic resonance image guided focused ultrasound surgery. *Cancer J*, 2002; 8: S100–S12
76. Auboiron V, Petrusca L, Viallon M et al: Ultrasonography based 2D motion compensated HIFU sonication integrated with reference free MR temperature monitoring: a feasibility study *ex vivo*. *Phys Med Biol*, 2012; 57: N159–71
77. Damianou C: MRI monitoring of the effect of tissue interfaces in the penetration of high intensity focused ultrasound in kidney *in vivo*. *Ultrasound Med Biol*, 2004; 30: 1209–15
78. Tempny CM, Stewart EA, McDannold N et al: MR imaging-guided focused ultrasound surgery of uterine leiomyomas: a feasibility study. *Radiology*, 2003; 226: 897–905
79. Siddiqui K, Chopra R, Vedula S et al: MRI guided transurethral ultrasound therapy of the prostate gland using real time thermal mapping: initial studies. *Urology*, 2010; 76: 1506–11
80. McDannold N, Tempny CM, Fennessy FM et al: Uterine leiomyomas: MR imaging based thermometry and thermal dosimetry during focused ultrasound thermal ablation. *Radiology*, 2006; 240: 263–72
81. Jolesz FA, McDannold N: Current status and future potential of MRI guided focused ultrasound surgery. *J. Magn. Reson. Imaging*, 2008; 27: 391–99
82. Ghobrial IM, Witzig TE, Adjei AA: Targeting apoptosis pathways in cancer therapy. *Cancer J Clin*, 2005; 55: 178–94
83. Poff JA, Allen CT, Traugher B et al: Pulsed high intensity focused ultrasound enhances apoptosis and growth inhibition of squamous cell carcinoma xenografts with proteasome inhibitor bortezomib. *Radiology*, 2008; 248: 485–91
84. Cvetkovic D, Chen X, Ma C et al: TH-C-217BCD-01: best in physics (imaging) – evaluation of apoptosis and proliferation in non-thermal pulsed HIFU treated mouse prostate tumors. *Med Phys*, 2012; 39: 4003