



Fatal liver gas gangrene after biliary surgery

Yui Miyata^a, Hiroyuki Kashiwagi^{a,*}, Kazuya Koizumi^b, Jun Kawachi^a, Madoka Kudo^c, Shinichi Teshima^c, Naoko Isogai^a, Katsunori Miyake^a, Rai Shimoyama^a, Ryota Fukai^a, Hidemitsu Ogino^a

^a Department of Surgery, Shonan Kamakura General Hospital, Okamoto 1370-1, Kamakura City, Kanagawa, 247-8533, Japan

^b Department of Gastroenterology Medicine Center, Shonan Kamakura General Hospital, Okamoto 1370-1, Kamakura City, Kanagawa, 247-8533, Japan

^c Department of Pathology, Shonan Kamakura General Hospital, Okamoto 1370-1, Kamakura City, Kanagawa, 247-8533, Japan

ARTICLE INFO

Article history:

Received 9 June 2017

Received in revised form 7 July 2017

Accepted 23 July 2017

Available online 28 July 2017

Keywords:

Fatal liver abscess

Liver gas gangrene

Post biliary reconstruction

ABSTRACT

INTRODUCTION: Liver gas gangrene is a rare condition with a highly mortality rate. It is mostly associated with host factors, such as malignancy and immunosuppression.

PRESENTATION OF CASE: A 57-year-old female was admitted to our hospital with abnormalities of her serum hepato-biliary enzymes. She had a history of hypertension, diabetes mellitus, cerebral infarction, and chronic renal failure. She was diagnosed with bile duct cancer of the liver hilum and a left hepatectomy was carried out, with extrahepatic bile duct resection. Initially her post-operative state was uneventful. However, she suddenly developed melena with anemia on post-operative day (POD) 18. A Computed tomography (CT) examination on POD 19 revealed a massive build up of gas and portal gas formation in the anterior segment of the liver. Although we immediately provided the drainage and a probe laparotomy, she died on POD 20 due to shock with disseminated intravascular coagulation.

DISCUSSION: Liver gas gangrene is rare and has a high mortality rate. This case seems to have arisen from an immunosuppressive state after major surgery with biliary reconstruction for bile duct cancer and subsequent gastrointestinal bleeding, leading to gas gangrene of the liver.

© 2017 The Author(s). Published by Elsevier Ltd on behalf of IJS Publishing Group Ltd. This is an open access article under the CC BY-NC-ND license (<http://creativecommons.org/licenses/by-nc-nd/4.0/>).

1. Introduction

Massive liver gas gangrene is a rare but devastating complication. Mostly *Clostridium perfringens* infection has been described in the literature [1], recent reports however have shown other gut-derived bacteria [2]. Development of this complication is associated with host conditions such as malignancy and immunosuppression. We report a case of liver gas gangrene after biliary surgery and discuss about the etiology with other cases reported in Japan. This work has been reported in line with the SCARE criteria [3].

2. Presentation of case

A 57-year-old female was admitted to our hospital with abnormalities of her serum hepato-biliary enzymes. She had a history of hypertension, diabetes mellitus, cerebral infarction, and chronic kidney disease and was taking medicines for that condition. Although her glomerular filtration rate (GFR) was less than 40 ml, she didn't require hemodialysis. Morphological studies and a biopsy specimen revealed bile duct cancer, located between the

left intra-hepatic duct and right extra-hepatic duct (Fig. 1). We performed a left hepatectomy with extrahepatic bile duct resection. The anterior and posterior branches of the bile duct were reconstructed separately. Her post-operative course was normal until post-operative day (POD) 18, except for a small amount of bile leakage from the resected surface. She could walk to the cafeteria and take some coffee. On POD 18, she suddenly developed melena with anemia. An emergency endoscopic examination of the upper gastro-intestinal (GI) tract was unremarkable. A computed tomography (CT) examination showed a tiny gas formation in the liver but no massive bleeding in the GI tract. She had complained abdominal discomfort then. A CT examination on POD 19 revealed a massive build up of gas and portal gas in the anterior segment of the liver (Fig. 2). Simultaneously, her conscious level worsened and mechanical ventilation was required. Serum hepato-biliary enzymes were elevated and severe acidosis was shown in her blood samples (Table 2). We performed percutaneous drainage for the gas forming area immediately and started intensive care for her shock condition. Then, a probe laparotomy was planned for her GI bleeding after negative findings on interventional angiography and colonoscopy. The colonoscopy findings revealed massive intestinal bleeding from the oral side of the Bauhin (ileocecal) valve. Intra-operative findings showed the disrupted surface of the anterior segment of liver and partial necrosis of the small intestine (Fig. 3).

* Corresponding author.

E-mail address: hiroyukiwagi1967@yahoo.co.jp (H. Kashiwagi).

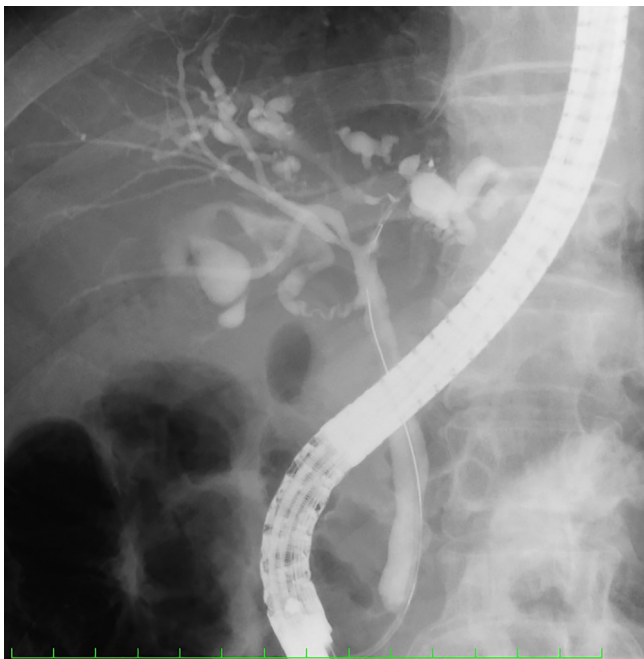


Fig. 1. Cholangiography by ERCP showing biliary stenosis in the liver hilum.

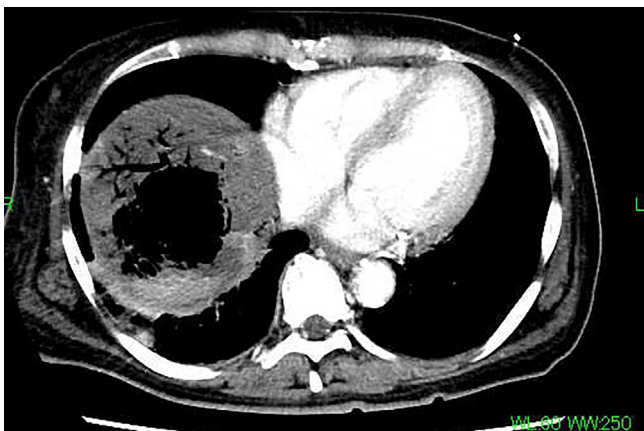


Fig. 2. Enhanced CT scan showing gas accumulation in the anterior segment of the liver. Portal gas is also detected.

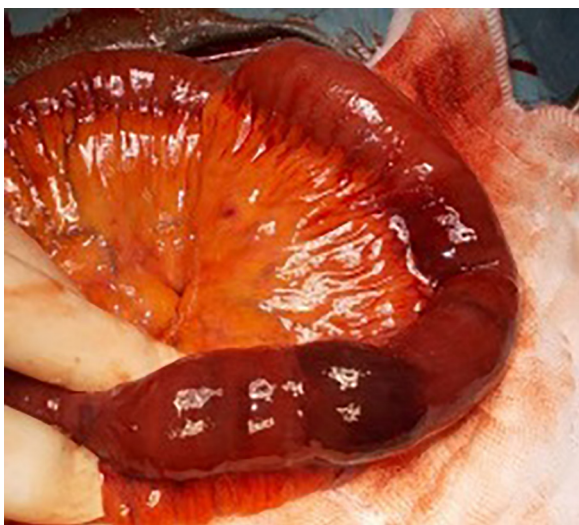


Fig. 3. Intra-operative findings shows an ischemic area of small intestine. Resected specimen was diagnosed as a necrosis of small intestine by pathological confirmation.

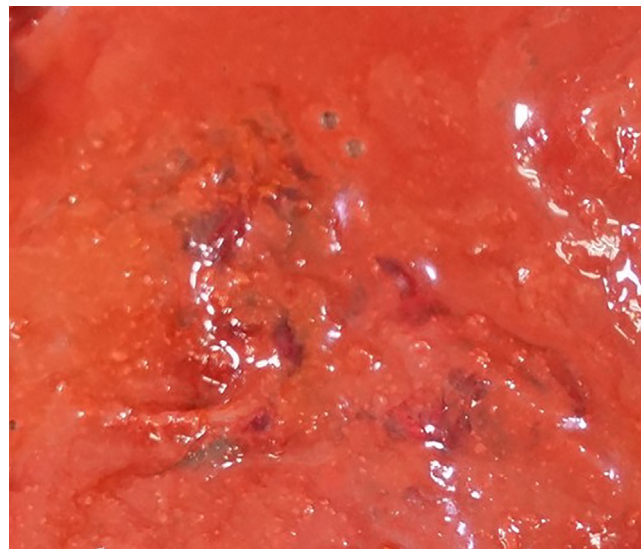


Fig. 4. Autopsy findings showed sponge-like appearance of anterior segment of liver.

Surgical debridement of the liver surface with saline lavage, gauze packing on the debridement part, and partial resection of the small intestine were performed. After surgery, shock and a disseminated intravascular coagulation (DIC) state continued and she died on POD 20. The autopsy findings revealed the sponge-like appearance of the anterior segment of liver (Fig. 4). Necrotic membrane with bleeding was seen in the mucosal layer of the resected intestine. Arterial thrombosis was not seen in superior mesenteric artery, common hepatic artery, or peripheral vessels of small intestine. Enterococcus species and *Klebsiella pneumoniae* were detected in the blood and drainage samples. Serum endotoxin was negative.

3. Discussion

Since the first description of gas gangrene of an organ by Fraenkel in 1889, few cases of acute organ failure following acute *Clostridium perfringens* infection have been described in the literature [4]. Up to the middle of the last century, generalized gas gangrene was most often a consequence of soil-contaminated war wounds and was mostly lethal [5]. Today, gas gangrene has been classified into three types: post-traumatic, post-operative and spontaneous [4]. This last type is often observed on a background of malignant or immunosuppressive primary disease. *Clostridium perfringens* infection has mostly been described in the literature, however recent reports have shown other gut-derived bacteria, such as *E. coli*, *Enterococcus* and *Klebsiella* species [6]. Because gas gangrene caused by clostridia and several other species occurs in anaerobic condition, gas gangrene of blood enriched organs such as liver seems to be extremely rare.

Nine publications were reported by Ichushiweb in Japan from 1979 [2,7–11]. Table 1 shows the patient's characteristics and a short summary of liver gas gangrene, including our case. The outcomes of the reported cases were dismal and showed rapid progression. Nine cases (90%) were fatal, four (40%) within 6 h of arrival at the hospital or diagnosis. *Clostridium perfringens* was detected in blood samples from these 4 cases. Seventy percent of the patients had a history of malignant disease and, in 2 of 7 cases with hepatocellular carcinoma, the liver gas gangrene developed after embolic treatment for hepatocellular carcinoma. Interestingly, 70% of the cases had the previous surgical treatment for primary malignant disease and liver gas gangrene had occurred within 70 (6–70) days after treatment, except for 2 poorly described cases (Table 1). In

Table 1
Japanese reported cases of liver gas gangrene.

Year	Author	Age	Primary disease	Past History	Previous treatment for primary disease	Time to LGG development from 1st. Surgery	Surgical Treatment for LGG	Blood cultures	Outcome	Time to Death after diagnosis
1979	Konishi	52	Gastric Cancer/Necrotizing cholecystitis	None	Surgery (Appleby ope.)	53 days	Surgical drainage	E. coli	Death	8 days
1992	Yoshida	67	Duodenal Cancer	None	Surgery (biliary reconstruction(+))	70 days	Conservative	C. perfringens, E. coli	Death	3 days
2000	Aoki	83	Liver gas gangrene	Acute Pancreatitis	None	-	Conservative	C. perfringens	Death	5 h
2004	Ohtani	73	Necrotizing cholecystitis	Diabetes Mellitus, Hypertension	PTCGBD	Simultaneously	Percutaneous Drainage	C. perfringens	Death	6 h
2011	Kishi	70	Gallbladder Cancer	Hypertension	Surgery (biliary reconstruction(+))	Not described	Conservative	C. perfringens	Death	3 days
2013	Nakano	60	Pancreas Cancer	COPD	Surgery (biliary reconstruction(+))	6 days	Surgical drainage	Enterobacter cloacae	Alive	-
2013	Watanabe	60s	Hepatocellular Carcinoma	Multiple Myeloma, Bladder cancer	Transarterial intervention	7 days	Conservative	C. perfringens	Death	3 h
2015	Echigoya	84	Liver gas gangrene	Not described	None	-	Surgical drainage	C. perfringens	Death	5 h
2016	Kondo	60s	Hepatocellular Carcinoma	Not described	Transarterial intervention Percutaneous ablation	Not described	Conservative	C. perfringens	Death	Not described
2016	Miyata	57	Bile duct cancer	Hypertension, Diabetes Mellitus, Cerebral Infarction	Surgery (biliary reconstruction(+))	19 days	Surgical drainage	Enterococcus, Klebsiella pneumoniae	Death	3 days

Table 2
Laboratory Findings on POD 19.

Blood Counts	Blood Chemistry	Coagulation & Arterial Blood Gas
Hb 8.0 g/dl	AST 938 IU/l	PT 16.1 s
WBC 25300 /μl	ALT 319 IU/l	APTT 32.6 s
Platelet 21.1 × 10 ⁴	γ-GTP 87 IU/l	PT-INR 1.4
	T.Bil. 5.0 mg/dl	
	BUN 44.9 mg/dl	pH 7.056
	Crea 1.1 mg/dl	pCO2 19.8 mmHg
	Alb 2.3 g/dl	pO2 505.3 mmHg
	CRP 13.1 mg/dl	HCO3 5.4 mmol/l
		BE -22.6 mmol/l
		(Under FiO ₂ 1.0 ventilation)

two cases, the gangrene was followed by necrotizing cholecystitis. Therefore, a treatment history of malignant disease, an ischemic condition of the liver and inflammation of other neighboring organs may be the crucial risk factors of liver gas gangrene.

Another risk is biliary reconstruction. In the literature, some descriptions of a higher incidence of liver abscess after biliary-enteric anastomosis [12], or endoscopic interventions such as papillotomy and stent implantation, have been reported because bacterial invasion of the bile duct may occur after loss of protection by the papillae [4]. A high frequency of surgical site infections (SSIs) after hepato-pancreatic-biliary (HBP) surgery, including biliary reconstruction, was also reported in a trial of antimicrobial therapy [13]. Because 40% of Japanese cases had HBP surgery with biliary reconstruction, prophylactic antibiotics could be considered to avoid this critical condition, if the patient has other systemic risks.

In this case, the primary malignant disease and biliary reconstruction by a Roux-Y hepatico-jejunostomy appears to have been the cause of gas gangrene of the liver. Cardio-vascular risks such as a history of cerebral infarction, hypertension, and diabetes mellitus, might be additional factors. The origin was probably invasion by gut-derived bacteria. Besides the bacterial invasion, an immunosuppressive condition followed by major surgery, and ischemic GI bleeding may also have had some influence.

4. Conclusion

We report a fatal case of liver gas gangrene. The immunosuppressive condition of the patient and biliary reconstruction seems to have led to progression to gas gangrene of the liver.

Conflict of interest statement

None.

Funding

This research did not receive any specific grant from funding agencies in the public, commercial, or not-for-profit sectors.

Ethical approval

Written informed consent was obtained from the patient for publication of this case report and accompanying images.

Consent

Written informed consent was obtained from the patient for publication of this case report and accompanying images.

Author contributions

Dr. Yui Miyata is the first author and drafted manuscript. Dr. Hiroyuki Kashiwagi is the corresponding author, drafted and finalized the manuscript. Dr. Madoka Kudo and Dr. Shinichi Teshima are pathologist and confirmed pathological findings including at autopsy. Dr. Koizumi made critical diagnosis in this study. Other doctors, Jun Kawachi, Naoko Isogai, Katsunori Miyake, Rai Shimoyama, Ryota Fukai and Hidemitsu Ogino have cooperated in this manuscript.

Disclosure statement

We, the authors, disclose that we have not received any payment or services from a third party that are related to this research.

Guarantor

Hiroyuki Kashiwagi.

References

- [1] S. Kuroda, Y. Okada, M. Mita, Y. Okamoto, H. Kato, S. Ueyama, I. Fujii, S. Morita, Y. Yoshida, Fulminant massive gas gangrene caused by *Clostridium perfringens*, *Intern. Med.* 44 (5) (2005) 499–502.
- [2] M. Nakano, H. Okamoto, T. Okamura, K. Ono, Y. Tamiya, A case of hepatic gas gangrene with disseminated intravascular coagulation and multiple organ failure successfully treated with repeated necrosectomy, *Jpn. J. Gastroenterol. Surg.* 46 (6) (2013) 416–423.
- [3] R.A. Agha, A.J. Fowler, A. Saeta, I. Barai, S. Rajmohan, D.P. Orgill, S. Group, The SCARE statement: consensus-based surgical case report guidelines, *Int. J. Surg.* 34 (2016) 180–186.
- [4] H. Bergert, T. Illert, K. Friedrich, D. Ockert, Fulminant liver failure following infection by *Clostridium perfringens*, *Surg. Infect. (Larchmt.)* 5 (2) (2004) 205–209.
- [5] D.L. Stevens, M.J. Aldape, A.E. Bryant, Life-threatening clostridial infections, *Anaerobe* 18 (2) (2012) 254–259.
- [6] S. Doblecki-Lewis, E. Palaios, P.A. Bejarano, A.G. Tzakis, G. Selvaggi, M.I. Morris, Hepatic gas gangrene following orthotopic liver transplantation: three cases treated with re-transplantation and a review of the literature, *Transpl. Infect. Dis.* 10 (4) (2008) 280–285.
- [7] K. Konishi, K. Miwa, O. Nagata, M. Yamagishi, I. Miyazaki, A case of hepatic gas gangrene, *Shokakigeka* 2 (6) (1979) 1245–1250.
- [8] M. Yoshida, M. Ryu, Y. Fujita, I. Honda, S. Watanabe, Y. Kawakami, M. Miyauchi, W. Takayama, M. Hirokawa, K. Sasada, S. Wakatsuki, An autopsy case of clostridial gas gangrene of liver, *Jpn. J. Gastroenterol. Surg.* 25 (8) (1992) 2181–2185.
- [9] Y. Watanabe, S. Monzawa, N. Yuasa, A. Higashida, H. Yamada, Fatal hepatic gas gangrene due to *clostridium perfringens* infection after transcatheter arterial chemoembolization, *Jpn. J. Intervent. Radiol.* 28 (2013) 058–061.
- [10] R. Echigoya, A. Kuriyama, N. Umakoshi, Hepatic gas gangrene, *Intern. Med.* 54 (2014) 1319.
- [11] T. Kondo, An autopsy case of hepatic gas gangrene due to *clostridium perfringens*, *Intern. Med.* 117 (2) (2014) 303.
- [12] M.G. Buimer, E.J. Spillenaar Bilgen, Gas gangrene of the liver after a choledoch-jejunostomy, *Dig. Surg.* 25 (4) (2008) 260–261.
- [13] K. Okamura, K. Tanaka, T. Miura, Y. Nakanishi, T. Noji, T. Nakamura, T. Tsuchikawa, K. Okamura, T. Shichinohe, S. Hirano, Randomized controlled trial of perioperative antimicrobial therapy based on the results of preoperative bile cultures in patients undergoing biliary reconstruction, *J. Hepato-biliary-pancreatic Sci.* 24 (7) (2017) 382–393.

Open Access

This article is published Open Access at sciedirect.com. It is distributed under the [IJSCR Supplemental terms and conditions](#), which permits unrestricted non commercial use, distribution, and reproduction in any medium, provided the original authors and source are credited.